

Duan Deng - Hui (Orcid ID: 0000-0003-2547-7246)

Wang Hom - Lay (Orcid ID: 0000-0003-4238-1799)

Title: Bone regeneration using titanium plate stabilization for the treatment of peri-implant bone defects: A retrospective radiologic pilot study

Running title: Bone regeneration using titanium plate stabilization

Authors:

Deng-Hui Duan, DDS; Department of Oral and Maxillofacial Surgery, Peking University School and Hospital of Stomatology, No. 22, Zhongguancun South Avenue, HaiDian District, Beijing, 100081, P.R. China.

Hom-Lay Wang, DDS, PhD; Department of Periodontics and Oral Medicine, School of Dentistry, University of Michigan, Ann Arbor, MI, 48109, USA.

Wu-Cai Xiao, MPH; Department of Maternal and Child Health, School of Public Health, Peking University, No. 38, Xueyuan Road, Haidian District, Beijing 100191, P.R. China.

Zheng Liu, PhD; Department of Maternal and Child Health, School of Public Health, Peking University, No. 38, Xueyuan Road, Haidian District, Beijing 100191, P.R. China.

This is the author manuscript accepted for publication and has undergone full peer review but has not been through the copyediting, typesetting, pagination and proofreading process, which may lead to differences between this version and the Version of Record. Please cite this article as doi: [10.1111/cid.13139](https://doi.org/10.1111/cid.13139)

This article is protected by copyright. All rights reserved.

En-Bo Wang, DDS; Department of Oral and Maxillofacial Surgery, Peking University School and Hospital of Stomatology, No. 22, Zhongguancun South Avenue, HaiDian District, Beijing, 100081, P.R. China.

Corresponding Author:

En-Bo Wang, Department of Oral and Maxillofacial Surgery, Peking University School and Hospital of Stomatology, No. 22, Zhongguancun South Avenue, HaiDian District, Beijing, 100081, P.R. China. E-mail: ebwang-hlg@163.com

Author contributions: DHD contributed to the surgical conception and design; data acquisition, analysis, and interpretation; and drafting of the manuscript. EBW contributed to the surgical conception and design, interpretation of important intellectual content, and final approval. WCX and ZL contributed to statistical analysis. HLW contributed to the critical revision of the manuscript and final approval.

Funding information: This study was performed in Peking University School and Hospital of Stomatology, Beijing, China, and supported by National Nature Science Foundation of China (81903343).

Conflicts of Interest: All authors do not have any financial interests, either directly or indirectly, in the products or information listed in the paper.

Ethics Statement: Ethical approval was obtained from the ethics committee of Peking University School and Hospital of Stomatology.

Data Availability Statement: The data sets used and/or analyzed during the current study are available from the corresponding author on reasonable request

Abstract

Aim: To 3-dimensional radiographically assess the effect of titanium plate in guided bone regeneration (GBR) for the treatment of peri-implant ridge defects in esthetic zone.

Material and methods: Nineteen patients with buccal peri-implant defects in the maxillary esthetic zone were treated with GBR using xenograft, autogenous bone, and collagen membrane. Subjects were divided into two groups: control (conventional GBR, ten patients with sixteen implants) and test (GBR with an adjunctive titanium plate; nine patients with fifteen implants). Cone-beam computed tomography (CBCT) images obtained immediately after and 5–7 months following GBR were used to assess buccal crestal bone level (BBL) and

buccal bone thickness (BBT) at different implant levels.

Results: Thirty-one implants in 19 patients were evaluated. Titanium plate exposure occurred in 3 cases (33.33%) of the test group. After 5-7 months, the mean BBL was located 1.48 ± 0.71 mm coronal to the platform in the test group and 0.90 ± 3.03 mm coronal to the platform in the control group ($p = 0.03$). The mean over all BBT (BBT-M) was 4.16 ± 0.48 mm in the test group and 2.38 ± 0.97 mm in the control group ($p < 0.01$). More resorption occurred in the control group than in the test group regarding mean BBL (3.00 ± 3.11 mm vs 0.78 ± 0.79 mm, respectively; $p = 0.04$), BBT-M change (1.87 ± 1.59 mm vs 0.56 ± 0.33 mm, respectively; $p = 0.02$), and percentage change in BBT-M ($40.69 \pm 24.01\%$ vs $11.53 \pm 5.86\%$, respectively; $p < 0.01$).

Conclusion: In the short-term, titanium plate-enhanced GBR maintained ridge dimensions better than conventional GBR did.

What is known:

Preserving the ridge morphology created during guided bone regeneration at the implant platform is difficult; various rigid support structures have been used to protect surgical sites, though exposure of these materials during healing may impair results. This study evaluated applying a titanium plate for space creation and maintenance to further improve bone regeneration.

What this study adds:

Using titanium plate with GBR for peri-implant defects led to more coronal

alveolar crest levels, thicker buccal plates, and less bone resorption compared with the conventional GBR approach.

KEYWORDS: bone regeneration; alveolar ridge augmentation; dental implants; cone-beam computed tomography

1. INTRODUCTION

Guided bone regeneration (GBR) using particulate bone graft with a collagen membrane is commonly employed to resolve peri-implant ridge defects^{1,2,3}. However, the stability of the surgically created ridge contour at the level of implant platform and along the buccal aspect is unpredictable; up to 68.9% of horizontal collapse may occur post-healing especially when absorbable membranes were used⁴⁻⁷, possibly due to pressure on the surgical site from the perioral muscles that apically displaces the graft and/or accelerates its absorption^{5, 8-10}.

To counteract these muscle forces, rigid support structures - tenting screws, titanium-reinforced polytetrafluorethylene membrane (TR-PTFE), and titanium mesh -- have been used to safeguard GBR spaces¹¹⁻¹⁷. Despite their high clinical success rates, these structures exhibit some disadvantages: (1) their surgical manipulation is relatively time-consuming and complicated¹⁸; (2) exposure during healing and subsequent graft infection may undermine regeneration¹⁹⁻²⁶; (3) extensive flap elevation may be required to remove the device(s); (4) some methods cannot be performed concurrently with implant placement, e.g., tenting-screw augmentation^{12, 17}.

Merli and his colleagues introduced the fence technique for GBR, where a titanium osteosynthesis plate, immediately beneath the barrier membrane, was

fixed by titanium screw to protect and to prevent grafted bone substitute from perioral muscle force²⁷⁻³². Stability of vertically augmented areas was therefore observed^{28,29,30}. However, the influence of such anchorage on horizontal augmentation was reported in limited cases^{27, 31, 32}, and the fence technique was performed prior to, not with, implant placement.

Our pilot study analyzed morphological ridge changes following titanium plate-enhanced guided bone regeneration for peri-implant ridge defects in the esthetic zone.

2. MATERIAL AND METHODS

2.1 Patient selection

Consecutive patients who underwent GBR with implant placement at the Department of Oral and Maxillofacial Surgery, Peking University School and Hospital of Stomatology, Beijing, China, from August 2019 to December 2021 were reviewed. A total of 19 patients, including 10 patients with GBR treated in a traditional manner from August 2019 to October 2020 (control group) and 9 patients with titanium plate assisted GBR treated from October 2020 to December 2021 (test group), were included in this retrospective study. All patients were selected from the consecutive surgeries in both groups. All treated patients were included in the study no matter if they have treatment

failure or not.” Patients meeting the following inclusion criteria were enrolled: (1) age ≥ 19 years; (2) ≤ 3 consecutive missing teeth in the maxillary esthetic zone, including first premolars; (3) Terheyden type 2/4 alveolar ridge defects³³; (4) two sets of cone-beam computed tomography (CBCT) data available (immediately after GBR and 5–7 months after GBR); and (5) healthy status of all teeth. Exclusion criteria included (1) any medical contraindication for oral surgery; (2) ongoing immunosuppressant, corticosteroid, or bisphosphonate therapy; and (3) smoking > 10 cigarettes per day.

All patients were informed of the treatment protocol, signed informed consent, and were treated in accordance with the 1975 Declaration of Helsinki and its revision in 2013. The study protocol was approved by the Institutional Review Board of Peking University School and Hospital of Stomatology, Beijing, China (approval number: PKUSSIRB-202171209). The STROBE guidelines were followed. The study protocol is summarized in Figure 1.

2.2 Treatment procedures

After local infiltration anesthesia, a mid-crestal incision was made at the ridge and vertical releases were placed at the line angles of teeth 1 - 2 units mesial and distal to the edentulous region. Full-thickness buccal and palatal mucoperiosteal flaps were raised. The buccolingual dimension at the alveolar crest was measured with a periodontal probe (15 UNC, Hu-Friedy, Chicago, IL,

USA). Per manufacturer's instructions, 10 mm-long implants of 3.3 mm or 4.1 mm diameter were placed in prosthetically driven positions (Bone Level, Straumann, Basel, Switzerland) and capped with 2 mm-tall healing abutments. A collagen membrane (Bio-Gide, Geistlich Pharma AG, Wolhusen, Switzerland) was trimmed, placed buccally, and fixed apically with a minimum of two titanium tacks. Autogenous particles were harvested from the adjacent ridge to cover exposed implant surfaces and deproteinized bovine bone mineral (DBBM) (Bio-Oss, Geistlich Pharma AG, Wolhusen, Switzerland) was overlaid over the autograft, up to the level of healing abutment. The membrane was stretched tightly over the graft and sutured to the palatal mucosal flap. Additional particulate was placed to fill the created space under the membrane. In the test group, a titanium osteosynthesis plate with a 0.6 mm thickness and 3.8 mm width (Micro titanium plate, Cibe Medical, Ningbo, China) was trimmed at its termini and shaped to parallel the alveolar ridge contour, then secured to the buccal plate at each terminus with 1–2 titanium micro screws prior to membrane and graft placement; the collagen membrane was laid over the titanium plate. Periosteal releasing incisions were made at the buccal flap to achieve passive primary wound closure (Figure 2A–H).

The postoperative regimen included a 5-day antibiotic course (amoxicillin 1 g BID or, in the case of penicillin allergy, erythromycin 600 mg BID), oral rinsing (0.2% chlorhexidine 15 ml TID) for 1 week, and analgesics (ibuprofen 600 mg)

as needed. After 1–2 weeks, sutures were removed. Patients were recalled monthly post-GBR to check healing. Reentry surgery was performed after 5–7 months to remove fixation devices and place taller healing abutments as needed (Figure 2 I – O). The implants were restored with single screw-retained zirconia crowns 1–2 months after the implant second stage surgery.

2.3 Radiographic evaluation

Scans of all implants were performed (FOV diameter, 10 cm; FOV height, 5.6 cm, acceleration voltage, 90 kV; beam current, 8.0 mA; voxel size, 0.2 mm) with a CBCT machine (3DX Accuitomo, Morita, Kyoto, Japan) immediately following GBR (T1) and 5–7 months after GBR (T2, immediately prior to reentry surgery) and were exported as DICOM-format files. To determine morphological changes of the alveolar ridge after GBR, volumetric imaging software (Mimics 15.0, Materialise, Leuven, Belgium) was used.

The following outcome variables at each implant site were measured on the coronal view (Figure 3):

1. Titanium plate level (TPL), which was vertical distance from the apical rim of the titanium plate to the implant platform. Taken at T1 in test group.
2. Planned buccal bone thickness (BBT-P), which was the lateral distance from the apical rim of the titanium plate to the buccal implant surface. Taken at T1 and T2 in test group.
3. Augmented buccal bone thickness (BBT-A), which was the bone graft/bone

thickness buccal to the implant surface at the level of apical rim of the titanium plate. Taken at T1 and T2 in test group.

4. Buccal bone thickness (BBT-0 to BBT-10), which was the bone graft/bone thickness buccal to the implant surface at levels 0 mm, 2 mm, 4 mm, 6 mm, 8 mm, and 10 mm apical to the implant platform. Taken at T1 and T2 in both groups. BBT-M was defined as mean buccal bone thickness of all implant levels.

5. Buccal bone level (BBL), which was the vertical distance from the implant platform to the alveolar crest. This measurement was given a negative value if the alveolar crest was apical to the implant platform. Taken at T1 and T2 in both groups.

All CBCT measurements were performed by a single calibrated examiner (DHD). Intra-examiner repeatability was assessed using intra-class correlation coefficients of 10 pairs of randomly selected recordings³⁴. The coefficients of intra-examiner repeatability for BBT and BBL were at least 0.95.

2.4 Statistical evaluation

Data management and analysis were performed using STATA (V.16.0, StataCorp LLC, Texas, USA) software. Results of the descriptive analyses were expressed as the mean \pm SD. The difference of age and gender between the control and test group were tested with independent samples *t*-test and Chi square test, respectively. To address the statistical issues of clustered data (i.e., a patient contains more than one implant) and small sample size in this

study, multi-level mixed-effects linear regression was applied for statistical test³⁵.

For all tests, a p value < 0.05 was considered significantly.

3. RESULTS

A total of 19 patients with 31 implants placed in the esthetic zone, including 10 patients with 16 implants in the control group and 9 patients with 15 implants in the test group, were included in this retrospective study. The overall mean age was 45.3 ± 12.5 years, ranging from 29 to 61 years. Females comprised 63.16% of the study population. No significant differences in age or gender were found between the test and control groups ($p > 0.05$). In the test group, implant sites included 12 incisors, 2 canines, and 1 first premolar; in the control group, implant sites included 14 incisors, 1 canine, and 1 first premolar. The mean initial alveolar ridge width at implant level was 4.30 ± 0.99 mm in the test group and 4.97 ± 0.75 mm in the control group; no significant difference between groups was present ($p = 0.13$).

Uneventful soft tissue healing occurred in all cases except for three test group patients (33.3%) (Figure 4). One patient presented with exposure of a titanium micro-screw at the cutting end (terminus) of the plate 3 months after GBR. One patient presented with exposure of a titanium micro-screw at the cutting end of the plate and of an adjacent plate ring, infiltrated with mucosa, 2 months after GBR. One patient presented with exposure of three adjacent

terminal plate rings, infiltrated with mucosa, 3 months after GBR. No obvious signs of infection were identified in these cases, and no treatment other than thorough oral hygiene was administered. At reentry (T2, 5-7 months after GBR surgery), all implants had osseointegrated and were immobile under torque of 35 N-cm. In all test group cases, fibrous tissue formation under the titanium plates was detected (Figure 3 K - N). Compared with non-exposed sites, exposed sites demonstrated more fibrous tissue and less graft maturation (e.g., more soft bone appearance).

Table 1 details buccal dimensions relative to the apical rim of the titanium plate at implant level. Immediately following GBR (T1, immediately after GBR surgery), the titanium plates were fixed to the buccal ridge with their apical rims at a mean 2.35 ± 1.55 mm apical to the implant platform. The alveolar ridge at this level was labially over-augmented with bone graft by a mean of 0.61 ± 0.68 mm ($p < 0.01$), or by $15.85 \pm 18.44\%$. At reentry, BBT-A was less than BBT-P by -0.26 ± 0.36 mm ($p < 0.01$), or by $-5.55 \pm 7.67\%$. From T1 to T2, the augmented buccal thickness (BBT-A) shrunk significantly by a mean of 0.91 ± 0.56 mm ($p < 0.01$), equivalent to a $17.79 \pm 11.02\%$ decrease.

Table 2 details buccal dimensions relative to the implant platform at implant level. Immediately following GBR (T1), there was no difference between control and test groups except in BBT-4 and BBT-6 ($p < 0.05$) (Table 2). At reentry (T2), significant mean and all individual-level differences of BBT were observed

between the groups. The test group had a significantly thicker mean alveolar ridge (BBT-M of 4.16 ± 0.48 mm) than the control group (BBT-M of 2.38 ± 0.97 mm) ($p < 0.01$). From T1 to T2, greater mean bone graft resorption occurred in the control group than in the test group. The BBT-M change was 0.56 ± 0.33 mm for the test group and 1.87 ± 1.59 mm for the control group and was significantly different between groups ($p = 0.02$). The mean percentage of change in BBT of the control group ($40.69 \pm 24.01\%$) was nearly four times that of the test group ($11.53 \pm 5.86\%$) ($p < 0.01$).

Table 3 summarizes the crestal bone level dimensions buccally. At T1, no difference in BBL between the test and control group was present ($p = 0.92$). At T2, a significant difference between groups was seen ($p = 0.03$), with the test group BBL located 1.48 ± 0.71 mm coronal to the implant platform and the control group BBL located 0.90 ± 3.03 mm coronal to the platform. From T1 to T2, more vertical resorption occurred in the control group (3.00 ± 3.11 mm) than in the test group (0.78 ± 0.79 mm) ($p = 0.04$).

4. DISCUSSION

Space maintenance is a requisite for predictable GBR “PASS” principle³⁶. Placing particulate bone graft in the space created by a membrane³⁷ helps to buttress the barrier, providing an environment conducive to regeneration. However, displacement and premature absorption of the membrane and graft

can occur, even after “tension-free” closure, from perioral muscle traction that shifts materials apically^{8-10, 38}; this issue is especially problematic in the esthetic zone. Our results suggest that using a titanium plate rigid support structure in GBR may better preserve space and reduce collapse vertically and buccally, especially at implant platform level. At reentry, the mean crestal buccal bone level (BBL) in the titanium plate test group was 2.38 mm more coronal to that of the no titanium plate control group (1.48 ± 0.71 mm vs -0.90 ± 3.03 mm, respectively; $p = 0.03$), respectively). The mean buccal bone thickness (BBT-M) achieved in the test group was nearly three times that of the control group (4.16 ± 0.48 mm vs 2.38 ± 0.97 mm). The control group demonstrated almost three to four times more buccal resorption than the test group based on BBT-M change (1.87 ± 1.59 mm vs 0.56 ± 0.33 mm) and percentage of BBT-M change ($40.69 \pm 24.01\%$ vs $11.53 \pm 5.86\%$).

Other investigations have observed BBT-0 and BBT-2 to be 0.58–1.31 mm and 1.90–2.02 mm, respectively, immediately following GBR with collagen membrane and bone particulate^{4, 7}. After healing, BBT-0 and BBT-2 decreased by 1.05–1.68 mm and 0.71–1.70 mm, respectively^{4, 7}, and the crestal bone level at the buccal was found to be 0.35–0.77 mm apical to the implant platform^{13, 15}. However, greater ridge volume has been obtained using adjunctive titanium mesh or TR-PTFE, with BBL at reentry ranging from -0.22–1.44 mm coronal to the implant platform^{13, 15, 39, 40}; BBT-0 and BBT-2 at reentry of 2.0–3.01 mm¹³,

³⁹⁻⁴¹ and 2.74–2.86 mm^{39, 40}, respectively; and losses in BBT-0 and BBT-2 from initial surgery to reentry of 0.14–0.30 mm^{13, 40} and 0.29 mm⁴⁰, respectively.

Our results align with or slightly surpass those figures; at reentry, BBL of the test group was 1.48 mm coronal to the implant platform, whereas that of the control group was 0.90 mm coronal to the platform. In the test group, the losses in BBT-0 and BBT-2 from initial surgery to reentry were 0.53 mm and 1.19 mm, respectively. In contrast, the control group had the losses in BBT-0 and BBT-2 from initial surgery to reentry were 2.55 mm and 2.51 mm, respectively. Utilizing a titanium plate may afford a more favorable alveolar contour compared with applying a membrane only or even titanium mesh or TR-PTFE. Our superior results may be due to formation of a larger space at the alveolar crest via more rigid tenting of the titanium plate that was anchored near the implant platform, thus buffering that vital area from muscle pull.

We fixed the apical rims of the titanium plates to the ridge a mean 2.35 mm apical to the implant platform. Lateral resorption was noted 2 mm apical to the platform, with a mean loss of 1.19 mm, equivalent to 22.33% resorption, from initial surgery to reentry. As we over-augmented the graft, layering it labial to the titanium plate, unshielded material may have been vulnerable to muscle compression and apically displaced. At the apical rim of the titanium plate, a mean BBT loss (BBT-P minus BBT-A at T2) of 0.26 mm occurred over time,

equivalent to a 5.55% decrease, which was consistent with a 0.33 mm deviation reported in a GBR study on three-dimensional printed titanium mesh⁴².

Titanium plate exposure occurred in 33.3% of our test patients, a figure higher than the 23.9% reported by a meta-analysis reviewing GBR with titanium mesh and absorbable membranes²³. The possible explanation for the high titanium plate exposure may be attributed to the learning curve since all these 3 exposures occurred in the early stages of the study. In addition, mesh exposure frequently develops in a regeneratively important location²⁶. However, plates were exposed at their lateral termini, relatively far away from the augmented region, and any major impact on peri-implant bone was avoided. Compared with other rigid support structures, a titanium plate is more easily shaped to parallel the curved alveolar ridge and more easily removed; these advantages, along with its better GBR stabilization at reentry, make it a viable alternative to titanium mesh, especially in a 3-D printed form.

As our study was retrospective and non-randomized with a small number of patients, short follow-up period, and no post-reentry evaluation, results should be interpreted with caution. Future study with larger sample size and longer follow-up are needed to understand if titanium plate-enhanced GBR can generate new bone, treat extensive defects, and preserve ridge contours or esthetics over time. At this moment, we are continuing to follow the patients enrolled in this initial pilot study.

5. CONCLUSIONS

Titanium plate-enhanced guided bone regeneration for peri-implant ridge defects in the esthetic zone may confer greater hard tissue volume stability than GBR with only collagen membrane and graft. Long-term data following functional loading are required before recommending this technique for daily practice.

REFERENCES

1. Jung RE, Fenner N, Hämmerle CH, Zitzmann NU. Long-term outcome of implants placed with guided bone regeneration (GBR) using resorbable and non-resorbable membranes after 12-14 years. *Clin Oral Implants Res.* 2013;24(10):1065-73.
2. Thoma DS, Bienz SP, Figuero E, Jung RE, Sanz-Martin I. Efficacy of lateral bone augmentation performed simultaneously with dental implant placement: A systematic review and meta-analysis. *J Clin Periodontol.* 2019;46 Suppl 21:257-76.
3. Hammerle CH, Jung RE, Feloutzis A. A systematic review of the survival of implants in bone sites augmented with barrier membranes (guided bone regeneration) in partially edentulous patients. *J Clin Periodontol.* 2002;29 Suppl 3:226-31; discussion 32-3.
4. Fu JH, Oh TJ, Benavides E, Rudek I, Wang HL. A randomized clinical trial evaluating the efficacy of the sandwich bone augmentation technique in increasing buccal bone thickness during implant placement surgery: I. Clinical and radiographic parameters. *Clin Oral Implants Res.* 2014;25(4):458-67.
5. Benic GI, Thoma DS, Jung RE, Sanz-Martin I, Unger S, Cantalapedra A, et al. Guided bone regeneration with particulate vs. block xenogenic bone substitutes: a pilot cone beam computed tomographic investigation. *Clin Oral Implants Res.* 2017;28(11):e262-e70.
6. Jung EH, Jeong SN, Lee JH. Augmentation stability and early wound healing outcomes of guided bone regeneration in peri-implant dehiscence

defects with L- and I-shaped soft block bone substitutes: A clinical and radiographic study. *Clin Oral Implants Res.* 2021;32(11):1308-17.

7. Ye GH, Duan DH, Wang EB. Ridge Volume Stability of Maxillary Anterior Implants Placed with Simultaneous Lateral Guided Bone Regeneration during Healing: a Radiographic Analysis. *Chin J Dent Res.* 2021;24(4):251-6.

8. Mir-Mari J, Wui H, Jung RE, Hammerle CH, Benic GI. Influence of blinded wound closure on the volume stability of different GBR materials: an in vitro cone-beam computed tomographic examination. *Clin Oral Implants Res.* 2016;27(2):258-65.

9. Nagy P, Molnar B, Nemes B, Schupbach P, Windisch P. Histologic Evaluation of Human Intrabony Periodontal Defects Treated with Deproteinized Bovine Bone Mineral in Combination with Orthodontic Tooth Movement: A Case Series. *Int J Periodontics Restorative Dent.* 2019;40(3):321–30.

10. Araújo MG, Carmagnola D, Berglundh T, Thilander B, Lindhe J. Orthodontic movement in bone defects augmented with Bio-Oss. An experimental study in dogs. *J Clin Periodontol.* 2001;28(1):73-80.

11. Farias D, Caceres F, Sanz A, Olate S. Horizontal Bone Augmentation in the Posterior Atrophic Mandible and Dental Implant Stability Using the Tenting Screw Technique. *Int J Periodontics Restorative Dent.* 2021;41(4):e147-e55.

12. César Neto JB, Cavalcanti MC, Sapata VM, Pannuti CM, Hämmerle CHF, Naenni N, et al. The positive effect of tenting screws for primary horizontal guided bone regeneration: A retrospective study based on cone-beam computed tomography data. *Clin Oral Implants Res.* 2020;31(9):846-55.

13. Naenni N, Schneider D, Jung RE, Hüsler J, Hämmerle CHF, Thoma DS. Randomized clinical study assessing two membranes for guided bone regeneration of peri-implant bone defects: clinical and histological outcomes at 6 months. *Clin Oral Implants Res.* 2017;28(10):1309-17.

14. Miyamoto Y, Obama T. Dental cone beam computed tomography analyses of postoperative labial bone thickness in maxillary anterior implants: comparing immediate and delayed implant placement. *Int J Periodontics Restorative Dent.* 2011;31(3):215-25.

15. Konstantinidis I, Kumar T, Kher U, Stanitsas PD, Hinrichs JE, Kotsakis GA. Clinical results of implant placement in resorbed ridges using simultaneous guided bone regeneration: a multicenter case series. *Clin Oral Investig.* 2015;19(2):553-9.

16. Atef M, Tarek A, Shaheen M, Alarawi RM, Askar N. Horizontal ridge augmentation using native collagen membrane vs titanium mesh in atrophic maxillary ridges: Randomized clinical trial. *Clin Implant Dent Relat Res.* 2020;22(2):156-66.

17. Deeb GR, Tran D, Carrico CK, Block E, Laskin DM, Deeb JG. How Effective Is the Tent Screw Pole Technique Compared to Other Forms of Horizontal

- Ridge Augmentation? *J Oral Maxillofac Surg.* 2017;75(10):2093-8.
18. Sumida T, Otawa N, Kamata YU, Kamakura S, Mtsushita T, Kitagaki H, et al. Custom-made titanium devices as membranes for bone augmentation in implant treatment: Clinical application and the comparison with conventional titanium mesh. *J Craniomaxillofac Surg.* 2015;43(10):2183-8.
19. Cucchi A, Vignudelli E, Napolitano A, Marchetti C, Corinaldesi G. Evaluation of complication rates and vertical bone gain after guided bone regeneration with non-resorbable membranes versus titanium meshes and resorbable membranes. A randomized clinical trial. *Clin Implant Dent Relat Res.* 2017;19(5):821-32.
20. Moses O, Pitaru S, Artzi Z, Nemcovsky CE. Healing of dehiscence-type defects in implants placed together with different barrier membranes: a comparative clinical study. *Clin Oral Implants Res.* 2005;16(2):210-9.
21. Ciocca L, Lizio G, Baldissara P, Sambuco A, Scotti R, Corinaldesi G. Prosthetically CAD-CAM-Guided Bone Augmentation of Atrophic Jaws Using Customized Titanium Mesh: Preliminary Results of an Open Prospective Study. *J Oral Implantol.* 2018;44(2):131-7.
22. Zhou L, Su Y, Wang J, Wang J, Wang X, Liu Q. Effect of Exposure Rates with Customized versus Conventional Titanium Mesh on Guided Bone Regeneration: A Systematic Review and Meta-Analysis. *J Oral Implantol.* 2021.
23. Gu C, Xu L, Shi A, Guo L, Chen H, Qin H. Titanium Mesh Exposure in Guided Bone Regeneration Procedures: A Systematic Review and Meta-analysis. *Int J Oral Maxillofac Implants.* 2022;37(1):e29-e40.
24. Her S, Kang T, Fien MJ. Titanium mesh as an alternative to a membrane for ridge augmentation. *J Oral Maxillofac Surg.* 2012;70(4):803-10.
25. Rocuzzo M, Ramieri G, Bunino M, Berrone S. Autogenous bone graft alone or associated with titanium mesh for vertical alveolar ridge augmentation: a controlled clinical trial. *Clin Oral Implants Res.* 2007;18(3):286-94.
26. Torres J, Tamimi F, Alkhraisat MH, Manchón A, Linares R, Prados-Frutos JC, et al. Platelet-rich plasma may prevent titanium-mesh exposure in alveolar ridge augmentation with anorganic bovine bone. *J Clin Periodontol.* 2010;37(10):943-51.
27. Merli M, Mariotti G, Moscatelli M, Motroni A, Mazzoni A, Mazzoni S, et al. Fence technique for localized three-dimensional bone augmentation: a technical description and case reports. *Int J Periodontics Restorative Dent.* 2015;35(1):57-64.
28. Merli M, Migani M, Bernardelli F, Esposito M. Vertical bone augmentation with dental implant placement: efficacy and complications associated with 2 different techniques. A retrospective cohort study. *Int J Oral Maxillofac Implants.* 2006;21(4):600-6.
29. Merli M, Migani M, Esposito M. Vertical ridge augmentation with

autogenous bone grafts: resorbable barriers supported by osteosynthesis plates versus titanium-reinforced barriers. A preliminary report of a blinded, randomized controlled clinical trial. *Int J Oral Maxillofac Implants.* 2007;22(3):373-82.

30. Merli M, Moscatelli M, Mariotti G, Rotundo R, Bernardelli F, Nieri M. Bone level variation after vertical ridge augmentation: resorbable barriers versus titanium-reinforced barriers. A 6-year double-blind randomized clinical trial. *Int J Oral Maxillofac Implants.* 2014;29(4):905-13.

31. Merli M, Nieri M, Mariotti G, Franchi L, Quiroga Souki B. The fence technique: Autogenous bone graft versus 50% deproteinized bovine bone matrix / 50% autogenous bone graft-A clinical double-blind randomized controlled trial. *Clin Oral Implants Res.* 2020;31(12):1223-31.

32. Merli M, Moscatelli M, Mazzoni A, Mazzoni S, Pagliaro U, Breschi L, et al. Fence technique: guided bone regeneration for extensive three-dimensional augmentation. *Int J Periodontics Restorative Dent.* 2013;33(2):129-36.

33. Cordaro L TH. Preoperative assessment and treatment plan. In: Chen S BD, Wismeijer D, editor. *ITI Treatment Guide: Ridge Augmentation Procedures in Implant Patients: A Staged Approach 7.* Germany: Quintessence; 2013. p. 48-9.

34. Shrout PE, Fleiss JL. Intraclass correlations: uses in assessing rater reliability. *Psychol Bull.* 1979;86(2):420-8.

35. Harring DMMJR. Clustered data with small sample sizes: Comparing the performance of model-based and design-based approaches, *Communications in Statistics Simulation and Computation.* 2017;46(2):855-69.

36. Wang HL, Boyapati L. "PASS" principles for predictable bone regeneration. *Implant Dent.* 2006;15(1):8-17.

37. Strietzel FP, Khongkhunthian P, Khattiya R, Patchanee P, Reichart PA. Healing pattern of bone defects covered by different membrane types--a histologic study in the porcine mandible. *J Biomed Mater Res B Appl Biomater.* 2006;78(1):35-46.

38. Schwarz F, Herten M, Ferrari D, Wieland M, Schmitz L, Engelhardt E, et al. Guided bone regeneration at dehiscence-type defects using biphasic hydroxyapatite + beta tricalcium phosphate (Bone Ceramic) or a collagen-coated natural bone mineral (BioOss Collagen): an immunohistochemical study in dogs. *Int J Oral Maxillofac Surg.* 2007;36(12):1198-206.

39. Zhang T, Zhang T, Cai X. The application of a newly designed L-shaped titanium mesh for GBR with simultaneous implant placement in the esthetic zone: A retrospective case series study. *Clin Implant Dent Relat Res.* 2019;21(5):862-72.

40. Li S, Zhang T, Zhou M, Zhang X, Gao Y, Cai X. A novel digital and visualized guided bone regeneration procedure and digital precise bone augmentation: A

case series. Clin Implant Dent Relat Res. 2021;23(1):19-30.

41. Wang X, Wang G, Zhao X, Feng Y, Liu H, Li F. Short-Term Evaluation of Guided Bone Reconstruction with Titanium Mesh Membranes and CGF Membranes in Immediate Implantation of Anterior Maxillary Tooth. Biomed Res Int. 2021;2021:4754078.

42. Li L, Wang C, Li X, Fu G, Chen D, Huang Y. Research on the dimensional accuracy of customized bone augmentation combined with 3D-printing individualized titanium mesh: A retrospective case series study. Clin Implant Dent Relat Res. 2021;23(1):5-18.

TABLE 1. Buccal bone thickness at the apical rim of the titanium plate in test group

	T1	T2	Change from T1 to T2	<i>p</i> value ^{&}	Percentage change fr T1 to T2
BBT-P	4.63 ± 1.09	4.59 ± 1.07	-0.04 ± 0.05	0.75	0.81 ± 1.01%
BBT-A	5.24 ± 0.96	4.34 ± 1.08	0.91 ± 0.56	<0.01	17.79 ± 11.02%
Difference between BBT-P and BBT-A	0.61 ± 0.68	-0.26 ± 0.36			
<i>p</i> value ^{&}	<0.01	<0.01			
Percentage difference between BBT-P and BBT-A	15.85 ± 18.44%	-5.55 ± 7.67%			

Abbreviations: T1, immediately after guided bone regeneration surgery; T2, immediately prior to reentry; BBT-P, planned buccal bone thickness; BBT-A, augmented buccal bone thickness.

[&]Multi-level mixed-effects linear regression with individual level correlations was considered.

Values are in mm unless otherwise noted.

TABLE 2. Buccal bone thickness at levels apical to the implant platform

	BBT-0	BBT-2	BBT-4	BBT-6	BBT-8	BBT-10	BBT-M
At T1							
Test group (n = 15)	3.89 ±0.72	5.21 ±0.87	5.61 ±0.65	5.46 ±0.63	4.67 ±0.99	3.47 ±1.23	4.72 ±0.63
Control group (n = 16)	3.68 ±1.03	4.44 ±0.95	4.66 ±1.05	4.50 ±0.98	4.30 ±0.98	3.90 ±1.21	4.25 ±0.93
<i>p</i> value [#]	0.70	0.08	<0.01	<0.01	0.27	0.37	0.15
At T2							
Test group (n = 15)	3.36 ±0.73	4.03 ±0.73	4.81 ±0.90	4.87 ±0.78	4.27 ±0.83	3.60 ±0.80	4.16 ±0.48
Control group (n = 16)	1.13 ±1.27	1.94 ±1.31	2.50 ±1.28	2.85 ±1.24	3.01 ±1.03	2.87 ±0.83	2.38 ±0.97
<i>p</i> value [#]	<0.01	<0.01	<0.01	<0.01	<0.01	0.01	<0.01
Change from T1 to T2							
Test group (n = 15)	0.53 ±0.84	1.19 ±0.64	0.80 ±0.64	0.59 ±0.42	0.39 ±0.38	0.00 ±0.96	0.56 ±0.33
Control group (n = 16)	2.55 ±1.31	2.51 ±1.74	2.16 ±1.98	1.65 ±1.94	1.29 ±1.72	1.03 ±1.56	1.87 ±1.59
<i>p</i> value [#]	<0.01	0.04	0.08	0.13	0.16	0.03	0.02
Percentage of change from T1 to T2							
Test group (n=15)	12.08 ±17.66	22.33 ±10.23	14.55 ±12.37	10.93 ±7.73	7.74 ±7.70	-12.00 ±29.30	11.53 ±5.86
Control group (n=16)	69.59 ±28.19	54.26 ±26.77	42.82 ±28.67	32.04 ±30.62	24.91 ±30.92	20.91 ±28.27	40.69 ±24.01
<i>p</i> value [#]	<0.01	<0.01	0.02	0.05	0.11	<0.01	<0.01

Abbreviations: T1, immediately after guided bone regeneration surgery; T2, immediately prior to reentry; BBT-0, buccal bone thickness 0 mm apical to the implant platform; BBT-2, buccal bone thickness 2 mm apical to the implant platform; BBT-4, buccal bone thickness 4 mm apical to the implant platform; BBT-6, buccal bone thickness 6 mm apical to the implant platform; BBT-8, buccal bone thickness 8 mm apical to the implant platform; BBT-10, buccal bone thickness 10 mm apical to the implant platform; BBT-M, mean buccal bone thickness of all implant levels.

Multi-level mixed-effects linear regression with individual level correlations

was considered.
Values are in mm unless otherwise noted.

TABLE 3. Correlation analysis of buccal bone level and the use of a titanium plate

	Test group ($n = 9$)	Control group ($n = 10$)	p value [#]
T1	2.26 ± 0.52	2.10 ± 0.98	0.92
T2	1.48 ± 0.71	-0.90 ± 3.03	0.03
Change from T1 to T2	0.78 ± 0.79	3.00 ± 3.11	0.04

Abbreviations: T1, immediately after guided bone regeneration surgery; T2, immediately prior to reentry.

Multi-level mixed-effects linear regression with individual level correlations was considered.

Values are in mm unless otherwise noted.

Figures Legends:

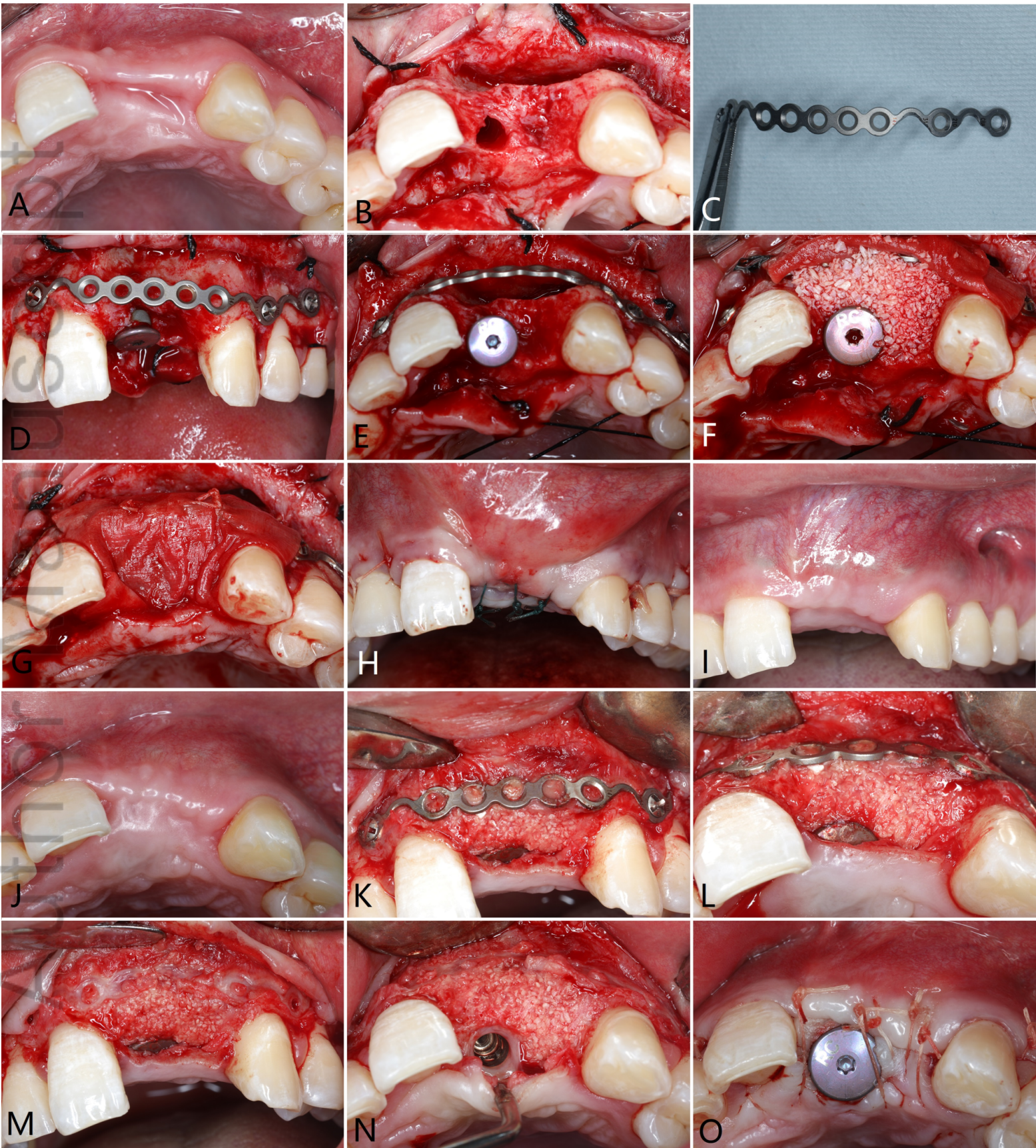
FIGURE 1. Study flow diagram

Figure 2 Titanium plate-enhanced guided bone regeneration. The presurgical ridge is seen (A). The alveolar ridge defect is showed after implant site preparation(B). A titanium plate was trimmed, reshaped, and anchored at the buccal ridge to create a wide space paralleling the alveolar contour (C, D and E). The space was filled with particulate xenograft, and a collagen membrane was laid over both titanium plate and graft (F, G). Primary wound closure was obtained (H). Immediately prior to reentry (4 months after GBR surgery), healing without exposure of the titanium plate was noted (I, J). Upon reentry, the bone graft integrated well with layers of fibrous tissue beneath the titanium plate (K, L, M and N). A taller healing abutment was secured onto the implant (O).

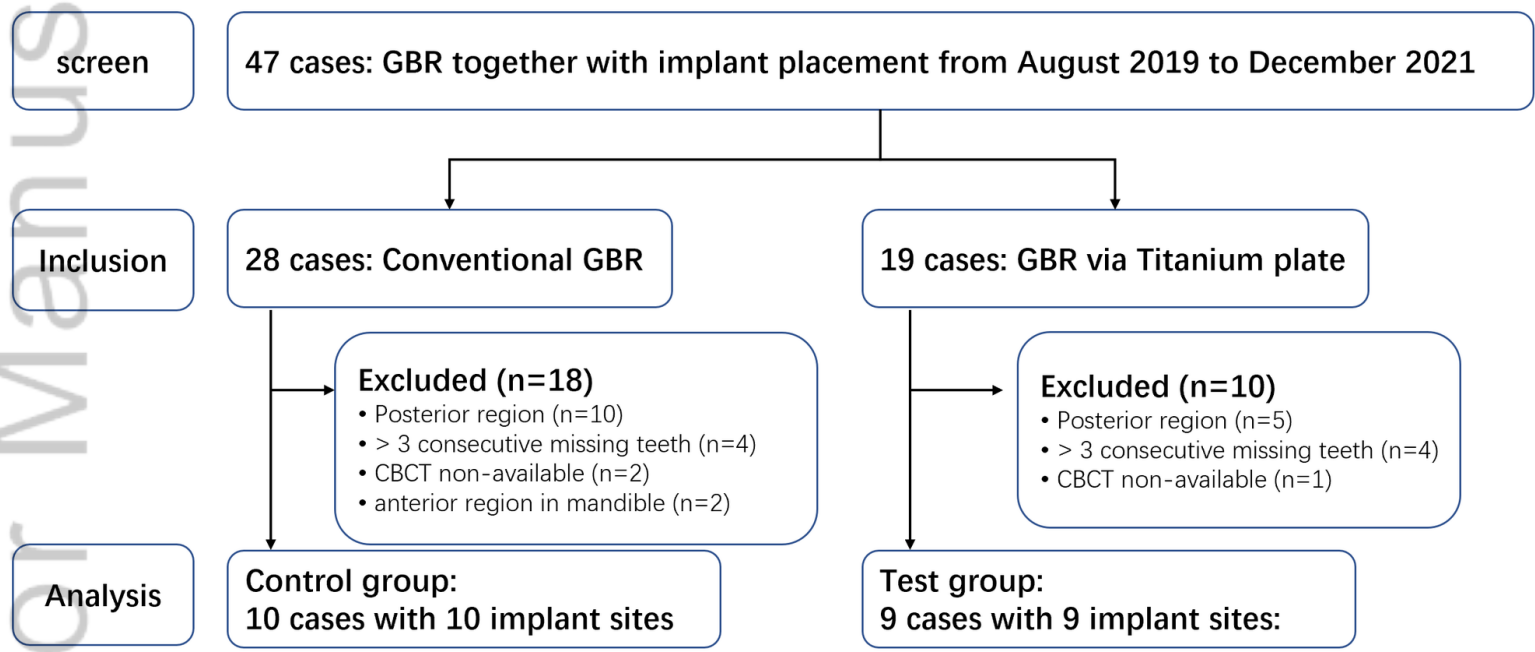
FIGURE 3 Measured cone-beam computed tomographic parameters. Immediately after guided bone regeneration, the augmented buccal bone thickness (BBT-A), planned buccal bone thickness (BBT-P), and titanium plate level (TPL) were measured (A,B). At reentry, the buccal bone thickness (BBT) at levels 0 mm, 2 mm, 4 mm, 6 mm, 8 mm, and 10 mm apical to the implant platform (BBT-0 to BBT-10) were calculated (C).

FIGURE 4. Exposure of the titanium plate in three cases. One patient had an exposed titanium screw at the cutting end 3 months post-guided bone

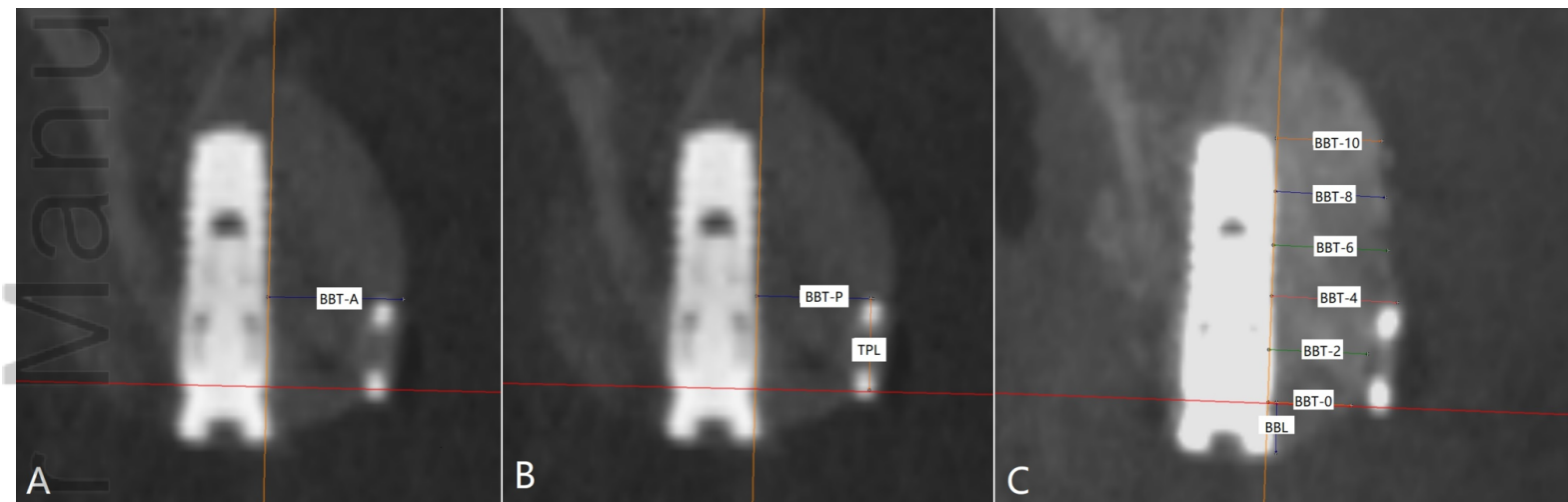
regeneration (A). Another patient had an exposed terminal titanium screw and an adjacent plate ring 2 months post-surgically (B). A third patient had exposure of three adjacent plate rings at the cutting end 3 months post-surgically (C).



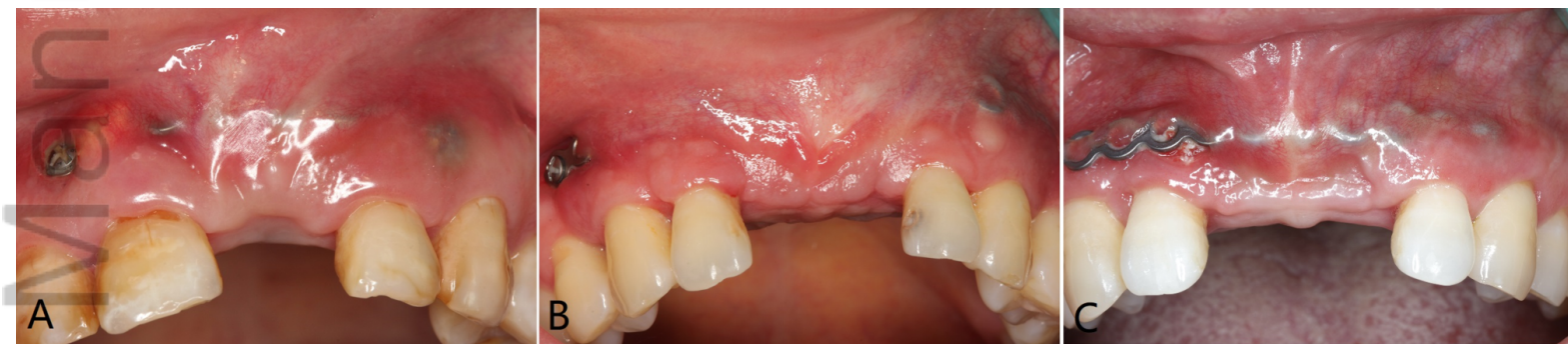CID_13139_Figure 2 Titanium plate-enhanced guided bone regeneration..tif



CID_13139_FIGURE 1. Study flow diagram.tif



CID_13139_FIGURE 3 Measured cone-beam computed tomographic parameters..tif



CID_13139_FIGURE 4. Exposure of the titanium plate in three cases..tif