

REVIEW ARTICLE

Impact of peri-implant soft tissue characteristics on health and esthetics

Alberto Monje DDS, MS, PhD^{1,2,3}  | Oscar González-Martín DDS, MS, PhD^{4,6}  | Gustavo Ávila-Ortiz DDS, MS, PhD^{4,5,7} 

¹Department of Periodontology and Oral Medicine, University of Michigan, Ann Arbor, Michigan, USA

²Department of Periodontology, Universitat Internacional de Catalunya, Barcelona, Spain

³Department of Periodontology, University of Bern, Bern, Switzerland

⁴Private Practice, Atelier Dental Madrid, Madrid, Spain

⁵Department of Oral Medicine, Infection, and Immunity, Harvard School of Dental Medicine, Boston, USA

⁶Department of Periodontology, Complutense University of Madrid, Madrid, Spain

⁷Department of Periodontics, University of Iowa College of Dentistry, Iowa City, Iowa, USA

Correspondence

Gustavo Ávila-Ortiz DDS, MS, PhD, Atelier Dental Madrid, C/Blanca de Navarra 10, Madrid, Spain
Email: Gustavo_Avila-Ortiz@hsdm.harvard.edu

Abstract

Objective: To review the impact of key peri-implant soft tissue characteristics on health and esthetics.

Main Considerations: The keratinized mucosa width (KMW), the mucosal thickness (MT), and the supracrestal tissue height (STH) are essential components of the peri-implant soft tissue phenotype. An inadequate KMW (<2 mm) has been associated with local discomfort upon oral hygiene performance and increased risk for the onset of peri-implant diseases. A minimum buccal MT (≥ 2 mm) is generally required to prevent esthetic issues related to the effect of transmucosal prosthetic elements on the color of the mucosa and can also contribute to long-term mucosal stability. STH is directly related to marginal bone remodeling patterns during the early healing process that follows the connection of transmucosal prosthetic components. Short STH, generally defined as <3 mm, has been consistently associated with marginal bone loss resulting from the physiologic establishment of the mucosal seal. Insufficient STH may also derive into the fabrication of unfavorable transmucosal prosthetic contours, which frequently results in unpleasing esthetic outcomes and predisposes to submarginal biofilm accumulation. Peri-implant soft tissue dehiscences (PISTDs) are a type of peri-implant deformity that are associated with esthetic issues and often occur in sites presenting KMW, MT, and/or STH deficiencies. PISTDs should be correctly diagnosed and treated accordingly, usually by means of multidisciplinary therapy.

Conclusion: Understanding the impact of different dimensional and morphologic features of the peri-implant mucosa on health and esthetic outcomes is fundamental to make appropriate clinical decisions in the context of tooth replacement therapy with implant-supported prostheses.

KEYWORDS

implants

1 | INTRODUCTION

In contemporary implant dentistry, survival is no longer the ultimate endpoint. Other treatment outcomes related to peri-implant health and esthetics have been set to define therapeutic success.

Two tissue compartments support and surround implant fixtures and implant-supported prostheses: the peri-implant mucosa and the peri-implant bone. Since the inception of implant dentistry, for decades, clinical practice and research pivoted around the relevance of the peri-implant bone, specifically on how to predictably achieve osseointegration in the shortest possible time and on the optimization

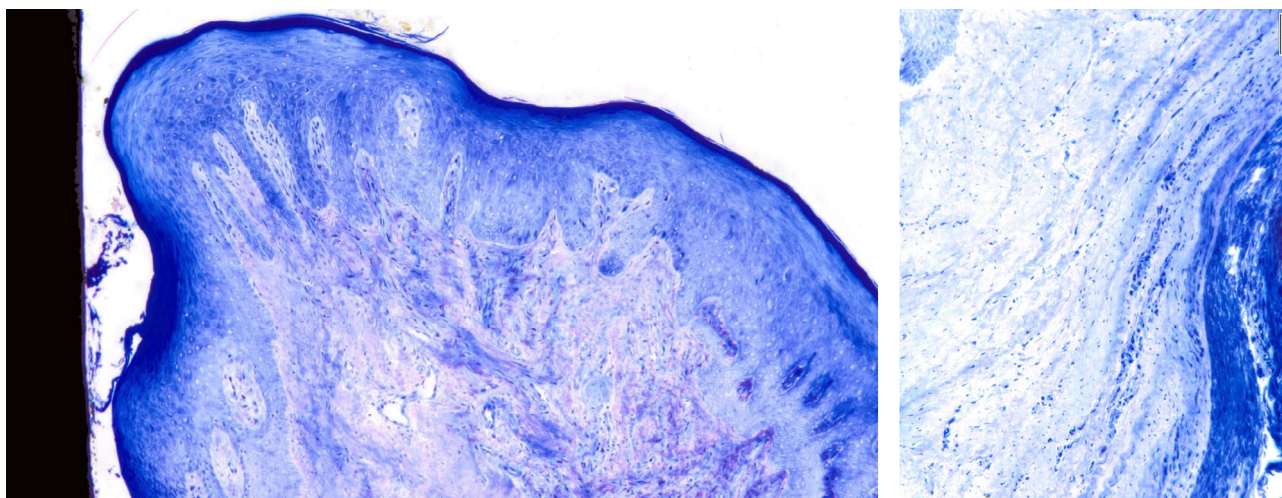


FIGURE 1 Photomicrograph of a sample of human keratinized peri-implant marginal mucosa (left). Note arrangement of the fibers contained within the connective tissue compartment (right). Histology processed by Peter Schüpbach. (Reprinted with permission from Monje & Avila-Ortiz)⁸⁴

of bone-related implant site development interventions. However, in recent times the focus has shifted towards the peri-implant soft tissue and the clinical relevance of its phenotypical features.

Three distinct components of the peri-implant soft tissue phenotype (i.e., the morphologic and dimensional features of the peri-implant mucosa) deserve special attention: the keratinized mucosa width (KMW), the mucosal thickness (MT), and the supracrestal tissue height (STH).¹ Mounting scientific evidence has demonstrated the crucial role that each one of these elements plays on the outcomes of implant therapy. Therefore, careful analysis of each individual constituent of the peri-implant soft tissue phenotype and the identification of related deformities is required for proper diagnosis and treatment planning.

The objective of this narrative review is to provide an up-to-date evidence-based perspective on the effect that phenotypical (morphological and dimensional) peri-implant soft tissue characteristics have on health and esthetic outcomes, as well as a brief overview the therapeutic management of peri-implant soft tissue deformities that may compromise the success of implant therapy.

2 | THE PERI-IMPLANT MUCOSA

The peri-implant mucosa is oral mucosa adapted to the presence of an osseointegrated implant and its transmucosal prosthetic components.²

On its oral surface, the peri-implant mucosa is covered by a stratified squamous epithelium that may be keratinized or not (Figure 1). Keratinized mucosa (KM) is masticatory in nature and its external surface is covered by a keratinized stratified squamous epithelium identical to the oral epithelium that lines the gingiva (Figure 2). If present, this keratinized epithelium extends apically from the mucosal margin to the mucosal junction, where it meets the lining alveolar mucosa, which is non-keratinized. In the absence of keratinized mucosa, only alveolar lining alveolar mucosa can be observed around implant fixtures and transmucosal components.

On its internal surface, three different peri-implant soft tissue compartments may be observed from the mucosal margin to the peri-implant bone crest: 1. The sulcular epithelium, which may be partly keratinized on its coronal aspect; 2. The junctional epithelium, which is non-keratinized; and 3. the supracrestal connective tissue.

Although often indistinguishable from the gingiva and alveolar lining mucosa that is typically observed around teeth after a simple visual assessment, the peri-implant mucosa presents some important biological and structural differences. Notably, the connective tissue of the peri-implant mucosa normally contains a higher proportion of collagen fibers and exhibits lower cellularity and vascularity. In addition, there is no connective tissue attachment to the transmucosal implant surfaces, but rather epithelial adhesion through hemidesmosomes and a direct contact of the underlying connective tissue.^{3,4} Also, the supracrestal soft tissue is generally taller around implants.^{5,6} These features result in a reduced protective response, and a higher susceptibility to the onset and progression of microbial-based inflammatory diseases compared to the periodontal tissues.⁷

3 | SIGNIFICANCE OF KMW ON PERI-IMPLANT HEALTH AND ESTHETICS

KMW is the vertical dimension of keratinized soft tissue that runs in an apico-coronal direction from the mucosal margin to the mucosal junction. As previously mentioned, this phenotypic component may be present or not, as there are peri-implant sites that do not exhibit any keratinized mucosa.

3.1 | KMW and peri-implant health

According to existing evidence in the field of periodontology, the presence of attached gingiva, which is keratinized by definition, is beneficial

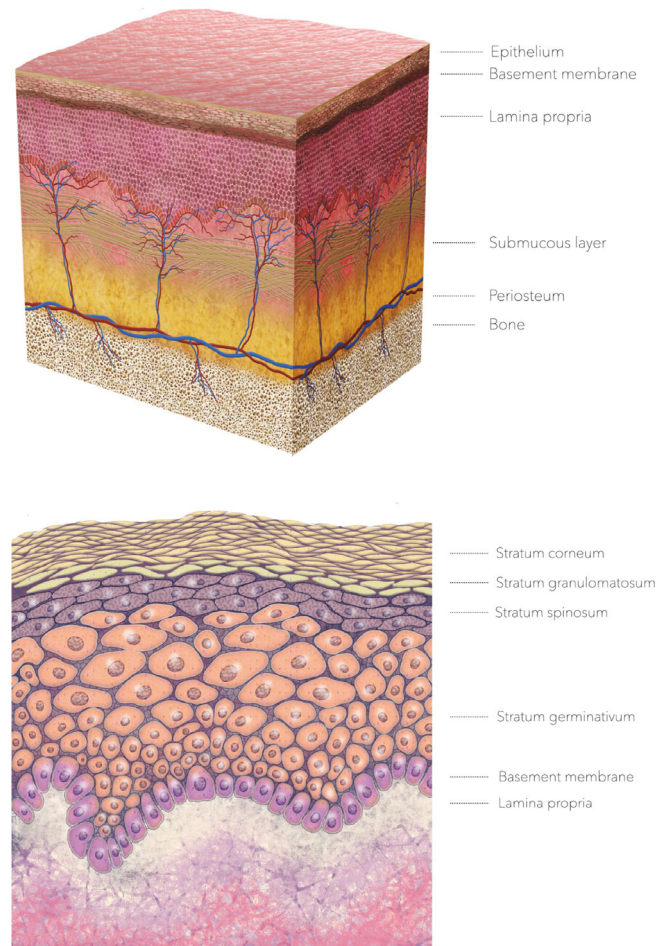


FIGURE 2 Illustrations showing (A) the arrangement of the main components of the oral mucosa and (B) the layers of the keratinized stratified squamous epithelium of the oral mucosa (Reprinted with permission from Monje & Avila-Ortiz)⁸⁴

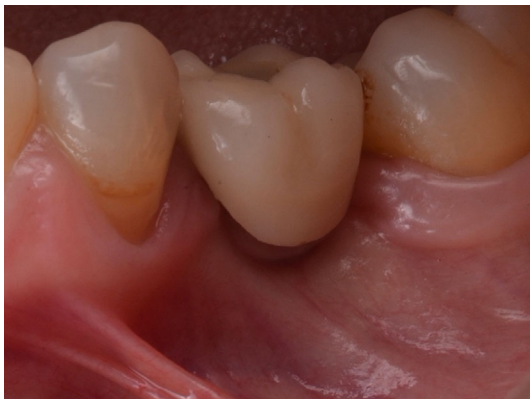

FIGURE 3 Alveolar mucosa is often associated with a shallow vestibulum. This often interferes with self-performed plaque-control measures and typically leads to mucosal inflammation.

in patients with suboptimal oral hygiene; whereas patients with adequate plaque control may not benefit from the presence of a minimum width attached gingiva.⁸ However, it must be noted that absence of or a reduced width of gingival tissue (<2 mm, of which 1 mm should be attached) has been linked to an increased risk for the appearance of gingival recession defects and non-carious cervical lesions.^{9,10}

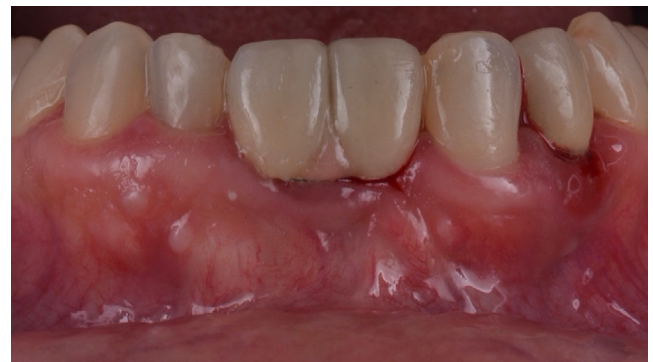

FIGURE 4 The presence of keratinized mucosa does not ensure an effective soft tissue sealing in sites where microbial biofilm control is suboptimal and in absence of partial attachment of that keratinized tissue to the underlying bone.

Although it is well established that there is no connective tissue attachment around implants, when there is sufficient KMW and part of it is attached to the alveolar bone, the peri-implant soft tissue collar is more firmly adapted to the transmucosal prosthetic components and the mucosal seal is, therefore, more efficient in preventing bacterial apical migration.^{11,12} On the contrary, friable and movable non-

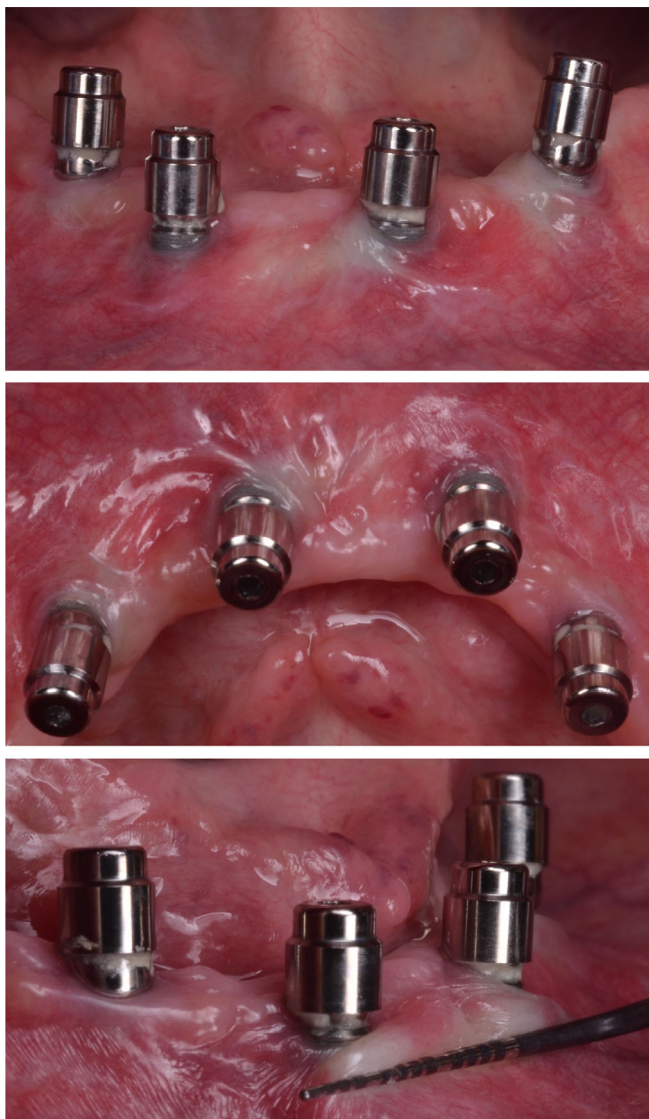


FIGURE 5 Edentulous and atrophic alveolar ridges often display a lack of keratinized mucosa. In these scenarios, adequate biofilm control is often challenging due to discomfort during brushing and the inefficient mucosal sealing. In sites presenting thin mucosa, this combination of factors frequently leads to apical displacement of the mucosal margin.

keratinized mucosa, predisposes for biofilm accumulation, leading to a steady status of inflammation and sparse soft tissue healing.^{8,11}

Interestingly, it has been shown that pro-inflammatory mediators, such as prostaglandin E2, interleukin-1beta, and tumor necrosis factor-alpha, are upregulated in sites lacking KM.^{13,14} This may explain why the severity of mucositis is increased in peri-implant locations that do not exhibit KM¹⁵ and why presence of KMW is correlated to resolution of peri-implant mucositis in humans.¹² In addition, it must be noted that the lack of KM has been associated with shallow vestibular depth.¹⁶ This may hamper the patient's ability to achieve an adequate plaque control and may further contribute to the onset and progression of peri-implant diseases (Figures 3 and 4).

Early studies on this topic suggested that a lack of KM is not necessarily correlated with a higher prevalence of peri-implant disease.¹⁷ Recent data has demonstrated, however, that the presence of ≥ 2 mm of KM is associated with reduced plaque and bleeding scores, and a lower risk for apical displacement of the mucosal margin, patient discomfort upon oral hygiene performance, and bone loss (Figure 5).^{11,18–20} Furthermore, it has been shown that in erratic maintenance compliers (<2 visits/year) the incidence of peri-implant inflammation and marginal bone loss were substantially higher in sites presenting <2 mm of KMW.²¹ In alignment with these findings, Kungsadalpipob et al. observed in a cross-sectional study that peri-implant sites presenting no KM were associated with a higher prevalence of plaque accumulation, apical migration of the mucosal margin, marginal bone loss and peri-implantitis.²² Conversely, Roos-Jans aker et al. found only a slightly higher rate of peri-implantitis in sites that lacked KM.²³ However, it was also observed that those sites lacking KM were associated with a higher prevalence of peri-implant mucositis, which always precedes peri-implantitis in susceptible individuals. Similarly, Lim et al. in a retrospective 5-year analysis of clinical data from a population of compliant patients showed that the band of KM had a negligible role on peri-implant tissue conditions (Table 1).²⁴

Hence, in light of existing evidence it seems that the lack of or <2 mm of KMW should be considered as a local predisposing factor for the occurrence of peri-implant disease and apical migration of the mucosal margin in patients not enrolled in an adequate supportive maintenance program and in sites where self-performed oral hygiene measures are inefficient (Figure 6).

3.2 | KMW and peri-implant esthetics

Compared to KM, non-keratinized lining mucosa is less stable and more friable, which increases the risk for progressive apical migration of the mucosal margin, particularly in sites also presenting thin MT, which will be addressed in the next section of this article. Lining mucosa also exhibits a darker red color, in contrast with the coral pink tone of healthy KM. For those reasons, sites lacking KM on the buccal aspect are more prone to present esthetic problems.²⁵

3.3 | Clinical management of KMW deficiency

The use of an autogenous free epithelized mucosal graft is generally acknowledged as the gold standard therapy to treat sites presenting a complete absence of or a reduced KMW with the purpose of preventing disease onset and progressive deterioration of the mucosal architecture.²⁶ Furthermore, in peri-implantitis sites presenting KM deficiency, predictable and favorable KM gain and disease resolution have been reported after a dual therapeutic approach combining a partial thickness flap and implantoplasty for surface decontamination with the subsequent application of an autogenous free mucosal graft (Figure 7).²⁷ Interestingly, the use of collagen matrices for KMW

TABLE 1 Summary of relevant clinical evidence on the effect of KMW on peri-implant health, in chronological order

Authors (year)	Study type	Length of observational period	Number of patients/implants	Supportive maintenance	Buccal KMW threshold (mm)	Number of implants	Clinical parameters				Comments
							Mean SBI	Mean PPD (mm)	Mean PI	Mean apical migration of mucosal margin (mm)	
Wennstrom et al. (1994) ¹⁷	Prospective	5–10 years	39/171	RC	<2	63	NR	NR	NR	NR	<ul style="list-style-type: none"> Data on GI, PPD and PI was reported as % values, hence mean values could not be enclosed in this table. Authors reported that absence of keratinized mucosa did not influence peri-implant conditions.
					≥2	108	NR	NR	NR	NR	
Kim et al. (2009) ⁸⁵	Retrospective	13 months (mean)	100/276	NR	<2	90	0.44	2.62	0.74	0.72	<ul style="list-style-type: none"> No significant differences in terms of GI, PI and PD were observed regardless of KMW. However, apical migration of the mucosal margin and MBL significantly increased in the KM deficient group
					≥2	186	0.38	2.84	0.74	0.32	
Boynuegri et al. (2013) ¹⁴	Prospective	12 months	15/36 (implants retaining overdentures were included in the analyses)	NR	<2	17	0.5	NR	0.2	NR	<ul style="list-style-type: none"> GI and PI values were significantly higher for implant sites presenting inadequate KMW Expression of TNF-α increased significantly after 12 months in sites showing inadequate KMW
					≥2	19	0	NR	0	NR	
Romanos et al. (2015) ⁸⁶	Retrospective	6.4 years	118/320 (platform switched dental implants)	42 RC / 76 EC	<2	199	NR	NR	0.7	0.2	<ul style="list-style-type: none"> A band of ≥2 mm of KM was associated with significantly lower mBI, PI and less apical migration of the mucosal margin
					≥2	121	NR	NR	0.4	0.06	
Rocuzzo et al. (2016) ⁸⁷	Prospective	10 years	98	82% exhibiting KM and 68% with no KM were RC	0	42	NR	2.7	NR	2.08	<ul style="list-style-type: none"> The absence of KM was associated with higher plaque accumulation, increased incidence of
					≥1	86	NR	3.1	NR	0.16	

(Continues)

TABLE 1 (Continued)

Authors (year)	Study type	Length of observational period	Number of patients/implants	Supportive maintenance	Buccal KMW threshold (mm)	Number of implants	Clinical parameters			Comments	
							Mean SBI	Mean PPD (mm)	Mean PI margin (mm)		
Bonino et al. (2018) ⁸⁸	Prospective	6 months	238/216 implants with mucositis/46 implants diagnosed with peri-implantitis)	RC	0 ≥1	15 13	NR	NR	NR	soft tissue dehiscences, and a higher number of sites that required additional surgical and/or antibiotic treatment.	
							NR	NR	NR		
Perussolo et al. (2018) ⁸⁹	Prospective	4 years	54/202	RC	≥2 <2	112 90	NR NR	2.7 2.7	0.54 0.91	NR NR	<ul style="list-style-type: none"> • Marginal bone loss was higher in sites exhibiting an inadequate KMW • In the group presenting <2 mm of KMW, 51.4% patients reported brushing discomfort
					NR	NR	NR	NR	NR		
Monje et al. (2019) ²¹	Cross-sectional	NA	37/66 implants: 26 implants <2 mm/40 implants ≥2 mm	EC	≥2 <2	40 26	NR NR	3.6 4.8	0.2 1	NR NR	<ul style="list-style-type: none"> • Except for suppuration, all clinical and radiographic parameters were significantly less favorable in sites with KMW <2 mm • Patients reported no brushing discomfort if KMW was at least 2.5 mm
					NR	NR	NR	NR	NR		

TABLE 1 (Continued)

Authors (year)	Study type	Length of observational period	Number of patients/implants	Supportive maintenance	Buccal KMW threshold (mm)	Number of implants	Clinical parameters				Comments
							Mean SBI	Mean PPD (mm)	Mean PI	Mean mucosal margin (mm)	
Lim et al. (2019) ²⁴	Prospective	5 years	87/87	RC	NR	NR	NR	NR	NR	NR	<ul style="list-style-type: none"> Correlation between buccal KMW and PD, BOP, PI and MBL was weak at baseline and after three years of follow-up
Ravidà et al. (2020) ⁹⁰	Retrospective	52.4 months (mean)	40/68	RC	≥2 <2	42 26	NR NR	5.67 5.75	NR NR	NR NR	<ul style="list-style-type: none"> Sites exhibiting KMW <2 mm exhibited increased SUP and MBL The presence or absence of KM does not influence the outcomes following surgical treatment of peri-implantitis
Kungsadapipob et al. (2020) ²²	Cross-sectional	52 months (mean)	200/412	RC	≥1 0	380 32	0.31 0.25	2.83 2.74	0.15 0.18	0 1.17	<ul style="list-style-type: none"> Lack of peri-implant KMW was associated with increased plaque accumulation, soft tissue dehiscences ≥1 mm, MBL ≥3 mm, and peri-implantitis.

Abbreviations: BOP: bleeding on probing; EC: erratic compliers; KMW: keratinized mucosa with; KT: keratinized tissue; MBL: marginal bone loss; NA: not applies; NR: not reported; PI: plaque index; PPD: probing pocket depth; RC: regular compliers; SBI: sulcular bleeding index; SUP: suppuration; TNF-α: tumor necrosis factor alpha.

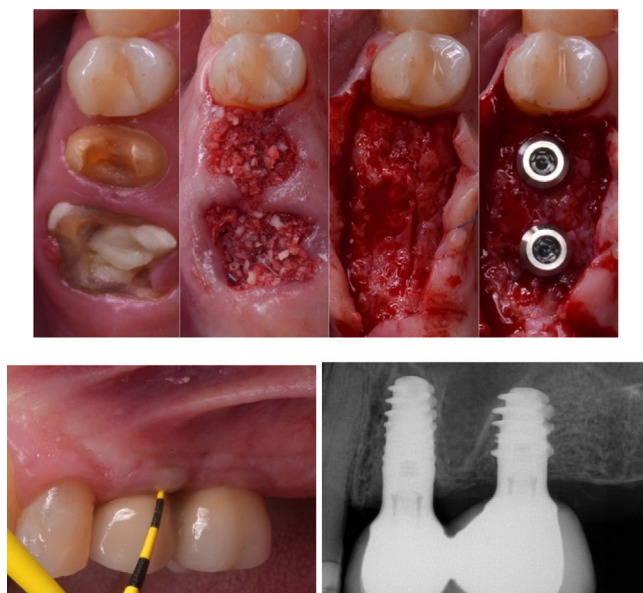


FIGURE 6 Significance of keratinized mucosa on peri-implant health. (A) Hopeless teeth were extracted and (B) ridge preservation was performed to attenuate dimensional changes. (C) After 4 months of healing the site was surgically re-entered and (D) implants were placed with adequate primary stability. (E) Clinical and (F) radiographic assessment after 12 months of functional loading revealed mucosal and bone stability, in consistency with peri-implant health.

augmentation has been shown to render acceptable clinical outcomes compared to the free autogenous graft in areas free of disease and in sites presenting peri-implantitis.^{28,29}

While an autogenous free mucosal graft approach is the most predictable therapeutic option to gain keratinized tissue and recreate peri-implant health in a site presenting deficient KMW,²⁶ this approach usually results in poor tissue color integration, which can be problematic in esthetic areas due to low patient satisfaction.³⁰ In situations where esthetics are priority other alternatives may be considered. For example, in sites presenting adequate vestibular depth (≥ 4 mm),¹⁶ a bilaminar technique consisting of the combination of an autogenous connective tissue graft together with a coronally advanced flap,³¹ either with a trapezoidal or tunnel design, can be a viable option. In the presence of shallow vestibular depth, the use of collagen matrices alone or in conjunction with an autogenous mucosal strip graft can result in favorable outcomes.^{32,33}

4 | SIGNIFICANCE OF MT ON PERI-IMPLANT HEALTH AND ESTHETICS

MT is the horizontal dimension of the peri-implant soft tissue, which may or may not be keratinized. It is important to recognize that MT may vary at different vertical locations, from the mucosal margin to the vestibular fornix, within the same peri-implant area. The relevance of MT is particularly critical in the cervical, most coronal region of the

peri-implant mucosa. Although the minimum MT required to maintain long-term peri-implant health and to achieve predictable esthetic results may vary from site to site as a function of local anatomical features and the characteristics of the implant-supported prosthesis, current evidence suggests that a minimum of 2 mm is often associated with favorable outcomes.³⁴

4.1 | MT and peri-implant health

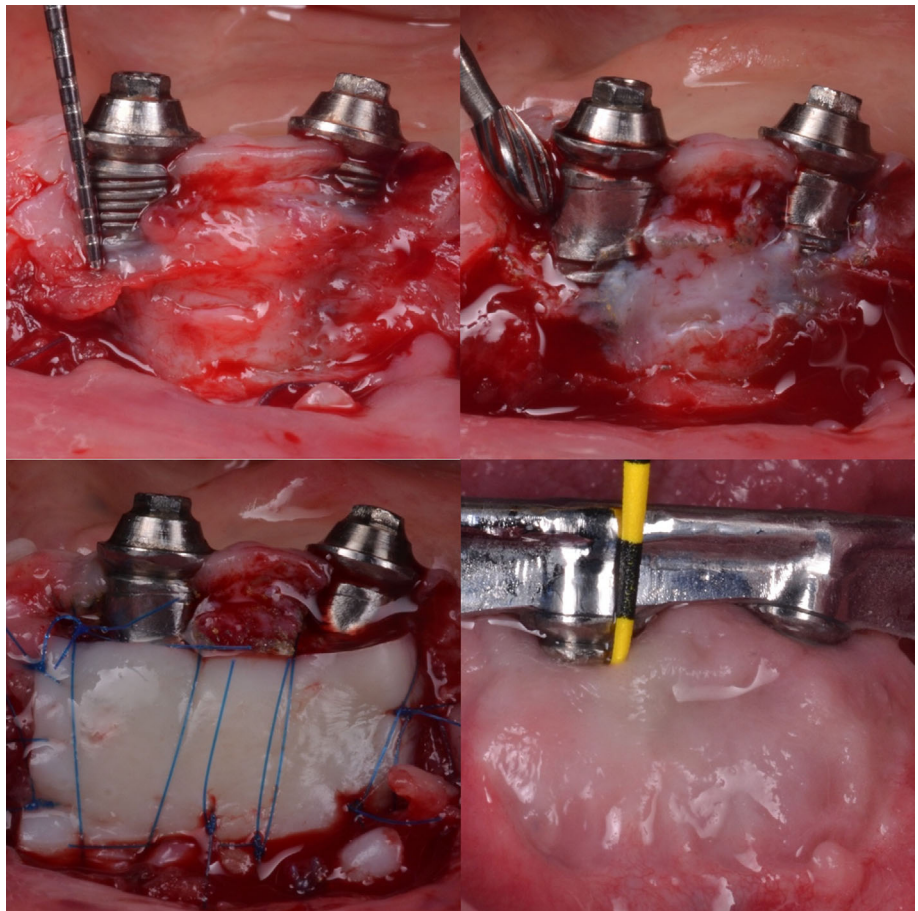
According to the findings of a systematic review that analyzed the effect of soft tissue augmentation on peri-implant health, thicker MT is associated with peri-implant marginal bone stability.³⁵ Although thicker peri-implant soft tissue seems to be generally beneficial for peri-implant health (Figures 8 and 9), the effect of MT on other clinical parameters, such as implant survival, prevention of biofilm accumulation, and the subsequent onset of peri-implant disease, has not been elucidated yet (Figure 9).

4.2 | MT and peri-implant esthetics

In general, the esthetic appearance of the peri-implant mucosa is inferior to the gingiva around teeth,³⁶ which is often correlated with a MT deficit. In fact, the importance of MT on the esthetic outcomes of implant therapy has been well documented. Empirical and clinical evidence indicates that a minimum MT, particularly in the most coronal area, is required to prevent tissue discoloration due to partial transparency of the transmucosal abutment. This is particularly critical around implants that are placed in the esthetic zone in patients with a high smile line and when abutments with a gray shade (e.g., conventional titanium abutments) are employed. An *in vitro* study by Ioannidis et al. revealed that while all reconstructive materials resulted in variable degree of mucosal discoloration this decreased with increasing MT. They also observed that the use of fluorescent zirconia or gold alloy led to less mucosal discoloration.³⁷ Other investigations on this topic have consistently shown that the mucosal discoloration effect can be predictably avoided if MT is at least 2 mm.^{36,38–41}

There is also evidence indicating that thick mucosa is associated with a lower risk of developing apical migration of the mucosal margin in patients that have been carrying implant-supported restorations for an extended period of time (mean follow-up = 7.65 years).⁴² In a recent study, Fürhauser et al. observed that the more palatal the implant is positioned and, therefore, the thicker the facial peri-implant bone, the less apical migration of the mucosal margin.⁴³ According to these findings, it could be extrapolated that implant position largely influences buccal MT and the stability to the mucosal margin. Additionally, a systematic review on the topic of peri-implant soft tissue phenotypic features and esthetics concluded that the pink esthetic score⁴⁴ is usually higher in sites presenting at least 2 mm of MT. Additionally, apical migration of the marginal mucosa is more prone to occur in the presence of thin phenotype, which usually leads to unpleasant esthetic outcomes and low patient satisfaction.⁴⁵

FIGURE 7 Peri-implant bone dehiscence defects resulting from peri-implantitis are often associated with lack of keratinized mucosa (A). In this case, implantoplasty was performed (B) prior to soft tissue augmentation using an autogenous free mucosal graft (C). Note the presence of an increase in keratinized mucosa width and the absence of clinical signs of peri-implant soft tissue inflammation (D).



4.3 | Clinical management of MT deficiency

Surgical interventions aimed at thickening the mucosa at implant sites are frequently indicated to prevent esthetic problems prior to or after the delivery of the final implant-supported prosthesis with the purpose of enhancing the appearance of sites that already exhibit discolorations due to the presence of thin mucosa. A bilaminar approach consisting of the combination of a repositioned or a coronally advanced flap (depending on the anatomical configuration of the site and the treatment goals a tunnel approach may be preferred to preserve the integrity of the interproximal papillae) in combination with an autogenous connective tissue graft or a soft tissue graft substitute is generally recommended to correct MT deficiencies.²⁶

5 | SIGNIFICANCE OF STH ON PERI-IMPLANT HEALTH AND ESTHETICS

The peri-implant supracrestal tissue height (STH) is the vertical dimension of peri-implant soft tissue that surrounds a dental implant from the mucosal margin to the crestal bone.

In the periodontal literature, the classic term “biologic width”, which has been recently replaced with “supracrestal tissue attachment” (STA),⁴⁶ refers to the vertical compartment extending from the most

coronal point of the junctional epithelium to the base of the connective tissue.

Although similar, the concept of STH around implants is not analogous to the STA around teeth. The peri-implant STH encompasses the entire vertical dimension of the peri-implant mucosa from the mucosal margin to the peri-implant bone crest, including the sulcular epithelium, the long junctional epithelium, and the supracrestal connective tissue, which is directly in contact with, but not attached to transmucosal prosthetic components.

As previously discussed in this article, compared to the lamina propria of the gingiva, the peri-implant connective tissue typically has lower cellularity, less density of blood vessels, and a higher proportion of collagen fibers that mainly run in parallel to the implant surface.⁵ Additionally, the vertical dimension of the peri-implant supracrestal tissue is taller than its counterpart around teeth by an average of 1.0 to 1.5 mm.^{6,47,48}

5.1 | STH and peri-implant health

Establishment of the STH is a physiologic event that results from the adaptation of the oral mucosa around an implant-supported transmucosal component. In sites presenting limited baseline STH, this process usually occurs at the expense of physiologic bone remodeling, the magnitude of this effects is typically larger around bone level

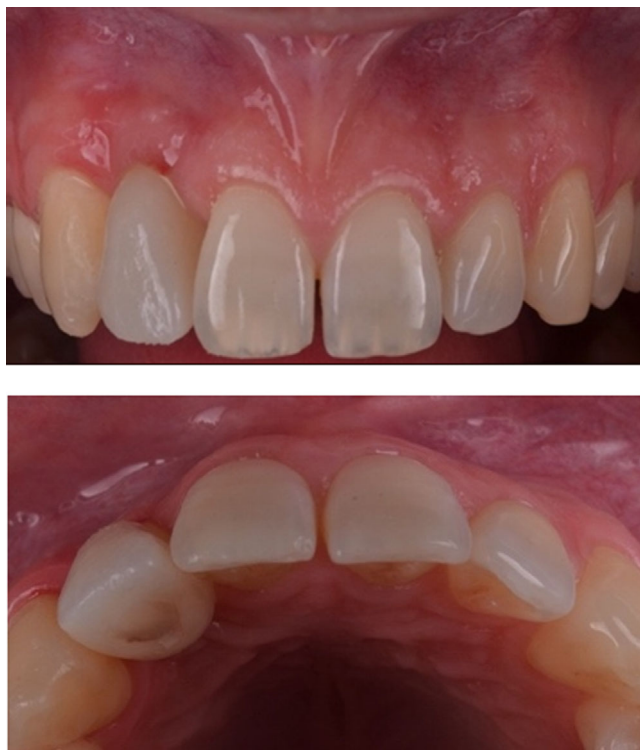

FIGURE 8 Thin mucosal phenotype is frequently associated with esthetic issues and lower patient satisfaction. Note the horizontal collapse (a and b).

implants with the restorative platform placed juxtacrestally.³⁴ While some investigators have defined short STH as <2 mm,^{49,50} in other studies on this topic this dimension has been set at 3 mm.⁵¹⁻⁵⁴ This range may be justified depending on macroscopic implant feature and the anatomical location, as STH tends to be taller in anterior sites. At any rate, the most widely accepted threshold to define short STH is <3 mm.¹

Although there is no conclusive clinical evidence indicating that there is a direct link between a certain threshold of STH and an increased risk for the development of peri-implant diseases, early marginal bone loss, although often self-limiting, may jeopardize long-term health. In fact, it has been shown that if initial marginal bone loss exceeds ~ 0.5 mm over the first 6 months, it is very likely that the loss will extend to 2 mm after 2 years, increasing the risk for the occurrence and progression of peri-implantitis.⁵⁵ A 10-year prospective study validated that implants that exceed 0.5 mm during the first year of function are 5.43 times more prone for future peri-implantitis development.⁵⁶ In relation to these observations, it has been speculated that the partial exposure of implant surface to the peri-implant sulcus can facilitate bacterial colonization, which may increase the risk for inflammatory disease.⁵⁷ This can also be related to the fact that insufficient STH due to shallow implant position is also often associated with the fabrication of esthetically unpleasant and non-cleansable transmucosal prosthetic contours, which may lead to patient dissatisfaction and onset or progression of disease (Figure 10).

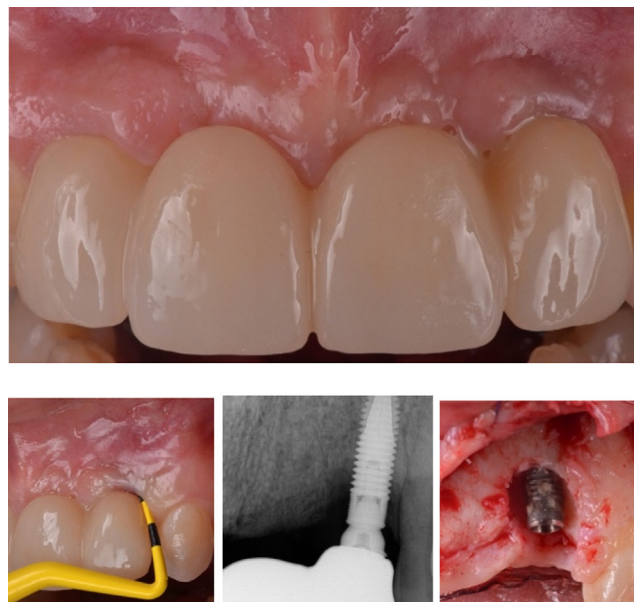

FIGURE 9 This clinical example illustrates an implant-supported fixed prosthesis where peri-implantitis has occurred around the implant that exhibits thinner mucosa (A). Note suppuration and bleeding on probing (B) that correlates with radiographic (C) and clinical bone loss (D)

It must also be acknowledged that STH directly correlates with abutment height, which may explain why it has been consistently reported by different investigators that the taller the abutment, the lower the extent of early marginal bone loss around bone level implants.⁵⁸⁻⁶⁰ It is relevant to note, though, that abutment height may be pivotal on early bone loss even around subcrestal implants surrounded by thin mucosa,⁶¹ irrespective of STH.⁶²

It is, however, important to recognize that an excessively tall STH, far from being exponentially beneficial, may be associated with some disadvantages in patients with suboptimal microbial biofilm control. According to the findings of a study aimed at assessing the effect of STH on the development and resolution of experimental peri-implant mucositis, mucosal tunnel ≥ 3 mm was associated with a less favorable pattern of disease resolution compared to sites presenting a mucosal tunnel of ≤ 1 mm.⁶³ Therefore, it is important to carefully plan and appropriately execute the surgical intervention to place the implant fixture at the ideal depth, balancing anatomical, implant and prosthetic factors.⁶⁴

5.2 | STH and peri-implant esthetics

While the esthetic implications of STH are not as relevant as those related to KMW and MT deficiencies, a short STH usually forces the fabrication of unfavorable emergence profiles that could have detrimental esthetic consequences. Additionally, incomplete interproximal papillary fill, although not necessarily, can be associated with short STH. Insufficient papillary height can predispose for debris impaction

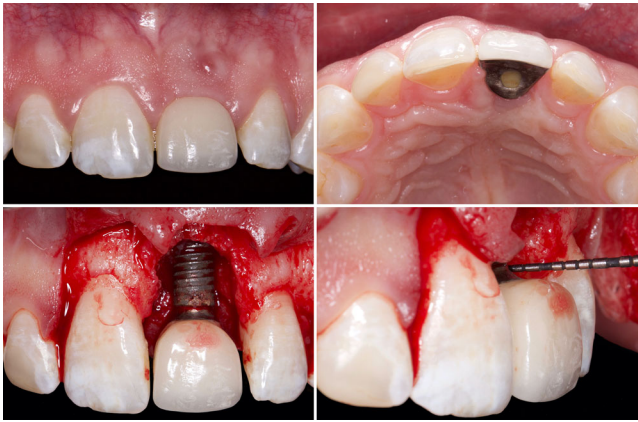

FIGURE 10 Short STH as consequence of shallow implant placement derived into the fabrication of an implant-supported prosthesis with unfavorable contours. This made plaque control very challenging and eventually lead to peri-implantitis, which was likely preceded by early physiologic marginal bone remodeling, also because of shallow implant placement (Images courtesy of Dr. Theodoros Katsaros, private practice in Toronto, Canada)

and lead to poor esthetic outcomes, particularly in the esthetic zone. Interestingly, sites exhibiting stable marginal mucosa levels are associated with papillary height stability.⁶⁵

5.3 | Clinical management of STH deficiency

To prevent the occurrence of marginal bone loss as a consequence of initial physiologic remodeling, it is important to select an implant with adequate dimensions, accommodate the implant position according to baseline STH, to employ prosthetic components with contours that can help drive the establishment of the STH, and to perform soft tissue augmentation, if necessary. Soft tissue augmentation procedures may involve the use of autogenous connective tissue grafts or substitute materials.⁶⁶⁻⁶⁹ In sites presenting unpleasant papillary height, the use of “platform” autogenous soft tissue grafts has been associated with successful clinical outcomes.⁷⁰⁻⁷²

6 | PERI-IMPLANT SOFT TISSUE DEHISCENCES

Peri-implant soft tissues dehiscences (PISTDs), also known as peri-implant marginal mucosa defects, are a type of clinical entity that deserves special attention given its correlation with the peri-implant soft tissue phenotype. These deformities have been defined as alterations of the peri-implant soft tissue morphology characterized by an apical discrepancy of the mucosal margin respective to its ideal position with or without exposure of transmucosal prosthetic components or the implant fixture surface.⁷³

On the other hand, gingival recession defects (GRDs) are defined periodontal deformities characterized by an apical migration of the

gingival margin respective to the cemento-enamel junction (CEJ) resulting in partial exposure of the root surface to the oral cavity, which may have important esthetic, functional, and periodontal health implications.⁷⁴

In the natural dentition, GRDs are assessed by determining the relative position of the gingival margin respective to the cemento-enamel junction (CEJ). However, due to the wide variety of implant fixtures and prosthetic interfaces that can be encountered, a standard reference comparable to the CEJ that could be utilized consistently and universally does not exist. It should also be noted that, depending on the prosthetic design, apical migration of the mucosal margin does not always lead to the exposure of unesthetic transmucosal components.

Furthermore, PISTDs may be caused by true apical migration of the mucosal margin (i.e., recession) because of, for example, local inflammation, sustained trauma, or the effect of iatrogenic dentistry (i.e., too facial implant position),^{25,75} by progressive marginal mucosa discrepancies respective to adjacent teeth due to lifelong craniofacial growth (passive pattern), or a combination of both patterns. Therefore, the use of the term “recession” at implant sites is generally not recommended.⁷⁶ At any rate, the presence of PISTDs should be determined after the establishment of the peri-implant soft tissue height once a transmucosal component is present.

Interestingly, the presence of an adjacent implant, a longer time of the implant in function, limited MT, a reduced band of KM, and increased buccal bone crest distance have been associated with the presence of PISTDs. In turn, KMW ≥ 2 mm, presence of adjacent natural teeth, cemented restorations, and two-piece implants have been identified as protective factors.²⁵

Treatment of PISTDs primarily aims at recreating an adequate peri-implant mucosa architecture considering all the phenotypical components previously addressed in this review (i.e., KMW, MT, and STH). Proper management of these defects can be very challenging and may require a purely surgical^{77,78} or, in most situations, a combined multidisciplinary approach, including surgical, prosthetic, and even orthodontic therapy.^{73,79}

7 | FINAL REMARKS

The dimensional and morphological characteristics of the peri-implant mucosa, particularly in the cervical region, have a major importance in implant therapy as they can greatly influence short- and long-term health and esthetic outcomes. Careful assessment and consideration of each individual component (i.e., KMW, MT and STH) and their dimensional correlation,⁸⁰ as it is not uncommon to identify concomitant deficiencies (e.g., absence/minimal KMW, thin peri-implant mucosa, and PISTD), is fundamental to outline treatment needs and make appropriate clinical decisions.

It is also critical to note that the clinical appearance and structural configuration of the peri-implant mucosa can be influenced by the position of the implant fixture⁸¹ and the contours of the transmucosal prosthetic components.^{82,83} Hence, prior to indicating surgical

interventions to modify the peri-implant soft tissue phenotype it is important to assess whether the implant fixture is in a restorable position and, if so, determine the need for replacement or modification of the existing implant-supported prosthesis.

Finally, as previously mentioned elsewhere, it should be acknowledged that the threshold values proposed in this article, although derived from a meticulous analysis of relevant available evidence, "may vary depending on location (anterior versus posterior) and may not be applicable in specific situations in which the characteristics of the implant-supporting apparatus deviate from normal, including sites undergoing local inflammatory processes that may directly influence the dimensions, morphology and/or integrity of the peri-implant tissues."¹

DISCLOSURE

The authors declare that they do not have any financial interest in the companies whose materials are included in this article.

DATA AVAILABILITY STATEMENT

Research data not shared.

ORCID

Alberto Monje  <https://orcid.org/0000-0001-8292-1927>

Oscar González-Martín  <https://orcid.org/0000-0003-3957-4872>

Gustavo Ávila-Ortiz  <https://orcid.org/0000-0002-5763-0201>

REFERENCES

- Avila-Ortiz G, Gonzalez-Martín O, Couso-Queiruga E, Wang HL. The peri-implant phenotype. *J Periodontol*. 2020;91:283-288.
- Chambrone L, Avila-Ortiz G. Chapter 1: the tissues. In: Chambrone L, Avila-Ortiz G, eds. *TISSUES: Critical Issues in Periodontal and Implant-Related Plastic and Reconstructive Surgery*. Quintessence Publishing; 2022.
- Gläuser R, Schupbach P, Gottlow J, Hammerle CH. Periimplant soft tissue barrier at experimental one-piece mini-implants with different surface topography in humans: a light-microscopic overview and histometric analysis. *Clin Implant Dent Relat Res*. 2005;7(Suppl 1): S44-S51.
- Wiley online library. Periimplant soft tissue architecture and attachment to titanium and zirconia abutments – an experimental LM, SEM, and TEM study. Available at: https://onlinelibrary.wiley.com/doi/full/10.1111/clr.9_13040. Accessed: February 1st, 2020.
- Berglundh T, Abrahamsson I, Welander M, Lang NP, Lindhe J. Morphogenesis of the peri-implant mucosa: an experimental study in dogs. *Clin Oral Implants Res*. 2007;18:1-8.
- Parpaiola A, Cecchinato D, Toia M, Bressan E, Speroni S, Lindhe J. Dimensions of the healthy gingiva and peri-implant mucosa. *Clin Oral Implants Res*. 2015;26:657-662.
- Sanz M, Schwarz F, Herrera D, et al. Importance of keratinized mucosa around dental implants: consensus report of group 1 of the DGI/SEPA/osteology workshop. *Clin Oral Implants Res*. 2022;33(Suppl 23):47-55.
- Lang NP, Loe H. The relationship between the width of keratinized gingiva and gingival health. *J Periodontol*. 1972;43:623-627.
- Agudio G, Chambrone L, Selvaggi F, Pini-Prato GP. Effect of gingival augmentation procedure (free gingival graft) on reducing the risk of non-carious cervical lesions: a 25- to 30-year follow-up study. *J Periodontol*. 2019;90:1235-1243.
- Chambrone L, Tatakis DN. Long-term outcomes of untreated buccal gingival recessions: a systematic review and meta-analysis. *J Periodontol*. 2016;87:796-808.
- Warrar K, Buser D, Lang NP, Karring T. Plaque-induced peri-implantitis in the presence or absence of keratinized mucosa. An experimental study in monkeys. *Clin Oral Implants Res*. 1995;6:131-138.
- Schwarz F, Becker J, Civalo S, Sahin D, Iglhaut T, Iglhaut G. Influence of the width of keratinized tissue on the development and resolution of experimental peri-implant mucositis lesions in humans. *Clin Oral Implants Res*. 2018;29:576-582.
- Zigdon H, Machtei EE. The dimensions of keratinized mucosa around implants affect clinical and immunological parameters. *Clin Oral Implants Res*. 2008;19:387-392.
- Boynuegri D, Nemli SK, Kasko YA. Significance of keratinized mucosa around dental implants: a prospective comparative study. *Clin Oral Implants Res*. 2013;24:928-933.
- Grischke J, Karch A, Wenzlaff A, Foitzik MM, Stiesch M, Eberhard J. Keratinized mucosa width is associated with severity of peri-implant mucositis. A cross-sectional study. *Clin Oral Implants Res*. 2019;30: 457-465.
- Halperin-Sternfeld M, Zigdon-Giladi H, Machtei EE. The association between shallow vestibular depth and peri-implant parameters: a retrospective 6 years longitudinal study. *J Clin Periodontol*. 2016;43: 305-310.
- Wennstrom JL, Bengazi F, Lekholm U. The influence of the masticatory mucosa on the peri-implant soft tissue condition. *Clin Oral Implants Res*. 1994;5:1-8.
- Lin GH, Chan HL, Wang HL. The significance of keratinized mucosa on implant health: a systematic review. *J Periodontol*. 2013;84:1755-1767.
- Ramanauskaitė A, Schwarz F, Sader R. Influence of width of keratinized tissue on the prevalence of peri-implant diseases: a systematic review and meta-analysis. *Clin Oral Implants Res*. 2022;33(Suppl 23): 8-31.
- Perussolo J, Matarazzo F, Dias DR, Oliveira RP, Araujo MG. The effect of brushing discomfort on peri-implant health in sites exhibiting inadequate keratinized mucosa width: a cross-sectional study. *Clin Oral Implants Res*. 2022;33:1212-1223.
- Monje A, Blasi G. Significance of keratinized mucosa/gingiva on peri-implant and adjacent periodontal conditions in erratic maintenance compliers. *J Periodontol*. 2019;90:445-453.
- Kungsadalpipob K, Supanimitkul K, Manopattanasoontorn S, Sophon N, Tangsathian T, Arunyanak SP. The lack of keratinized mucosa is associated with poor peri-implant tissue health: a cross-sectional study. *Int J Implant Dent*. 2020;6:28.
- Roos-Jansaker AM, Renvert H, Lindahl C, Renvert S. Nine- To fourteen-year follow-up of implant treatment. Part III: factors associated with peri-implant lesions. *J Clin Periodontol*. 2006;33:296-301.
- Lim HC, Wiedemeier DB, Hammerle CHF, Thoma DS. The amount of keratinized mucosa may not influence peri-implant health in compliant patients: a retrospective 5-year analysis. *J Clin Periodontol*. 2019; 46:354-362.
- Tavelli L, Barootchi S, Majzoub J, et al. Prevalence and risk indicators of midfacial peri-implant soft tissue dehiscence at single site in the esthetic zone: a cross-sectional clinical and ultrasonographic study. *J Periodontol*. 2022;93:857-866.
- Tavelli L, Barootchi S, Avila-Ortiz G, Urban IA, Giannobile WV, Wang HL. Peri-implant soft tissue phenotype modification and its impact on peri-implant health: a systematic review and network meta-analysis. *J Periodontol*. 2021;92:21-44.
- Monje A, Blasi G, Nart J, Urban IA, Nevins M, Wang HL. Soft tissue conditioning for the surgical therapy of peri-implantitis: a prospective 12-month study. *Int J Periodontics Restorative Dent*. 2020;40: 899-906.
- Solonko M, Regidor E, Ortiz-Vigón A, Montero E, Vilchez B, Sanz M. Efficacy of keratinized mucosal augmentation with a collagen matrix

- concomitant to the surgical treatment of peri-implantitis: a dual-center randomized clinical trial. *Clin Oral Implants Res.* 2022;33:105-119.
29. Lorenzo R, Garcia V, Orsini M, Martin C, Sanz M. Clinical efficacy of a xenogeneic collagen matrix in augmenting keratinized mucosa around implants: a randomized controlled prospective clinical trial. *Clin Oral Implants Res.* 2012;23:316-324.
 30. Thoma DS, Buranawat B, Hammerle CH, Held U, Jung RE. Efficacy of soft tissue augmentation around dental implants and in partially edentulous areas: a systematic review. *J Clin Periodontol.* 2014;41(Suppl 15):S77-S91.
 31. Zucchelli G, Tavelli L, Stefanini M, Barootchi S, Wang HL. The coronally advanced flap technique revisited: treatment of peri-implant soft tissue dehiscences. *Int J Oral Implantol (Berl).* 2021;14:351-365.
 32. Urban IA, Lozada JL, Nagy K, Sanz M. Treatment of severe mucogingival defects with a combination of strip gingival grafts and a xenogeneic collagen matrix: a prospective case series study. *Int J Periodontics Restorative Dent.* 2015;35:345-353.
 33. Urban IA, Tavelli L, Barootchi S, Wang HL, Barath Z. Labial strip gingival graft for the reconstruction of severely distorted mucogingival defects: a prospective case series. *Int J Periodontics Restorative Dent.* 2020;40:845-852.
 34. Suarez-Lopez Del Amo F, Lin GH, Monje A, Galindo-Moreno P, Wang HL. Influence of soft tissue thickness on peri-implant marginal bone loss: a systematic review and meta-analysis. *J Periodontol.* 2016;87:690-699.
 35. Thoma DS, Naenni N, Figuero E, et al. Effects of soft tissue augmentation procedures on peri-implant health or disease: a systematic review and meta-analysis. *Clin Oral Implants Res.* 2018;29(Suppl 15):32-49.
 36. Khorshed A, Vilarrasa J, Monje A, Nart J, Blasi G. Digital evaluation of facial peri-implant mucosal thickness and its impact on dental implant aesthetics. *Clin Oral Investig.* 2022. doi:10.1007/s00784-022-04753
 37. Jung RE, Sailer I, Hammerle CH, Attin T, Schmidlin P. In vitro color changes of soft tissues caused by restorative materials. *Int J Periodontics Restorative Dent.* 2007;27:251-257.
 38. Jung RE, Holderegger C, Sailer I, Khraisat A, Suter A, Hammerle CH. The effect of all-ceramic and porcelain-fused-to-metal restorations on marginal peri-implant soft tissue color: a randomized controlled clinical trial. *Int J Periodontics Restorative Dent.* 2008;28:357-365.
 39. Lops D, Stellini E, Sbricoli L, Cea N, Romeo E, Bressan E. Influence of abutment material on peri-implant soft tissues in anterior areas with thin gingival biotype: a multicentric prospective study. *Clin Oral Implants Res.* 2017;28:1263-1268.
 40. Kim A, Campbell SD, Viana MA, Knoernschild KL. Abutment material effect on peri-implant soft tissue color and perceived esthetics. *J Prosthodont.* 2016;25:634-640.
 41. Ferrari M, Carrabba M, Vichi A, Goracci C, Cagidiaco MC. Influence of abutment color and mucosal thickness on soft tissue color. *Int J Oral Maxillofac Implants.* 2017;32:393-399.
 42. Mailoa J, Arnett M, Chan HL, George FM, Kaigler D, Wang HL. The association between buccal mucosa thickness and Periimplant bone loss and attachment loss: a cross-sectional study. *Implant Dent.* 2018;27:575-581.
 43. Furhauser R, Furhauser L, Furhauser N, Pohl V, Pommer B, Haas R. Bucco-palatal implant position and its impact on soft tissue level in the maxillary esthetic zone. *Clin Oral Implants Res.* 2022;33:1125-1134.
 44. Furhauser R, Florescu D, Benesch T, Haas R, Mailath G, Watzek G. Evaluation of soft tissue around single-tooth implant crowns: the pink esthetic score. *Clin Oral Implants Res.* 2005;16:639-644.
 45. Bienz SP, Pirc M, Papageorgiou SN, Jung RE, Thoma DS. The influence of thin as compared to thick peri-implant soft tissues on aesthetic outcomes: a systematic review and meta-analysis. *Clin Oral Implants Res.* 2022;33(Suppl 23):56-71.
 46. Jepsen S, Caton JG, Albandar JM, et al. Periodontal manifestations of systemic diseases and developmental and acquired conditions: consensus report of workgroup 3 of the 2017 world workshop on the classification of periodontal and peri-implant diseases and conditions. *J Periodontol.* 2018;89(Suppl 1):S237-S248.
 47. Tomasi C, Tassarolo F, Caola I, Wennstrom J, Nollo G, Berglundh T. Morphogenesis of peri-implant mucosa revisited: an experimental study in humans. *Clin Oral Implants Res.* 2014;25:997-1003.
 48. Kan JY, Rungcharassaeng K, Umezue K, Kois JC. Dimensions of peri-implant mucosa: an evaluation of maxillary anterior single implants in humans. *J Periodontol.* 2003;74:557-562.
 49. Canullo L, Camacho-Alonso F, Tallarico M, Meloni SM, Khanari E, Penarrocha-Oltra D. Mucosa thickness and peri-implant crestal bone stability: a clinical and histologic prospective cohort trial. *Int J Oral Maxillofac Implants.* 2017;32:675-681.
 50. Diaz-Sanchez M, Soto-Penalzoa D, Penarrocha-Oltra D, Penarrocha-Diago M. Influence of supracrestal tissue attachment thickness on radiographic bone level around dental implants: a systematic review and meta-analysis. *J Periodontol Res.* 2019;54:573-588.
 51. Linkevicius T, Apse P, Grybauskas S, Puisys A. Influence of thin mucosal tissues on crestal bone stability around implants with platform switching: a 1-year pilot study. *J Oral Maxillofac Surg.* 2010;68:2272-2277.
 52. Linkevicius T, Apse P, Grybauskas S, Puisys A. Reaction of crestal bone around implants depending on mucosal tissue thickness. A 1-year prospective clinical study. *Stomatologija.* 2009;11:83-91.
 53. Linkevicius T, Apse P, Grybauskas S, Puisys A. The influence of soft tissue thickness on crestal bone changes around implants: a 1-year prospective controlled clinical trial. *Int J Oral Maxillofac Implants.* 2009;24:712-719.
 54. Linkevicius T, Linkevicius R, Alkimavicius J, Linkeviciene L, Andrijauskas P, Puisys A. Influence of titanium base, lithium disilicate restoration and vertical soft tissue thickness on bone stability around triangular-shaped implants: a prospective clinical trial. *Clin Oral Implants Res.* 2018;29:716-724.
 55. Galindo-Moreno P, Catena A, Perez-Sayans M, Fernandez-Barbero JE, O'Valle F, Padijal-Molina M. Early marginal bone loss around dental implants to define success in implant dentistry: a retrospective study. *Clin Implant Dent Relat Res.* 2022;24:630-642.
 56. Windael S, Collaert B, De Buyser S, De Bruyn H, Vervaeke S. Early peri-implant bone loss as a predictor for peri-implantitis: a 10-year prospective cohort study. *Clin Implant Dent Relat Res.* 2021;23:298-308.
 57. Monje A, Insua A, Wang HL. Understanding peri-implantitis as a plaque-associated and site-specific entity: on the local predisposing factors. *J Clin Med.* 2019;8(2):279. doi:10.3390/jcm8020279.
 58. Vervaeke S, Collaert B, Cosyn J, De Bruyn H. A 9-year prospective case series using multivariate analyses to identify predictors of early and late peri-implant bone loss. *Clin Implant Dent Relat Res.* 2016;18:30-39.
 59. Galindo-Moreno P, Leon-Cano A, Ortega-Oller I, et al. Prosthetic abutment height is a key factor in peri-implant marginal bone loss. *J Dent Res.* 2014;93:80 S-85 S.
 60. Blanco J, Pico A, Caneiro L, Novoa L, Batalla P, Martin-Lancharro P. Effect of abutment height on interproximal implant bone level in the early healing: a randomized clinical trial. *Clin Oral Implants Res.* 2018;29:108-117.
 61. Pico A, Martin-Lancharro P, Caneiro L, Novoa L, Batalla P, Blanco J. Influence of abutment height and implant depth position on interproximal peri-implant bone in sites with thin mucosa: a 1-year randomized clinical trial. *Clin Oral Implants Res.* 2019;30:595-602.
 62. Munoz M, Busoms E, Vilarrasa J, Albertini M, Ruiz-Magaz V, Nart J. Bone-level changes around implants with 1- or 3-mm-high abutments and their relation to crestal mucosal thickness: a 1-year randomized clinical trial. *J Clin Periodontol.* 2021;48:1302-1311.
 63. Chan D, Pelekos G, Ho D, Cortellini P, Tonetti MS. The depth of the implant mucosal tunnel modifies the development and resolution of experimental peri-implant mucositis: a case-control study. *J Clin Periodontol.* 2019;46:248-255.

64. Spinato S, Bernardello F, Lombardi T, et al. Influence of apico-coronal positioning of tissue-level implants on marginal bone stability during supracrestal tissue height establishment: a multi-center prospective study. *Clin Implant Dent Relat Res*. 2022;24:611-620.
65. Garabetyan J, Malet J, Kerner S, Detzen L, Carra MC, Bouchard P. The relationship between dental implant papilla and dental implant mucosa around single-tooth implant in the esthetic area: a retrospective study. *Clin Oral Implants Res*. 2019;30:1229-1237.
66. Hutton CG, Johnson GK, Barwacz CA, Allareddy V, Avila-Ortiz G. Comparison of two different surgical approaches to increase peri-implant mucosal thickness: a randomized controlled clinical trial. *J Periodontol*. 2018;89:807-814.
67. Puisys A, Jonaitis A, Vindasiute E, Zukauskas S, Linkevicius T. The use of a porcine-derived collagen matrix for vertical soft tissue augmentation. A case report. *Stomatologija*. 2019;21:125-128.
68. Puisys A, Zukauskas S, Kubilius R, Vindasiute E, Linkevicius T. Bone augmentation and simultaneous soft tissue thickening with collagen tissue matrix derivate membrane in an aesthetic area. A case report. *Stomatologija*. 2017;19:64-68.
69. Puisys A, Vindasiute E, Linkeviciene L, Linkevicius T. The use of acellular dermal matrix membrane for vertical soft tissue augmentation during submerged implant placement: a case series. *Clin Oral Implants Res*. 2015;26:465-470.
70. Stefanini M, Marzadori M, Tavelli L, Bellone P, Zucchelli G. Peri-implant papillae reconstruction at an esthetically failing implant. *Int J Periodontics Restorative Dent*. 2020;40:213-222.
71. Urban IA, Klokkevold PR, Takei HH. Papilla reformation at single-tooth implant sites adjacent to teeth with severely compromised periodontal support. *Int J Periodontics Restorative Dent*. 2017;37:9-17.
72. Zucchelli G, Mazzotti C, Bentivogli V, Mounssif I, Marzadori M, Monaco C. The connective tissue platform technique for soft tissue augmentation. *Int J Periodontics Restorative Dent*. 2012;32:665-675.
73. Gamborena I, Avila-Ortiz G. Peri-implant marginal mucosa defects: classification and clinical management. *J Periodontol*. 2021;92:947-957.
74. Chambrone L, Avila-Ortiz G. An evidence-based system for the classification and clinical management of non-proximal gingival recession defects. *J Periodontol*. 2021;92:327-335.
75. Monje A, Chappuis V, Monje F, et al. The critical peri-implant buccal Bone Wall thickness revisited: an experimental study in the beagle dog. *Int J Oral Maxillofac Implants*. 2019;34:1328-1336.
76. Sanz-Martin I, Regidor E, Cosyn J, Wiedemeier DB, Thoma DS. Buccal soft tissue dehiscence defects at dental implants-associated factors and frequency of occurrence: a systematic review and meta-analysis. *Clin Oral Implants Res*. 2022;33(Suppl 23):109-124.
77. Anderson LE, Inglehart MR, El-Kholy K, Eber R, Wang HL. Implant associated soft tissue defects in the anterior maxilla: a randomized control trial comparing subepithelial connective tissue graft and acellular dermal matrix allograft. *Implant Dent*. 2014;23:416-425.
78. Rocuzzo M, Dalmaso P, Pittoni D, Rocuzzo A. Treatment of buccal soft tissue dehiscence around single implant: 5-year results from a prospective study. *Clin Oral Investig*. 2019;23:1977-1983.
79. Zucchelli G, Tavelli L, Stefanini M, et al. Classification of facial peri-implant soft tissue dehiscence/deficiencies at single implant sites in the esthetic zone. *J Periodontol*. 2019;90:1116-1124.
80. Nozawa T, Enomoto H, Tsurumaki S, Ito K. Biologic height-width ratio of the buccal supra-implant mucosa. *Eur J Esthet Dent*. 2006;1:208-214.
81. Hammerle CHF, Tarnow D. The etiology of hard- and soft-tissue deficiencies at dental implants: a narrative review. *J Periodontol*. 2018;89-(Suppl 1):S291-S303.
82. Gonzalez-Martin O, Lee E, Weisgold A, Veltri M, Su H. Contour Management of Implant Restorations for optimal emergence profiles: guidelines for immediate and delayed provisional restorations. *Int J Periodontics Restorative Dent*. 2020;40:61-70.
83. Su H, Gonzalez-Martin O, Weisgold A, Lee E. Considerations of implant abutment and crown contour: critical contour and subcritical contour. *Int J Periodontics Restorative Dent*. 2010;30:335-343.
84. Monje A, Avila-Ortiz G. Critical soft tissue dimensions on peri-implant health and disease. In: Monje A, Wang HL, eds. *Unfolding Peri-Implantitis*. Quintessence; 2022.
85. Kim BS, Kim YK, Yun PY, et al. Evaluation of peri-implant tissue response according to the presence of keratinized mucosa. *Oral Surg Oral Med Oral Pathol Oral Radiol Endod*. 2009;107:e24-e28.
86. Romanos G, Grizas E, Nentwig GH. Association of Keratinized Mucosa and Periimplant Soft Tissue Stability around Implants with Platform Switching. *Implant Dent*. 2015;24:422-426.
87. Rocuzzo M, Grasso G, Dalmaso P. Keratinized mucosa around implants in partially edentulous posterior mandible: 10-year results of a prospective comparative study. *Clin Oral Implants Res*. 2016;27:491-496.
88. Bonino F, Steffensen B, Natto Z, Hur Y, Holtzman LP, Weber HP. Prospective study of the impact of peri-implant soft tissue properties on patient-reported and clinically assessed outcomes. *J Periodontol*. 2018;89:1025-1032.
89. Perussolo J, Souza AB, Matarazzo F, Oliveira RP, Araujo MG. Influence of the keratinized mucosa on the stability of peri-implant tissues and brushing discomfort: a 4-year follow-up study. *Clin Oral Implants Res*. 2018;29:1177-1185.
90. Ravida A, Saleh I, Siqueira R, et al. Influence of keratinized mucosa on the surgical therapeutical outcomes of peri-implantitis. *J Clin Periodontol*. 2020;47:529-539.

How to cite this article: Monje A, González-Martín O, Ávila-Ortiz G. Impact of peri-implant soft tissue characteristics on health and esthetics. *J Esthet Restor Dent*. 2023;35(1):183-196. doi:10.1111/jerd.13003