



CASE STUDY

Two cases of challenging cutaneous lymphoid infiltrates presenting in the context of COVID-19 vaccination: A reactive lymphomatoid papulosis-like eruption and a bona fide lymphoma

Scott C. Bresler MD, PhD^{1,2}  | Tyler D. Menge MD² | Trilokraj Tejasvi MD² | Shannon A. Carty MD^{3,4} | Alexandra C. Hristov MD^{1,2} 

¹Department of Pathology, Michigan Medicine, University of Michigan, Ann Arbor, Michigan, USA

²Department of Dermatology, Michigan Medicine, University of Michigan, Ann Arbor, Michigan, USA

³Division of Hematology/Oncology, Michigan Medicine, University of Michigan, Ann Arbor, Michigan, USA

⁴Department of Internal Medicine, Michigan Medicine, University of Michigan, Ann Arbor, Michigan, USA

Correspondence

Alexandra C. Hristov, Departments of Pathology and Dermatology, 2800 Plymouth Road, Building 35, Ann Arbor, MI 48109-2800, USA.

Email: ahristov@med.umich.edu

Abstract

COVID-19 infection and vaccination may be associated with a wide variety of cutaneous and immune manifestations. Here, we describe two patients who presented with monoclonal cutaneous T-cell infiltrates that showed cytologic and immunophenotypic features concerning for lymphoma shortly following COVID-19 vaccination. In one case, the eruption completely resolved. The second patient showed initial resolution, but her disease recurred and progressed following a breakthrough SARS-CoV-2 infection. These cases suggest that immune stimulation following exposure to SARS-CoV-2 protein(s) in vaccine or infection may facilitate the development of a lymphoma or lymphoproliferative disorder in susceptible individuals. Moreover, they show that separating these cases from pseudolymphomatous reactive conditions is often challenging and requires close clinical correlation.

KEYWORDS

COVID-19, cutaneous T-cell lymphoma, SARS-CoV-2

1 | INTRODUCTION

Adverse cutaneous reactions are known to occur both in the context of COVID-19 infection and administration of COVID-19 vaccines.^{1,2} In patients with documented SARS-CoV-2 infection, cutaneous manifestations may occur in up to 20% of patients and may present with a number of morphologies including morbilliform, vesicular, urticarial, and vascular appearances, among others.^{1,3} Cutaneous adverse effects in vaccine recipients appear to be less common and are typically mild, most often representing delayed or immediate injection site reactions such as localized erythema and swelling but may resemble widespread cutaneous reactions seen in the context of SARS-CoV-2 infection.^{2,4}

Additional less common cutaneous reactions that occur in the context of vaccination include herpes zoster and herpes simplex flares, possibly reflecting altered immunity in the immediate postvaccinated state.⁴ Isolated instances of purported recurrences of cutaneous T-cell lymphoproliferative disorders have also been reported.^{5,6}

Here, we report two cases of atypical, clonal T-cell infiltrates that presented as cutaneous eruptions shortly after administration of a COVID-19 vaccine. In each case, the eruption initially regressed without cutaneous T-cell lymphoma (CTCL)-specific therapy. In one case, the eruption recurred and progressed following a breakthrough SARS-CoV-2 infection. These examples show that lymphoproliferative disorders and even overt lymphoma may occur in association with COVID-19 vaccine administration.

This is an open access article under the terms of the [Creative Commons Attribution-NonCommercial-NoDerivs](https://creativecommons.org/licenses/by-nc-nd/4.0/) License, which permits use and distribution in any medium, provided the original work is properly cited, the use is non-commercial and no modifications or adaptations are made.

© 2022 The Authors. *Journal of Cutaneous Pathology* published by John Wiley & Sons Ltd.

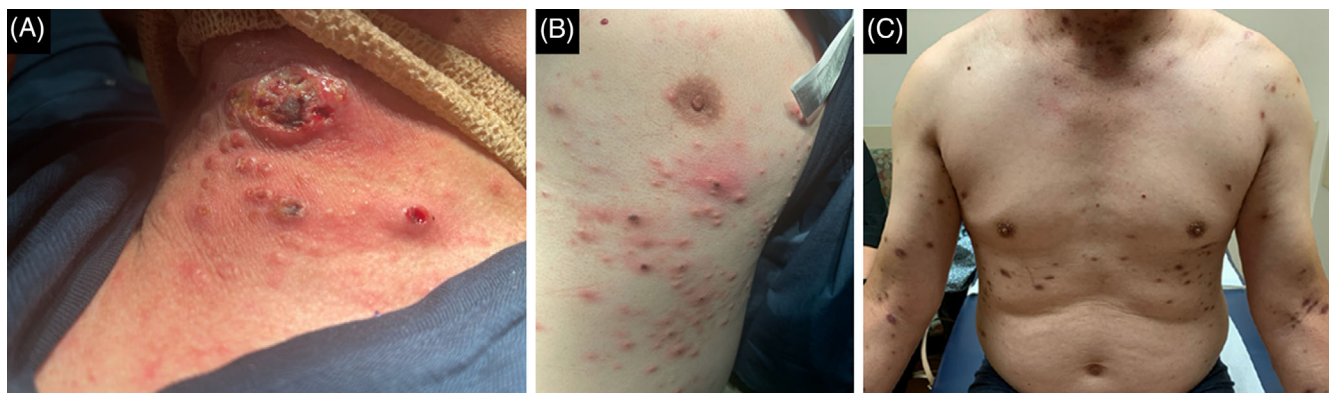


FIGURE 1 Lymphomatoid reaction to COVID-19 vaccination (Case 1). The patient developed an ulcerated papulonodular eruption shortly following his second dose (A, B). Two months after vaccination, he was left with residual hyperpigmentation and hyperpigmented scars (C).

Moreover, they suggest that immune stimulation following exposure to SARS-CoV-2 protein(s) may facilitate the development of a lymphoma or lymphoproliferative disorder in susceptible individuals.^{5,6} These cases stress that establishing a diagnosis of CTCL and definitively separating these cases from pseudolymphomatous reactive conditions is often challenging and requires correlation with clinical findings.⁷

2 | CASE REPORT

2.1 | Case 1

The first case is a 53-year-old Asian man with a history of eczema (primarily on the hands) since his teenage years who presented with a papulonodular eruption on his head and the front of his neck approximately 1 week after receiving his first dose of the Moderna COVID-19 vaccine. After the second dose, the rash worsened significantly and was intensely pruritic (Figure 1A,B). However, the patient did not experience systemic symptoms at any time. Complete blood counts with differential and peripheral blood flow cytometry did not reveal evidence of systemic disease. The papules/pustules would grow, drain serous fluid, and then regress. The rash persisted despite a 2-week course of oral prednisone. It progressively spread across the chest, back, axillae, and inguinal regions. Valacyclovir, doxycycline, and hydroxyzine were attempted without success.

Multiple punch biopsies were performed. The left lateral neck and central neck specimens both showed an atypical epidermotropic T-cell infiltrate composed of intermediate-sized to large T-cells that expressed CD3 (a subset showed weak CD3 expression) and co-expressed CD4 and TIA1 (Figure 2A–E). CD2, CD5, and CD7 were diminished in expression. In situ hybridization for EBER was negative. CD30 marked a subset of cells (Figure 2F). A subsequent skin biopsy specimen from the left anterior shoulder showed a similar atypical T-cell infiltrate with epidermotropism and a similar immunophenotype with more robust CD30 expression (Figure 3A–H). Polymerase chain reaction (PCR) revealed clonal rearrangements in the genes encoding T-cell receptor γ (*TRG*) and T-cell receptor β (*TRB*) with matching base

pair peaks in the lateral neck, central neck, and left anterior shoulder biopsy specimens. Positron emission tomography–computed tomography (PET/CT) was not performed because of lack of insurance coverage; however, flow cytometry performed on peripheral blood was negative for involvement. The rash improved significantly without additional intervention with only residual hyperpigmentation and hyperpigmented scars remaining (Figure 1C), and the patient has remained disease-free for the past 12 months. Given the close association with vaccination, complete resolution, and limited CD30 expression by the atypical T-cells in the initial biopsies (Figure 2), the findings were favored to represent a lymphomatoid reaction, though a CD30⁺ T-cell lymphoproliferative disorder such as lymphomatoid papulosis (LyP) remains in the differential diagnosis.

2.2 | Case 2

The second case is a 62-year-old white woman who presented several days after the second dose of the Pfizer-BioNTech COVID-19 vaccine with red, flat asymptomatic macules scattered on the bilateral arms. Systemic symptoms such as fevers, chills, weight loss, or night sweats were absent. Complete blood counts with differential were within normal limits and peripheral blood flow cytometry revealed a slightly elevated CD4/CD8 ratio but no other abnormalities. An initial punch biopsy was performed at an outside institution and revealed a superficial perivascular infiltrate containing small to medium-sized lymphoid cells with slight cytologic atypia in the form of nuclear irregularities and hyperchromasia with overlying epidermal spongiosis and exocytosis. This was interpreted as a spongiotic hypersensitivity reaction that was treated with oral and topical steroids for 2 weeks without improvement. A second biopsy, also performed at an outside hospital, showed a dense dermal infiltrate, again of small to intermediate-sized cells, within the dermis and extending into the superficial subcutis.

A third punch biopsy was performed at our institution and showed an intradermal population of atypical, intermediate-sized T-cells with irregular, hyperchromatic nuclei in an interstitial distribution that dissected between collagen fibers in single-file arrays (Figure 4A–C). The

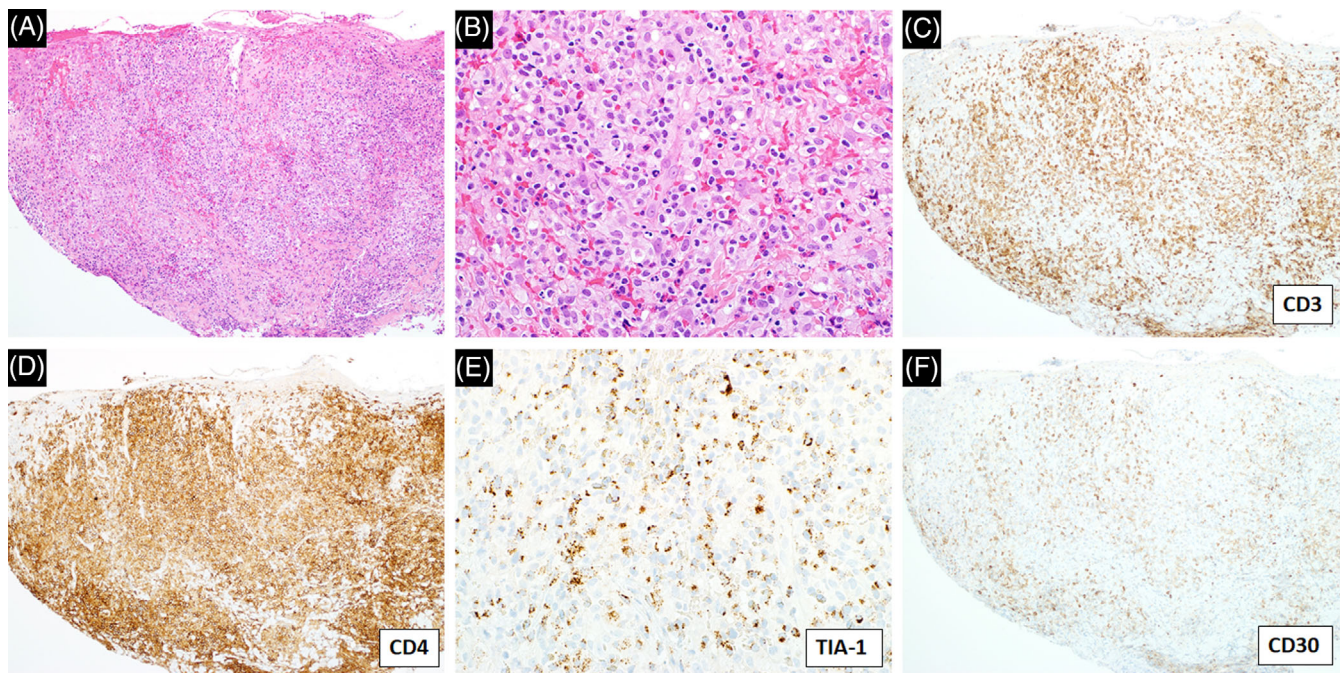


FIGURE 2 Lymphomatoid reaction to COVID-19 vaccination (Case 1). The neck biopsy specimens showed sheets of enlarged atypical T-cells with some epidermotropism (A, B; H&E $\times 100$, $\times 400$, respectively) that expressed CD3 (C, original $\times 100$), CD4 (D), TIA-1 (E), and limited CD30 (F).

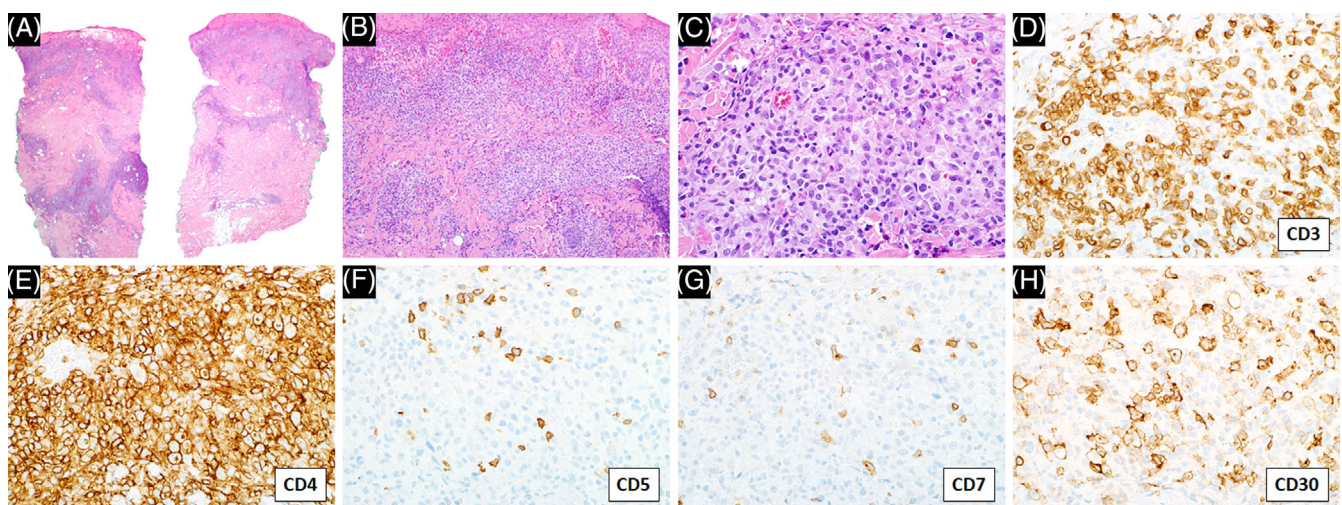


FIGURE 3 Lymphomatoid reaction to COVID-19 vaccination (Case 1). The left shoulder biopsy specimen showed aggregates of large, atypical T-cells with epidermotropism (A–C, H&E $\times 20$, $\times 100$, $\times 400$, respectively) that expressed CD3 (D) and CD4 (E) and showed loss of CD5 (F) and CD7 (G). CD30 highlights a subset of cells (H).

atypical lymphocytes showed weak expression of CD2 and CD3, partial loss of CD7, and coexpression of TIA1 and CD8 (Figure 4D–H). CD4, TCR β F1, TCR δ , granzyme, CD56, TdT, and TCL1 were not expressed, and CD30 marked rare, scattered cells. EBER was negative. PCR revealed clonal rearrangements in *TRG* and *TRB*. A PET/CT revealed mild hypermetabolic, non-enlarged lymph nodes, interpreted as possibly reactive, and a repeat PET/CT performed 3 months later was negative.

Peripheral blood flow cytometry was negative for systemic involvement. Serologic testing was negative for human T-lymphotropic virus 1. A fourth biopsy was performed at our institution, which again showed an atypical T-cell infiltrate with a similar immunophenotype (though with strong CD2 expression) with matching *TRG* and *TRB* rearrangements by PCR. The rash largely resolved without additional therapy. However, following a breakthrough SARS-CoV-2 infection the

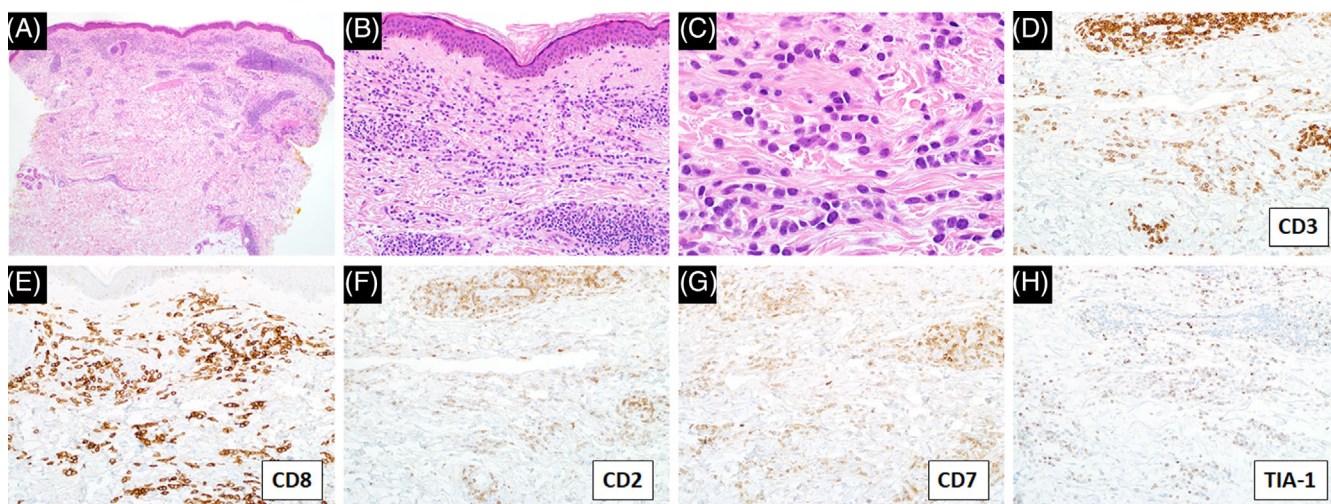


FIGURE 4 Lymphoma following COVID-19 vaccination and infection (Case 2). A right upper back biopsy specimen showed a perivascular and interstitial infiltrate of slightly enlarged lymphoid cells (A–C, H&E $\times 40$, $\times 200$, $\times 600$, respectively) that expressed diminished CD3 (D) and were also positive for CD8 (E) and TIA-1 (H). These atypical T-cells showed dim expression of CD2 (F) and CD7 (G).

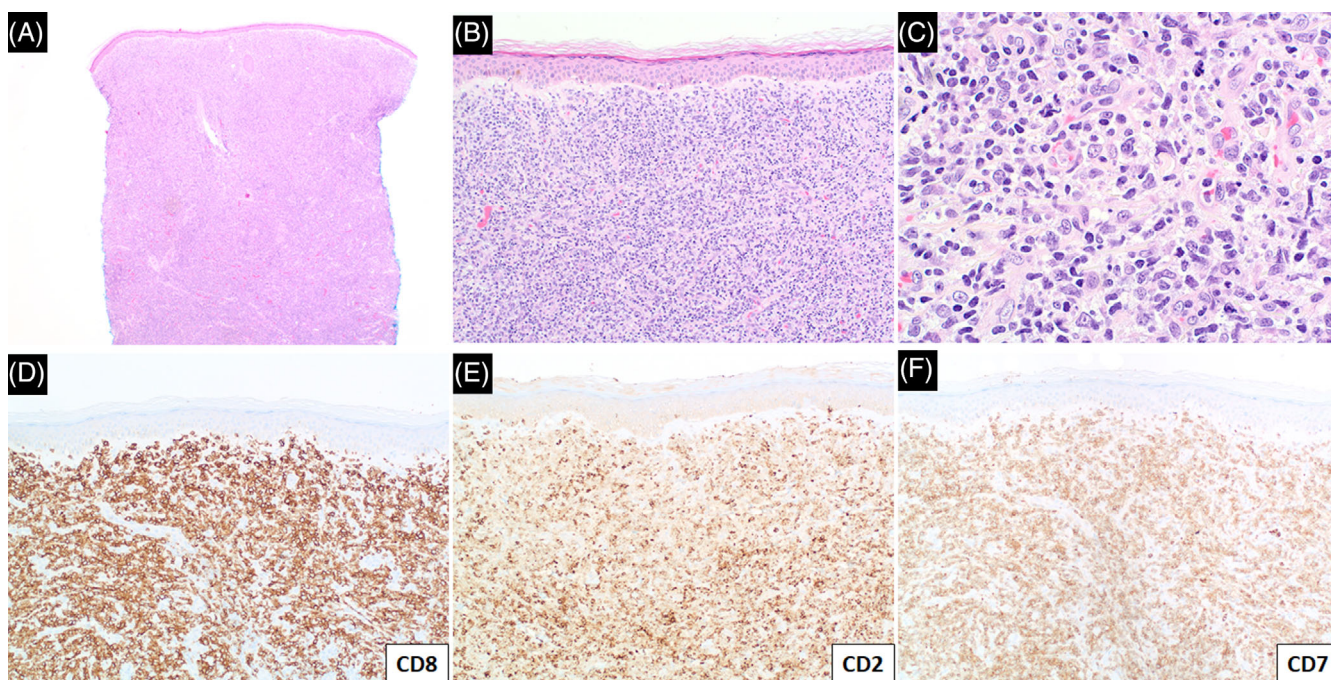


FIGURE 5 Lymphoma following COVID-19 vaccination and infection (Case 2). A thigh biopsy showed a dense dermal lymphoid infiltrate of intermediate-sized, atypical cells (A–C, H&E $\times 20$, $\times 100$, $\times 600$, respectively). These cells expressed CD8 (D) and showed weak expression of CD2 (E) and partial loss to diminished CD7 (F).

patient's rash recurred and progressed with significant cutaneous spread and the development of tumors. A repeat biopsy showed a dense dermal infiltrate of intermediate to large lymphoid cells separated from the epidermis by a grenz zone (Figure 5A–C). The lymphoid cells were positive for CD8 and showed weak expression of CD2 and partial dim to lost CD7 but retained expression of CD5 (Figure 5D–F). T-cell receptor gene rearrangement studies again showed matching TRG and TRB rearrangements by PCR. Next generation sequencing revealed a

TERT promoter mutation and a loss of function mutation in *GRIN2A*. PET/CT did not reveal definitive evidence of extracutaneous disease and peripheral blood flow cytometry was negative. Given the sum of features, this patient was diagnosed with an unusual CD8⁺, cytotoxic T-cell lymphoma best characterized as a primary cutaneous CD8⁺ peripheral T-cell lymphoma, not otherwise specified.⁸ She was initially treated with methotrexate then brentuximab, but continued to develop tumors. A repeat PET/CT showed mildly hypermetabolic non-enlarged

bilateral axillary and pelvic lymph nodes, which could be neoplastic or reactive. She is now considering systemic chemotherapy followed by allogeneic bone marrow transplant vs total skin electron beam therapy.

3 | DISCUSSION

Numerous cutaneous reactions have been reported in patients with documented SARS-CoV-2 infection including early reports of a generalized morbilliform eruption, generalized erythema, extensive urticaria, and vesicular rashes.^{3,9} Dengue fever-like petechial rashes,^{10,11} chilblains-like, and other vascular-type reactions have also been reported.¹² Cutaneous reactions to the COVID-19 vaccine are typically mild and are most commonly injection site reactions, which include localized pain, swelling, and/or erythema, and are either delayed or immediate in timing.^{2,4} Clinically detectable regional lymphadenopathy may occur uncommonly and may be cause for concern in patients with an oncologic history.^{13,14}

Although establishing a true causal relationship is difficult, widespread cutaneous reactions have included eruptions similar those seen in SARS-CoV-2 infection, including urticarial, morbilliform, and pernio/chilblains-type eruptions.⁴ Additional reported manifestations include pityriasis rosea, lichen planus, erythema multiforme, Rowell syndrome, and purpuric/petechial rashes, among others.² In addition to newly diagnosed cutaneous conditions, flares of pre-existing cutaneous conditions such as pustular psoriasis, herpes simplex, and have also been reported following vaccination.^{4,15} Occurrences of herpes zoster may also be related to COVID-19 vaccination.^{4,16} Other reported reactions include the development or flaring of various systemic autoimmune disorders including Behçet disease, myasthenia gravis, and systemic lupus erythematosus.¹⁷

Despite the varied presentations of COVID-19 vaccine-related eruptions, the incidence of serious cutaneous adverse events appears to be quite rare, with one study estimating that they occur below 0.3% in frequency.² Examples of drug reaction with eosinophilia and systemic symptoms/acute generalized exanthematous pustulosis overlap as well as Stevens-Johnson syndrome have been reported.^{18,19} Subepidermal blistering eruptions, including bullous pemphigoid, have also been documented after COVID-19 vaccination.²⁰ Additional exceptional severe reactions include several occurrences of systemic drug-related intertriginous and flexural erythema^{21,22} and vaccine-induced thrombotic thrombocytopenia with an associated widespread petechial rash.²³

Notably, isolated purported recurrences of CTCL have been reported following COVID-19 vaccination.⁵ The first case described in this report was a 60-year-old man with folliculotropic mycosis fungoides (MF) that was well-controlled for 2 years who developed large cell transformation 1 week after his second dose of vaccine. The second case was a 73-year-old female with a 10-year history of early MF and type A LyP who was in remission the last 7 years and developed a recurrence of LyP 10 days after the first vaccine dose. Both patients received the AstraZeneca vaccine. An additional case of a recurrent primary CD30⁺ T-cell lymphoproliferative disorder most consistent with primary cutaneous anaplastic large cell lymphoma has also been

reported in a patient 2 days after receiving the first dose of the Pfizer-BioNTech formulation.⁶ In addition, new onset LyP following AstraZeneca and Pfizer-BioNTech vaccinations have recently been described.²⁴ Finally, a case of a T-cell predominant pseudolymphoma has been recently reported; however, this was at the site of injection rather than a widespread eruption.²⁵ The infiltrating T-cells did not show loss of mature T-cell antigens.²⁵

COVID-19 vaccination and/or infection are known to result in a robust immune response with both stimulation and exhaustion of T-cells.²⁶ It has been suggested that overproduction and exhaustion of both CD4⁺ and CD8⁺ T-cells combined with viral-associated CD30 expression facilitates the recurrence of known lymphoproliferative disorders/lymphomas⁵; however, this mechanism may be less relevant to the cases discussed herein as both patients received mRNA vaccines. Multiple studies have documented T-cells, including antigen-experienced subsets, that recognize SARS-CoV-2 in unexposed individuals.²⁷⁻³² In addition, a recent study has documented pre-existing SARS-CoV-2-specific T-cells in unexposed individuals that are cross-reactive to commensal bacterial flora from skin and the gastrointestinal tract.³³ Because it is well-recognized that mutation leading to overactive T-cell receptor signaling is an important driver of CTCL pathogenesis,^{34,35} it is possible that the antigens from the SARS-CoV-2 vaccine and/or virus stimulated pre-existing SARS-CoV-2-reactive T-cells in these cases and drove clonal proliferation of this (potentially already premalignant) population contributing to the development of lymphomas and lymphoproliferative disorders in rare cases.

Isolated cases of pseudolymphoma resembling cutaneous lymphoid hyperplasia (CLH) at the injection site have also been reported in the context of several vaccinations including those against COVID-19,³⁶ hepatitis A and hepatitis B,^{37,38} early summer meningoencephalitis,³⁸ tetanus,³⁸ quadrivalent human papillomavirus,³⁹ and influenza.⁴⁰ A causative role for aluminum hydroxide in the development of CLH-type injection site reactions has been suggested.³⁷ A case of marginal zone B-cell lymphoma has also been reported in the context of influenza vaccination.⁴⁰ One exceptional case showing a possible association between COVID-19 vaccination and spontaneous resolution of organ involvement by primary cutaneous anaplastic large cell lymphoma has also been reported, further suggesting that COVID-19 vaccination may modulate antitumor responses.⁴¹

These cases highlight that lymphomatoid reactions as well as overt lymphoma may be temporally associated with COVID-19 vaccination and/or infection with SARS-CoV-2. These examples may represent T-cell lymphoproliferative disorders that were unmasked by a change in the inflammatory milieu of the affected patients or possibly direct causation. These cases also highlight that establishing a diagnosis of CTCL or pseudolymphomatous reactive conditions is often challenging and requires close correlation with clinical findings and the course of disease.

CONFLICT OF INTEREST

The authors declare no conflict of interest.

DATA AVAILABILITY STATEMENT

Data sharing not applicable - no new data generated

ORCID

Scott C. Bresler  <https://orcid.org/0000-0003-2504-466X>

Alexandra C. Hristov  <https://orcid.org/0000-0002-1836-6591>

REFERENCES

- Sanghvi AR. COVID-19: an overview for dermatologists. *Int J Dermatol*. 2020;59(12):1437-1449. doi:10.1111/ijd.15257
- Niebel D, Novak N, Wilhelm J, et al. Cutaneous adverse reactions to covid-19 vaccines: insights from an immuno-dermatological perspective. *Vaccine*. 2021;9(9):944. doi:10.3390/vaccines9090944
- Recalcati S. Cutaneous manifestations in COVID-19: a first perspective. *J Eur Acad Dermatology Venereol*. 2020;34(5):e212-e213. doi:10.1111/jdv.16387
- McMahon DE, Amerson E, Rosenbach M, et al. Cutaneous reactions reported after Moderna and Pfizer COVID-19 vaccination: a registry-based study of 414 cases. *J Am Acad Dermatol*. 2021;85(1):46-55. doi:10.1016/j.jaad.2021.03.092
- Panou E, Nikolaou V, Marinos L, et al. Recurrence of cutaneous T-cell lymphoma (CTCL) post viral vector COVID-19 vaccination. *J Eur Acad Dermatology Venereol*. 2022;36(2):e91-e93. doi:10.1111/jdv.17736
- Brumfiel CM, Patel MH, DiCaudo DJ, Rosenthal AC, Pittelkow MR, Mangold AR. Recurrence of primary cutaneous CD30-positive lymphoproliferative disorder following COVID-19 vaccination. *Leuk Lymphoma*. 2021;62(10):2554-2555. doi:10.1080/10428194.2021.1924371
- Novice T, Ahn JW, Wilcox R, Tejasvi T, Hristov A, Mancuso J. Distinguishing reactive inflammatory dermatoses from lymphoma: 2 cases of severe drug reactions to phenytoin/phenobarbital and rosuvastatin mimicking lymphoma. *JAAD Case Rep*. 2020;6(4):311-315. doi:10.1016/j.jdcr.2020.01.016
- Kempf W, Petrella T, Willemze R, et al. Clinical, histopathological and prognostic features of primary cutaneous acral CD8⁺ T-cell lymphoma and other dermal CD8⁺ cutaneous lymphoproliferations: results of an EORTC Cutaneous Lymphoma Group Workshop. *Br J Dermatol*. 2022;186(5):887-897. doi:10.1111/bjd.20973
- Hunt M, Koziatsek C. A case of COVID-19 pneumonia in a young male with full body rash as a presenting symptom. *Clin Pract Cases Emerg Med*. 2020;4(2):219-221. doi:10.5811/cpcem.2020.3.47349
- Joob B, Wiwanitkit V. COVID-19 can present with a rash and be mistaken for dengue. *J Am Acad Dermatol*. 2020;82(5):e177. doi:10.1016/j.jaad.2020.03.036
- Jimenez-Cauhe J, Ortega-Quijano D, Prieto-Barrios M, Moreno-Arrones OM, Fernandez-Nieto D. Reply to "COVID-19 can present with a rash and be mistaken for dengue": petechial rash in a patient with COVID-19 infection. *J Am Acad Dermatol*. 2020;83(2):e141-e142. doi:10.1016/j.jaad.2020.04.016
- Bouaziz JD, Duong TA, Jachiet M, et al. Vascular skin symptoms in COVID-19: a French observational study. *J Eur Acad Dermatol Venereol*. 2020;34(9):e451-e452. doi:10.1111/jdv.16544
- Özütemiz C, Krystosek LA, Church AL, et al. Lymphadenopathy in COVID-19 vaccine recipients: diagnostic dilemma in oncologic patients. *Radiology*. 2021;300(1):E296-E300. doi:10.1148/radiol.2021210275
- Hagen C, Nowack M, Messerli M, Saro F, Mangold F, Bode PK. Fine needle aspiration in COVID-19 vaccine-associated lymphadenopathy. *Swiss Med Wkly*. 2021;151:w20557. doi:10.4414/smww.2021.20557
- Onsun N, Kaya G, Işık BG, Güneş B. A generalized pustular psoriasis flare after CoronaVac COVID-19 vaccination: case report. *Health Promot Perspect*. 2021;11(2):261-262. doi:10.34172/hpp.2021.32
- Triantafyllidis KK, Giannos P, Mian IT, Kyrtonis G, Kechagias KS. Varicella zoster virus reactivation following COVID-19 vaccination: a systematic review of case reports. *Vaccine*. 2021;9(9):1013. doi:10.3390/vaccines9091013
- Watad A, De Marco G, Mahajna H, et al. Immune-mediated disease flares or new-onset disease in 27 subjects following mRNA/DNA SARS-CoV-2 vaccination. *Vaccine*. 2021;9(5):435. doi:10.3390/vaccines9050435
- Lospinoso K, Nichols CS, Malachowski SJ, Mochel MC, Nutan F. A case of severe cutaneous adverse reaction following administration of the Janssen Ad26.COV2.S COVID-19 vaccine. *JAAD Case Rep*. 2021;13:134-137. doi:10.1016/j.jdcr.2021.05.010
- Dash S, Sirka CS, Mishra S, Viswan P. COVID-19 vaccine-induced Stevens-Johnson syndrome. *Clin Exp Dermatol*. 2021;46(8):1615-1617. doi:10.1111/ced.14784
- Tomayko MM, Damsky W, Fathy R, et al. Subepidermal blistering eruptions, including bullous pemphigoid, following COVID-19 vaccination. *J Allergy Clin Immunol*. 2021;148(3):750-751. doi:10.1016/j.jaci.2021.06.026
- Lim PN, Wylie G. Symmetrical drug-related intertriginous and flexural exanthema like eruption associated with COVID-19 vaccination. *Clin Exp Dermatol*. 2022;47(1):175-176. doi:10.1111/ced.14898
- Hai J, Shawa H, Kim-Lim P, et al. Systemic drug-related intertriginous and flexural exanthema (SDRIFE) induced by the Pfizer-BioNTech COVID-19 vaccine: a report of 2 cases. *JAAD Case Rep*. 2021;18:57-60. doi:10.1016/j.jdcr.2021.10.016
- Waraiha A, Williams G. Haematuria, a widespread petechial rash, and headaches following the Oxford AstraZeneca ChAdOx1 nCoV-19 vaccination. *BMJ Case Rep*. 2021;14(10):e245440. doi:10.1136/bcr-2021-245440
- Koumaki D, Marinos L, Nikolaou V, et al. Lymphomatoid papulosis (LyP) after AZD1222 and BNT162b2 COVID-19 vaccines. *Int J Dermatol*. 2022;61(7):900-902. doi:10.1111/ijd.16296
- Mintoff D, Scerri L, Betts A. SARS-CoV-2 mRNA vaccine injection site pseudolymphoma. *J Eur Acad Dermatol Venereol*. 2022;36(1):e20-e22. doi:10.1111/jdv.17680
- Vardhana S, Baldo L, Morice WG, Wherry EJ. Understanding T cell responses to COVID-19 is essential for informing public health strategies. *Sci Immunol*. 2022;7(71):eabo1303. doi:10.1126/sciimmunol.abo1303
- Grifoni A, Weiskopf D, Ramirez SI, et al. Targets of T cell responses to SARS-CoV-2 coronavirus in humans with COVID-19 disease and unexposed individuals. *Cell*. 2020;181(7):1489-1501.e15. doi:10.1016/j.cell.2020.05.015
- Mateus J, Grifoni A, Tarke A, et al. Selective and cross-reactive SARS-CoV-2 T cell epitopes in unexposed humans. *Science*. 2020;370(6512):89-94. doi:10.1126/science.abd3871
- Le Bert N, Tan AT, Kunasegaran K, et al. SARS-CoV-2-specific T cell immunity in cases of COVID-19 and SARS, and uninfected controls. *Nature*. 2020;584(7821):457-462. doi:10.1038/s41586-020-2550-z
- Braun J, Loyal L, Frentsch M, et al. SARS-CoV-2-reactive T cells in healthy donors and patients with COVID-19. *Nature*. 2020;587(7833):270-274. doi:10.1038/s41586-020-2598-9
- Nelde A, Bilich T, Heitmann JS, et al. SARS-CoV-2-derived peptides define heterologous and COVID-19-induced T cell recognition. *Nat Immunol*. 2021;22(1):74-85. doi:10.1038/s41590-020-00808-x
- Bacher P, Rosati E, Esser D, et al. Low-avidity CD4⁺ T cell responses to SARS-CoV-2 in unexposed individuals and humans with severe COVID-19. *Immunity*. 2020;53(6):1258-1271.e5. doi:10.1016/j.immuni.2020.11.016
- Bartolo L, Afroz S, Pan Y-G, et al. SARS-CoV-2-specific T cells in unexposed adults display broad trafficking potential and cross-react with commensal antigens. *Sci Immunol*. 2022;7:eabn3127. doi:10.1126/sciimmunol.abn3127
- Herrera A, Cheng A, Mimitou EP, et al. Multimodal single-cell analysis of cutaneous T-cell lymphoma reveals distinct subclonal tissue-dependent signatures. *Blood*. 2021;138(16):1456-1464. doi:10.1182/blood.202009346

35. Park J, Daniels J, Wartewig T, et al. Integrated genomic analyses of cutaneous T-cell lymphomas reveal the molecular bases for disease heterogeneity. *Blood*. 2021;138(14):1225-1236. doi:[10.1182/blood.202009655](https://doi.org/10.1182/blood.202009655)
36. LeWitt T, Chung C, Manton J, et al. Rare lymphomatoid reactions following SARS-CoV-2 vaccination. *JAAD Case Rep*. 2022;20:26-30. doi:[10.1016/j.jdc.2021.11.021](https://doi.org/10.1016/j.jdc.2021.11.021)
37. Maubec E, Pinquier L, Viguier M, et al. Vaccination-induced cutaneous pseudolymphoma. *J Am Acad Dermatol*. 2005;52(4):623-629. doi:[10.1016/j.jaad.2004.12.021](https://doi.org/10.1016/j.jaad.2004.12.021)
38. Cerroni L, Borroni RG, Massone C, Chott A, Kerl H. Cutaneous B-cell pseudolymphoma at the site of vaccination. *Am J Dermatopathol*. 2007;29(6):538-542. doi:[10.1097/DAD.0b013e3181591bea](https://doi.org/10.1097/DAD.0b013e3181591bea)
39. Ramos Pinheiro R, Duarte B, João A, Lencastre A. Cutaneous pseudolymphoma following quadrivalent human papillomavirus vaccination—a rare adverse event. *J Dtsch Dermatol Ges*. 2018;16(4):465-467. doi:[10.1111/ddg.13470](https://doi.org/10.1111/ddg.13470)
40. May SA, Netto G, Domiati-Saad R, Kasper C. Cutaneous lymphoid hyperplasia and marginal zone B-cell lymphoma following vaccination. *J Am Acad Dermatol*. 2005;53(3):512-516. doi:[10.1016/j.jaad.2005.04.036](https://doi.org/10.1016/j.jaad.2005.04.036)
41. Gambichler T, Boms S, Hessam S, et al. Primary cutaneous anaplastic large-cell lymphoma with marked spontaneous regression of organ manifestation after SARS-CoV-2 vaccination. *Br J Dermatol*. 2021;185(6):1259-1262. doi:[10.1111/bjd.20630](https://doi.org/10.1111/bjd.20630)

How to cite this article: Bresler SC, Menge TD, Tejasvi T, Carty SA, Hristov AC. Two cases of challenging cutaneous lymphoid infiltrates presenting in the context of COVID-19 vaccination: A reactive lymphomatoid papulosis-like eruption and a bona fide lymphoma. *J Cutan Pathol*. 2023;50(3): 213-219. doi:[10.1111/cup.14371](https://doi.org/10.1111/cup.14371)