

# Flap versus flapless alveolar ridge preservation: A clinical and histological single-blinded, randomized controlled trial

Trever L. Siu<sup>\*</sup>, Himabindu Dukka<sup>†</sup>, Muhammad H.A. Saleh<sup>‡</sup>, Mustafa Tattan<sup>§</sup>, Ziad Dib<sup>†</sup>, Andrea Ravidà<sup>\*\*</sup>, Henry Greenwell<sup>†</sup>, Hom-Lay Wang<sup>‡</sup>, Mauricio G. Araujo<sup>††</sup>

<sup>1</sup> The first and second author contributed equally to the manuscript

Corresponding author:

Hom-Lay Wang, DDS, MSD, PhD

Department of Periodontics and Oral Medicine,

---

<sup>\*</sup> Department of Periodontics, Midwestern University Clinics, Glendale, AZ

<sup>†</sup> Department of Periodontics, University of Louisville School of Dentistry, Louisville, KY

<sup>‡</sup> Department of Periodontics and Oral Medicine, University of Michigan School of Dentistry, Ann Arbor, MI, USA

<sup>§</sup> Department of Periodontics, College of Dentistry, University of Iowa, Iowa City, Iowa

<sup>\*\*</sup> Department of Periodontics & Oral Medicine, University of Pittsburg, Pittsburg, PA, USA.

<sup>††</sup> Department of Periodontics, Department of Dentistry, State University of Maringá, Maringá, Brazil.

This is the author manuscript accepted for publication and has undergone full peer review but has not been through the copyediting, typesetting, pagination and proofreading process, which may lead to differences between this version and the [Version of Record](#). Please cite this article as [doi: 10.1002/jper.11012](https://doi.org/10.1002/jper.11012).

This article is protected by copyright. All rights reserved.

University of Michigan School of Dentistry

1011 North University Avenue

Ann Arbor, Michigan 48109-1078, USA.

TEL: (734) 763-3325; FAX: (734) 936-0374 E-mail address: homlay@umich.edu

Abstract word count: 254

Total word count: 3640

Total number of tables and figures: 3 Tables; 3 Figures

Supplementary figures: 1 Figure

Number of references: 33

**Running title: Flap versus flapless alveolar ridge preservation.**

**Key words (MeSH):** clinical trial; dental implant; alveolar ridge augmentation; tooth extraction; tooth socket.

**Authors' contributions:** TS, ZD performed the surgeries, HG, TS, ZD contributed to the conception and design of the work. TS, ZD and HD collected and analyzed the data; MS, MT, TS and ZD contributed to manuscript preparation, HLW, MA and MS made critical changes and gave final approval to the manuscript. All authors gave their final approval and agreed to be accountable for all aspects of the work.

**Conflict of Interest and Source of Funding:** The authors do not have any financial interests, either directly or indirectly, in the products or information listed in the paper.

**Data availability:** The data that support the findings of this study are available from the corresponding author upon request.

**One sentence summary:** Alveolar ridge preservation, using either flap or flapless approach, did not make any significant difference in crestal ridge width, height, and percentage of vital mineralized bone.

**Acknowledgments:** None.

## ABSTRACT

**Background:** The aim of this randomized clinical trial was to compare a flapless technique of alveolar ridge preservation (ARP) to a flap technique, to determine if preserving the periosteal blood supply would limit loss of crestal ridge width and height.

**Materials and Methods:** Twenty-four patients were randomly assigned to receive ARP using either a flapless or flap technique. Sockets were grafted with demineralized bone matrix and mineralized particulate allograft then covered with a barrier. Re-entry was performed at 4 months to obtain samples for histological analysis and subsequent implant placement.

**Results:** Ridge width of the flapless group at the crest decreased from  $8.3 \pm 1.3$  mm to  $7.0 \pm 1.9$  mm for a mean loss of  $1.3 \pm 0.9$  mm ( $p < 0.05$ ), whereas the flap group decreased from  $8.5 \pm 1.5$  mm to  $7.5 \pm 1.5$  mm for a mean loss of  $1.0 \pm 1.1$  mm ( $p < 0.05$ ). The mean mid-buccal vertical change for the flap group was a loss of  $0.9 \pm 1.3$  mm ( $p < 0.05$ ) versus  $0.5 \pm 0.9$  mm ( $p < 0.05$ ) for the flapless group. There was no statistically significant difference between the groups. Histologically, flapless ARP revealed more vital mineralized tissue ( $44 \pm 10\%$ ) compared to the flap group ( $p > 0.05$ ). In the flapless group, the occlusal soft tissue was significantly thicker than the flap group at the 4-month reentry ( $p < 0.05$ ).

**Conclusions:** Crestal ridge width, height, and percentage of vital mineralized bone following treatment with a flapless ARP technique was not significantly different from a flap technique.

## 1 | INTRODUCTION

Alveolar ridge preservation (ARP) is a procedure designed to attenuate post-extraction osseous ridge dimension changes. Most studies on post-extraction dimensional changes show that following extraction of single teeth, the horizontal dimension is most affected by loss while the vertical dimension undergoes only slight change.<sup>1, 2</sup> Extraction studies, in general, show that there is substantial loss of horizontal ridge width that increases with time. Thus, studies with 12-month observational periods demonstrate more loss than 6-month follow-up studies which show more loss than 4-month follow-up studies.”<sup>3-5</sup>

Reflection of a mucoperiosteal flap has been shown to cause loss of crestal alveolar bone.<sup>6</sup> These studies were performed with the tooth present when the crestal bone had a dual blood supply from both the periosteum as well as the periodontal ligament, and when it was not possible to determine an effect on ridge width.<sup>7</sup> Crestal bone loss may have been at least in part due to the disruption of blood supply derived from the periosteum. The thin nature of the crestal bone and its minimal vascular supply make it prone to resorption leading to loss of crestal width<sup>8</sup>. Hence, it may seem advantageous to avoid flap reflection and preserve the remaining blood supply from the periosteum.

However, there is still conflicting evidence regarding significant benefit, or lack thereof, associated with a flapless surgical procedure compared to traditional flap reflection as it relates to post-extraction bone loss and subsequent ARP procedures. Animal studies have not demonstrated a significant difference in alveolar bone loss between full thickness flap and flapless or partial thickness flap elevation.<sup>9, 10</sup> Similarly, no histological or histomorphometric differences were reported between the flap and flapless approaches for tooth extraction and socket grafting procedures in humans.<sup>11</sup> In contrast, in a human study by Barone et al. and a canine model by Fickl et al., it was shown that more bone resorption occurred with a full thickness flap in post-extraction sockets.<sup>12, 13</sup> As indicated by the recent systematic reviews, there is a need for clinical studies investigating ARP that allow for direct comparison between surgical variables, such as flap reflection among others.<sup>3, 14</sup>

Hence, the primary aim of this randomized controlled single-blinded clinical trial was to compare a flapless technique of ARP versus a conventional flap technique. We hypothesize that preserving the periosteal blood supply may minimize loss of crestal ridge width and height.

As a secondary objective, the histological composition of the newly formed bone that occupies the extraction socket was evaluated to determine vital bone percentage. It was hypothesized that the increased vascularity provided by the intact periosteum lining the facial and lingual bone may promote more rapid vascularization of the graft resulting in greater formation of vital bone and faster resorption of non-vital/residual graft particles.

## **2 | MATERIALS AND METHODS**

### **2.1 | Ethical approval and registration**

This randomized, single-blinded controlled clinical trial reports on patients presenting to the Graduate Periodontology Clinic at the University of Louisville, Kentucky, and requiring ARP for the purpose of implant placement. This study was conducted in accordance with the Helsinki Declaration for the ethical principles for medical research involving human subjects, as revised in 2013. The study was approved by the Institutional Review Board (IRB) of University of Louisville, Kentucky, protocol #047.06. The study was registered at U.S. national library of medicine (ClinicalTrials.gov: NCT01901783). The present study complied with the Consolidated Standards Of Reporting Trials (CONSORT) guidelines.<sup>15</sup>

### **2.2 | Study design and population**

Twenty-four patients participated in this randomized controlled single-blinded clinical trial with two parallel study groups, conducted at a single center. This study was conducted at the University of Louisville School of Dentistry, Department of Periodontics. By random selection, using a coin toss, patients were assigned either to the test or control group. Twelve control patients were selected to receive an intrasocket graft composed of demineralized bone matrix allograft<sup>¶</sup> mixed with a cortico-cancellous mineralized particulate allograft<sup>#</sup> and covered by a calcium sulfate barrier<sup>\*\*</sup> using a full-thickness flap technique. Twelve test patients received the same intrasocket allograft mixture covered

by a calcium sulfate barrier using a flapless technique. All clinicians and examiners participating in the trial were calibrated before the surgeries and the measurements.

### **2.3 | Inclusion criteria**

The following inclusion criteria were applied: (1) had one non-molar tooth treatment planned for extraction and replacement with a dental implant where at least one adjacent tooth was present, (2) the study subjects were at least 18 years old and had signed an informed consent.

### **2.4 | Exclusion Criteria**

The following exclusion criteria were applied: (1) had a debilitating systemic disease, or a disease that affected the periodontium, (2) had an allergy to any material or medication used in the study, (3) required prophylactic antibiotics, (4) had previous head and neck radiation therapy, (5) had chemotherapy in the previous 12 months, (6) were taking long term Nonsteroidal Anti-inflammatory Drugs or steroid therapy, (7) smoked more than one pack of cigarettes per day.

### **2.5 | Surgical treatment**

For the flap group, a papilla preservation incision was utilized to raise a full thickness mucoperiosteal flap on the facial and palatal/lingual to expose the alveolar ridge (Figure 1a- a, b). The flap was reflected past the mucogingival junction, beyond 5mm from the crest. Teeth were elevated and extracted with periostomes, elevators, and forceps. For the flapless group, the same extraction technique was utilized without flap reflection (Figure 1b, a, b). The extraction socket was then curetted to remove all granulation tissue. Both the demineralized bone matrix and the mineralized cortico-cancellous particulate allograft were hydrated in sterile water for about 10 minutes. For both the flap and flapless groups, 0.5cc of mineralized particulate allograft was thoroughly mixed with one package of demineralized bone matrix. The mixture was placed into the socket to the level of the socket crest. A criss-cross suture was placed over the bone graft in both groups to provide retention for the calcium sulfate barrier. The calcium sulfate barrier was mixed and placed over the bone graft and was contained by the buccal and palatal/lingual flaps. A second criss-cross suture was placed over the barrier after it had completely set. In the flap group, the flaps were replaced and sutured with 5-0

monofilament polyglyconate sutures<sup>††</sup>. At 4-months, papilla preservation incisions were utilized, and a full thickness flap was elevated for both the flap and flapless groups. Core Biopsies were taken using trephine burs. Following that, osteotomy for implant placement, was performed according to the manufacturer recommendation and implants were placed.

Each patient received a post-surgical regimen of oral antibiotics (Doxycycline Hyclate 50 mg daily for 2 weeks), anti-inflammatory (Naproxen Sodium 375 mg for 1 week), 0.12% chlorhexidine gluconate rinse twice daily, and analgesics as needed. Patients also received detailed oral hygiene instructions.

At 4 months post-surgery, a 2.7x6 mm trephine core was taken from the center of the grafted socket immediately prior to implant placement. The core was placed in 10% buffered formalin and submitted for histological preparation. The osteotomy site was then fully prepared, and a dental implant placed.

## 2.6 | Outcome Measurements

### 2.6.1 | Clinical Indices and Parameters

Each patient received a diagnostic work-up including standardized periapical radiographs, study models, clinical photographs, and a clinical examination to record attachment level, probing depth, recession, and mobility of teeth adjacent to the extraction sites. A customized acrylic occlusal stent was fabricated on the study models to serve as a fixed reference guide for the vertical measurements.<sup>12</sup>

Pre-surgical baseline data consisted of measurements on the site to be treated included: 1) keratinized tissue and 2) soft tissue thickness measured using the dedicated tissue thickness meter<sup>‡‡</sup>.<sup>16-18</sup>

After tooth extraction, the following measurements were recorded: 1) horizontal ridge width at the crest and 5 mm apical to the crest using a digital caliper<sup>§§</sup> and 2) vertical height of the ridge relative to an acrylic stent customized to fit on neighboring teeth.<sup>12</sup> All height measurements were done at mid-buccal, mid-lingual, mesial and distal, all of them were measured at the crest using a custom stent (Figure 2). For the flapless group, a 2 mm soft tissue plug was removed at the ridge crest using a trephine to create access for the digital caliper. The measurement 5 mm apical to the crest was not performed for the flapless group.

At 4 months, another standardized radiograph was taken. All baseline indices and measurements were repeated. A blinded examiner performed all clinical measurements for both the initial and final data collection points.

## 2.6.2 | Histological analysis

Trephine cores 2.7 X 6 mm were decalcified, sectioned, and prepared for histological analysis using hematoxylin and eosin staining. Twelve to 15 step serial sections were taken from the center of each longitudinally sectioned trephine core. Six randomly selected fields, one per slide, if possible, were used to obtain percent of vital bone, remaining graft particles, and trabecular space using a light microscope<sup>†</sup> at 150X, with a 10X objective and Nikon<sup>®</sup> 15X reticle eyepieces<sup>††</sup>.

## 2.7 | Data Analysis

Means and standard deviations were calculated for all parameters. The data were analyzed using a paired t-test to determine the statistical significance of the differences between baseline and follow-up data and an unpaired t-test was used to evaluate statistical difference between the test and control groups. A predetermined sample size of 12 gave 83% statistical power to detect a difference of 1 mm ridge width between the groups with a standard deviation of 0.8 mm. The mean and standard deviation used for the power calculation was based on data from previous studies.<sup>19, 20</sup> The histomorphometric analysis was performed using an independent t-test. In all tests, statistical significance was set at a p-value of 0.05. All data analysis was conducted using a commercially available software<sup>††</sup>.

# 3 | RESULTS

## 3.1 | Sample characteristics

A total of 16 females and 8 males with a mean age of  $55.0 \pm 14.4$  years, ranging from 26 to 78 years, were enrolled. Patients were equally distributed between the two study groups, with 12 patients per group and no dropouts. Recruitment stopped after required sample size was reached in both groups. The study design

flowchart is presented in Table 1. No difference was noted in terms of early post-operative healing between the two groups and implants were successfully placed at all treated sites for the flapless group. Implant placement was delayed at two sites in the flap group; one site needed sinus augmentation prior to implant placement while the other required restorative work on adjacent teeth prior to implant placement and placement was delayed by four and one month, respectively.



### 3.2 | Alveolar ridge width at the crest

Flap cases had a mean initial width at the crest of  $8.5 \pm 1.5$  mm, which decreased to  $7.5 \pm 1.5$  mm at the 4-month re-entry for a mean loss of  $1.0 \pm 1.1$  mm ( $p < 0.05$ , Table 2). Flapless cases presented with a mean initial width at the crest of  $8.3 \pm 1.3$  mm, which decreased to  $7.0 \pm 1.9$  mm at the 4-month re-entry for a mean loss of  $1.3 \pm 1.0$  mm ( $p < 0.05$ ). There were no statistically significant differences between the flap and flapless groups ( $p > 0.05$ , Table 2a).

### 3.3 | Alveolar ridge width 5 mm apical to the crest

Flap cases presented with a mean loss of  $0.6 \pm 1.0$  mm ( $p > 0.05$ ). For the flapless group, there were no ridge width measurements 5 mm apical to the crest at baseline. At the 4-month re-entry, the flap and flapless cases had a similar mean width of  $8.6 \pm 1.4$  mm and  $8.0 \pm 1.6$  mm, respectively. There were no statistically significant differences between the flap and flapless groups at 5 mm apical to the crest ( $p > 0.05$ , Table 2a).

### 3.4 | Changes in vertical ridge height

Over a period of 4 months, the flap group showed a statistically significant decrease in the mean facial height of  $0.9 \pm 1.3$  mm ( $p < 0.05$ ). In the flapless group, there was a statistically significant mean loss of facial height of  $0.5 \pm 0.9$  mm ( $p < 0.05$ ). There were no statistically significant differences between groups in terms of vertical change ( $p > 0.05$ ). Vertical ridge height changes are reported in Table 2b.

### 3.5 | Histological Evaluation

A high percentage of vital bone was found in both groups (Table 3). Histological analysis revealed that flap sites healed with  $35 \pm 15\%$  vital bone,  $19 \pm 12\%$  remaining graft particles,  $46 \pm 17\%$  trabecular space. The flapless sites healed with  $44 \pm 10\%$  vital bone,  $17 \pm 13\%$  remaining graft particles,  $39 \pm 9\%$  trabecular space. There were no statistically significant differences between the flap and flapless groups ( $p > 0.05$ ) (Table 3 and "see Figure S1 in online Journal of Periodontology").

### 3.6 | Bone Quality

Bone quality was assessed subjectively as Type I through IV for all sites.<sup>21</sup> The flap group was comprised of 1 Type I site, 2 Type II sites, 8 Type III sites, and 1 Type IV site. The flapless group consisted of 1 Type I site, 7 Type II sites, 3 Type III sites, and 1 Type IV site (Figure 3).

### 3.7 | Soft Tissue Thickness

Soft tissue thickness increased from 0.1 to 0.4 mm on the facial and lingual for both the flap and flapless groups (Table 2c). This increase was statistically significant only on the lingual for both groups ( $p < 0.05$ ). In the flapless group, the occlusal soft tissue was significantly thicker than the flap group at the 4-month reentry ( $p < 0.05$ ).

## 4 | DISCUSSION

In this 4-month randomized controlled clinical study of alveolar ridge preservation, a flapless surgical technique was compared to a flap reflection technique. While there are a number of pre-clinical and clinical studies comparing the two surgical techniques for implant placement, this is one of the very few human studies investigating ridge alterations as it relates to ARP.<sup>22-24</sup> For both groups, the socket was grafted using a demineralized bone matrix allograft mixed with a mineralized particulate allograft then capped with a calcium sulfate barrier in the socket opening to contain the graft. There were no statistically significant differences in ridge dimension changes between groups in this study (Figure 1a c & d, Figure 1b c & d). These findings are in agreement with the results demonstrated by Araujo & Lindhe and Filipek et al., in that, there is no statistically significant difference in hard tissue loss between the two surgical approaches.<sup>9,25</sup> Araujo & Lindhe examined the ridge dimension changes in an animal model following tooth extraction with and without flap reflection, while Filipek et al., did a hard and soft tissue comparative analysis between flap and flapless tooth extractions in humans.<sup>9,25</sup> Furthermore, the current findings also confirmed that bone loss cannot be prevented completely irrespective of the surgical approach used, which concurred with the results of several other studies.<sup>9,12,19</sup> However, our findings differed from the conclusions of Fickl et al., and Barone et al.<sup>12,13</sup> who evaluate healing socket sites at earlier time intervals. Fickl et al., examined the tissue alterations following tooth extraction in flap and flapless groups at 2- and 4-month time intervals.<sup>13</sup> Their canine

study showed increased soft and hard tissue loss in the flap group but the experimental model did not distinctly distinguish between hard and soft tissue components. The human study conducted by Barone et al., examining the socket healing in flap vs. flapless procedures after 3 months of healing, showed statistically significant differences in buccolingual width and vertical ridge height between the two groups.<sup>12</sup> The flapless group showed more loss in the ridge height compared to the flap group. They investigated soft and hard tissue changes in extraction sockets grafted with cortico-cancellous porcine bone and a collagen membrane after 3 months. The teeth included in their analysis were molars and premolars. The differences in tooth type, graft materials and healing time period may have contributed to the difference in results.

The flapless group showed a loss of 1.3 mm in crestal ridge width which was slightly greater than the flap group with the loss of 1.0 mm (Table 2). Both groups lost ridge height at all locations (mid-buccal, mid-lingual, mesial and distal). Although these changes were not statistically significant between groups, the flapless group showed less loss of ridge height than the flap group. The flap group showed a loss of ridge height of 0.8 - 0.9 mm at all locations. The flapless group showed the greatest loss of 0.7 mm at the mid-lingual site and the least loss of 0.2 mm at the mesial site (Table 3) which was comparable to 0.9 ±0.9 mm (lingual) and 0.2 ±0.7mm (mesial) vertical dimension loss in a flapless ridge preservation study by Barone et al.<sup>11</sup>

Whether raising a flap would negatively influence the outcomes of ARP is controversial, but what we know is that the extent of facial bone loss after extraction depends on several unrelated factors. The ones that seem to stand out most prominently are facial bone thickness and tooth angulation.<sup>26</sup> In a landmark computed tomography study, teeth with facial bone thickness  $\leq 1$  mm had a median vertical bone loss of 7.5 mm (62% of facial height) after just 8 weeks of flapless extraction.<sup>27</sup> Interestingly, in 90% of cases in the anterior maxilla, facial bone thickness is  $< 1$  mm; and  $< 0.5$  mm in roughly 50% of cases.<sup>28-30</sup> On the other hand, patients with a facial wall thickness of  $> 1$  mm, exhibited only a median vertical bone loss of 1.1 mm<sup>27</sup>. What literature shows and this study confirms, is that short-term hard tissue changes following ARP with either a flapped or flapless approach are very similar<sup>31</sup>.

Trephine cores were taken from the center of the grafted socket at 4 months for histological analysis (Supplementary Figure 1). There was approximately 40% vital bone and 18% non-vital residual graft particles in each group with no statistically significant differences between groups. This was consistent with previous reports of the 3 to 6-month histological composition of the ridge following placement of mineralized particulate allograft into sockets.<sup>11, 19</sup> However, the percentage of vital bone was higher in the current study compared to Barone et al., who showed 22.5%.<sup>11</sup> Perhaps the higher percentage of vital bone at 4 month is the reason why the flapless group had relatively denser bone at the time of

implant placement (Figure 3).

This study evaluated loss of crestal ridge width in extraction sites with at least one adjacent tooth. Eighteen of the 24 sites had two adjacent teeth. Loss of crestal width may be greater when there are no adjacent teeth, when a terminal tooth is extracted, and especially when all teeth in an arch are being removed. This observation was in agreement with the findings of Chen et al., and Schropp et al.<sup>32, 33</sup> Thus, the means and ranges reported in this study may not be generalizable and should be limited in application to bounded single-tooth sites.

Overall, changes in the crestal ridge dimensions did not show any statistically significant differences between the flap and flapless ARP techniques. The observation made in our study is largely in agreement with that presented by Araujo & Lindhe (2009)<sup>9</sup> in that, similar amount of bone loss was noted among the two techniques, and while the latter was an animal study, the present study is in humans. Within the limitations of this study, a flap could be used with minimal compromise to the bone when necessary for an ARP procedure. As with most procedures, there are indications and contraindications for use of the flapless technique. It is yet to be determined if the difference in crestal ridge alterations between flap and flapless techniques is significant enough to impact the outcome of implant placement or has a long-lasting detrimental effect on the final ridge dimensions. The results from this study did not indicate the aforementioned.

## 5 | CONCLUSION

In conclusion, post-extraction dimensional changes of the alveolar ridge were statistically comparable between the flap and flapless surgical techniques. Similarly, percent of vital bone and remaining graft particles were comparable between the two surgical approaches. Though, the flapless technique may result in an increased tissue thickness at the occlusal aspect.

## CONFLICT OF INTEREST

All authors declare that they have no conflict of interest related to this manuscript.

Table 1: Clinical indices for flap and flapless sites (Mean ± SD).

		Baseline (index units)	4 months (index units)	Change (index units)
<b>Mean Plaque Index</b>	Flap	0.1 ± 0.2	0.2 ± 0.2	-0.1 ± 0.2
	Flapless	0.1 ± 0.2	0.0 ± 0.1	0.1 ± 0.2
<b>Mean Gingival Index</b>	Flap	0.1 ± 0.1	0.0 ± 0.0	0.1 ± 0.1
	Flapless	0.1 ± 0.2	0.0 ± 0.1	0.1 ± 0.2
<b>Mean Bleeding on Probing</b>	Flap	0.2 ± 0.2	0.1 ± 0.2	0.1 ± 0.3
	Flapless	0.2 ± 0.3	0.1 ± 0.2	0.1 ± 0.2

SD= standard deviation

Table 2a: Horizontal crestal ridge width changes (in mm) for flap and flapless sites (Mean ± SD).

	n	Baseline (mm)	4 months (mm)	Change (mm)	Range (mm)
<b>Horizontal crestal ridge width</b>					
<b>At Crest</b>	Flap	8.5 ± 1.5	7.5 ± 1.5	-1.0 ± 1.1*	-2.5 to -0.9
	Flapless	8.3 ± 1.3	7.0 ± 1.9	-1.3 ± 1.0*	-2.7 to +0.5

At 5 mm	Flap	12	9.2 ± 1.6	8.6 ± 1.4	-0.6 ± 1.0	-2.5 to 1.5
	Flapless			8.0 ± 1.6		

\* = p < 0.05 between initial and 4-month values; \*\* = p < 0.05 between flap and flapless groups; SD=standard deviation

Table 2b: Vertical ridge height change for flap and flapless sites (Mean ± SD).

Location	Flap	Flapless	Flap	Flapless
	Mean change (in mm)		Range (in mm)	
Mid-Buccal	-0.9 ± 1.3*	-0.5 ± 0.9*	-2.5 to 2.5	-2.0 to 1.0
Mid-Lingual	-0.9 ± 1.3*	-0.7 ± 1.1*	-2.5 to 1.0	-2.5 to 1.5
Mesial	-0.8 ± 0.8*	-0.2 ± 0.5*	-2.2 to 0.5	-1.0 to 0.7
Distal	-0.9 ± 0.7*	-0.3 ± 0.7*	-1.8 to 0.2	-1.8 to 1.0

\* = p < 0.05 between initial and 4-month values; SD=standard deviation

Table 2c: Soft tissue thickness changes (in mm) for flap and flapless sites (Mean ± SD).

	n	Baseline (mm)	4 months (mm)	Change (mm)	Range (mm)
		Soft tissue thickness changes			
<b>Flap</b>					
Buccal	12	1.1 ± 0.5	1.3 ± 0.6	0.2 ± 0.7	-1.2 ± 1.4
Lingual		2.0 ± 1.0	2.3 ± 1.3	0.3 ± 0.7*	-1.4 ± 1.6
Occlusal		1.7 ± 0.5	1.2 ± 2.9		
<b>Flapless</b>					
	12				

Buccal	0.9 ± 0.4	1.0 ± 0.4	0.1 ± 0.3	-0.4 ± 0.6
Lingual	2.3 ± 0.5	2.7 ± 0.5	0.4 ± 0.5*	-0.6 ± 1.3
Occlusal		2.3 ± 0.8**		0.8 ± 3.1

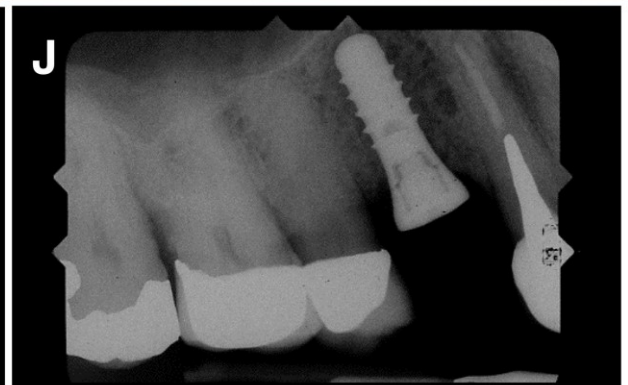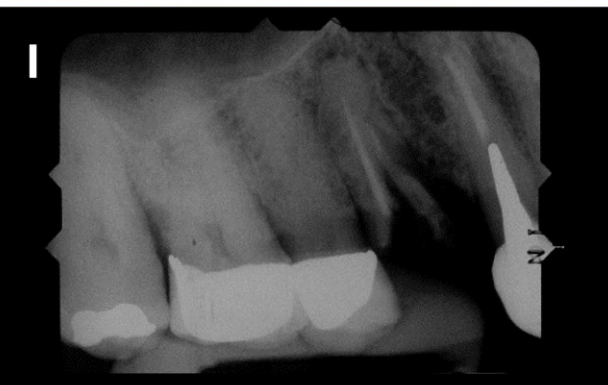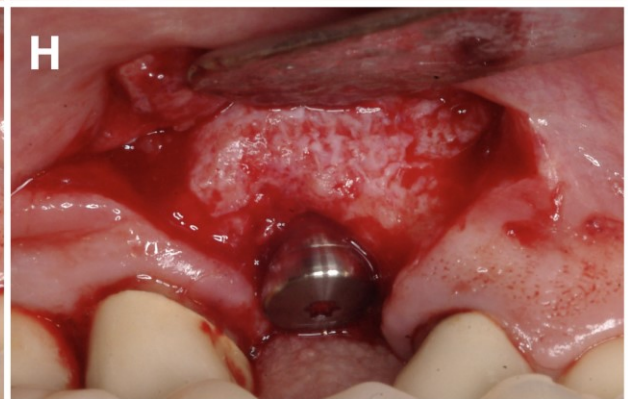
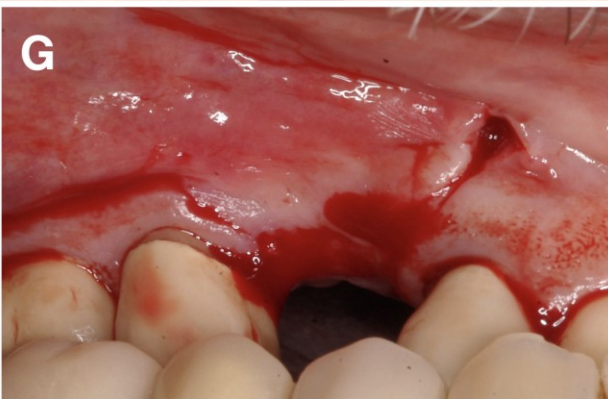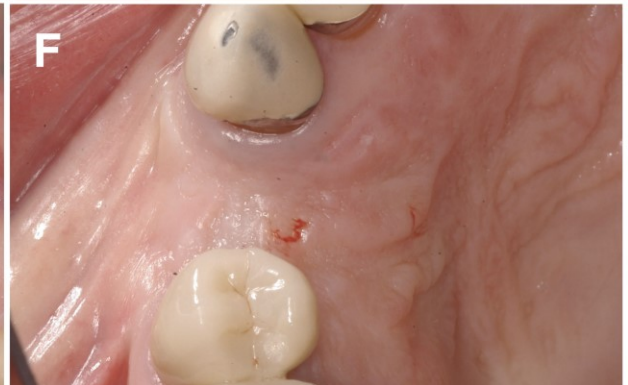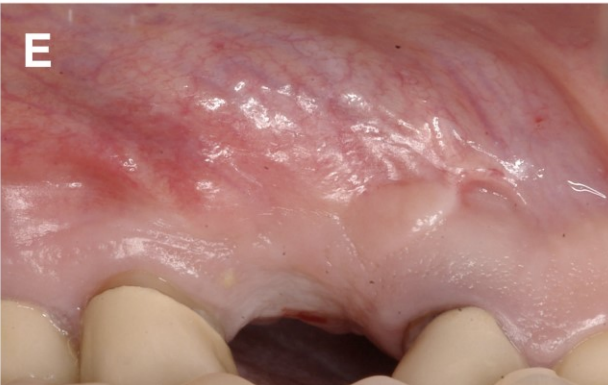
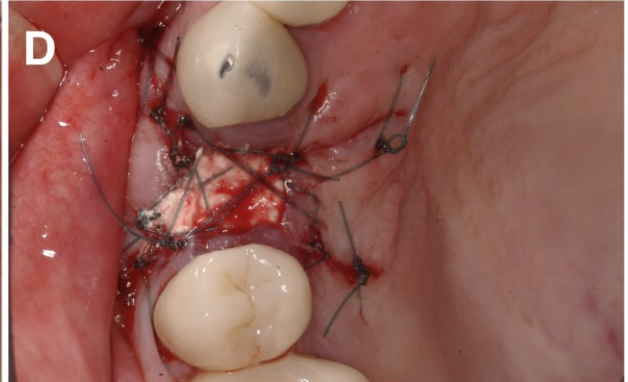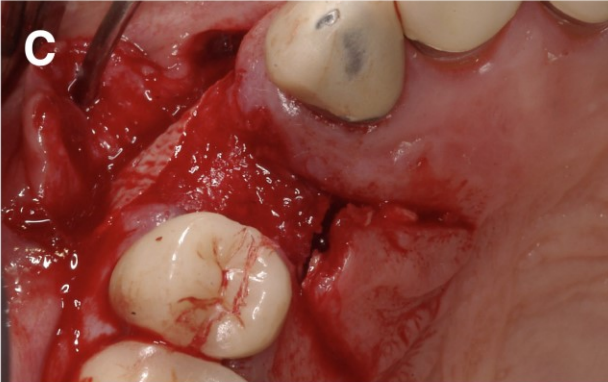
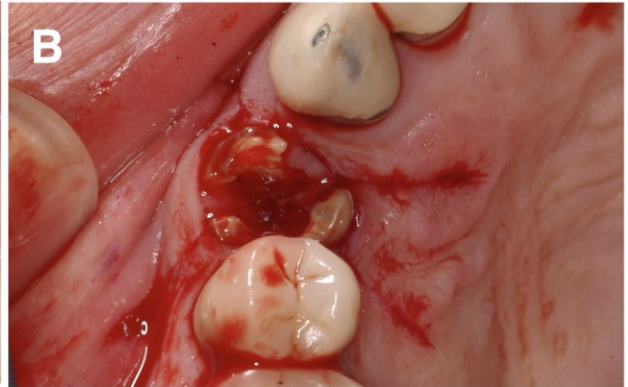
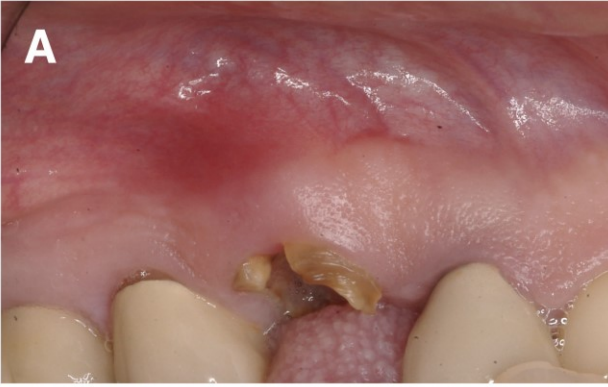\* = p < 0.05 between initial and 4-month values; \*\* = p < 0.05 between flap and flapless groups; SD=standard deviation

Table 3: Histological data at implant placement for flap and flapless sites (Mean percentage ± SD).

Study group	Timepoint	n	VMT (%)	NVMT (%)	% Trabecular bone
Flap	4 months	12	35 ± 15	19 ± 12	46 ± 17
Flapless	4 months	12	44 ± 10	17 ± 13	39 ± 9

SD=standard deviation; VMT: Vital mineralized tissue; NVMT: Non-vital mineralized tissue

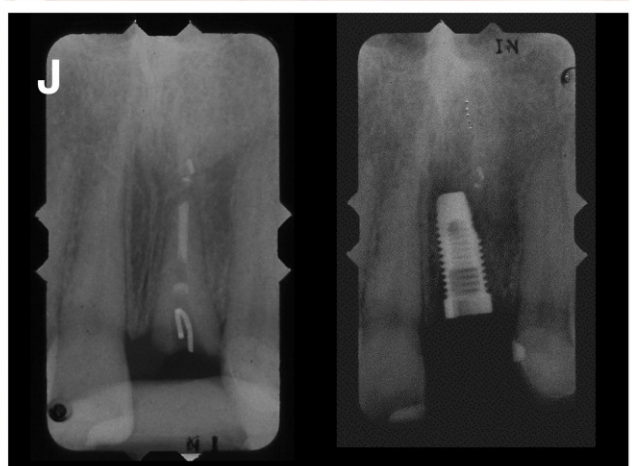
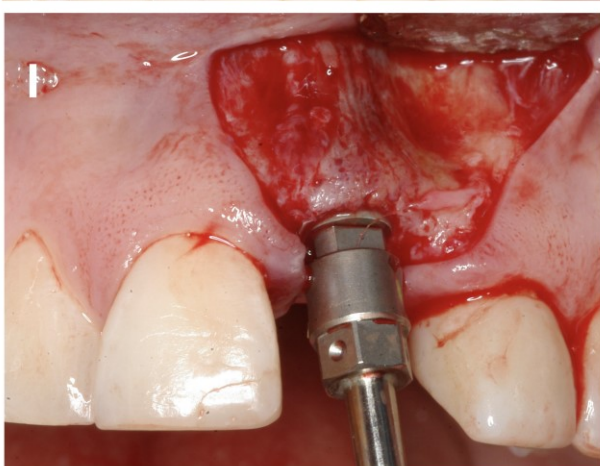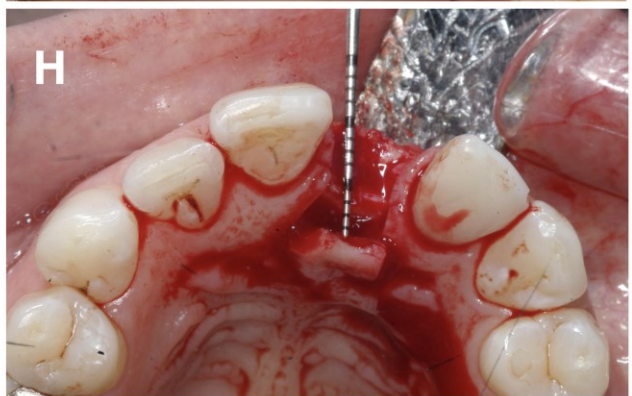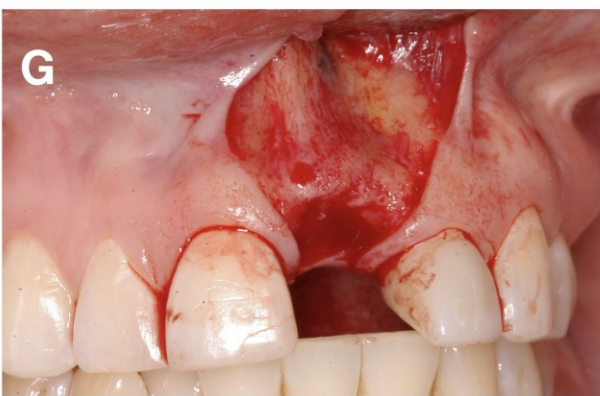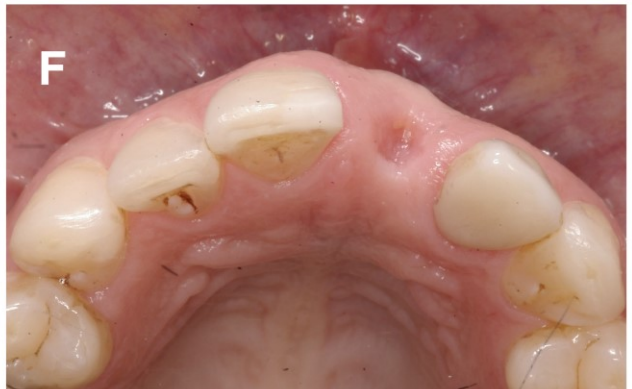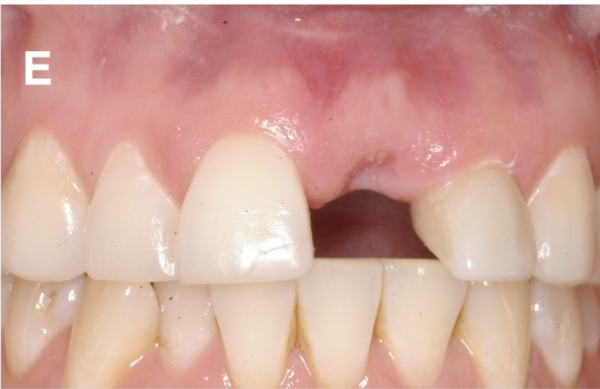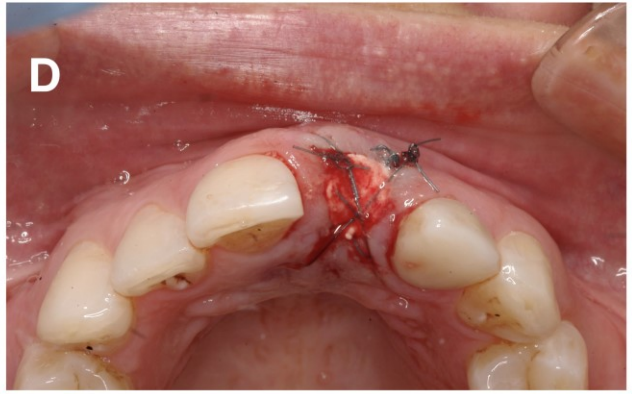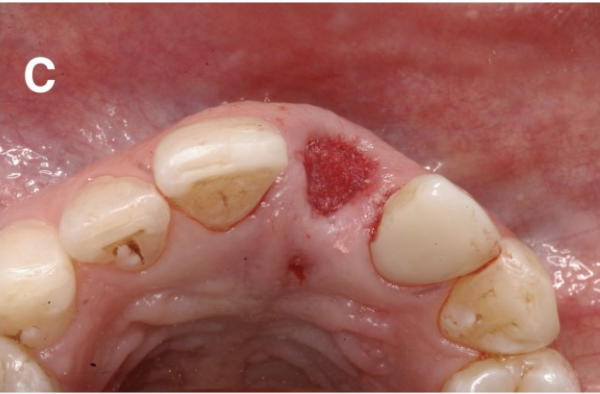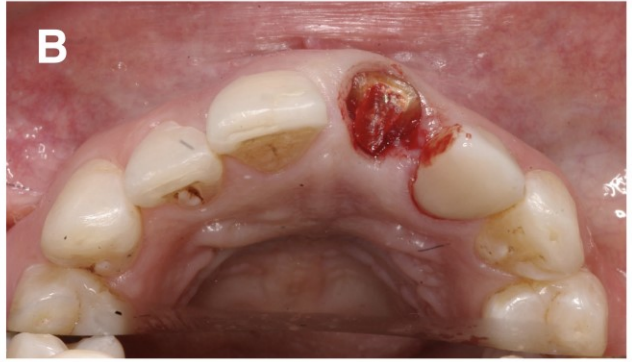
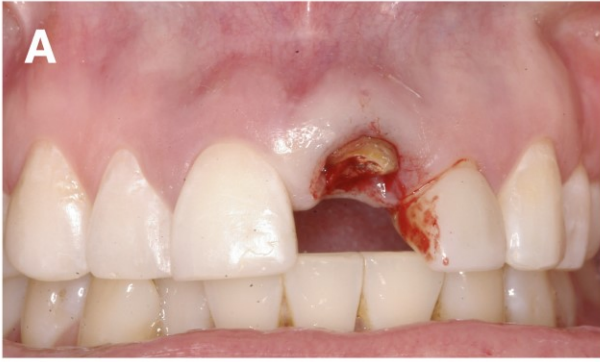**Figure 1a.** Flap procedure. **A.** Tooth site before extraction showing a premolar with vertical root fracture; **B.** Trapezoidal papilla preservation incisions buccally and lingually; **C.** Tooth extracted and mineralized particulate allograft + demineralized bone matrix was packed to the bone crest; **D.** Criss-cross sutures placed over the bone graft in both groups to provide retention for the calcium sulfate barrier; **E, F.** Healed site 4 month after ARP; **G.** Trapezoidal papilla preservation incisions buccally and lingually to facilitate clinical measurements, **H.** A tissue-level implant placed in a single stage approach; **I, J.** Pre and Post Periapical radiographs.

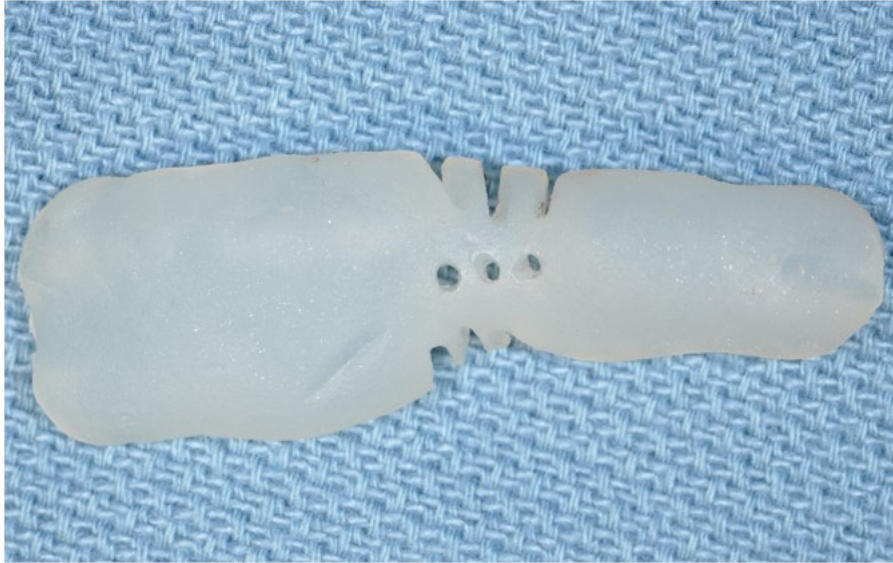




**Figure 1b.** Flapless procedure. **A, B.** Tooth site before extraction; **C.** Tooth extracted and mineralized particulate allograft + demineralized bone matrix was packed filling the socket to the bone crest; **D.** Criss-cross sutures placed over the bone graft in both groups to provide retention for the calcium sulfate barrier; **E, F.** Healed site 4 month after ARP; **G.** Trapezoidal papilla preservation incisions buccally and lingually; **H.** Horizontal ridge width demonstrated clinically after 4 months (note that the measurements were taken using a digital caliper); **I,** Implant placement showing adequate buccal bone. **J.** Pre and Post Periapical radiographs.

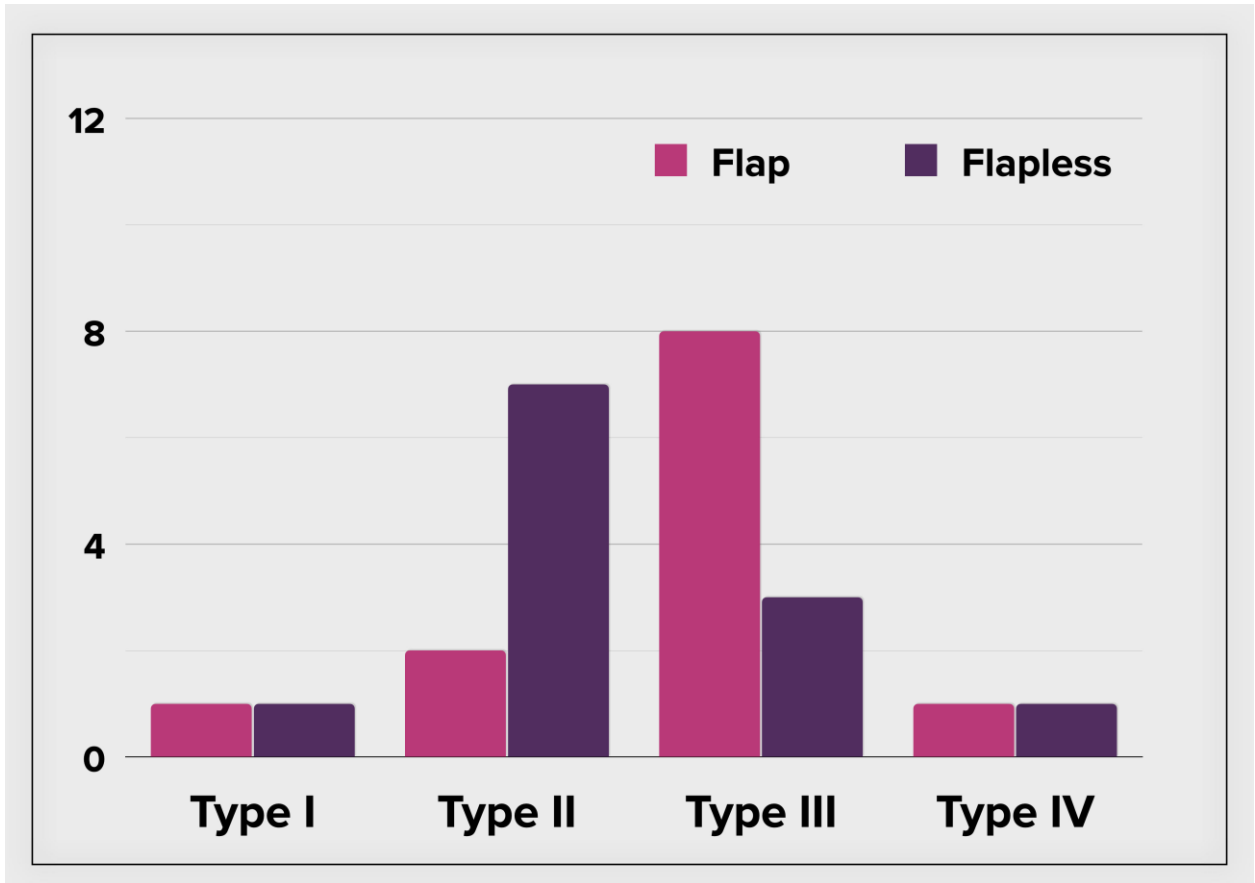
Author Manuscript





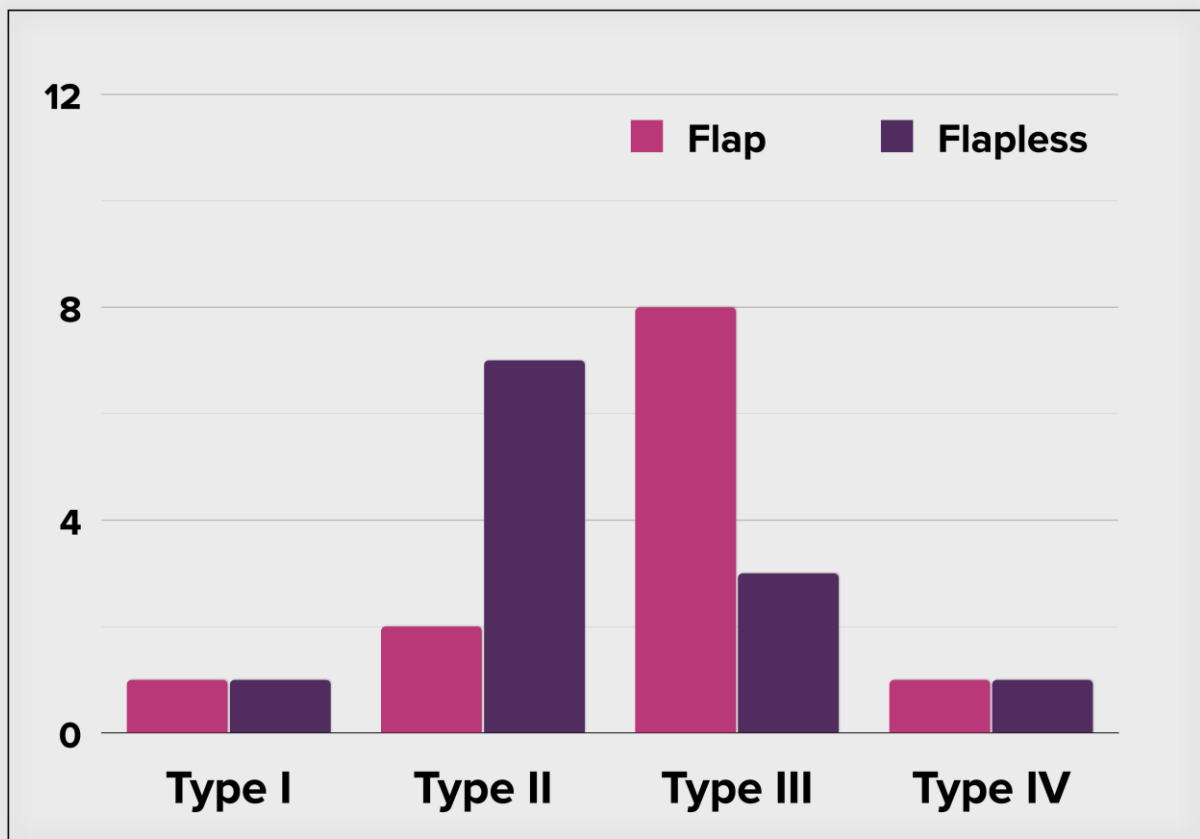
**Figure 2.** Custom surgical stent was fabricated before each case. Channels in these stents guide the North Carolina periodontal probe placement for intra-surgical and re-entry measurements.

Author Manuscript



**Figure 3.** Bone quality as subjectively assessed as Type I through IV for both flap and flapless techniques based on the Lekholm and Zarb classification.<sup>21</sup>

Author



Author M

#### REFERENCES

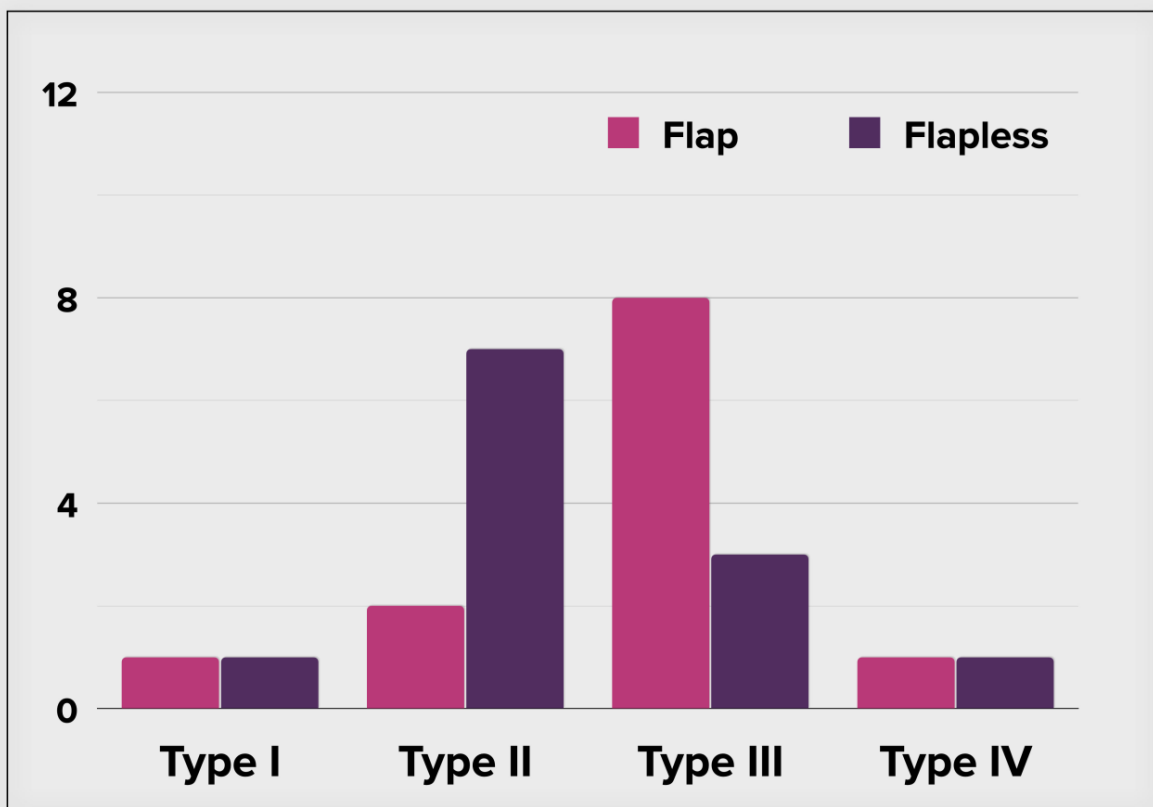
1. Araujo MG, da Silva JCC, de Mendonca AF, Lindhe J. Ridge alterations following grafting of fresh extraction sockets in man. A randomized clinical trial. *Clin Oral Implants Res* 2015;26:407-412.
2. Van der Weijden F, Dell'Acqua F, Slot DE. Alveolar bone dimensional changes of post-extraction sockets in humans: a systematic review. *J Clin Periodontol* 2009;36:1048-1058.
3. Avila-Ortiz G, Chambrone L, Vignoletti F. Effect of alveolar ridge preservation interventions following tooth extraction: A systematic review and meta-analysis. *J Clin Periodontol* 2019;46 Suppl 21:195-223.

4. Avila-Ortiz G, Elangovan S, Kramer KW, Blanchette D, Dawson DV. Effect of alveolar ridge preservation after tooth extraction: a systematic review and meta-analysis. *J Dent Res* 2014;93:950-958.
5. Vignoletti F, Matesanz P, Rodrigo D, Figuero E, Martin C, Sanz M. Surgical protocols for ridge preservation after tooth extraction. A systematic review. *Clin Oral Implants Res* 2012;23 Suppl 5:22-38.
6. Wilderman M. Exposure of bone in periodontal surgery. *Dent Clin North Am* 1964; 8:23-35.
7. Wood DL, Hoag PM, Donnenfeld OW, Rosenfeld LD. Alveolar crest reduction following full and partial thickness flaps. *J Periodontol* 1972;43:141-144.
8. Saleh MHA, Couso-Queiruga E, Ravida A, et al. Impact of the periodontal phenotype in premolar and molar sites on bone loss following full thickness mucoperiosteal flap. A 1-year prospective clinical trial. *J Periodontol* 2022.2022 Feb 8 doi: 10.1002/JPER.21-0591. Online ahead of print.
9. Araujo MG, Lindhe J. Ridge alterations following tooth extraction with and without flap elevation: an experimental study in the dog. *Clin Oral Implants Res* 2009;20:545-549.
10. Fickl S, Kepschull M, Schupbach P, Zuhr O, Schlagenhauf U, Hürzeler MB. Bone loss after full-thickness and partial-thickness flap elevation. *J Clin Periodontol* 2011;38:157-162.
11. Barone A, Borgia V, Covani U, Ricci M, Piattelli A, Iezzi G. Flap versus flapless procedure for ridge preservation in alveolar extraction sockets: a histological evaluation in a randomized clinical trial. *Clin Oral Implants Res* 2015;26:806-813.
12. Barone A, Toti P, Piattelli A, Iezzi G, Derchi G, Covani U. Extraction socket healing in humans after ridge preservation techniques: comparison between flapless and flapped procedures in a randomized clinical trial. *J Periodontol* 2014;85:14-23.
13. Fickl S, Zuhr O, Wachtel H, Bolz W, Hürzeler M. Tissue alterations after tooth extraction with and without surgical trauma: a volumetric study in the beagle dog. *J Clin Periodontol* 2008;35:356-363.
14. Hammerle CH, Araujo MG, Simion M, G. Evidence-based knowledge on the biology and treatment of extraction sockets. *Clin Oral Implants Res* 2012;23 Suppl 5:80-82.
15. Moher D, Hopewell S, Schulz KF, et al. CONSORT 2010 Explanation and Elaboration: Updated guidelines for reporting parallel group randomised trials. *J Clin Epidemiol* 2010;63:e1-37.
16. Laster L, Laudenbach KW, Stoller NH. An evaluation of clinical tooth mobility measurements. *J Periodontol* 1975;46:603-607.

17. Loe H. The Gingival Index, the Plaque Index and the Retention Index Systems. *J Periodontol* 1967;38:Suppl:610-616.
18. Silness J, Loe H. Periodontal disease in pregnancy. Ii. Correlation between oral hygiene and periodontal condtion. *Acta Odontol Scand* 1964;22:121-135.
19. Iasella JM, Greenwell H, Miller RL, et al. Ridge preservation with freeze-dried bone allograft and a collagen membrane compared to extraction alone for implant site development: a clinical and histologic study in humans. *J Periodontol* 2003;74:990-999.
20. Vance GS, Greenwell H, Miller RL, Hill M, Johnston H, Scheetz JP. Comparison of an allograft in an experimental putty carrier and a bovine-derived xenograft used in ridge preservation: a clinical and histologic study in humans. *Int J Oral Maxillofac Implants* 2004;19:491-497.
21. Lekholm U, Zarb G. Patient selection and preparation. In: Branemark P-I, Zarb G, Albrektsson T, eds. *Tissue integrated prostheses: Osseointegration in clinical dentistry*, 1985:199-209.
22. Blanco J, Nunez V, Aracil L, Munoz F, Ramos I. Ridge alterations following immediate implant placement in the dog: flap versus flapless surgery. *J Clin Periodontol* 2008;35:640-648.
23. Caneva M, Botticelli D, Salata LA, Souza SL, Bressan E, Lang NP. Flap vs. "flapless" surgical approach at immediate implants: a histomorphometric study in dogs. *Clin Oral Implants Res* 2010;21:1314-1319.
24. Wang F, Huang W, Zhang Z, Wang H, Monje A, Wu Y. Minimally invasive flapless vs. flapped approach for single implant placement: a 2-year randomized controlled clinical trial. *Clin Oral Implants Res* 2017;28:757-764.
25. Filipek D, Koszowski R, Smieszek-Wilczewska J. A comparative clinical study on human tooth extractions: flap vs flapless buccal surgery. *Quintessence Int* 2012;43:887-889.
26. Misawa M, Lindhe J, Araujo MG. The alveolar process following single-tooth extraction: a study of maxillary incisor and premolar sites in man. *Clin Oral Implants Res* 2016;27:884-889.
27. Chappuis V, Engel O, Reyes M, Shahim K, Nolte LP, Buser D. Ridge alterations post-extraction in the esthetic zone: a 3D analysis with CBCT. *J Dent Res* 2013;92:195S-201S.
28. Braut V, Bornstein MM, Belser U, Buser D. Thickness of the anterior maxillary facial bone wall-a retrospective radiographic study using cone beam computed tomography. *Int J Periodontics Restorative Dent* 2011;31:125-131.

29. Januario AL, Duarte WR, Barriviera M, Mesti JC, Araujo MG, Lindhe J. Dimension of the facial bone wall in the anterior maxilla: a cone-beam computed tomography study. *Clin Oral Implants Res* 2011;22:1168-1171.
30. Vera C, De Kok IJ, Reinhold D, et al. Evaluation of buccal alveolar bone dimension of maxillary anterior and premolar teeth: a cone beam computed tomography investigation. *Int J Oral Maxillofac Implants* 2012;27:1514-1519.
31. Atieh MA, Alfardan L, Alsabeeha NHM. Flapped versus flapless alveolar ridge preservation: a systematic review and meta-analysis. *Int J Oral Maxillofac Surg* 2022;51:133-142.
32. Chen ST, Darby I. The relationship between facial bone wall defects and dimensional alterations of the ridge following flapless tooth extraction in the anterior maxilla. *Clin Oral Implants Res* 2017;28:931-937.
33. Schropp L, Wenzel A, Kostopoulos L, Karring T. Bone healing and soft tissue contour changes following single-tooth extraction: a clinical and radiographic 12-month prospective study. *Int J Periodontics Restorative Dent* 2003;23:313-323.





†† Microsoft Excel for Windows version 16.0, Microsoft Corporation, Redmond, WA, USA

¶ Grafton Matrix Plug™, BioHorizons, Birmingham, AL

© MinerOss®, BioHorizons, Birmingham, AL

\*\* CalForma®, Lifecore Biomedical, Inc, Chaska, MN

†† Maxon™, Kendall Healthcare, Mansfield, MA

‡‡ SDM® gingival thickness meter (Austenal Medizintechnik, Cologne, Germany)

§§ Mitutoyo™, Tokyo, Japan

|| American Optics® light microscope, NY, USA

¶¶ Nikon®, Tokyo, Japan

### Microsoft Excel for Windows version 16.0, Microsoft Corporation, Redmond, WA, USA

### Figure Legends

---

**Figure 1a.** Flap procedure. **A.** Tooth site before extraction showing a premolar with vertical root fracture; **B.** Trapezoidal papilla preservation incisions buccally and lingually; **C.** Tooth extracted and mineralized particulate allograft + demineralized bone matrix was packed to the bone crest; **D.** Criss-cross sutures placed over the bone graft in both groups to provide retention for the calcium sulfate barrier; **E, F.** Healed site 4 month after ARP; **G.** Trapezoidal papilla preservation incisions buccally and lingually to facilitate clinical measurements, **H.** A tissue-level implant placed in a single stage approach; **I, J.** Pre and Post Periapical radiographs.

**Figure 1b.** Flapless procedure. **A, B.** Tooth site before extraction; **C.** Tooth extracted and mineralized particulate allograft + demineralized bone matrix was packed filling the socket to the bone crest; **D.** Criss-cross sutures placed over the bone graft in both groups to provide retention for the calcium sulfate barrier; **E, F.** Healed site 4 month after ARP; **G.** Trapezoidal papilla preservation incisions buccally and lingually; **H.** Horizontal ridge width demonstrated clinically after 4 months (note that the measurements were taken using a digital caliper); **I.** Implant placement showing adequate buccal bone. **J.** Pre and Post Periapical radiographs.

**Figure 2.** Custom surgical stent was fabricated before each case. Channels in these stents guide the North Carolina periodontal probe placement for intra-surgical and re-entry measurements.

**Figure 3.** Bone quality as subjectively assessed as Type I through IV for both flap and flapless techniques based on the Lekholm and Zarb classification.<sup>21</sup>

**Supplementary Figure 1.** Representative histological observations 4 months after ridge preservation surgery. **A.** Vital bone- Flapless group, Hematoxylin and eosin stain; **B.** non-vital residual (acellular) bone, probably allograft, encapsulated in fibrous connective tissue- Flap group, Hematoxylin and eosin stain; **C.** Vital woven bone (cellular)- Flap group, Toluidine blue

---

## **Table Legends**

**Table 1:** Study design flowchart.

**Table 2:** a: Horizontal crestal ridge width changes for both flap and flapless sites (Mean  $\pm$  SD). b:

Vertical ridge height change for flap and flapless sites (Mean  $\pm$  SD). c. Soft tissue thickness changes (in mm) for flap and flapless sites (Mean  $\pm$  SD).

**Table 3:** Histological data at implant placement for flap and flapless sites (Mean percentage  $\pm$  SD).

**Consort form:** The CONSORT 2010 (Consolidated Standards Of Reporting Trials) checklist.

Author Manuscript