



ORIGINAL ARTICLE

Metastatic prostate cancer diagnosed by fine-needle aspiration: Contemporary cytopathologic and biomarker assessment with clinical correlates

Richard L. Cantley MD¹  | Xiaoming Wang PhD^{1,2} | Zachery R. Reichert MD, PhD^{3,4} | Arul M. Chinnaiyan MD, PhD^{2,3,5} | Rahul Mannan MD^{1,2} | Xuhong Cao MS^{1,2} | Daniel E. Spratt MD⁶ | Ulka N. Vaishampayan MBBS^{3,4} | Joshi J. Alumkal MD^{3,4} | Todd M. Morgan MD^{3,7} | Ganesh Palapattu MD^{3,7,8} | Matthew S. Davenport MD^{7,9} | Liron Pantanowitz MD, PhD, MHA¹  | Rohit Mehra MD^{1,3}

¹Department of Pathology, University of Michigan Medical School, Ann Arbor, Michigan, USA

²Michigan Center for Translational Pathology, Ann Arbor, Michigan, USA

³Rogel Cancer Center, Michigan Medicine, Ann Arbor, Michigan, USA

⁴Department of Internal Medicine, University of Michigan, Ann Arbor, Michigan, USA

⁵Howard Hughes Medical Institute, Ann Arbor, Michigan, USA

⁶Department of Radiation Oncology, University Hospitals Seidman Cancer Center, Case Western Reserve University, Cleveland, Ohio, USA

⁷Department of Urology, University of Michigan Medical School, Ann Arbor, Michigan, USA

⁸Department of Urology, Medical University of Vienna, Vienna, Austria

⁹Department of Radiology, University of Michigan Medical School, Ann Arbor, Michigan, USA

Correspondence

Rohit Mehra, Department of Pathology, Michigan Medicine, University of Michigan, 2800 Plymouth Rd, Building 35 Ann Arbor, MI 48109, USA.
Email: mrohiti@med.umich.edu

Abstract

Introduction: The diagnosis of metastatic prostatic cancer (MPC) by fine needle aspiration (FNA) can usually be rendered by typical cytomorphologic and immunohistochemical (IHC) features. However, MPC diagnosis may be complicated by transformation to atypical phenotypes such as small cell carcinoma, typically under pressure from androgen deprivation therapy (ADT). Predictive and prognostic biomarkers can also be assessed by IHC. This study illustrates how careful assessment of cytologic and biomarker features may provide therapeutic and prognostic information in MPC.

Design: We reviewed our anatomic pathology archives for MPC diagnosed by FNA from January 2014 to June 2021. Clinical histories, cytology slides, and cell blocks were reviewed. Extensive IHC biomarker workup was performed, including markers of prostate lineage, cell-cycle dysfunction, Ki-67, neuroendocrine markers, PDL1, and androgen receptor splice variant 7. Cases were reclassified into three categories: conventional type, intermediary type, and high-grade neuroendocrine carcinoma (HGNC).

Results: Eighteen patients were identified. Twelve had conventional MPC, including six of six ADT-naive patients. Six of twelve (50%) with prior ADT were reclassified as intermediary or HGNC. Four intermediary cases included two with squamous differentiation and two with pro-proliferative features. Two HGNC cases had typical small cell carcinoma cytomorphology. Expression of PDL1 was identified in two cases and ARv7 in three cases. Five of five intermediary

Liron Pantanowitz and Rohit Mehra contributed equally to this study.

This is an open access article under the terms of the Creative Commons Attribution-NonCommercial License, which permits use, distribution and reproduction in any medium, provided the original work is properly cited and is not used for commercial purposes.

© 2022 The Authors. Cancer Cytopathology published by Wiley Periodicals LLC on behalf of American Cancer Society.

Funding information

Michigan Prostate SPORE, Grant/Award
Number: P50CA186786; EDRN, Grant/Award
Number: U01CA214170

and HGNC patients died of disease versus six of eleven with with conventional type.

Conclusions: Aggressive cytomorphologic variants were commonly identified in patients with prior ADT. Identification of nonconventional cytomorphology and increased proliferation can provide important prognostic information. Recognition of these changes is important for an accurate diagnosis, and the identification of high-grade variants can affect therapeutic decision-making. Clinically actionable biomarkers such as PDL1 and ARv7 can be assessed by IHC.

KEYWORDS

androgen receptor (AR), cytopathology, fine needle aspiration, neuroendocrine, prostate cancer, small cell carcinoma, transdifferentiation

INTRODUCTION

Prostate cancer is the third most diagnosed malignancy worldwide, with approximately 270,000 new cases and 34,500 deaths annually in the United States.¹ Initial therapy for newly diagnosed primary prostatic adenocarcinoma or prostate cancer is based primarily on clinical stage, pathologic grade, prostate-specific antigen (PSA) levels, and life expectancy. Most patients have localized disease at the time of initial diagnosis, but more advanced disease is present in 15% to 20% of patients.^{1,2} Patients with carcinoma confined to the prostate are typically treated with either radical prostatectomy or definitive radiotherapy. Active surveillance is also an option for those afflicted with low-risk disease or reduced life expectancy.³ For patients with distant metastatic disease, androgen deprivation therapy (ADT) continues to be a mainstay of therapy.⁴⁻⁶

Metastatic prostate cancer can be readily diagnosed by fine-needle aspiration (FNA).⁷ The diagnosis of metastatic prostate cancer (MPC) is relatively straightforward for conventional or acinar MPC. Morphologically, tumor cells are present in crowded, three-dimensional groups of cells with indistinct cell borders. Nuclei are usually round and uniform, with easily identified single central prominent nucleoli. Acinar arrangements of tumor cells can be appreciated, both within larger groups and as individual follicle-like structures.^{8,9} The unique immunohistochemical profile of prostate cancer (PC) aids the FNA diagnosis when needed. Conventional forms of PC usually express PSA, prostate-specific membrane antigen (PSMA), NK3 Homeobox1 (NKX3.1), and androgen receptor (AR). Erythroblast transformation-specific-related gene protein (ERG) rearrangements are common early in prostate cancer development and can be detected with high sensitivity and specificity by immunohistochemistry (IHC).^{8,9}

Although conventional forms of PC are relatively easy to diagnose on FNA, metastatic disease may display variant morphology which can complicate the diagnosis. Such variant morphology may exhibit uncommon histologic variants of PC (e.g., ductal, squamous cell) or morphologic phenotypes (pro-proliferative, neuroendocrine

reflective of lineage plasticity developing as a manifestation of therapeutic pressure and/or treatment resistance.¹⁰⁻¹² Pro-proliferative and other variant forms of MPC may lack the acinar morphology of conventional PC, and exhibit necrosis and high mitotic activity. Transformation to nonacinar forms, including small cell carcinoma and squamous cell carcinoma, can be seen.¹⁰⁻¹⁴

AR plays a critical role in the development and ultimate metastatic progression of PC.¹⁵⁻¹⁷ AR is a hormone ligand-dependent transcription factor that regulates cell-cycle progression in prostate origin tissue and induces transcription of prostate-specific genes, including PSA and NKX3.1.

ADT is a mainstay of treatment for PC patients presenting with metastatic disease, who develop metastatic disease, or may have other high-risk factors.⁶ Conventional ADT include luteinizing hormone-releasing hormone receptor agonists (e.g., leuporelin) and nonsteroidal antiandrogens (e.g., bicalutamide).^{5,18} More recently, novel androgen receptor signaling inhibitor therapies have shown improvement in disease-free survival in PC. Examples include abiraterone, which directly blocks androgen production from all sources, and enzalutamide, which directly sequesters AR and blocks nuclear translocation.

Despite improved disease-free survival, most patients receiving ADT eventually develop castrate-resistant prostate cancer (CRPC).^{19,20} Early castrate resistance often develops through reactivation of AR signaling, such as the constitutive activation that occurs through the AR splice variant ARv7.¹⁷ Eventually, PC can acquire additional alterations that lead to "androgen indifference," such as PI3K/AKT pathway mutations.²¹ Androgen indifference, in turn, may be associated with lineage plasticity and pro-proliferative features. Androgen-indifferent PC include those with overlapping conventional acinar morphology and neuroendocrine features. CRPC can also differentiate to nonacinar, nonneuroendocrine phenotypes, such as squamous cell carcinoma. Ultimately, PC can become hormone refractory. Such cancers may exhibit complete loss of acinar morphology, loss of prostate-lineage marker (PLM) expression, and Ki-67 elevation. Many of these cases exhibit neuroendocrine marker

expression and typical cytologic features of high-grade neuroendocrine carcinoma (HGNC).¹² Androgen-refractory PC, lacking neuroendocrine differentiation (“double-negative” PC), may also develop through alternate pathways, such as fibroblastic growth factor pathway.¹²

After an androgen deprivation refractory state develops in CRPC, nonhormonal chemotherapeutics are preferred and may still be effective for HGNC and “double negative” MPC. Taxane chemotherapies (docetaxel and cabazitaxel) are mainstays for conventional PC, and they are used in combination with platinum-based chemotherapy (e.g., cisplatin) for HGNC.⁶

Cytomorphology and immunohistochemical features of MPC diagnosed by FNA can provide important prognostic and predictive information. The presence of nonacinar phenotypes, especially small cell carcinoma, are associated with poor prognosis.²² Identifying HGNC transformation in MPC is important because alternate therapies (e.g., cisplatin) are considered. Immunohistochemical stains for retinoblastoma (RB), phosphatase and tensin homolog (PTEN), and ARV7 may provide further prognostic implications, helping to identify high-risk cases.^{23,24} Ki-67 labeling index is typically <10% in conventional MPC.²⁵ However, Ki-67 index may be significantly elevated in prostate cancer with pro-proliferative, neuroendocrine transformation, or small cell phenotype. Expression of Programmed Death Ligand 1 (PDL1), an important predictive marker involved in immune evasion by carcinomas, has also been identified in a subset of MPC and can be targeted with the monoclonal antibody therapy pembrolizumab via compassionate use. PDL1 immunohistochemistry is

considered positive when any specific (>1%) expression is seen.^{26,27} Finally, ERG expression is highly specific for MPC and hence of diagnostic utility and may also serve as a potential predictive marker for docetaxel response.²⁸

In this study, we retrospectively reviewed cases of MPC diagnosed by FNA and correlated the findings with clinicopathologic features and contemporary prostate cancer therapies including CRPC. Cases were specifically evaluated for variant morphologies or other pro-proliferative features and the impact of prior therapy on pathologic features and clinical outcome. Finally, we investigated the feasibility of several novel prognostic and predictive biomarkers in FNA material of MPC.

METHODS AND MATERIALS

Patient Selection

This study was performed under institutional review board-approved protocols (with a waiver of informed consent). We searched our anatomic pathology archives for a period of 7.5 years (January 1, 2014–June 30, 2021) for FNA cases flagged as malignant with “prostate” or “prostatic” in the diagnostic line or comment section. We identified a total of 19 FNA cytology cases from 18 patients. FNAs were performed under endobronchial ultrasound-guidance in seven cases, ultrasound-guidance in six cases, and computer tomographic guidance in six cases. In all cases, cell block

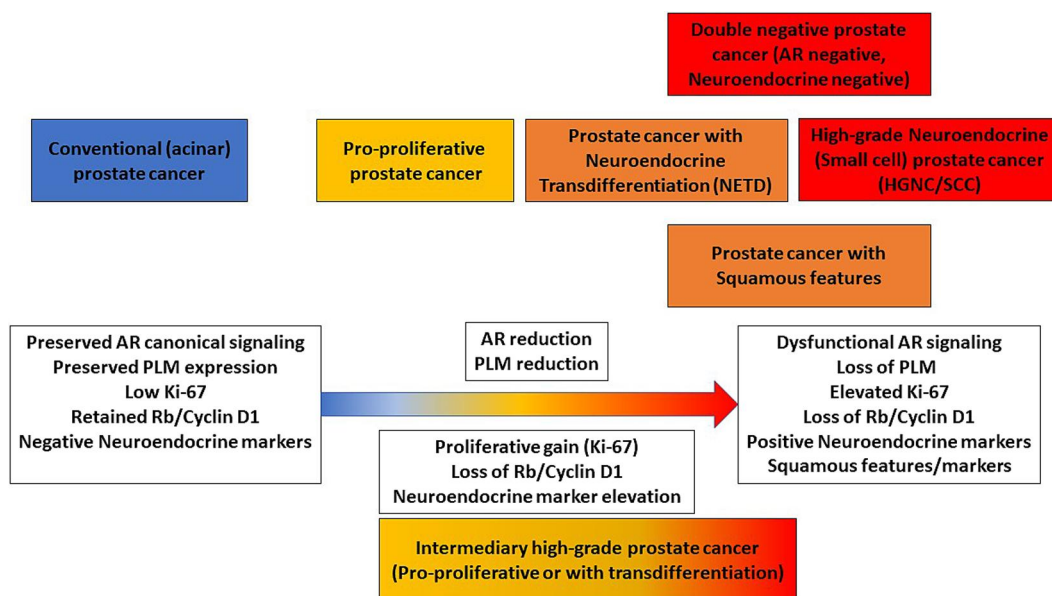


FIGURE 1 Schematic of prostate cancer progression. Conventional prostate cancer exhibits acinar architecture with canonical androgen receptor signaling and prostate lineage marker expression. However, prostate cancer can undergo progression to pro-proliferative or transdifferentiated (neuroendocrine and/or squamous) states, under therapeutic pressure or de novo, and then exhibit reduced prostate lineage marker expression, reduced dependence on androgen signaling, and increased proliferation. Prostate cancer can ultimately develop full progression to high-grade neuroendocrine carcinoma, with elevated proliferation and neuroendocrine markers, a dysfunctional AR pathway, and loss of RB and Cyclin D1. AR indicates androgen receptor; RB, retinoblastoma

TABLE 1 Clinical histories and radiographic findings in patients with metastatic prostate cancer

Patient	Age (years) at FNA	History of prostate cancer?	Years since prostate cancer diagnosis	Prior metastatic disease	Serum PSA at FNA (ng/ml)	Bone metastases ^a	Soft tissue metastases ^a	Site of FNA
1	65	No	0	-	Not performed	Axial skeleton	Widespread lymph nodes	Lymph node - left cervical
2	88	No	0	-	Not performed	Axial skeleton	Mediastinal lymph nodes	Bone - left sacrum
3	64	No	0	-	15.8	Isolated rib metastasis	Iliac lymphadenopathy	Bone - rib
4	67	No	0	-	36.5	Axial skeleton	Iliac lymphadenopathy	Bone - right sacrum
5	74	Yes	9	Yes (bone)	115.4	Axial skeleton	Mediastinal lymph nodes	Lymph nodes - mediastinal
6	67	Yes	11	No	4.1	None	Retropertitoneal lymph nodes	Lymph node - retroperitoneal
7	66	Yes	16	No	6.2	None	Retropertitoneal lymph nodes	Lymph node - retroperitoneal
8	67	Yes	12	Yes (bone)	Not performed	Axial skeleton	Cervical and supraclavicular lymph nodes	Lymph node - left cervical
9	67	Yes	5	No	0.6	None	Abdominal soft tissue	Soft tissue - abdominal
10	73	Yes	14	Yes (iliac lymph nodes)	4.1	None	Mediastinal lymph nodes	Lymph node - mediastinal
11	75	Yes	10	Yes (bone)	2.7	Widespread bone metastases	Widespread lymph nodes	Lymph node - left supraclavicular
12	68	Yes	7	No	1.2	None	Mediastinal lymph nodes	Lymph node - mediastinal
13	58	Yes	1	Yes (bone)	0.9	Widespread bone metastases	None	Bone - left femur
14	71	Yes	9	No	2.0	Isolated rib metastasis	Mediastinal lymph nodes	Lymph node - mediastinal
15	85	Yes	21	No	115.6	Axial skeleton and humerus	Mediastinal lymph nodes	Lymph node - subcarinal
16	80	Yes	11	No	24.5	None	Mediastinal lymph nodes	Lymph node - mediastinal
17	53	Yes	6	No	Not performed	None	Widespread lymph nodes, lung, pelvic mass	Lymph node - left cervical
18	65	Yes	10	Yes (bone)	463.4	Widespread bone metastases	Widespread lymph nodes	Lymph node - left cervical

Abbreviations: FNA, fine-needle aspiration; PSA, prostate-specific antigen.

^aBased on radiographic evidence of disease at time of FNA.

TABLE 2 Prostate cancer therapy history in patients with metastatic prostate cancer

Patient	Category	Prostatectomy	RT	Androgen deprivation therapy	Abiraterone	Enzalutamide	Docetaxel	Cisplatin
5	Conventional	Yes	Yes, prostate-bed RT	No	Yes	Yes	Yes	No
6	Conventional	No	Yes, definitive RT	No	No	No	No	No
7	Conventional	Yes	Yes, prostate-bed RT	Leuprorelin	No	No	No	No
8	Conventional	Yes	Yes, prostate-bed RT	Leuprorelin and Bicalutamide	No	No	No	No
9	Conventional	Yes	Yes, prostate-bed RT	No	No	No	No	No
10	Conventional	Yes	No	Leuprorelin	No	No	No	No
11	Conventional	Yes	Yes, prostate-bed RT	Leuprorelin	Yes	No	No	No
12	Conventional	Yes	No	Leuprorelin	Yes	No	No	No
13	Intermediary	No	Yes, bone metastasis RT	Leuprorelin	No	No	Yes	No
14	Intermediary	No	Yes, definitive RT	Leuprorelin and Bicalutamide	No	No	No	No
15	Intermediary	No	Yes, definitive RT	Leuprorelin	No	No	No	No
16	Intermediary	No	Yes, definitive RT	Leuprorelin and Bicalutamide	No	No	No	No
17	High-grade neuroendocrine carcinoma	Yes	No	Leuprorelin and Bicalutamide	No	No	No	No
18	High-grade neuroendocrine carcinoma	Yes	No	Leuprorelin	Yes	Yes	No	No

Note: Patients 1-4 were therapy-naive (no history of prostate cancer) with conventional metastatic prostate cancer. Abbreviation: RT, radiation therapy.

and hematoxylin and eosin–stained slides were prepared. Cytologic material was prepared as either Diff-Quik and Papanicolaou-stained smear slides (15 cases) or one liquid-based cytology (ThinPrep) slide (four cases). All slides, including cytology, cell block, and immunohistochemical stains were retrieved from the study cases identified. All cytologic material and patient clinical histories were reviewed by two study pathologists with expertise in cytopathology and genitourinary pathology (R.C., R.Mehra) to confirm the diagnosis of MPC and to assess the cytomorphologic features of the cases in this cohort. Prostate cancer histories were reviewed, including prior prostate surgical pathology material and prior metastatic disease. When available, prior surgical pathology and cytopathology material was rereviewed. Therapeutic records were obtained, including history of definitive or salvage radiation, chemotherapy, and ADT, including second-generation agents such as abiraterone and enzalutamide.

Immunohistochemistry

To further categorize study cases and assess for prognostic and predictive markers, immunohistochemical stains were performed on archived formalin-fixed, paraffin-embedded cell block material. Stains were performed using antibodies against NKX3.1 (BioCare CP42213), PSMA (Dako M3620), PSA (Ventana 760-2506), AR (Ventana 760-4605), synaptophysin (Ventana 790-4407), chromogranin (Ventana 760-2519), Ki-67 (Ventana 790-4286), PTEN (Cell Signaling 9188), ERG (Ventana 790-4576), PDL1 (Spring Biosciences M4420), RB protein (Cell Signaling 9309), cyclin D1 (Cell Marque 241R-18), and androgen receptor variant 7 (ARv7 RevMAb Biosciences 31-1109-00). IHC was performed on the Ventana Discovery XT automated slide staining system using an ultraView or OptiView DAB detection kit (Roche-Ventana, ZA). All cases were rereviewed and assessed for cytologic features, including the presence or

TABLE 3 Cytomorphologic findings in metastatic prostate cancer

Patient	Acinar morphology	Non-acinar morphology	Necrosis	Mitotic activity	Category
1	Present	Absent	Present	Absent	Conventional
2	Present	Absent	Absent	Absent	Conventional
3	Present	Absent	Absent	Absent	Conventional
4	Present	Absent	Absent	Absent	Conventional
5A	Present	Absent	Absent	Absent	Conventional
5B	Present	Absent	Absent	Absent	Conventional
6	Present	Absent	Absent	Absent	Conventional
7	Present	Absent	Absent	Absent	Conventional
8	Present	Absent	Absent	Absent	Conventional
9	Present	Absent	Absent	Absent	Conventional
10	Present	Absent	Absent	Absent	Conventional
11	Present	Absent	Absent	Present	Conventional
12	Present	Absent	Absent	Absent	Conventional
13	Absent	Squamous cell carcinoma with keratinization	Present	Present	Intermediary
14	Present	Squamous cell carcinoma with keratinization	Present	Absent	Intermediary
15	Present	Solid growth with comedo necrosis	Present	Present	Intermediary
16	Present	Solid growth with neuroendocrine differentiation	Present	Absent	Intermediary
17	Absent	Small cell carcinoma	Present	Present	High-grade neuroendocrine carcinoma
18	Absent	Small cell carcinoma	Present	Present	High-grade neuroendocrine carcinoma

Note: Patient 5 underwent sampling of mediastinal sites twice in separate procedures.

absence of typical PC acinar morphology, solid tumor cell sheets, nonacinar morphology (e.g., small cell carcinoma, squamous cell carcinoma), mitoses, and necrosis.

Tumor Categorization

Based on our previous experience as well as published data reflecting PC tumor biology (Figure 1), cases of MPC were classified into three categories based on cytomorphologic and immunohistochemical features: conventional, intermediary, or HGNC.¹¹⁻¹³ Conventional cases were categorized by the presence of acinar morphology, retained expression of prostatic-specific markers, and absent neuroendocrine expression. Intermediary cases were categorized by the presence of either pro-proliferative features (i.e., Ki67 \geq 20% +/- neuroendocrine marker expression) or nonconventional prostatic morphology (e.g., squamous cell, ductal, sarcomatoid features). HGNC cases were categorized by morphologic and immunohistochemical features typical of small cell carcinoma and/or tumors exhibiting strong immunohistochemical expression of

neuroendocrine markers along with high Ki-67 labeling index, or loss of pathway markers Rb and Cyclin D1.

RESULTS

Clinical and Radiographic Features

We identified a total of 19 FNA cytology cases from 18 patients (Table 1). Patients ranged in age from 53 to 88 years. In 14 patients, there was a known history of PC, initially diagnosed from 1 to 21 years before FNA. In six (out of 14) patients, there was prior MPC diagnosed before the current FNA (five bone, one iliac lymph node). Four patients were de novo presentations of MPC.

All 14 patients with a prior diagnosis of PC had a documented history of prior therapy in the form of either surgical, radiotherapy, hormonal, or chemotherapy (Table 2). Of these, although nine (64%) patients had undergone prior prostatectomy, 10 (71%) patients had prior radiation therapy, including five (36%) with definitive radiation therapy and five (36%) with salvage radiation therapy. Twelve of 14

TABLE 4 Diagnostic immunohistochemistry in metastatic prostate cancer

Patient	Category	NKX3.1	PSMA	Androgen receptor	Synaptophysin	Chromogranin	Ki-67 labeling index
1	Conventional	+++	+++	+++	-	-	15%
2	Conventional	+++	+++	+++	-	-	5%
3	Conventional	+++	++	+++	-	-	5%
4	Conventional	+++	+	+++	-	-	2%
5A	Conventional	+++	+++	+++	-	-	5%
5B	Conventional	+++	+++	+++	-	-	5%
6	Conventional	++	+	+++	-	-	1%
7	Conventional	+++	+++	+++	-	-	2%
8	Conventional	+++	+	+++	-	-	5%
9	Conventional	+++	+++	+++	-	-	5%
10	Conventional	+++	++	+++	-	-	5%
11	Conventional	+++	+++	+++	-	-	5%
12	Conventional	+++	+++	+++	-	-	5%
13	Intermediary	-	+	-	-	-	10%
14	Intermediary	+++	+++	+++	-	-	20%
15	Intermediary	+++	+++	+++	-	-	60%
16	Intermediary	+++	+++	+++	++	+	20%
17	High-grade neuroendocrine carcinoma	-	+	-	-	-	60%
18	High-grade neuroendocrine carcinoma	+++	++	+++	+++	++	70%

Note: Immunohistochemical stain grading: +++, >50% expression; ++, 25-50% expression; +, <25% expression.

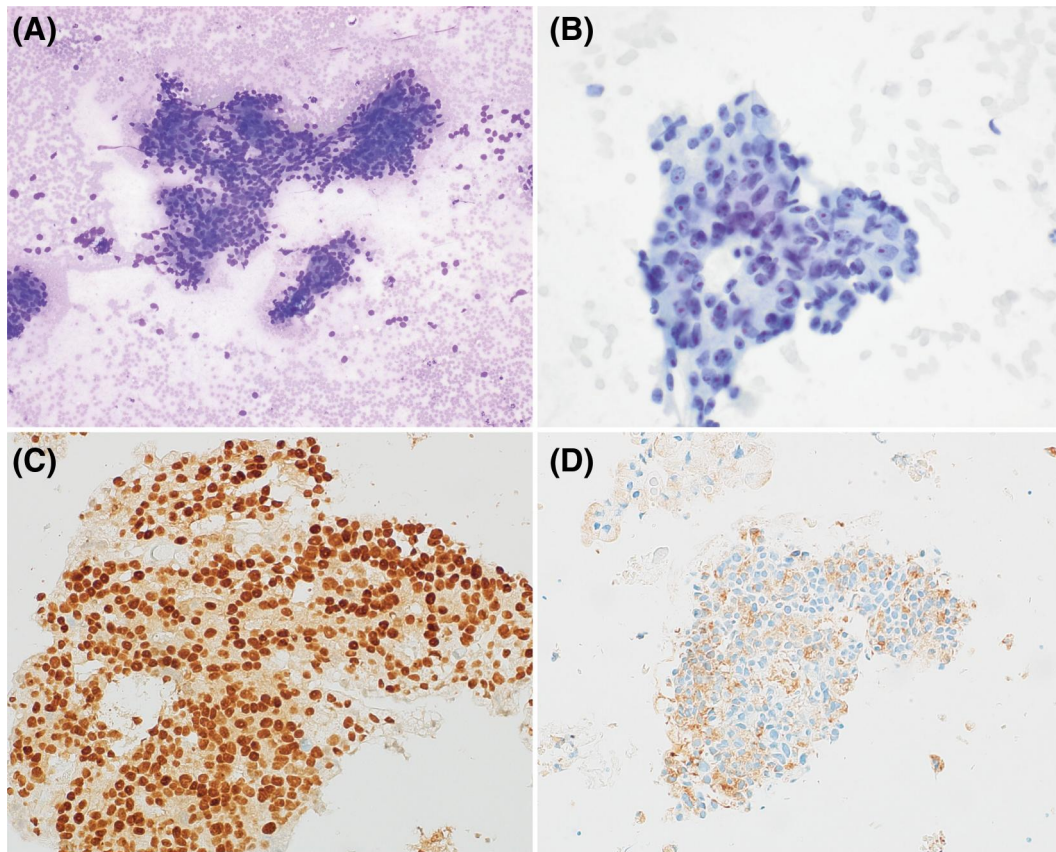


FIGURE 2 Conventional acinar prostatic adenocarcinoma metastatic to the sacrum in a therapy-naive patient (patient 2). Adenocarcinoma is present in cohesive acinar arrangements (A and B, smear slides, DiffQuik-stained 100 \times and Papanicolaou-stained, 200 \times). NKX3.1 (C) and PSMA (D) are diffusely expressed by immunohistochemical stain. PSMA indicates prostate-specific membrane antigen

(86%) patients received ADT, including four (29%) with combination of leuprorelin and bicalutamide, four (29%) leuprorelin alone, two (14%) with combination of leuprorelin and abiraterone, one (7%) with combination of leuprorelin, abiraterone, and enzalutamide; and one (7%) with combination of abiraterone and enzalutamide. Two (14%) patients received prior docetaxel therapy. None received cisplatin.

Eleven of 18 (61%) patients had radiologic evidence of bone metastatic disease at the time of FNA, including four (22%) with axial and appendicular metastases, five (28%) with axial metastases, and two (11%) with isolated rib metastases. Sixteen of 18 (89%) patients had lymph node involvement by radiographic imaging, including seven (39%) mediastinal lymphadenopathy, two (11%) iliac lymphadenopathy, two (11%) retroperitoneal lymphadenopathy, one (6%) with cervical lymphadenopathy, and four (22%) with multisystem lymphadenopathy. Two of 18 (11%) patients had soft-tissue metastatic disease on radiography, including one (6%) abdominal soft tissue and one (6%) with lung metastases and pelvic soft-tissue metastases. Nine of 18 (50%) patients had both bone and lymph node metastatic disease, including four of four (100%) patients without prior PC treatment and five of 14 (36%) with prior PC diagnosis and treatment. Among the four patients with a de novo diagnosis of MPC, four (100%) had axial bone involvement, whereas two (50%) had local and two (50%) had distal lymph node metastases.

Cytologic and Diagnostic Immunohistochemical Features

Among the 18 patients, 19 FNA sites were sampled: 14 lymph node (seven mediastinal, five left cervical or supraclavicular, two retroperitoneal), four bone (two sacrum, one femur, one rib), and one abdominal soft-tissue mass. One patient had sampling of different mediastinal lymph node sites in separate procedures. All other patients had only one FNA site sampled.

FNA cytology and cell block features were examined in all 19 cases (Table 3). Typical PC acinar morphology was observed in 16 (84%) cases and prominent nucleoli in 18 (95%) cases. Solid tumor sheets were seen in 10 (53%) cases. Mitotic activity was identified in five (26%) cases and tumor cell necrosis in seven (37%). Nonacinar morphologic variants were seen in five (26%) cases. Neuroendocrine differentiation reflective of small cell carcinoma features, including high nuclear to cytoplasmic ratios, fine chromatin, absence of prominent nucleoli, nuclear molding, and crush artifact, were seen extensively in two (11%) cases and focally in one (5%) case. Squamous differentiation with keratinization was seen extensively in one (5%) case and focally in one (5%) case.

In 17 (89%) cases, one or more PLM (NKX3.1, PSMA, and PSA) were strongly positive (>50% staining). Two (11%) cases had weak

focal positivity for PSMA and PSA but were negative for NKX3.1 and AR. Seventeen (89%) cases strongly expressed AR. Two (11%) cases expressed neuroendocrine markers (synaptophysin, chromogranin). Ki-67 labeling index ranged from 1% to 70%. Twelve (63%) had a labeling index of $\leq 5\%$. Five (26%) had labeling index of $\geq 20\%$ (Table 4).

Metastatic Prostatic Cancer Subcategorization

Based on cytomorphology and immunohistochemical features, cases of MPC were further subclassified into one of three categories: conventional type, intermediary type, or HGNC (Table 3).

There were 13 samples from 12 patients that were classified as conventional type (Figures 2 and 3). All cases had focal to diffuse acinar formation, and no variant morphologic forms of carcinoma were seen. PSMA and AR expression was seen in all cases by immunohistochemistry. No neuroendocrine expression by immunohistochemistry was identified. In 12 (92%) cases, Ki-67 was estimated at $\leq 5\%$. One (8%) case had Ki-67 labeling index of 15%.

There were four (22%) cases that were classified as intermediary type. All intermediary cases showed at least focal expression of PLM, including strong expression in three cases. Solid sheets of

tumor cells and necrosis were identified in all cases. Two of four (50%) cases showed solid growth with squamous cell carcinoma features, including keratinization (Figures 4 and 5). One (out of two) case showed diffuse squamous cell cytomorphology. The other case showed patchy squamous differentiation, solid growth, and Ki-67 of 20%. Two of four (50%) exhibited pro-proliferative and/or neuroendocrine features. One showed solid growth with central necrosis, mitotic activity, and Ki-67 index of 60% (Figure 6). The other case showed overlapping acinar and neuroendocrine cytomorphology (Figure 7), with synaptophysin expression and Ki-67 index of 20%.

There were two (11%) cases classified as HGNC type (Figures 8 and 9). Both cases showed cytomorphology typical of neuroendocrine carcinoma, including high nuclear to cytoplasmic ratios, fine chromatin, nuclear molding, crush artifact, necrosis, and frequent mitoses. Absent in both cases was acinar PC morphology. Ki-67 labeling index was highly elevated in both cases (60%-70%). One had retained expression of PLM in addition to neuroendocrine biomarker expression. One lacked PLM and neuroendocrine biomarker expression by immunohistochemical stain, despite typical neuroendocrine carcinoma cytologic features and lost expression of Rb and Cyclin D1. The latter patient had a recent rise in PSA and radiographic findings consistent with multifocal metastatic disease

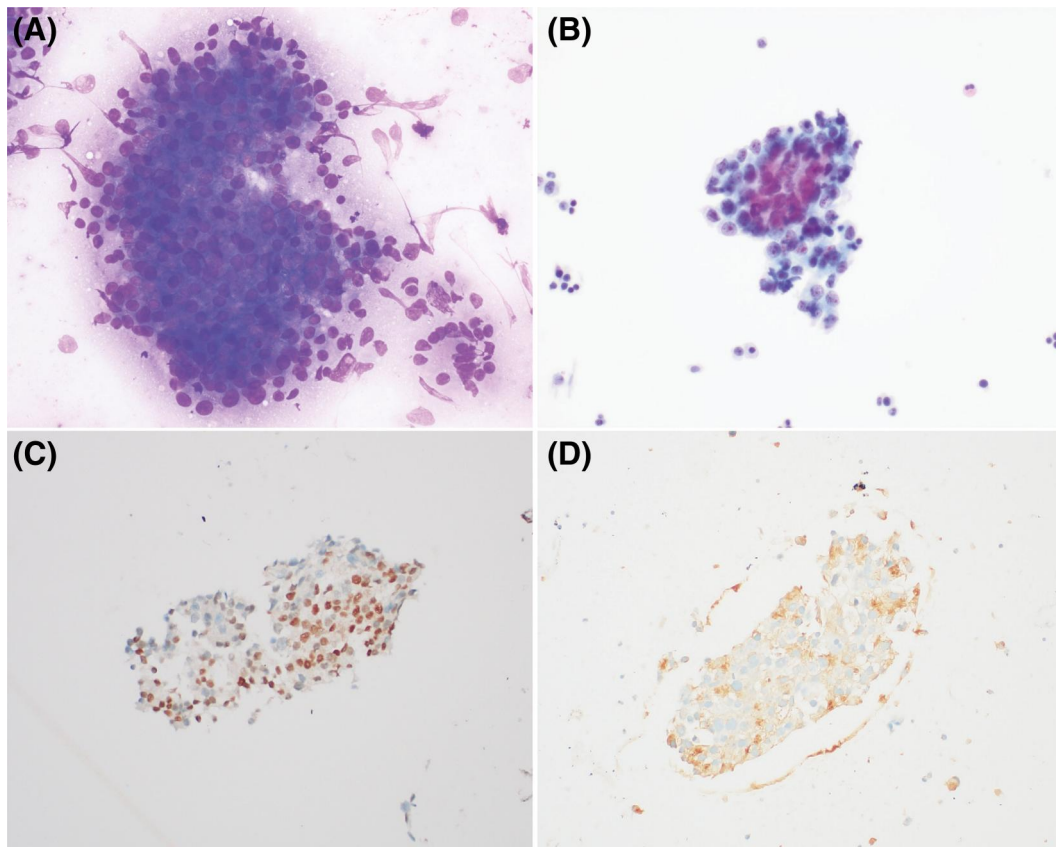


FIGURE 3 Conventional acinar prostatic adenocarcinoma metastatic to mediastinal lymph node in a patient who had received prior anti-androgen therapy (patient 12). The adenocarcinoma retains the conventional acinar morphology and prominent nucleoli typical of prostatic adenocarcinoma (A and B, smear slides, DiffQuik-stained 100 \times and Papanicolaou-stained, 200 \times). As in untreated cases, tumor cells retained expression of NKX3.1 (C) and PSMA (D). PSMA indicates prostate-specific membrane antigen

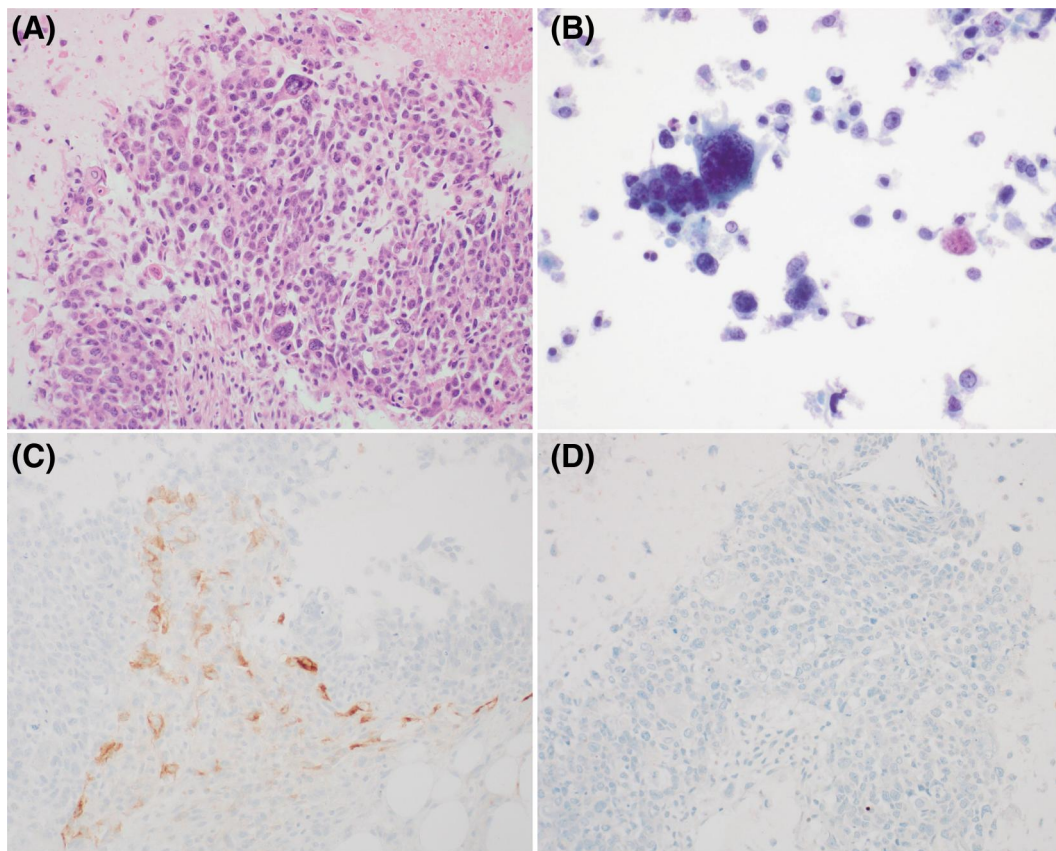


FIGURE 4 Squamous cell carcinoma differentiation in prostatic cancer metastatic to the femur (patient 13). Carcinoma is present as solid sheets with keratinization (A, cell block, hematoxylin and eosin, 200 \times) and as clusters with markedly pleomorphic forms (B, ThinPrep, Papanicolaou-stained, 400 \times). Patchy retained expression of PSMA (C) was present, whereas NKX3.1 (D) was negative. PSMA indicates prostate-specific membrane antigen

involving the pelvis, lung, and multiple lymph node sites, all clinical features known to be consistent with a small cell carcinoma phenotype.

Prognostic and Predictive Immunohistochemistry

Table 5 summarizes previously described prognostic and predictive immunohistochemistry results (Figure 10). ARv7 expression was identified by immunohistochemical stain in four FNAs from three (18%) patients, one each from the HGNC, intermediary, and conventional subcategories. The patient with two mediastinal lymph node samples had expression of ARv7 in both sites. PTEN expression was identified in one case, that of a small cell carcinoma. No PTEN expression was seen in conventional subtype cases. ERG expression was seen in six (33%) cases, including strong (>50%) expression in two of four intermediary cases and moderate (<50%) expression in four of 13 conventional cases. RB protein and cyclin D1 expression were both lost in two (11%) cases, one each of HGNC and conventional types. There were two additional cases (11%) that showed loss of RB protein with retained cyclin D1 expression. PDL1 expression was identified in two cases (11%) (Figure 10). All other cases showed complete absence of PDL1 expression (0%).

Prior Therapy and Metastatic Prostate Cancer Subcategory

Review of clinical history revealed a history of PC treatment for six of six (100%) patients with HGNC or intermediary types versus eight of 12 (67%) patients with conventional type MPC. Overall, six of 12 (50%) with a history of ADT were categorized as intermediary or HGNC, compared with zero of six (0%) without prior ADT. Both HGNC cases occurred after prostatectomy and treatment with multiple antiandrogenic medications: one receiving leuprorelin, abiraterone, and enzalutamide and one leuprorelin and bicalutamide. Neither had prior radiation therapy. Among the intermediary type, four of four patients received both radiation and antiandrogenic therapy. A total of 75% (three of four) of intermediary patients received initial definitive radiation therapy for PC, compared with 7% (one of 14) of HGNC and conventional type cases. Among conventional type cases, eight patients had a history of PC therapy, including six with antiandrogen therapy, one with definitive radiation, and one with prostatectomy with subsequent salvage radiation. Prior salvage radiation was common overall in this cohort (five of eight). Four of four cases with no prior therapy were of conventional type.

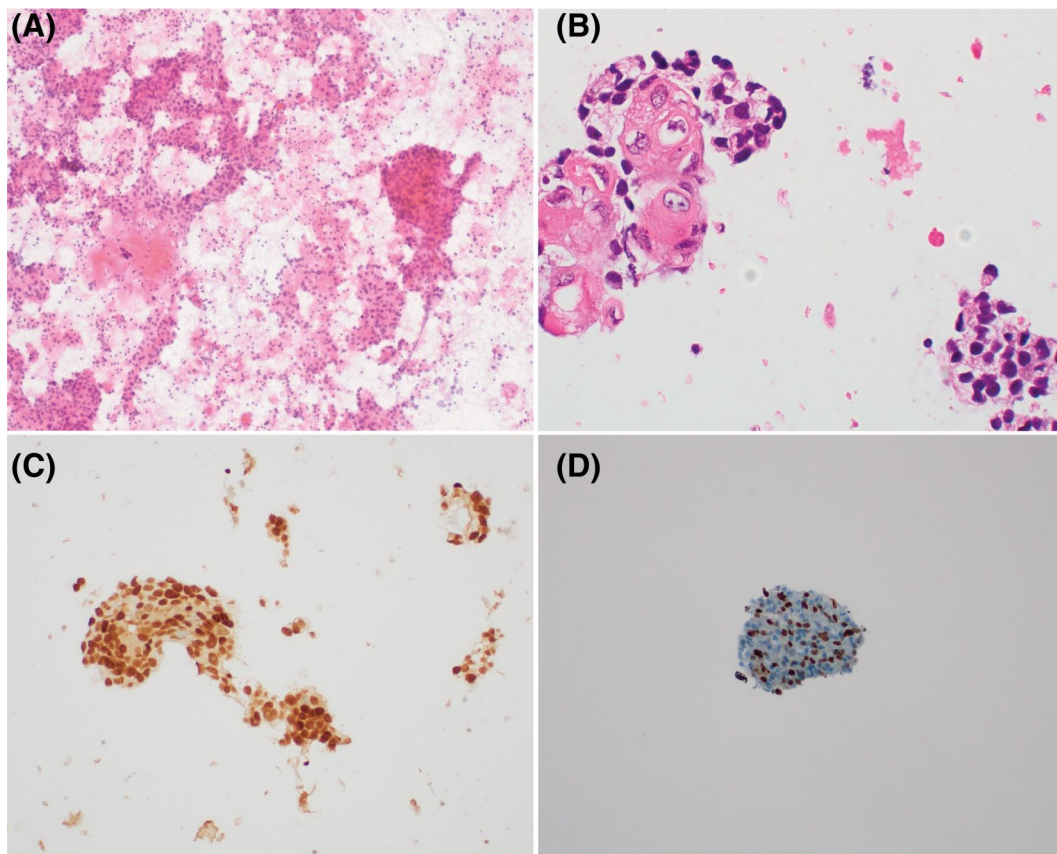


FIGURE 5 Squamous cell carcinoma differentiation in metastatic prostatic cancer to the mediastinal lymph node (patient 14). Solid sheets of large tumor cells are present with necrosis (A, smear slide, Papanicolaou-stained, 200 \times), including prominent keratinization (B, cell block, hematoxylin and eosin, 400 \times). Prostate lineage marker expression, such as NXX3.1 (C) was retained. Ki-67 labeling index was elevated (D)

Clinical Outcomes

Clinical follow-up was available for 16 patients (Table 6). There were 11 (69%) patients that died of PC, with survival times from 5 to 35 months. There were five (31%) patients alive at the time of this study, including three without radiographic evidence of disease. Three surviving patients (60%) had 2 years or less of ongoing follow-up. Two patients (40%) were without evidence of disease after longer periods of ongoing follow-up (5 and 7 years, respectively). The three patients alive without evidence of disease all had conventional MPC at FNA and no ADT history.

Six of 11 (55%) patients with conventional type metastasis on FNA died of disease, compared with five of five (100%) with HGNC or intermediary type who died of disease. Two patients with HGNC died at 6 and 8 months after FNA diagnosis. Three patients with intermediary type died at 5 months, 14 months, and 18 months. One patient with intermediary disease was lost to follow-up.

DISCUSSION

The diagnosis of MPC on FNA is often uncomplicated. Conventional PC shows characteristic cytomorphology (acinar formations, prominent nucleoli) and immunohistochemical staining (NXX3.1 and PSA

expression).⁸⁻¹⁰ Therapy-naive MPC is generally of the conventional type; however, treatment history can have a significant impact on the features of MPC. Clinical and radiographic features, such as widespread axial metastases and rising serum PSA, can assist the diagnosis. However, although conventional PC is easy to diagnose, transdifferentiation to atypical forms can occur. Transformation to castration-resistant and hormone-refractory phenotypes occurs first through reactivation of the AR pathway and then through acquisition of additional mutations, which may allow for independence from the AR pathway as a driver of proliferation.^{16,20} Cytopathologists must be aware of these variant morphologies, such as HGNC including small cell carcinoma, to avoid misclassification of metastatic carcinoma. Serum PSA can be a helpful ancillary study even in patients with nonconventional disease, as significant PSA elevations were seen in patients with not only conventional subtypes (e.g., patients 3-5) but also HGNC (patient 18) and intermediary (patients 15 and 16) subtypes (Table 1). The recognition of variant morphologies is also important for prognostic and predictive purposes. Identification of HGNC is particularly consequential because such cancers are typically treated with platinum-based chemotherapeutics. Notably, neither case of HGNC was identified as such by cytopathology report in our study.

A number of other genetic alterations can affect PC progression and contribute to the development of advanced stage PC and

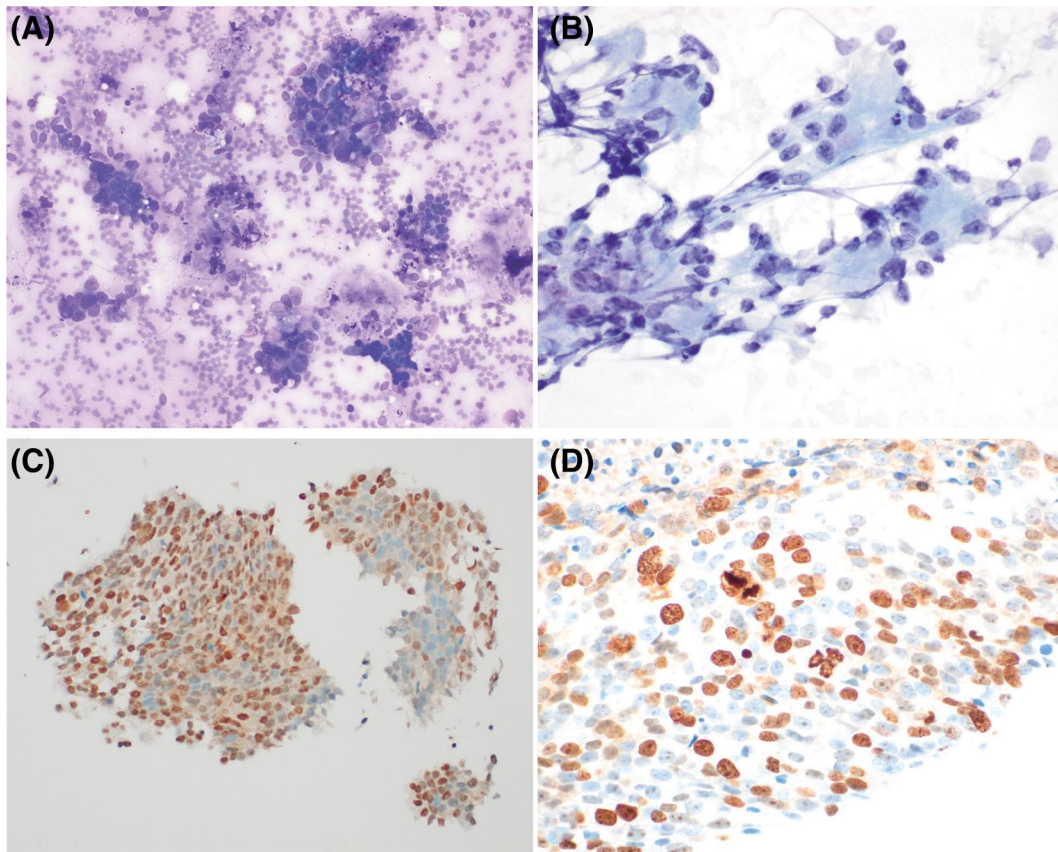


FIGURE 6 Pro-proliferative features in prostatic cancer metastatic to the subcarina (patient 15). Tumor is present in solid sheets and poorly formed acinar arrangements (A and B, smear slide, Papanicolaou stained, 400 \times and cell block, hematoxylin and eosin, 200 \times). NKX3.1 expression is retained (C), but Ki-67 labeling index is >50% (D)

CRPC.^{17,21,29} Rearrangements of the *ERG* oncogene, which encodes the transcription factor ERG protein, leading to fusion with *TMPRSS2*, a prostate-specific cell-surface serine protease gene, are identified in more than half of PC, and may represent an early step in the development of many cases.²⁹ Alterations of the tumor suppressor gene *PTEN*, especially deletions, are uncommon in localized PC but are present in up to 60% of metastatic cases.³⁰ *Rb* and *p53* gene mutations are also more commonly identified in metastatic disease and in PC with neuroendocrine phenotype.^{22,31}

In this retrospective study, we found that cytomorphologic and immunohistochemical features can allow for identification of PC subtypes of interest. Conventional MPC was the most common subtype, including among patients with prior treatment for PC. Such cases were characterized by the presence of typical acinar PC morphology, diffuse PLM expression, and low Ki-67 labeling index. HGNC was distinguished by typical small cell carcinoma morphology with or without associated neuroendocrine biomarker expression, with Ki-67 index of $\geq 50\%$. In between were intermediary cases, which included cases with transformation to nonacinar (squamous) morphology and pro-proliferative cases with features intermediate between conventional acinar MPC and HGNC. In our study, six cases (33%) displayed atypical PC features on FNA, including two that were HGNC (11%). There were four cases (22%) that showed intermediary variant morphologies, including two (11%) with squamous cell

carcinoma and two (11%) with pro-proliferative phenotype. These four intermediary cases maintained at least partial expression of PLM, with strong PLM staining in three (75%).

Although the vast majority of newly diagnosed PC show conventional features, therapy can induce changes, leading to atypical phenotypes. All patients with aggressive subtypes of MPC had prior therapy, including six (100%) with prior ADT. Notably, both patients with HGNC subtype had received at least two forms of androgen-targeting therapy. The four patients with intermediary subtype had all received at least one ADT and radiotherapy sessions, with three (75%) patients having been treated with both definitive radiotherapy and ADT. Among patients with conventional subtype of MPC, prior therapy (8/12, 67%) and prior ADT (6/12, 50%) were less common. Like ADT, radiation therapy may be associated with progression of disease.^{32,33} In this study, an initial prostate cancer treatment of definitive radiation was present in three of six (50%) of nonconventional forms of MPC compared with one of 12 (8%) of acinar MPC (Table 6).

Overall outcomes in our study correlated with MPC subtype. The presence of HGNC or intermediary morphology was an ominous finding, as five of five (100%) patients died within 14 months. HGNC and intermediary cases had a median survival of just 6 months; interestingly, intermediary cases exhibited aggressive disease similar to fully developed HGNC phenotype. Among patients with

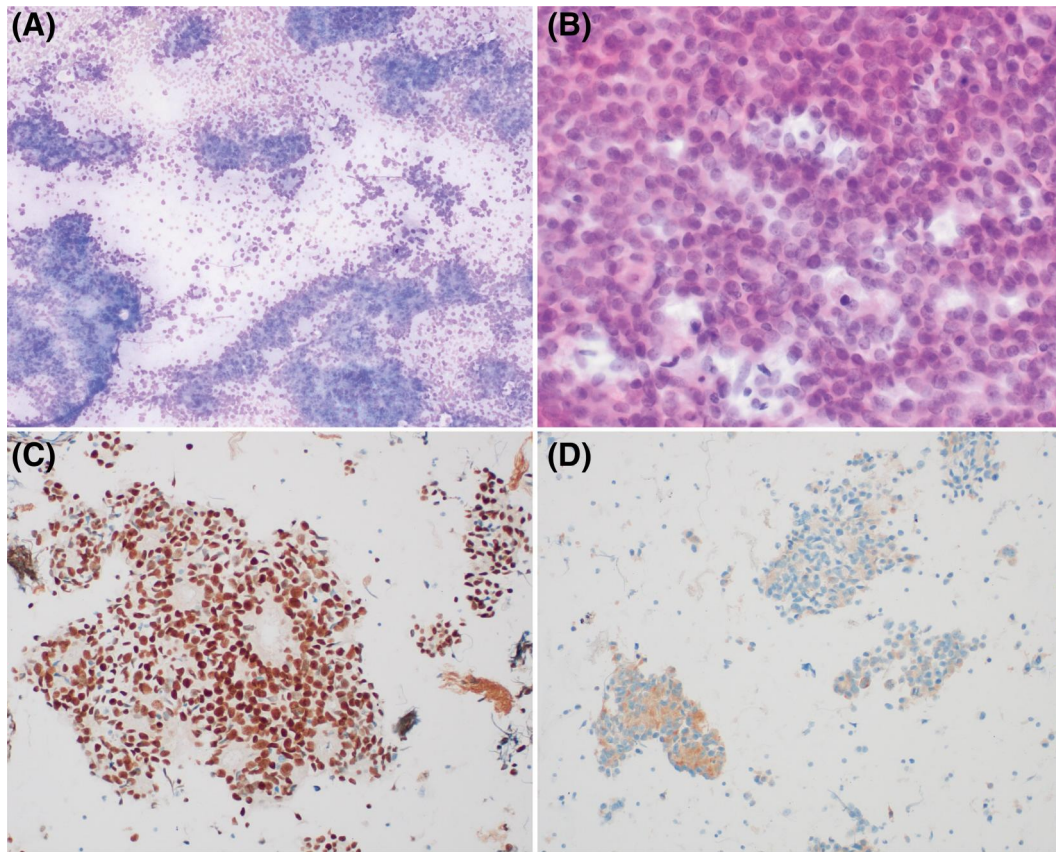


FIGURE 7 Neuroendocrine transdifferentiation in metastatic prostatic cancer with retained acinar features in a mediastinal lymph node (patient 16). Smear slides show clear acinar formations (A, smear slide, DiffQuik-stained, 200 \times), but in other areas tumor cells are present as single cells and in loose sheets, with fine chromatin lacking nucleoli (B, smear slide, Papanicolaou stained, 400 \times). NKX3.1 expression was retained (C), but moderate expression of synaptophysin (D) was also noted

conventional MPC, six of 11 (55%) died of disease after a median survival of 12 months. Of the five surviving patients, three had no clinoradiological evidence of disease at 2, 5, and 7 years. Notably, all three patients were naive to ADT at the time of FNA. Overall survival was 60% (three of five) in ADT-naïve patients compared with 18% (two of 11) for patients previously treated with at least one ADT agent.

From a diagnostic perspective, immunohistochemistry for PLM, such as AR, NKX3.1, PSMA, PSA, and ERG, helped confirm an MPC diagnosis (Table 7). In particular, PSMA showed at least focal staining in all cases. It is important to remember that the AR pathway can frequently be dysfunctional in metastatic, treated PC, especially during the castrate-resistant phase. Such dysfunctionality also affects and frequently leads to underexpression of androgen signaling-dependent biomarkers like PSA and ERG.³⁴ Hence, although positive ERG immunohistochemical expression is highly specific for a cancer of primary prostatic origin, negative ERG expression could result from dysfunctional androgen signaling; in such cases, genomic ERG rearrangement can be detected by using an ERG break-apart fluorescent in situ hybridization assay.³⁵ ERG expression may be a negative predictor for docetaxel response and was identified in six of 18 (33%) of cases. Complete loss of AR expression was identified in

only two cases, both of which exhibited variant morphology: one AR-null HGNC and one non-neuroendocrine AR-null (squamous cell) case.

Although immunohistochemistry for PLM is generally sufficient for diagnosing and characterizing therapy-naïve MPC, our findings suggest that an expanded diagnostic panel may be considered in ADT-treated patients, especially in those with nonacinar morphologic phenotypes. A Ki-67 labeling index of 20% or greater was seen to be associated with aggressive features in our study (five of six cases). Previous studies of primary prostate cancer have set Ki-67 thresholds of 5% or 10% for high-risk disease.³⁶⁻³⁸ One case of therapy-naïve, conventional subtype MPC (patient 1) had a Ki-67 labeling index of 15%. All other cases of conventional MPC showed Ki-67 labeling indices of <10%. Three intermediary cases had Ki-67 labeling index of more than 20%, whereas one intermediary case with squamous phenotype had 10% labeling. As expected, the two HGNC cases demonstrated Ki-67 labeling of 50% or greater. In addition to Ki-67, synaptophysin and chromogranin immunohistochemistry should be considered in any posttherapy cases with nonacinar morphology to help identify neuroendocrine transdifferentiation.

Immunohistochemical stains can highlight important prognostic and predictive features of MPC. Loss of PTEN expression, typically

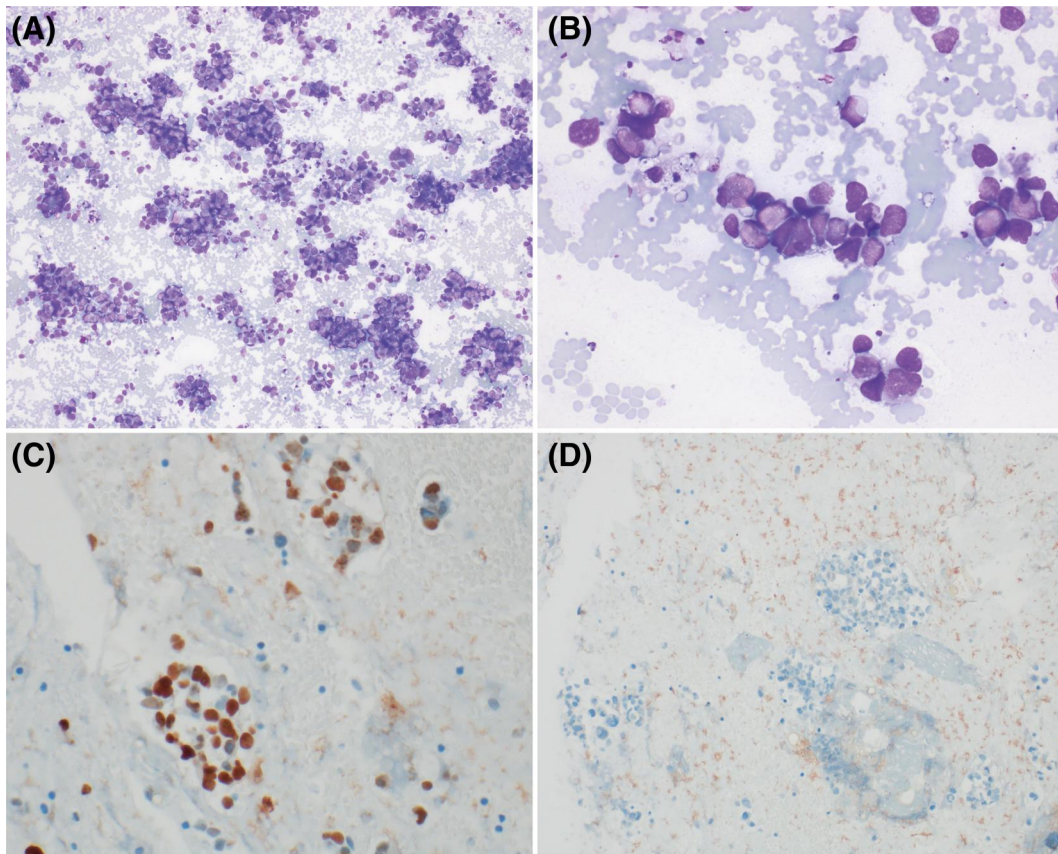


FIGURE 8 Small cell carcinoma (high-grade neuroendocrine) in prostatic cancer metastatic to a left cervical lymph node (patient 17). Tumor is present exclusively in loose sheets of cells exhibiting typical small cell features, including high nuclear to cytoplasmic ratios, fine chromatin, nuclear molding, and absent nucleoli (A and B, smear slides, DiffQuik stained, 200 \times and 400 \times). Acinar morphology is absent. Ki-67 labeling index is elevated over 50% (C), and Rb (D) expression is lost

through deletion of the gene locus, is a common early event in the development of MPC, and in fact all cases of conventional PC showed lost PTEN expression in our study. PTEN expression was only identified in one HGNC. Loss of RB is also associated with aggressive phenotypes, including androgen-refractory forms with or without HGNC transformation. One of two HGNC cases displayed loss of RB by immunohistochemistry, along with one of four intermediary and two of 12 conventional subtypes. Three of three patients with RB loss and clinical follow-up died within 12 months of FNA.

Constitutive activity of AR pathway through the ARv7 splice variant can allow for evasion of AR suppression by PTEN. ARv7 is associated with aggressive disease, and two of two patients with ARv7 positivity and clinical follow-up died within 14 months of FNA. Predictive immunohistochemistry for PDL1 and ERG may also provide useful clinical information. PDL1 immunohistochemistry is predictive for response to pembrolizumab in other cancers, and PDL1 expression of 1% or greater was identified in two of 18 (11%) cases.³¹ ARv7 and PDL1 expression were only identified in ADT-treated cases.

To our knowledge, this is the first study that details the cytopathologic features in patients with MPC relative to their past multimodality therapy, including second-generation androgen receptor

signaling inhibitors. The strengths of this study include a contemporary assessment using current and novel biomarkers to effectively subcategorize MPC cases. Limitations of this study include the small patient numbers and lack of corresponding biopsy material for definitive biopsy-cytology-based correlations.

In summary, MPC can show a spectrum of cytomorphologic and immunohistochemical features on FNA. Most cases are of conventional acinar type, but transformation to variant forms can occur as a result of prior therapy with ADT with or without radiation. Prior treatment with multiple modalities was associated with an enrichment of cases exhibiting transformation to intermediary (nonconventional) forms and HGNC in our study. Careful cytomorphologic assessment of FNA material is necessary for patients with previously anti-androgen-treated MPC to rule out transformation to atypical phenotypes. A panel of biomarkers (Table 7) can further help annotate and correctly categorize such MPC cases and hence carry clinical importance, including PLM (AR, NKX3.1, PSMA, PSA, ERG), Ki-67, and neuroendocrine markers such as synaptophysin and chromogranin, along with signal pathway markers like RB and Cyclin D1. An elevated Ki-67 labeling index in the correct morphologic and clinical context may help confirm such transformed MPC. Neuroendocrine marker expression and Ki-67 >50% can help confirm HGNC

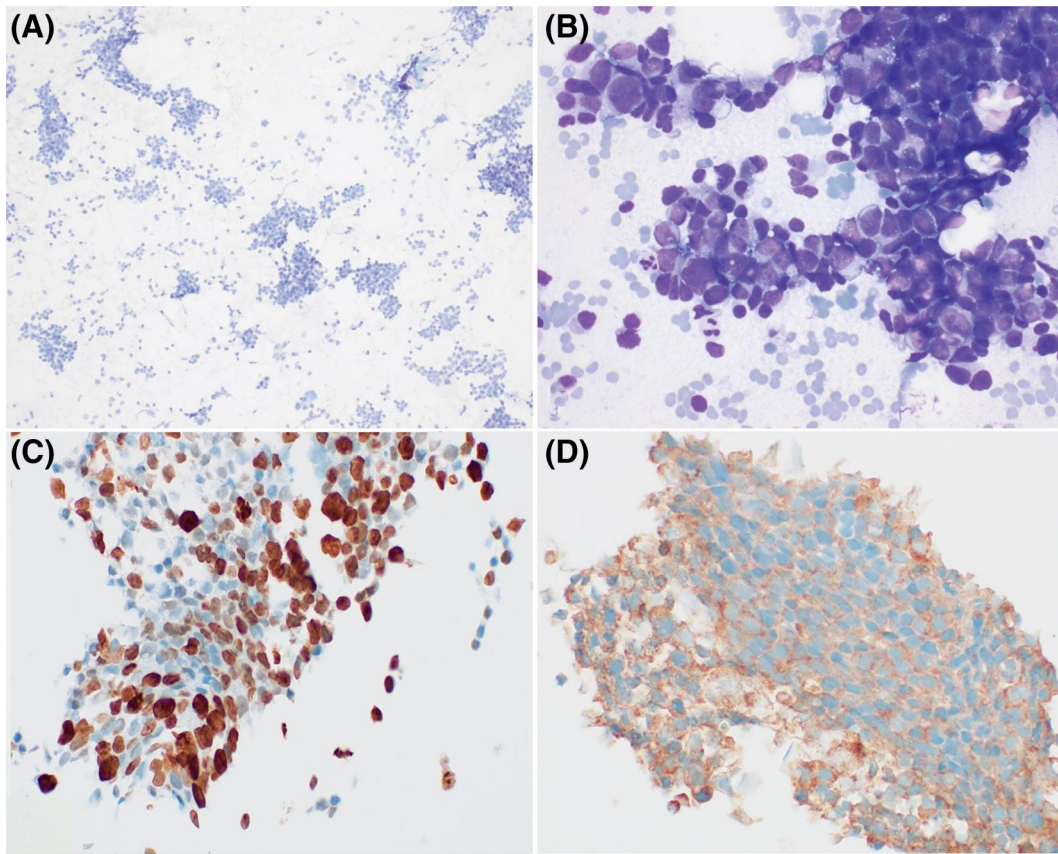


FIGURE 9 Small cell carcinoma (high-grade neuroendocrine) in prostatic cancer metastatic to a left cervical lymph node (patient 18). Like patient 17, typical features of small cell carcinoma are noted, such as loss of cohesion, fine chromatin, and nuclear molding. (A and B, smear slides, Papanicolaou-stained, 200 \times and DiffQuik stained, 400 \times). NKX3.1 (C) expression was retained, but diffuse synaptophysin (D) expression was also present

diagnosis, which is particularly important as HGNC is typically nonresponsive to AR-targeted therapies but may be responsive to platinum-based therapy (e.g., cisplatin). Intermediary transformed cases include MPC that show either partial transformation to neuroendocrine carcinoma or transformation to other nonacinar epithelial subtypes, such as squamous cell carcinoma. They show aggressive features, including nonacinar morphology, necrosis, and high Ki-67 labeling index (pro-proliferative phenotype), while maintaining at least partial PLM expression; such intermediary cases are best managed through multi-disciplinary case discussions in a genitourinary tumor board setting. Ancillary studies may identify biological aberrations such as ARv7 or PDL1 expression in patients treated with antiandrogen therapy. Ancillary immunohistochemical studies can accordingly provide important prognostic and predictive information for MPC in FNA material.

AUTHOR CONTRIBUTIONS

Richard L. Cantley: Methodology, formal analysis, investigation, writing: original draft, and visualization. **Xiaoming Wang:** Methodology, writing – review & editing, and visualization. **Zachery R. Reichert:** Investigation and writing – review & editing. **Arul M.**

Chinnaiyan: Conceptualization, resources, and writing – review & editing. **Rahul Mannan:** Methodology and writing – review & editing. **Xuhong Cao:** Methodology, resources, and writing – review & editing, and visualization. **Daniel E. Spratt:** Writing – review & editing. **Ulka N. Vaishampayan:** Writing – review & editing. **Joshi J. Alumkal:** Writing – review & editing. **Todd M. Morgan:** Writing – review & editing. **Ganesh Palapattu:** Writing – review & editing. **Matthew S. Davenport:** Writing – review & editing. **Liron Pantanowitz:** Conceptualization, methodology, formal analysis, writing – review & editing, and visualization. **Rohit Mehra:** Conceptualization, formal analysis, investigation, methodology, resources, writing – review & editing, visualization, and supervision.

ACKNOWLEDGMENTS

The authors thank Jyoti Athanikar, PhD, for the assistance in manuscript preparation and Angela Wilson for administrative support. We acknowledge the valuable assistance provided by the department of pathology's surgical pathology and immunohistochemistry staff at Michigan Medicine, University of Michigan. Grant number and/or funding information: Michigan Prostate SPORE: P50CA186786 and EDNRN: U01CA214170.

TABLE 5 Biomarker immunohistochemistry in metastatic prostate cancer

Patient	Category	ARv7	PTEN	ERG	PDL1	Rb	CyclinD1
1	Conventional	Negative	Negative	Negative	Negative	Retained	Retained
2	Conventional	Negative	Negative	Positive, diffuse	Negative	Retained	Retained
3	Conventional	Negative	Negative	Negative	Negative	Retained	Retained
4	Conventional	Negative	Negative	Negative	Negative	Lost	Lost
5A	Conventional	Positive	Negative	Negative	Negative	Retained	Retained
5B	Conventional	Positive	Negative	Negative	Negative	Retained	Retained
6	Conventional	Negative	Negative	Negative	Negative	Retained	Retained
7	Conventional	Negative	Negative	Negative	Positive	Retained	Retained
8	Conventional	Negative	Negative	Negative	Negative	Retained	Retained
9	Conventional	Negative	Negative	Negative	Negative	Retained	Retained
10	Conventional	Negative	Negative	Positive, focal	Negative	Retained	Retained
11	Conventional	Negative	Negative	Positive, focal	Negative	Lost	Retained
12	Conventional	Negative	Negative	Positive, focal	Negative	Retained	--- (No residual tissue)
13	Intermediary	Negative	Negative	Negative	Negative	Lost	Retained
14	Intermediary	Negative	Negative	Positive, diffuse	Negative	Retained	Retained
15	Intermediary	Positive	Negative	Positive, diffuse	Negative	Retained	Retained
16	Intermediary	Positive	Negative	Negative	Positive	Retained	Retained
17	High-grade neuroendocrine carcinoma	Negative	Negative	Negative	Negative	Lost	Lost
18	High-grade neuroendocrine carcinoma	Negative	Positive	Negative	Negative	Retained	Retained

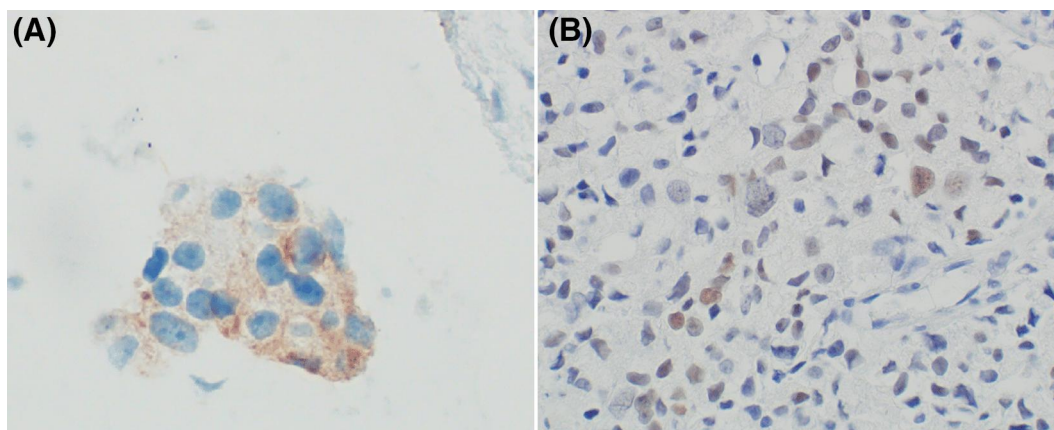


FIGURE 10 Biomarker immunohistochemistry in metastatic prostate cancer. PDL1 staining was identified in two cases, including patient 7 (A). ARv7 expression was present in 4 FNAs from three patients, including patient 5 (B). FNA indicates fine-needle aspiration

TABLE 6 Clinical trajectories for patients with metastatic prostate cancer

Patient	Tumor classification	History of first-generation ADT	History of SGAAT	History of definitive radiation	Clinical outcome
1	Conventional	No	No	No	DOD - 8 mo
2	Conventional	No	No	No	DOD - 30 mo
3	Conventional	No	No	No	Alive - NED at 7 y
4	Conventional	No	No	No	Lost to follow-up
5	Conventional	No	Yes	No	DOD - 12 mo
6	Conventional	No	No	Yes	Alive - NED at 5 y
7	Conventional	Yes	No	No	DOD - 35 mo
8	Conventional	Yes	No	No	DOD - 10 mo
9	Conventional	No	No	No	Alive - NED at 2 y
10	Conventional	Yes	No	No	Alive with disease at 2 y
11	Conventional	Yes	Yes	No	DOD - 12 mo
12	Conventional	Yes	Yes	No	Alive with disease at 1 y
13	Intermediary	Yes	No	No	DOD - 7 m
14	Intermediary	Yes	No	Yes	DOD - 5 mo
15	Intermediary	Yes	No	Yes	DOD - 14 mo
16	Intermediary	Yes	No	Yes	Lost to follow-up
17	High-grade neuroendocrine carcinoma	Yes	No	No	DOD - 6 mo
18	High-grade neuroendocrine carcinoma	Yes	Yes	No	DOD - 8 mo

Abbreviations: ADT, androgen deprivation therapy; DOD, died of disease; NED, no evidence of disease; SGAAT, second-generation anti-androgen therapy.

CONFLICT OF INTEREST

Liron Pantanowitz is on the scientific advisory board for Ibex and NTP and serves as a consultant for Hamamatsu. The University of Michigan

has been issued a patent on the detection of ETS gene fusions in prostate cancer, on which Rohit Mehra and Arul M. Chinnaiyan are listed as co-inventors. All other authors have no relevant disclosures.

TABLE 7 Proposed biomarkers for metastatic prostate cancer and transformed states

Marker category	Immunohistochemical stains
Prostate lineage	AR, NKX3.1, PSMA, PSA, ERG
Proliferation	Ki-67
Neuroendocrine	Synaptophysin, Chromogranin
Prognostic and predictive	Rb, Cyclin D1, ARv7, PTEN, PDL1

Abbreviations: AR, androgen receptor; ARv7, androgen receptor variant 7; ERG, ETS family transcription factor ERG; PDL1, programmed death-ligand 1; Rb, retinoblastoma protein; PSA, prostate-specific antigen; PSMA, prostate-specific membrane antigen; PTEN, phosphatase and tensin homolog.

ORCID

Richard L. Cantley  <https://orcid.org/0000-0002-6564-3889>

Liron Pantanowitz  <https://orcid.org/0000-0001-8182-5503>

REFERENCES

- Siegel RL, Miller KD, Fuchs HE, Jemal A. Cancer statistics, 2022. *CA - Cancer J Clin.* 2022;72(1):7-33. doi:10.3322/caac.21708
- Sailer V. Metastatic prostate cancer. In: Robinson B, Mosquera J, Ro J, Divatia M, eds. *Precision Molecular Pathology of Prostate Cancer. Molecular Pathology Library.* Springer; 2018.
- Hamdy FC, Donovan JL, Lane JA, et al. Active monitoring, radical prostatectomy and radical radiotherapy in PSA-detected clinically localised prostate cancer: the ProtecT three-arm RCT. *Health Technol Assess.* 2020;24(37):1-176. doi:10.3310/hta24370
- Donnelly AE, Den R. Radiotherapy for prostate cancer. In: Trabulsi EJ, Lallas CD, Lizardi-Calvaresi AE, eds. *Chemotherapy and Immunotherapy in Urologic Oncology.* Springer; 2021.
- Reyes C, Groshel C, Given R. Androgen deprivation therapy. In: Trabulsi EJ, Lallas CD, Lizardi-Calvaresi AE, eds. *Chemotherapy and Immunotherapy in Urologic Oncology.* Springer; 2021.
- Sartor O, de Bono JS. Metastatic prostate cancer. *N Engl J Med.* 2018;378(7):645-657. doi:10.1056/nejmra1701695
- Bubendorf L, Schöpfer A, Wagner U, et al. Metastatic patterns of prostate cancer: an autopsy study of 1,589 patients. *Hum Pathol.* 2000;31(5):578-583. doi:10.1053/hp.2000.6698
- Albadri ST, Salomão D. Metastatic prostate adenocarcinoma to cervical lymph nodes: an unusual diagnosis on fine-needle aspiration biopsy. *J Am Soc Cytopathol.* 2021;10(2):231-238. doi:10.1016/j.jasc.2020.08.009
- Gan Q, Joseph CT, Guo M, Zhang M, Sun X, Gong Y. Utility of NKX3.1 immunostaining in the detection of metastatic prostatic carcinoma on fine-needle aspiration smears. *Am J Clin Pathol.* 2019;152(4):495-501. doi:10.1093/ajcp/aqz063
- Abdulfatah E, Reichert ZR, Davenport MS, et al. De novo neuroendocrine transdifferentiation in primary prostate cancer—a phenotype associated with advanced clinico-pathologic features and aggressive outcome. *Med Oncol.* 2021;38(3):26. doi:10.1007/s12032-021-01473-2
- Abdulfatah E, Fine SW, Lotan T, Mehra R. De novo neuroendocrine features in prostate cancer. *Hum Pathol.* 2022;127:112-122. doi:10.1016/j.humpath.2022.07.002
- Beltran H, Hruszkewycz A, Scher HI, et al. The role of lineage plasticity in prostate cancer therapy resistance. *Clin Cancer Res.* 2019;25(23):6916-6924. doi:10.1158/1078-0432.CCR-19-1423
- Cackowski FC, Kumar-Sinha C, Mehra R, et al. Double-negative prostate cancer masquerading as a squamous cancer of unknown primary: a clinicopathologic and genomic sequencing-based case study. *JCO Precis Oncol.* 2020;4:PO.20.00309.
- Parwani AV, Ali SZ. Prostatic adenocarcinoma metastases mimicking small cell carcinoma on fine-needle aspiration. *Diagn Cytopathol.* 2002;27(2):75-79. doi:10.1002/dc.10146
- Schiewer MJ, Augello MA, Knudsen KE. The AR dependent cell cycle: mechanisms and cancer relevance. *Mol Cell Endocrinol.* 2012;352(1-2):34-45. doi:10.1016/j.mce.2011.06.033
- de Brot S, Mongan NP. The cell cycle and androgen signaling interactions in prostate cancer. In: Robinson B, Mosquera J, Ro J, Divatia M, eds. *Precision Molecular Pathology of Prostate Cancer. Molecular Pathology Library.* Springer; 2018.
- Pisano C, Tucci M, Di Stefano RF, et al. Interactions between androgen receptor signaling and other molecular pathways in prostate cancer progression: current and future clinical implications. *Crit Rev Oncol Hematol.* 2021;157:103185. doi:10.1016/j.critrevonc.2020.103185
- Helsen C, Van den Broeck T, Voet A, et al. Androgen receptor antagonists for prostate cancer therapy. *Endocr Relat Cancer.* 2014;21(4):T105-T118. doi:10.1530/erc-13-0545
- Shah RB, Mehra R, Chinnaiyan AM, et al. Androgen-independent prostate cancer is a heterogeneous group of diseases: lessons from a rapid autopsy program. *Cancer Res.* 2004;64(24):9209-9216. doi:10.1158/0008-5472.can-04-2442
- Tamada S, Iguchi T, Kato M, et al. Time to progression to castration-resistant prostate cancer after commencing combined androgen blockade for advanced hormone-sensitive prostate cancer. *Oncotarget.* 2018;9(97):36966-36974. doi:10.18632/oncotarget.26426
- Lotan TL. PI3K/Akt/mTOR/PTEN and ERK/MAPK pathways. In: Robinson B, Mosquera J, Ro J, Divatia M, eds. *Precision Molecular Pathology of Prostate Cancer. Molecular Pathology Library.* Springer; 2018.
- Gopalan A, Al-Ahmadie H, Chen YB, et al. Neuroendocrine differentiation in the setting of prostatic carcinoma: contemporary assessment of a consecutive series. *Histopathology.* 2022;81(2):246-254. doi:10.1111/his.14707
- Manucha V, Henegan J. Clinicopathologic diagnostic approach to aggressive variant prostate cancer. *Arch Pathol Lab Med.* 2020;144(1):18-23. doi:10.5858/arpa.2019-0124-ra
- Antonarakis ES, Lu C, Wang H, et al. AR-V7 and resistance to enzalutamide and abiraterone in prostate cancer. *N Engl J Med.* 2014;371(11):1028-1038. doi:10.1056/nejmoa1315815
- Bryden AA, Freemont AJ, Clarke NW, George NJ. Ki-67 index in metastatic prostate cancer. *Eur Urol.* 2001;40(6):673-676. doi:10.1159/000049856
- Haffner MC, Guner G, Taheri D, et al. Comprehensive evaluation of programmed death-ligand 1 expression in primary and metastatic prostate cancer. *Am J Pathol.* 2018;188(6):1478-1485. doi:10.1016/j.ajpath.2018.02.014
- Sharma M, Yang Z, Miyamoto H. Immunohistochemistry of immune checkpoint markers PD-1 and PD-L1 in prostate cancer. *Medicine (Baltim).* 2019;98(38):e17257. doi:10.1097/md.00000000000017257
- Kürönya Z, Sükösd F, Varga L, et al. ERG expression can predict the outcome of docetaxel combined with androgen deprivation therapy in metastatic hormone-sensitive prostate cancer. *Urol Oncol.* 2019;37(4):289.e1-289.e9. doi:10.1016/j.urolonc.2018.12.007
- Tomlins SA, Rhodes DR, Perner S, et al. Recurrent fusion of TMPRSS2 and ETS transcription factor genes in prostate cancer. *Science.* 2005;310(5748):644-648. doi:10.1126/science.1117679
- Jamaspishvili T, Berman DM, Ross AE, et al. Clinical implications of PTEN loss in prostate cancer. *Nat Rev Urol.* 2018;15(4):222-234. doi:10.1038/nrurol.2018.9
- Tsai H, Morais CL, Alshalalfa M, et al. Cyclin D1 loss distinguishes prostatic small-cell carcinoma from most prostatic adenocarcinomas.

- Clin Cancer Res.* 2015;21(24):5619-5629. doi:10.1158/1078-0432.ccr-15-0744
32. Hu CD, Choo R, Huang J. Neuroendocrine differentiation in prostate cancer: a mechanism of radioresistance and treatment failure. *Front Oncol.* 2015;5(90). doi:10.3389/fonc.2015.00090
33. Obata H, Shiota M, Akitake N, et al. Differential risk of castration resistance after initial radical prostatectomy or radiotherapy for prostate cancer. *Anticancer Res.* 2017;37(10):5631-5637.
34. Udager AM, Shi Y, Tomlins SA, et al. Frequent discordance between ERG gene rearrangement and ERG protein expression in a rapid autopsy cohort of patients with lethal, metastatic, castration-resistant prostate cancer. *Prostate.* 2014;74(12):1199-1208. doi:10.1002/pros.22836
35. Mehra R, Tomlins SA, Yu J, et al. Characterization of TMPRSS2-ETS gene aberrations in androgen-independent metastatic prostate cancer. *Cancer Res.* 2008;68(10):3584-3590. doi:10.1158/0008-5472.can-07-6154
36. Byun SS, Lee M, Hong SK, Lee H. Elevated Ki-67 (MIB-1) expression as an independent predictor for unfavorable pathologic outcomes and biochemical recurrence after radical prostatectomy in patients with localized prostate cancer: a propensity score matched study. *PLoS One.* 2019;14(11):e0224671. doi:10.1371/journal.pone.0224671
37. Kammerer-Jacquet SF, Ahmad A, Møller H, et al. Ki-67 is an independent predictor of prostate cancer death in routine needle biopsy samples: proving utility for routine assessments. *Mod Pathol.* 2019;32(9):1303-1309. doi:10.1038/s41379-019-0268-y
38. Lotan TL, Tomlins SA, Bismar TA, et al. Report from the International Society of Urological Pathology (ISUP) Consultation Conference on Molecular Pathology of Urogenital Cancers. I. Molecular biomarkers in prostate cancer. *Am J Surg Pathol.* 2020;44(7):e15-e29. doi:10.1097/PAS.0000000000001450

How to cite this article: Cantley RL, Wang X, Reichert ZR, et al. Metastatic prostate cancer diagnosed by fine-needle aspiration: contemporary cytopathologic and biomarker assessment with clinical correlates. *Cancer Cytopathol.* 2023;131(2):117-135. doi:10.1002/cncy.22652