

Tavelli Lorenzo (Orcid ID: 0000-0003-4864-3964)
Wang Hom-Lay (Orcid ID: 0000-0003-4238-1799)
Barootchi Shayan (Orcid ID: 0000-0002-5347-6577)

Vertical soft tissue augmentation to treat implant esthetic complications: A prospective clinical and volumetric case series

Running title: Vertical soft tissue augmentation

Lorenzo Tavelli, DDS, MS^{1,2,3}, Giovanni Zucchelli, DDS, PhD^{3,4}, Martina Stefanini, DDS, PhD⁴, Giulio Rasperini^{1,5,6}, DDS, Hom-Lay Wang, DDS, MS, PhD², Shayan Barootchi, DMD, MS^{2,3}

¹ Department of Oral Medicine, Infection, and Immunity, Division of Periodontology, Harvard School of Dental Medicine, Boston, MA, USA

² Center for clinical Research and evidence synthesis In oral TissuE RegeneratION (CRITERION), Boston, MA, USA

³ Department of Periodontics & Oral Medicine, University of Michigan School of Dentistry, Ann Arbor, MI, USA

⁴ Department of Biomedical and Neuromotor Sciences, University of Bologna, Bologna, Italy

⁵ Department of Biomedical, Surgical and Dental Sciences, University of Milan, Milan, Italy

⁶ IRCCS Foundation Polyclinic Ca' Granda, Milan, Italy

Lorenzo Tavelli, DDS, MS; Assistant Professor, Harvard School of Dental Medicine, Boston, USA

Giovanni Zucchelli, DDS, PhD; Full Professor, University of Bologna, Italy

Martina Stefanini, DDS, PhD; Assistant Professor, University of Bologna, Italy

Giulio Rasperini, DDS; Associate Professor, University of Milan, Italy

Hom-Lay Wang, DDS, MS, PhD; Full Professor, University of Michigan, USA

Shayan Barootchi, DDS, MS; Clinical Assistant Professor, University of Michigan, USA

Corresponding author

Lorenzo Tavelli, DDS, MS

Division of Periodontology, Department of Oral Medicine, Infection, and Immunity

Harvard School of Dental Medicine, 188 Longwood Avenue, Boston 02115, MA, USA

E-mail address: lorenzo_tavelli@hsdm.harvard.edu

Figures and Tables: 3 figures and 3 tables

Conflict of interest and source of funding: The authors do not have any financial interests, either directly nor indirectly, in the products or information listed in the paper.

This is the author manuscript accepted for publication and has undergone full peer review but has not been through the copyediting, typesetting, pagination and proofreading process, which may lead to differences between this version and the Version of Record. Please cite this article as doi: [10.1111/cid.13188](https://doi.org/10.1111/cid.13188)

This article is protected by copyright. All rights reserved.

Contribution statement: L.T. and S.B. equally contributed to study design, clinical procedures, data collection and interpretation, drafting the article, critical revision of the manuscript and final approval of the article. S.B. performed the data analysis. G.Z., M.S., G.R. and H.L.W contributed to data interpretation, critical revision of the manuscript and final approval.

Acknowledgments: the study was self-supported.

Data availability statement: The data that support the findings of this study are available from the corresponding author upon reasonable request.

ABSTRACT

Introduction. Challenging implant esthetic complications are often characterized by implant malpositioning and interproximal attachment loss of the adjacent teeth. However, limited evidence is available on the treatment of these conditions. The aim of the present study was to evaluate the clinical, volumetric, and patient-reported outcome following treatment of peri-implant soft tissue dehiscences (PSTDs) exhibiting interproximal attachment loss on adjacent teeth, performed through vertical soft tissue augmentation with implant submersion.

Methods. Ten subjects with isolated PSTD in the anterior maxilla characterized by adjacent dentition exhibiting interproximal attachment loss were consecutively enrolled and treated with horizontal and vertical soft tissue augmentation, involving crown and abutment removal, two connective tissue grafts and submerge healing. Clinical outcomes of interest included mean PSTD coverage, mean PSTD reduction, clinical attachment level (CAL) gain at the implant and adjacent sites and soft tissue phenotype modifications at 1 year. Optical scanning was used for assessing volumetric changes. Professional assessment of esthetic outcomes was performed using the Implant Dehiscence coverage Esthetic Score (IDES), while patient-reported esthetic assessment involved a 0-10 visual analogue scale.

Results. The mean PSTD depth reduction and mean PSTD coverage at 1 year were 2.25 mm, and 85.14%, respectively. A mean keratinized tissue width (KTW) gain of 1.15 mm was observed, while the mean gain in mucosal thickness (MT) was 1.58 mm. A mean CAL gain of 1.45 mm was obtained at the interproximal aspect of the adjacent dentition at 1 year. Greater linear dimensional (LD) changes were observed at the midfacial aspect of the implant compared to the interproximal sites. The mean final IDES was 6.90 points, while patient-reported esthetic evaluation was 8.83 points.

Conclusions. The present study demonstrated that vertical soft tissue augmentation with a submerged healing is an effective treatment approach for the treatment of challenging PSTDs with adjacent dentition exhibiting interproximal attachment loss. This technique can be effective in resolution of esthetic complications in most cases, providing a substantial gain in interproximal attachment levels at the adjacent dentition.

Key words: dental implants, esthetic complications, connective tissue graft, 3D analysis, patient-reported outcomes, peri-implant soft tissue dehiscences

Tavelli Lorenzo (Orcid ID: 0000-0003-4864-3964)
Wang Hom-Lay (Orcid ID: 0000-0003-4238-1799)
Barootchi Shayan (Orcid ID: 0000-0002-5347-6577)

STUDY DESIGN

The present study is a case series.

SUMMARY BOX

What is known

- Peri-implant soft tissue dehiscences are common conditions. Their treatment can be complicated by implant malpositioning, shallow peri-implant papillae and interproximal attachment loss in the adjacent teeth.
- Only case reports are available in the literature when assessing the efficacy of surgical approaches for the treatment of challenging peri-implant soft tissue dehiscences that require vertical soft tissue augmentation at the implant and the adjacent sites.

What this study adds

The present report describes a series of successfully treated esthetic complications, as part of a controlled study setting, with an in-depth evaluation of clinical, volumetric and patient-reported outcomes following vertical soft tissue augmentation with implant submersion for implants with adjacent sites exhibiting attachment loss.

INTRODUCTION

By now, it is well known that the anatomy of dental implants – relative to natural dentition – and its adjacent tissues differ from the periodontia^{1,2}. Nonetheless, soft tissue deformities around implants and teeth also have similar features³. Both peri-implant soft tissue dehiscences (PSTDs)^{4,5} and gingival recessions (GRs) are highly prevalent clinical conditions⁶⁻⁹. Also, their main indication for treatment is patient's esthetic concerns¹⁰⁻¹³. GRs and PSTDs also share several common etiological factors, including lack of keratinized tissue, limited soft tissue thickness, buccal bone dehiscence and malposition, among others^{7,14-16}.

From the first studies describing the outcomes of PSTD treatment^{17,18}, it appeared that traditional root coverage techniques – as performed in natural dentition – have limited predictability for the correction of implant esthetic complications. When the conventional coronally advanced flap (CAF) was performed with subepithelial connective tissue graft (CTG), Burkhardt et al. reported none of the implants resulted in a complete resolution of the PSTD at 6 months¹⁸. Anderson et al. found a mean PSTD coverage of 40% and 28% following CAF + subepithelial CTG and the acellular dermal matrix, respectively¹⁷. Indeed, this does not appear to be in line with the treatment outcomes commonly observed when the same techniques are performed for GRs¹⁹⁻²¹. It has been advocated that the type of graft can also play a role on the treatment outcomes of PSTDs, with CTG obtained from the superficial palate or the maxillary tuberosity that should be preferred due to its higher amount of lamina propria and minimal presence of fatty and glandular tissue^{3,12,22}. Similarly, it has been suggested that an envelope CAF can also be beneficial in several cases of PSTDs^{12,23}, while the prosthetic-surgical approach, involving the removal of the crown (but with the abutment left in place) at least 1 month prior to the surgical procedure, can be advocated in other instances^{3,22}. With this technique, Zucchelli and coworkers obtained a mean PSTD coverage of 96.3% and 99.2% at 1 and 5 years, respectively.^{22,24}

More challenging case scenarios involve implant esthetic complications characterized by implant malpositioning which may have also resulted in interproximal attachment loss of the adjacent dentition⁷. These types of PSTDs are associated with papilla(ae) loss and the occurrence of black triangles, which are often the main reason for patients inquiring esthetic treatments²⁵⁻²⁷. However, limited evidence is available on papilla reconstruction between dental implants and teeth with interproximal attachment loss^{25,26,28-30}. Urban et al. showed that papilla reconstruction in the above condition can be obtained through a multidisciplinary approach involving implant explanation, guided bone regeneration, soft tissue augmentation and utilization of a customized abutment²⁸. Stefanini and coworkers described a successful case management for a PSTD with adjacent teeth showing interproximal attachment loss by application of a modified “connective tissue platform technique”³¹, previously introduced for soft tissue augmentation of edentulous areas²⁶. The authors stabilized one CTG on the buccal aspect of the implant and two CTGs, one on top of the other, over the implant

platform and on the de-epithelialized occlusal ridge, aiming for a submerged healing approach for the implant with PSTD ²⁶.

The aim of the present study was therefore to consequently enroll and treat patients with esthetic concerns due to PSTDs exhibiting interproximal attachment loss on adjacent teeth, through horizontal and vertical soft tissue augmentation with implant submersion, and assess the clinical, volumetric and subjective patient-reported outcomes.

MATERIAL AND METHODS

Study population

Ten patients presenting with esthetic concerns related to an isolated PSTD in the anterior maxilla with adjacent dentition exhibiting interproximal attachment loss were consecutively enrolled between August 2020 and April 2021. All patients were at least 18 years old, with good general health and oral hygiene (full-mouth plaque scores $\leq 15\%$), without systemic/periodontal disease. The isolated implants must have been without notable peri-implant disease characterized by class II, III or IV and subclass c PSTD⁴, with presence of at least one adjacent tooth with interproximal attachment loss and interproximal GR at least 1 mm. In addition, the presence of at least one notably visible “black triangle” in an exaggerated smile was required, and patients must have been willing to undergo removal of the abutment and implant-supported crown, and its replacement after the treatment.

Smoking, pregnancy (or planning to become pregnant), active periodontal disease, history of soft tissue grafting at the experimental site(s) within the past 6 months and the presence of peri-implant diseases at the implant site ³² were considered to be exclusion criteria. The study protocol was approved by the Institutional Review Board of the University of Michigan (HUM00146261), in accordance with the Declaration of Helsinki of 1975, revised in Fortaleza in 2013. Written informed consents were obtained from all individuals who participated in the study prior to the surgical procedures. This manuscript is prepared following the PROCESS 2020 Guideline for improving the quality of case series reports (<http://www.processguideline.com/>)^{33,34}.

Vertical soft tissue Augmentation with Implant Submersion

Participants were informed that the surgical approach would require crown as well as abutment removal, with the delivery of a provisional prosthesis (either a resin-bonded fix dental prosthesis or an essix retainer) at the day of the surgery. All patients also received a session of dental prophylaxis, including oral hygiene instructions. The surgical procedure consisted of a vertical and horizontal soft tissue augmentation with implant submersion, similar to the modification of the connective platform technique ³¹ previously described by Stefanini et al. ²⁶ (Fig. 1).

A horizontal incision was performed from the soft tissue margin of the implant to the gingival margin of the adjacent teeth, where intrasulcular incisions were made. Next, horizontal and vertical incisions were made at the level of the adjacent teeth to create anatomical papillae of adequate dimensions and

surgical papillae including keratinized tissue, as wide as possible. The flap included at least the two adjacent teeth (mesial and distal to the implant with PSTD). In the presence of additional sites with gingival recessions, the flap was extended. Flap elevation occurred split-thickness around the dental implant and interproximally using a miniblade (Salvin Dental Specialties, Charlotte, USA), while the midfacial portion of the teeth included in the flap was elevated full-thickness until exposing the crestal bone using a microperiosteal elevator. A split-thickness dissection was also performed on the palatal aspect, only at the level of the implant region, to expose a portion of the palatal connective tissue with the goal of facilitating closure, adaptation and stabilization of the buccal flap. After flap release with deep and superficial cuts, the anatomical papillae and the soft tissue on the ridge were de-epithelialized with a miniblade and a small round bur. The horizontal augmentation around the implant site (and if needed also around the adjacent sites) involved the harvesting of a CTG from the lateral palate as a free gingival graft that was then extraorally de-epithelialized and stabilized over the implant site with simple interrupted sutures to the periosteum and de-epithelialized adjacent papilla soft tissue (7/0 PGA, Butterfly, Cavenago di Brianza, Italy). The vertical augmentation at the level of the implant site was performed with a second CTG, that was harvested either from the maxillary tuberosity (if available) or from the palate as an epithelialized free gingival graft. After extraoral de-epithelialization, the graft was stabilized over the occlusal ridge on the implant platform and sutured against the papilla(e) of the tooth (teeth) with interproximal attachment loss using simple interrupted sutures for anchorage to the periosteum and the de-epithelialized soft tissues (7/0 PGA, Butterfly, Cavenago di Brianza, Italy). Autogenous platelet-rich fibrin membranes (PRF) were prepared as previously described³⁵ and applied over the CTGs prior to flap closure. A closure by primary intention - or with a minimal exposure of the graft - was obtained. A first layer of one or more horizontal mattress suture(s) from the buccal flap to the palatal flap was performed, followed by simple interrupted sutures approximating the edges of the buccal and palatal flaps (6/0 and/or 7/0 polypropylene [Ethicon, Johnson & Johnson, Somerville, USA]). Flap adaptation was completed with sling sutures at the level of the elevated papillae, and simple interrupted sutures for the vertical incisions (6/0 and/or 7/0 polypropylene [Ethicon, Johnson & Johnson, Somerville, USA]).

Oral and written post-operative instructions were provided to patients, as well as prescriptions for analgesics (Ibuprofen 600 mg every 4-6 hours as needed), antibiotics (Amoxicillin 500 mg every 8 hours for 7 days), and a mouth rinse (chlorhexidine gluconate 0.12% for the first two weeks). The sutures were removed at the 2-week post-op visit, where the subjects were instructed to resume oral hygiene procedures using an extra-soft toothbrush for the first month, prior to switching to a soft-bristle toothbrush. Patients were recalled at 1, 3, 6 and 12 months for post-operative healing assessment and measurements.

Restorative phase

As previously implied, the implant-supported crown and abutment were removed at the day of the surgical procedure and replaced with a cover screw. Based on the bucco-lingual position of the implant, its mesio-distal distance from the adjacent teeth, and the restorative status of the adjacent dentition (unrestored, with a previous crown or restoration), a decision was taken together with the patient regarding the restorative plan for the implant with the PSTD. In case of buccally positioned implants, < 1.5 mm apart from the adjacent tooth showing a significant interproximal attachment loss, and adjacent teeth with pre-existing crowns or extensive restorations, it was suggested to leave the implant submerged also after the healing, and finalize the case with a fixed dental prosthesis, a resin-bonded fixed dental prosthesis or alternative solutions involving anchorage to the adjacent dentition. The final decision was always taken in agreement with the patient.

For implants that could be restored, the sites were opened 3 months following the vertical soft tissue augmentation procedure, using a punch biopsy technique to identify the cover screw. A temporary crown was then delivered, while the final implant-supported restorations were delivered at least after 6 months (Fig. 2).

Study endpoints

The main outcome of the study was the assessment of the mean PSTD coverage (in %) after 1 year. Secondary endpoints included vertical soft tissue gain – assessed as mean PSTD reduction (in mm) – and interproximal clinical attachment level (CAL) gain at the implant and adjacent sites. Changes in mucosal thickness (MT), keratinized mucosa width (KMW) were also evaluated at the implant site, while gingival recession (REC) depth and keratinized gingiva width (KGW) were assessed in the adjacent dentition at the midfacial and interproximal (towards the implant) aspects.

Volumetric changes were assessed using digital impressions obtained with intraoral optical scanning at baseline and 1 year. The Implant Dehiscence coverage Esthetic Score (IDES)¹³ was utilized for the professional assessment of the esthetic outcomes following vertical soft tissue augmentation after 1 year. Patient-reported outcome measures (PROMs) included the evaluation of post-operative discomfort during the first two weeks and final esthetic assessment at 1 year using questionnaires with 0-10 visual analogue scales (VASs). Willingness for retreatment, if needed, was also set as an outcome and evaluated at the 1-year follow-up.

Additional information on the assessment of the above-mentioned clinical, esthetic and patient-reported parameters are described in the Supplementary Appendix.

STL file acquisition and Volumetric outcomes assessment

An intraoral optical scanner (Trios, 3Shape, Denmark) was utilized at baseline and at the last follow-up visit to generate digital models that were saved as STL files and imported in an image analysis software (GOM Inspect, GOM, Germany). A single pre-calibrated examiner with experience in 3D volumetric analysis (L.T.) performed all the measurements. A semi-automated alignment, based on the

selection of reproducible points on the digital models and on a best-fit algorithm was used to superimpose the STL files ^{36,37}. The STL file at the 1-year follow-up was superimposed to the one obtained at baseline (prior to treatment), which was used as the reference (Fig. 3). The region of interest (ROI) was defined as previously described ^{38,39}. Briefly, the ROI was a rectangular shape with the soft tissue margin as its coronal border, extending 7 mm in a corono-apico direction. The ROI was delimited by two lines perpendicular to the occlusal plane and to the CEJ of the adjacent teeth, passing through the mid-point of the mesial and distal papillae of the implant ³⁸. The volumetric outcomes of interest were calculated as linear dimensional (LD) changes, assessed at the interproximal and midfacial aspects of the implant site at 8 points, 1 mm apart from each other, starting from the tip of the papilla at baseline (for the interproximal sites) and starting from the most coronal point of the buccal soft tissue at baseline (for the midfacial site) ^{38,40,41}. LD outcomes at the mesial and distal papilla were then merged.

Statistical analysis

Descriptive statistics were used to present the clinical, ultrasonographic and volumetric data, as well as PROMs, with means \pm standard deviations (SD). Adjusted paired t-tests were utilized to statistically compare the changes in these outcomes between baseline and 1 year. To explore for statistically meaningful influence of any clinical parameters at baseline (to the final outcome), linear regression analysis was used which also accounted for subject/patient baseline characteristics that could potentially influence the results (e.g., age, sex). A p value threshold of 0.05 was set for statistical significance. The analyses were performed in Rstudio (Rstudio Version 1.1.383, Rstudio, Inc., Boston, USA) by an author with experience in data and statistical analysis (S.B.).

RESULTS

Ten systemically and periodontally healthy patients (3 males and 7 females, mean age of 52.8 ± 13.9 years) were included in the study. All cases were bone-level implants, and the mean loading time prior to the initial visit was 8.6 ± 2.7 years. Among the treated PSTDs, six were central incisors, 2 lateral incisors and 2 canines. Eight PSTDs were diagnosed as class IV subclass c and the remaining 2 were class III subclass c⁴. Six sites showed 1 black triangle, while 4 implants exhibited 2 black triangles. The mean PSTD depth at baseline was 2.60 mm, while the mean baseline REC and CAL at the adjacent teeth were 1.55 mm and 2.85 mm, respectively. An average interproximal CAL of 3.3 mm was observed at the level of adjacent dentition at baseline (Table 1).

No intra- or post-operative complications had occurred. The healing was uneventful at all sites with the subjects reporting a mean morbidity during the first 2 weeks of 2.63 points on a 0-10 VAS. Five implant sites were re-opened, and new implant-supported crowns and abutments were delivered, while in the other 5 cases, the implants were left submerged, and the restorations relied on the adjacent dentition.

Table 1 depicts in detail the outcomes at 1 year following vertical soft tissue augmentation. The mean PSTD depth reduction and mean PSTD coverage at 1 year were 2.25 mm, and 85.14%, respectively. A mean KTW gain of 1.15 mm was observed, while the mean gain in MT was 1.58 mm. A mean REC reduction and CAL gain of 1.28 mm and 1.45 mm, respectively, was obtained at 1 year at the interproximal aspect of the adjacent dentition. At the 1-year assessment, 5 sites showed only 1 black triangle, while the other treated implants did not show any black triangles. The overall percentage of black triangle reduction (compared to baseline) was 64.3%.

LD changes are depicted in detail in Table 2. Overall greater LD changes were observed at the midfacial aspect of the implant site compared to peri-implant papillae. Mean LD changes at the midfacial aspect of the implant range between 2.11 mm and 3.15 mm, while at the interproximal aspect the mean LD changes were between 0.68 mm and 1.95 mm. The professional esthetic outcomes, evaluated with the IDES, revealed a mean final IDES of 6.90 points (Table 3). Patient-reported esthetic assessment at the last visit was 8.83 points on a 0-10 VAS, with all the treated subjects stating that they would be available for retreatment, if needed. Supplementary Table 1 displays the results of the exploratory regression analysis for assessing factors related to the final outcome of mean PSTD coverage (in %) after 1 year. Among the variables, the analysis indicated that gender had a significant association with the results among this dataset, such that males obtained a significantly lower coverage of their treated PSTD (model estimate -35.9 (95% CI [-53.50, -18.31]), $p < 0.01$).

DISCUSSION

Dental implants have reached a very high level of popularity among patients and clinicians. Indeed, this also accompanies an inevitable increase in the occurrence of implant complications as well⁴²⁻⁴⁵. PSTDs associated with implant malpositioning are often characterized by loss of interproximal papilla and attachment levels of the adjacent dentition, resulting in “black triangles”, which are typically one of patients’ main concerns^{25,46,47}.

Vertical reconstruction of the lost hard and soft tissue architecture at implant sites is considered one of greatest challenges when treating PSTDs. Urban and coworkers illustrated a case of an implant esthetic complication successfully managed with implant removal, vertical bone augmentation, delayed implant placement with simultaneous CTG (placed vertically, on top of the implant head) and prosthetic soft tissue conditioning²⁸. The same group recently showed that vertical bone and soft tissue augmentation can further benefit from the application of recombinant human platelet-derived growth factor-BB (rhPDGF-BB) on the root surface of the adjacent dentition showing interproximal attachment loss⁴⁸. Based on the concepts of the connective tissue platform technique, advocating that localized alveolar ridge defects can be corrected with soft tissue augmentation alone³¹, Stefanini and coworkers described the management of a challenging PSTD with the adjacent teeth exhibiting interproximal attachment loss with multiple soft tissue augmentation procedures²⁶. Enamel matrix derivative (EMD) was also

used with the aim of promoting periodontal regeneration at the interproximal aspect of the adjacent dentition²⁶.

We designed a prospective case series to further evaluate the predictability of vertical soft tissue augmentation with a submerged healing approach for the treatment of PSTDs associated with interproximal papilla loss. We observed an overall mean PSTD depth reduction of 2.25 mm, corresponding to a mean PSTD coverage of 85.14%. Few studies reporting the outcomes of PSTDs treatment are available in the literature. The lack of uniform inclusion criteria and diagnosis of PSTDs may explain the wide range of mean PSTD coverage observed among studies (28-96.3%)^{12,17,18,22,49}. With the goal of promoting standard criteria for characterizing different types of PSTDs and allowing for the comparison of the obtained outcomes between different studies, our group recently proposed a new classification for PSTDs⁴. This classification system identifies four classes of PSTDs that, except for class I, are based on the bucco-lingual position of the implant-supported crown and implant head, and 3 PSTD subclasses, which are determined by the height of the peri-implant papillae⁴. The present study included only PSTD subclasses c, which are considered the most difficult conditions to address. To the best of our knowledge, this is the first case series addressing exclusively PSTDs with papilla loss and adjacent teeth with interproximal attachment levels and, therefore, comparison between our outcomes, relative to the amount of PSTD coverage, and the literature is not feasible. Interestingly, regression analysis showed that, in our cohort, females obtained higher PSTD coverage than male at 1 year. Due to the preliminary nature of the present study and the limited sample size, this finding should be interpreted with caution and further studies are needed to explore the impact of gender on the outcomes of vertical soft tissue augmentation,

Another interesting finding from this study is the interproximal attachment level gain at the adjacent teeth, which is probably related to the two CTGs employed (one “horizontally” and the other “vertically”). We found an average interproximal recession reduction and CAL gain of 1.28 mm, and 1.45 mm at 1 year, respectively. When assessed with 3D digital technology through intraoral scanners, the mean papilla gain ranged from 0.68 mm to 1.95 mm. In a recent commentary, Rasperini and coworkers highlighted the anatomical factors affecting the height of the papilla in natural dentition and the challenges related to its augmentation²⁵. It can be assumed that papilla augmentation at implant sites share the same (or even more) challenges and limited predictability than natural dentition, if the implant-supported restoration is not removed. Soft tissue reconstruction at implant sites can tremendously benefit from removing the prosthetic component – either the crown alone or with the abutment – that results in an increased vascular bed between the implant and the adjacent dentition, which is crucial for the nutrition and survival of the graft and flap³. With respect to the obtained LD gains, it should be noticed that superior outcomes were overall achieved at the midfacial aspect of the implants with PSTD compared to the interproximal areas. It can be speculated that this findings may be due to the different recipient bed and vascularization receive by the grafts. At the midfacial aspect, the CTG is positioned on the periosteum and healthy connective tissue fibers adherent to the implant fixture, and it is then

completely covered by the flap, while at the interproximal areas, the CTG is placed against the denuded root surface of the natural tooth with interproximal clinical attachment loss and may receive less blood supply from the recipient bed and the overlying flap, compared to the graft sutured at the midfacial aspect.

It has been suggested that applying rhPDGF-BB or EMD on the root surface of the adjacent teeth during vertical soft tissue augmentation may further enhance the interproximal CAL gain^{26,48,50}. We can speculate that the use of PRF in our study may have positively contributed to the interproximal CAL gain and, overall, to the treatment of the PSTDs. PRF may have facilitated the maintenance of soft tissue closure (or facilitate an early closure when healing by primary intention was not aimed and achieved) during the first phases of healing since it has similar growth factors as those noted in the rhPDGF-BB, which can positively affect the survival, dimensional stability, and attachment of the CTG to the root surface.

It has to be mentioned that the concept of vertical soft tissue augmentation has been originally introduced for preventing/minimizing marginal bone loss occurring at implant sites characterized by thin vertical soft tissues (nowadays defined as “supracrestal tissue height”)⁵¹⁻⁵³. A vertical soft tissue gain ranging from 1.33 to 2.21 mm was described within the first 2-6 months when using a human or xenogeneic acellular dermal matrix⁵⁴⁻⁵⁷. Although these results are not comparable with our findings due to the different clinical conditions (augmentation at implant placement vs treatment of implant complications with flat papilla/ae and adjacent dentition exhibiting interproximal attachment loss) and graft utilized (dermal matrices vs CTG), we can conclude that the limit of vertical soft tissue augmentation at implant sites is, on average, within 2.5 mm.

Readers should be aware that a possible concern related to an excessively augmented vertical soft tissue dimension (supracrestal tissue height) is a potential increased risk for peri-implant disease^{58,59}. This concern may be more valid for posterior implants in patients with a history of periodontal disease rather than in implants with a previously treated PSTD in the esthetic zone. Further studies are necessary to evaluate the long-term effects of the described approach on peri-implant esthetics and health. Similarly, the lack of a control group, involving conventional augmentation approaches without submerge healing or different graft materials, does not allow to draw general conclusions on the described vertical soft tissue augmentation by a submerged healing for the treatment of challenging PSTDs and, therefore, future research is required to explore these aspects.

CONCLUSIONS

Within its limitations, the present clinical study described a series of consecutively treated cases, and their outcomes, following a vertical soft tissue augmentation by a submerged healing for management of challenging peri-implant soft tissue dehiscences with adjacent dentition exhibiting interproximal attachment loss. This approach can be effective in resolution of esthetic complications in most cases,

providing a significant gain in interproximal attachment levels and root coverage at the adjacent dentition.

Acknowledgment. The authors declare no conflicts of interest.

REFERENCES

1. Ivanovski S, Lee R. Comparison of peri-implant and periodontal marginal soft tissues in health and disease. *Periodontol 2000*. 2018;76(1):116-130.
2. Sculean A, Gruber R, Bosshardt DD. Soft tissue wound healing around teeth and dental implants. *J Clin Periodontol*. 2014;41 Suppl 15:S6-22.
3. Zucchelli G, Tavelli L, Stefanini M, Barootchi S, Wang HL. The coronally advanced flap technique revisited: Treatment of peri-implant soft tissue dehiscences. *Int J Oral Implantol (Berl)*. 2021;14(4):351-365.
4. Zucchelli G, Tavelli L, Stefanini M, et al. Classification of facial peri-implant soft tissue dehiscence/deficiencies at single implant sites in the esthetic zone. *J Periodontol*. 2019;90(10):1116-1124.
5. Barootchi S, Mancini L, Heck T, et al. Reliability assessment of the classification for facial peri-implant soft tissue dehiscence/deficiencies (PSTDs): A multi-center inter-rater agreement study of different skill-level practitioners. *J Periodontol*. 2022.
6. Romandini M, Soldini MC, Montero E, Sanz M. Epidemiology of mid-buccal gingival recessions in NHANES according to the 2018 World Workshop Classification System. *J Clin Periodontol*. 2020;47(10):1180-1190.
7. Tavelli L, Barootchi S, Majzoub J, et al. Prevalence and risk indicators of midfacial peri-implant soft tissue dehiscence at single site in the esthetic zone: A cross-sectional clinical and ultrasonographic study. *J Periodontol*. 2021.
8. Barootchi S, Tavelli L, Di Gianfilippo R, et al. Soft tissue phenotype modification predicts gingival margin long-term (10-year) stability: Longitudinal analysis of six randomized clinical trials. *J Clin Periodontol*. 2022.
9. Barootchi S, Tavelli L, Zucchelli G, Giannobile WV, Wang HL. Gingival phenotype modification therapies on natural teeth: A network meta-analysis. *J Periodontol*. 2020;91(11):1386-1399.
10. Tavelli L, Barootchi S, Di Gianfilippo R, et al. Patient experience of autogenous soft tissue grafting has an implication for future treatment: A 10- to 15-year cross-sectional study. *J Periodontol*. 2021;92(5):637-647.
11. Zucchelli G, Tavelli L, McGuire MK, et al. Autogenous soft tissue grafting for periodontal and peri-implant plastic surgical reconstruction. *J Periodontol*. 2020;91(1):9-16.
12. Rocuzzo M, Gaudio L, Bunino M, Dalmaso P. Surgical treatment of buccal soft tissue recessions around single implants: 1-year results from a prospective pilot study. *Clin Oral Implants Res*. 2014;25(6):641-646.
13. Zucchelli G, Barootchi S, Tavelli L, Stefanini M, Rasperini G, Wang HL. Implant soft tissue Dehiscence coverage Esthetic Score (IDES): A pilot within- and between-rater analysis of consistency in objective and subjective scores. *Clin Oral Implants Res*. 2021;32(3):349-358.
14. Fu JH, Su CY, Wang HL. Esthetic soft tissue management for teeth and implants. *J Evid Based Dent Pract*. 2012;12(3 Suppl):129-142.
15. Sanz-Martin I, Regidor E, Navarro J, Sanz-Sanchez I, Sanz M, Ortiz-Vigon A. Factors associated with the presence of peri-implant buccal soft tissue dehiscences: A case-control study. *J Periodontol*. 2020.
16. Zucchelli G, Mounssif I. Periodontal plastic surgery. *Periodontol 2000*. 2015;68(1):333-368.
17. Anderson LE, Inglehart MR, El-Kholy K, Eber R, Wang HL. Implant associated soft tissue defects in the anterior maxilla: a randomized control trial comparing subepithelial connective tissue graft and acellular dermal matrix allograft. *Implant Dent*. 2014;23(4):416-425.
18. Burkhardt R, Joss A, Lang NP. Soft tissue dehiscence coverage around endosseous implants: a prospective cohort study. *Clin Oral Implants Res*. 2008;19(5):451-457.
19. Tavelli L, Barootchi S, Di Gianfilippo R, et al. Acellular dermal matrix and coronally advanced flap or tunnel technique in the treatment of multiple adjacent gingival recessions. A 12-year follow-up from a randomized clinical trial. *J Clin Periodontol*. 2019;46(9):937-948.

20. Barootchi S, Tavelli L, Di Gianfilippo R, et al. Long term assessment of root coverage stability using connective tissue graft with or without an epithelial collar for gingival recession treatment. A 12-year follow-up from a randomized clinical trial. *J Clin Periodontol*. 2019;46(11):1124-1133.
21. Cairo F. Periodontal plastic surgery of gingival recessions at single and multiple teeth. *Periodontol 2000*. 2017;75(1):296-316.
22. Zucchelli G, Mazzotti C, Mounssif I, Mele M, Stefanini M, Montebugnoli L. A novel surgical-prosthetic approach for soft tissue dehiscence coverage around single implant. *Clin Oral Implants Res*. 2013;24(9):957-962.
23. Zucchelli G, Mazzotti C, Mounssif I, Marzadori M, Stefanini M. Esthetic treatment of peri-implant soft tissue defects: a case report of a modified surgical-prosthetic approach. *Int J Periodontics Restorative Dent*. 2013;33(3):327-335.
24. Zucchelli G, Felice P, Mazzotti C, et al. 5-year outcomes after coverage of soft tissue dehiscence around single implants: A prospective cohort study. *Eur J Oral Implantol*. 2018;11(2):215-224.
25. Rasperini G, Tavelli L, Barootchi S, et al. Interproximal attachment gain: The challenge of periodontal regeneration. *J Periodontol*. 2021;92(7):931-946.
26. Stefanini M, Marzadori M, Tavelli L, Bellone P, Zucchelli G. Peri-implant Papillae Reconstruction at an Esthetically Failing Implant. *Int J Periodontics Restorative Dent*. 2020;40(2):213-222.
27. Mazzotti C, Stefanini M, Felice P, Bentivogli V, Mounssif I, Zucchelli G. Soft-tissue dehiscence coverage at peri-implant sites. *Periodontol 2000*. 2018;77(1):256-272.
28. Urban IA, Klokkevold PR, Takei HH. Abutment-Supported Papilla: A Combined Surgical and Prosthetic Approach to Papilla Reformation. *Int J Periodontics Restorative Dent*. 2016;36(5):665-671.
29. Urban IA, Klokkevold PR, Takei HH. Papilla Reformation at Single-Tooth Implant Sites Adjacent to Teeth with Severely Compromised Periodontal Support. *Int J Periodontics Restorative Dent*. 2017;37(1):9-17.
30. Barootchi S, Tavelli L. Tunneled coronally advanced flap for the treatment of isolated gingival recessions with deficient papilla. *Int J Esthet Dent*. 2022;17(1):14-26.
31. Zucchelli G, Mazzotti C, Bentivogli V, Mounssif I, Marzadori M, Monaco C. The connective tissue platform technique for soft tissue augmentation. *Int J Periodontics Restorative Dent*. 2012;32(6):665-675.
32. Berglundh T, Armitage G, Araujo MG, et al. Peri-implant diseases and conditions: Consensus report of workgroup 4 of the 2017 World Workshop on the Classification of Periodontal and Peri-Implant Diseases and Conditions. *J Periodontol*. 2018;89 Suppl 1:S313-S318.
33. Agha RA, Borrelli MR, Farwana R, et al. The PROCESS 2018 statement: Updating Consensus Preferred Reporting Of Case Series in Surgery (PROCESS) guidelines. *Int J Surg*. 2018;60:279-282.
34. Agha RA, Fowler AJ, Rajmohan S, Barai I, Orgill DP, Group P. Preferred reporting of case series in surgery; the PROCESS guidelines. *Int J Surg*. 2016;36(Pt A):319-323.
35. Miron RJ, Horrocks NA, Zhang Y, Horrocks G, Pikos MA, Sculean A. Extending the working properties of liquid platelet-rich fibrin using chemically modified PET tubes and the Bio-Cool device. *Clin Oral Investig*. 2022;26(3):2873-2878.
36. Borges T, Fernandes D, Almeida B, et al. Correlation between alveolar bone morphology and volumetric dimensional changes in immediate maxillary implant placement: A 1-year prospective cohort study. *J Periodontol*. 2020;91(9):1167-1176.
37. Parvini P, Galarraga-Vinueza ME, Obreja K, Magini RS, Sader R, Schwarz F. Prospective study assessing three-dimensional changes of mucosal healing following soft tissue augmentation using free gingival grafts. *J Periodontol*. 2021;92(3):400-408.
38. Tavelli L, Barootchi S, Majzoub J, Siqueira R, Mendonca G, Wang HL. Volumetric changes at implant sites: A systematic appraisal of traditional methods and optical scanning-based digital technologies. *J Clin Periodontol*. 2021;48(2):315-334.

39. Tavelli L, Barootchi S, Vera Rodriguez M, et al. Early soft tissue changes following implant placement with or without soft tissue augmentation using a xenogeneic cross-link collagen scaffold: A volumetric comparative study. *J Esthet Restor Dent*. 2022;34(1):181-187.
40. Fickl S, Schneider D, Zuhr O, et al. Dimensional changes of the ridge contour after socket preservation and buccal overbuilding: an animal study. *J Clin Periodontol*. 2009;36(5):442-448.
41. Tian J, Wei D, Zhao Y, Di P, Jiang X, Lin Y. Labial soft tissue contour dynamics following immediate implants and immediate provisionalization of single maxillary incisors: A 1-year prospective study. *Clin Implant Dent Relat Res*. 2019;21(3):492-502.
42. Barootchi S, Askar H, Ravida A, Gargallo-Albiol J, Travan S, Wang HL. Long-term Clinical Outcomes and Cost-Effectiveness of Full-Arch Implant-Supported Zirconia-Based and Metal-Acrylic Fixed Dental Prostheses: A Retrospective Analysis. *Int J Oral Maxillofac Implants*. 2020;35(2):395-405.
43. Barootchi S, Ravida A, Tavelli L, Wang HL. Nonsurgical treatment for peri-implant mucositis: A systematic review and meta-analysis. *Int J Oral Implantol (Berl)*. 2020;13(2):123-139.
44. Barootchi S, Tavelli L, Majzoub J, Chan HL, Wang HL, Kripfgans OD. Ultrasonographic Tissue Perfusion in Peri-implant Health and Disease. *J Dent Res*. 2022;101(3):278-285.
45. Barootchi S, Wang HL. Peri-implant diseases: Current understanding and management. *Int J Oral Implantol (Berl)*. 2021;14(3):263-282.
46. Urban IA, Barootchi S, Tavelli L, Wang HL. Inter-Implant Papilla Reconstruction via a Bone and Soft Tissue Augmentation: A Case Report with a Long-Term Follow-up. *Int J Periodontics Restorative Dent*. 2021;41(2):169-175.
47. Wang, II, Barootchi S, Tavelli L, Wang HL. The peri-implant phenotype and implant esthetic complications. Contemporary overview. *J Esthet Restor Dent*. 2021;33(1):212-223.
48. Urban IA, Tattan M, Ravida A, Saleh M, Tavelli L, Avila-Ortiz G. Simultaneous alveolar ridge augmentation and periodontal regenerative therapy leveraging recombinant human platelet derived growth factor BB (rhPDGF-BB): A case report. *Int J Periodontics Restorative Dent*. 2022; Accepted for Publication.
49. Frisch E, Ratka-Kruger P. A new technique for peri-implant recession treatment: Partially epithelialized connective tissue grafts. Description of the technique and preliminary results of a case series. *Clin Implant Dent Relat Res*. 2020;22(3):403-408.
50. Tavelli L, Ravida A, Barootchi S, Chambrone L, Giannobile WV. Recombinant Human Platelet-Derived Growth Factor: A Systematic Review of Clinical Findings in Oral Regenerative Procedures. *JDR Clin Trans Res*. 2021;6(2):161-173.
51. Linkevicius T, Apse P, Grybauskas S, Puisys A. The influence of soft tissue thickness on crestal bone changes around implants: a 1-year prospective controlled clinical trial. *Int J Oral Maxillofac Implants*. 2009;24(4):712-719.
52. Linkevicius T, Linkevicius R, Alkimavicius J, Linkeviciene L, Andrijauskas P, Puisys A. Influence of titanium base, lithium disilicate restoration and vertical soft tissue thickness on bone stability around triangular-shaped implants: A prospective clinical trial. *Clin Oral Implants Res*. 2018;29(7):716-724.
53. Puisys A, Linkevicius T. The influence of mucosal tissue thickening on crestal bone stability around bone-level implants. A prospective controlled clinical trial. *Clin Oral Implants Res*. 2015;26(2):123-129.
54. Puisys A, Vindasiute E, Linkeviciene L, Linkevicius T. The use of acellular dermal matrix membrane for vertical soft tissue augmentation during submerged implant placement: a case series. *Clin Oral Implants Res*. 2015;26(4):465-470.
55. Puisys A, Zukauskas S, Kubilius R, et al. Clinical and Histologic Evaluations of Porcine-Derived Collagen Matrix Membrane Used for Vertical Soft Tissue Augmentation: A Case Series. *Int J Periodontics Restorative Dent*. 2019;39(3):341-347.
56. Verardi S, Orsini M, Lombardi T, et al. Comparison between two different techniques for peri-implant soft tissue augmentation: Porcine dermal matrix graft versus tenting screw. *J Periodontol*. 2019.

57. Zang J, Su L, Luan Q, Liu G, Li S, Yu X. Clinical and histological evaluation of the use of acellular dermal matrix (ADM) membrane in peri-implant vertical soft tissue augmentation: A controlled clinical trial. *Clin Oral Implants Res.* 2022.
58. Zhang Z, Shi D, Meng H, Han J, Zhang L, Li W. Influence of vertical soft tissue thickness on occurrence of peri-implantitis in patients with periodontitis: a prospective cohort study. *Clin Implant Dent Relat Res.* 2020;22(3):292-300.
59. Chan D, Pelekos G, Ho D, Cortellini P, Tonetti MS. The depth of the implant mucosal tunnel modifies the development and resolution of experimental peri-implant mucositis: A case-control study. *J Clin Periodontol.* 2019;46(2):248-255.

Figures and Tables

Table 1. Clinical outcomes at baseline and 1 year.

Table 2. Linear dimensional changes at the midfacial aspect of the implant and peri-implant papillae, evaluated from superimposition of the digital scans at baseline and 1 year.

Table 3. Esthetic outcomes evaluated with the Implant Dehiscence coverage Esthetic Score (IDES) at 1 year.

Figure 1. Vertical soft tissue augmentation with submerged implant healing for the treatment of a peri-implant soft tissue dehiscence with adjacent teeth exhibiting interproximal attachment loss and gingival recession. A-C) Baseline. D) Crown and abutment removal. E) Flap design, with a horizontal incision on the buccal mucosa and two divergent vertical incisions. F) Split-thickness flap elevation, except for the midfacial portion of the natural teeth that was raised full-thickness until exposing the bone crest. G) Occlusal view after flap elevation and releasing. H) De-epithelialization of the anatomical papillae and occlusal ridge. I) Connective tissue grafts from the lateral palate and from the tuberosity. J) Connective tissue grafts in place. K-L) Stabilization of the graft from the lateral palate to the periosteum and de-epithelialized occlusal ridge. M) Stabilization of the graft from the tuberosity over the occlusal ridge and against the lateral incisor in the attempt to promote interproximal clinical attachment level gain. N) Platelet-rich fibrin membrane. O) Application of the platelet-rich fibrin membrane over the grafts prior to flap suturing. P) Flap closure.

Figure 2. A-C) Frontal, lateral and occlusal view at baseline. D-F) Outcomes at 6 months with temporary crowns. G-I) Outcomes at 12 months. Note that the implant was left submerged.

Figure 3. Digital workflow for the 3D assessment of volumetric changes between baseline and 1 year.

Table 1. Clinical outcomes at baseline and 1 year after vertical soft tissue augmentation

| Outcome | Baseline | 1 year | BL - 1 year* (p-value) |
|---------------------------------------------------------|-------------|-------------|---------------------------|
| PSTD depth (mean ± SD) (mm) | 2.60 ± 0.61 | 0.35 ± 0.47 | 2.25 ± 0.82 (<.001) |
| Mean PSTD coverage (mean ± SD) (%) | | | 85.14 ± 21.11 |
| PD (mean ± SD) (mm) | 2.35 ± 0.47 | 2.17 ± 0.41 | 0.17 ± 0.75 (.611) |
| CAL (mean ± SD) (mm) | 4.95 ± 0.69 | 2.58 ± 0.49 | 2.17 ± 0.68 (<.001) |
| KMW (mean ± SD) (mm) | 2.40 ± 0.77 | 3.55 ± 0.60 | 1.15 ± 1.06 (.007) |
| AM (mean ± SD) (mm) | 0.40 ± 0.52 | 1.33 ± 0.68 | 0.75 ± 0.94 (.107) |
| MT (mean ± SD) (mm) | 0.93 ± 0.12 | 2.51 ± 0.53 | 1.58 ± 0.61(<.001) |
| Midfacial REC depth adjacent teeth† (mean ± SD) (mm) | 1.55 ± 0.84 | 0.30 ± 0.41 | 1.25 ± 0.94 (<.001) |
| Midfacial PD adjacent teeth† (mean ± SD) (mm) | 1.30 ± 0.47 | 1.25 ± 0.41 | 0.05 ± 0.58 (.705) |
| Midfacial CAL adjacent teeth† (mean ± SD) (mm) | 2.85 ± 0.95 | 1.45 ± 0.54 | 1.40 ± 1.20 (<.001) |
| Midfacial KGW adjacent teeth (mean ± SD) (mm) | 2.60 ± 0.82 | 3.58 ± 0.91 | 0.98 ± 1.22 (.002) |
| Interprox. REC adjacent teeth (mean ± SD) (mm) | 1.55 ± 0.63 | 0.28 ± 0.34 | 1.28 ± 0.66 (<.001) |
| Interprox. PD adjacent teeth† (mean ± SD) (mm) | 1.78 ± 0.41 | 1.60 ± 0.45 | 0.18 ± 0.59 (.201) |
| Interprox. CAL adjacent teeth† (mean ± SD) (mm) | 3.33 ± 0.67 | 1.88 ± 0.53 | 1.45 ± 0.84 (<.001) |

Legend. AM: attached mucosa. BL: baseline. CAL: clinical attachment level. Interprox: at the interproximal aspect. KGW: keratinized gingiva width. KMW: keratinized mucosa width. MT: mucosal thickness. PD: probing depth. PSTD: peri-implant soft tissue dehiscence. REC: gingival recession. SD: standard deviation. † Data from the mesial and distal teeth were merged. *Note that the difference between the outcome measures at baseline and 1-year are given as absolute values.

Table 2. Linear dimensional changes at the midfacial aspect of the implant and peri-implant papillae evaluated from superimposition of the digital scans at baseline and 1 year after vertical soft tissue augmentation.

| Outcome | Midfacial | Papillae* |
|------------------------------|------------------|------------------|
| LD0 (mean \pm SD) (points) | 3.02 \pm 1.97 | 0.68 \pm 0.42 |
| LD1 (mean \pm SD) (points) | 3.15 \pm 2.04 | 0.99 \pm 0.52 |
| LD2 (mean \pm SD) (points) | 2.36 \pm 1.62 | 1.39 \pm 0.78 |
| LD3 (mean \pm SD) (points) | 2.19 \pm 1.21 | 1.95 \pm 0.82 |
| LD4 (mean \pm SD) (points) | 2.47 \pm 0.97 | 1.94 \pm 0.75 |
| LD5 (mean \pm SD) (points) | 2.11 \pm 1.05 | 1.75 \pm 0.60 |
| LD6 (mean \pm SD) (points) | 1.48 \pm 0.96 | 1.14 \pm 0.79 |
| LD7 (mean \pm SD) (points) | 1.57 \pm 0.85 | 1.11 \pm 0.76 |
| LD8 (mean \pm SD) (points) | 1.59 \pm 0.90 | 1.19 \pm 0.86 |

Legend. LD: linear dimensional changes. SD: standard deviation. *Data from the mesial and distal papilla were merged.

Table 3. Esthetic outcomes evaluated with the Implant Dehiscence coverage Esthetic Score (IDES) at 1 year after vertical soft tissue augmentation

| Outcome | 1 year |
|-------------------------------------|-----------------|
| STM (mean \pm SD) (points) | 3.80 \pm 1.55 |
| PPH (mean \pm SD) (points) | 1.80 \pm 1.03 |
| PMC (mean \pm SD) (points) | 0.70 \pm 0.48 |
| PMA (mean \pm SD) (points) | 0.60 \pm 0.52 |
| Final IDES (mean \pm SD) (points) | 6.90 \pm 2.33 |

Legend. PMA: peri-implant mucosa appearance. PMC: peri-implant mucosa color. PPH: peri-implant papillae height. SD: standard deviation. STM: level of the soft tissue margin.

Tavelli Lorenzo (Orcid ID: 0000-0003-4864-3964)
Wang Hom-Lay (Orcid ID: 0000-0003-4238-1799)
Barootchi Shayan (Orcid ID: 0000-0002-5347-6577)

Author Manuscript

Figure 1. Vertical soft tissue augmentation with submerged implant healing for the treatment of a peri-implant soft tissue dehiscence with adjacent teeth exhibiting interproximal attachment loss and gingival recession. A-C) Baseline. D) Crown and abutment removal. E) Flap design, with a horizontal incision on the buccal mucosa and two divergent vertical incisions. F) Split-thickness flap elevation, except for the midfacial portion of the natural teeth that was raised full-thickness until exposing the bone crest. G) Occlusal view after flap elevation and releasing. H) De-epithelialization of the anatomical papillae and occlusal ridge. I) Connective tissue grafts from the lateral palate and from the tuberosity. J) Connective tissue grafts in place. K-L) Stabilization of the graft from the lateral palate to the periosteum and de-epithelialized occlusal ridge. M) Stabilization of the graft from the tuberosity over the occlusal ridge and against the lateral incisor in the attempt to promote interproximal clinical attachment level gain. N) Platelet-rich fibrin membrane. O) Application of the platelet-rich fibrin membrane over the grafts prior to flap suturing. P) Flap closure.

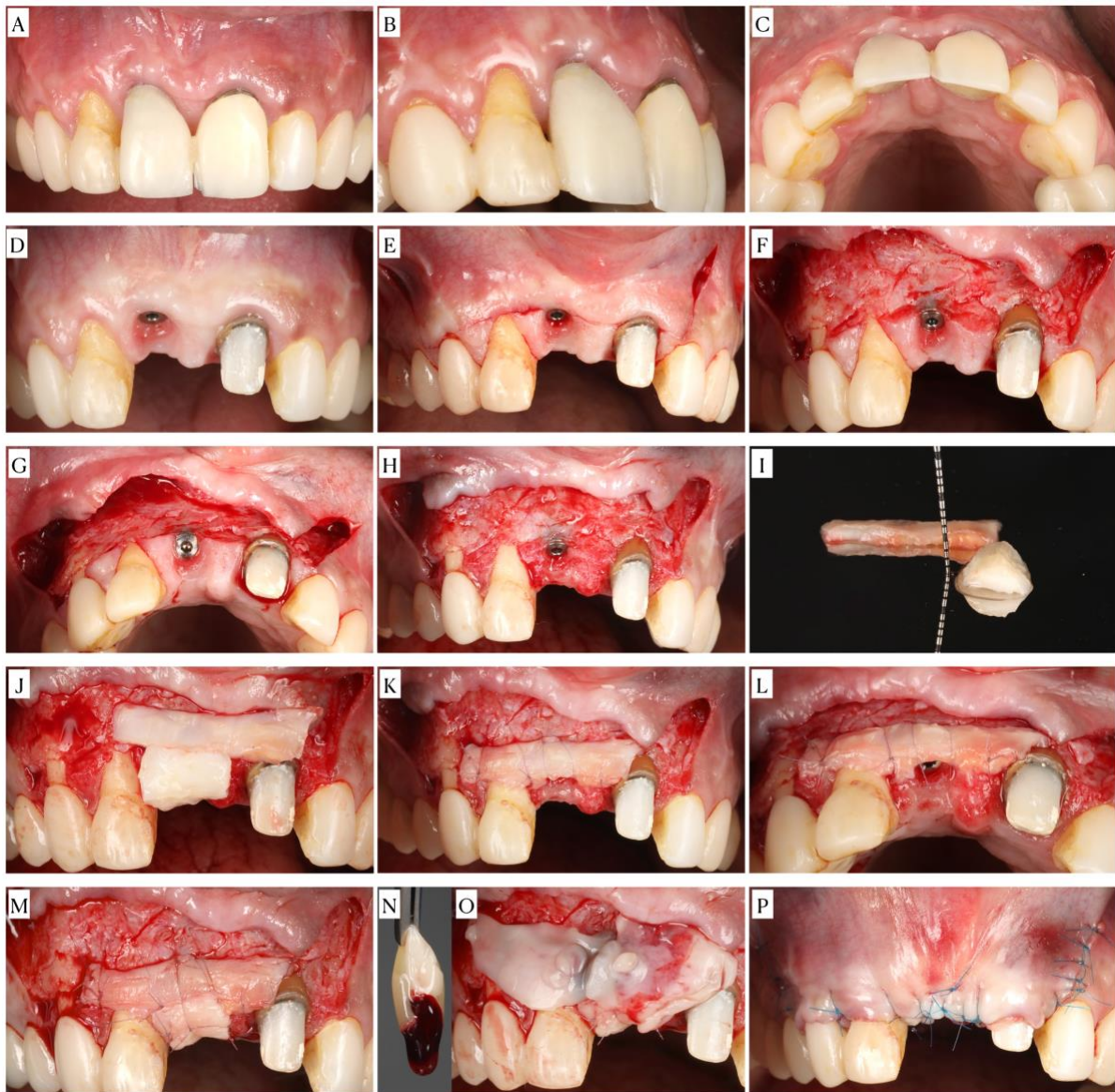


Figure 2. A-C) Frontal, lateral and occlusal view at baseline. D-F) Outcomes at 6 months with temporary crowns. G-I) Outcomes at 12 months. Note that the implant was left submerged.

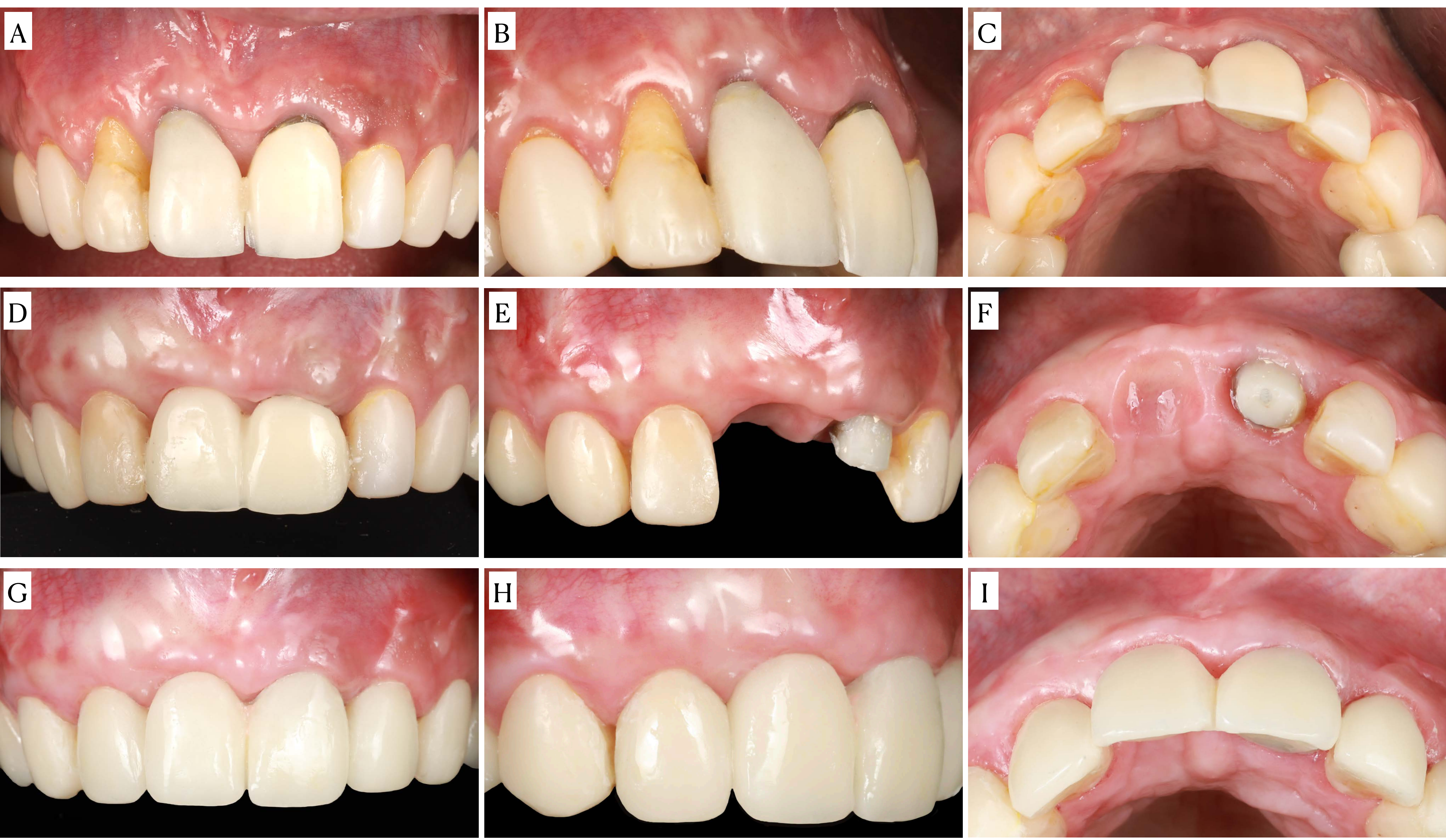
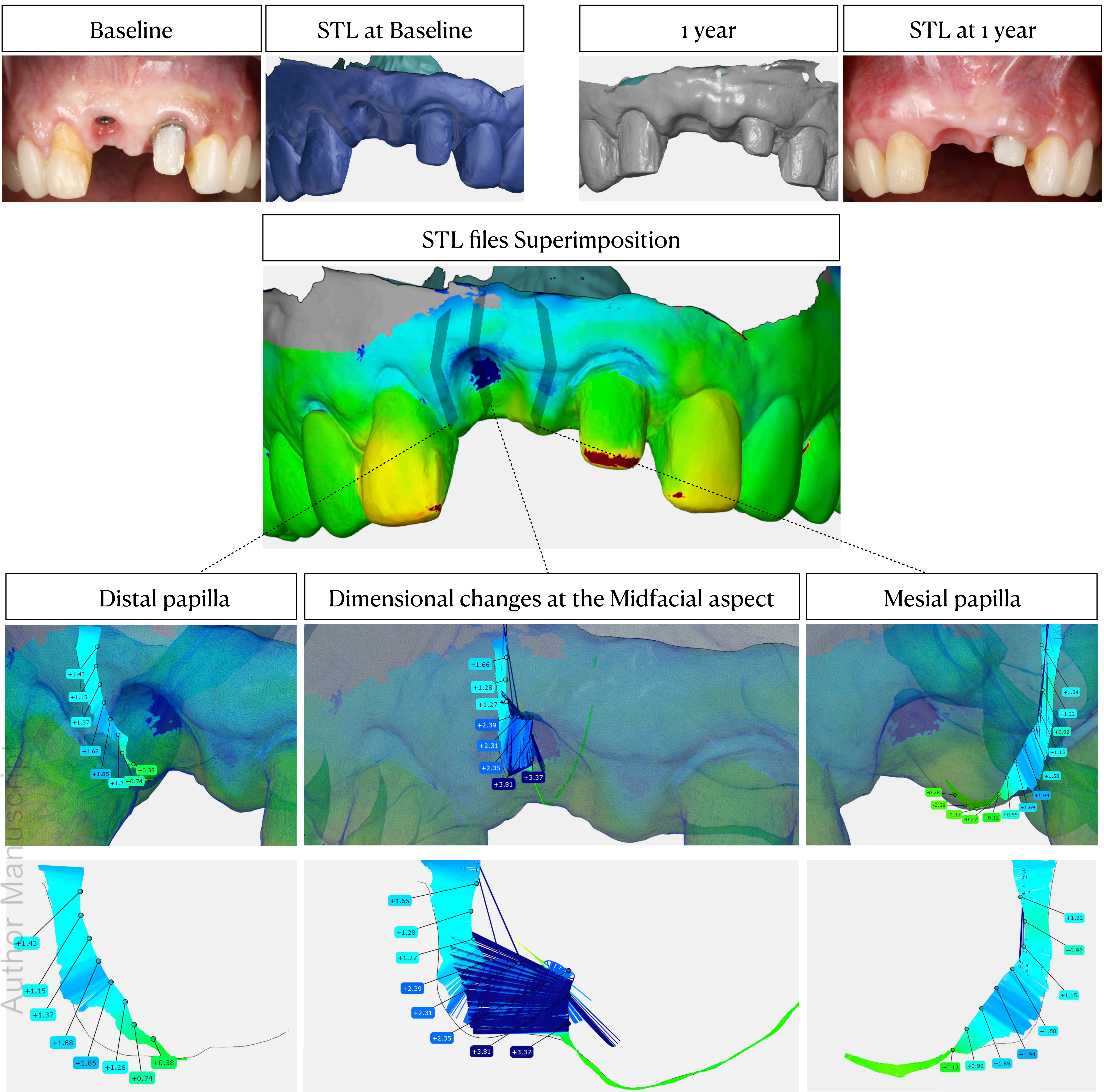


Figure 3. Digital workflow for the 3D assessment of volumetric changes between baseline and 1 year.



Author Manuscript