

## REVIEW ARTICLE

# Clinical considerations in the surgical management of peri-implantitis lesions in the esthetic zone

Alberto Monje DDS, MS, PhD<sup>1,2</sup>  | Paulo F. Mesquita DDS<sup>3</sup>

<sup>1</sup>Department of Periodontology, Universidad Internacional de Catalunya, Barcelona, Spain

<sup>2</sup>Department of Periodontology, School of Dental Medicine, University of Michigan, Ann Arbor, USA

<sup>3</sup>Private Practice, Sao Paulo, Brazil

## Correspondence

Alberto Monje, Department of Periodontology, Universitat Internacional de Catalunya, C/ Josep Trueta s/n, 08195 - Sant Cugat del Vallès (Barcelona), Spain.  
Email: [amonjec@umich.edu](mailto:amonjec@umich.edu)

## Abstract

**Objective:** The treatment of peri-implantitis is commonly associated to soft tissue changes as part of disease resolution. These changes may alter harmony in the esthetic area, and thus may negatively affect patient satisfaction. This technical note presents the key features that may lead to an unsatisfactory esthetic outcome when managing peri-implantitis in the anterior zone.

**Clinical Significance:** It is essential to consider four pivotal elements in securing therapeutic success through the resolution of inflammation while maintaining esthetics: (1) patient-related factors, including patient willingness to treat and the smile line; (2) implant-related factors that influence implant position; (3) site-related factors related to defect configuration; and (4) prosthetic-related factors referred to the prosthetic emergence profile and the type of prosthesis. A comprehensive examination must be carried out preoperatively to assess the impact of the surgical treatment upon the esthetic outcomes.

**Conclusion:** The clinician must be aware of the key features that condition the esthetic outcome when managing peri-implantitis.

## KEYWORDS

alveolar bone loss, dental implant, dental implantation, peri-implant endosseous healing, peri-implantitis

## 1 | INTRODUCTION

Peri-implantitis is regarded as an inflammation disorder characterized by the colonization of bacteria that leads to tissue breakdown.<sup>1</sup> A key aspect to understand about this disorder is its site-specific onset and progression as reported by epidemiological studies.<sup>2</sup> In other words, certain local factors have been identified as predisposing to or precipitating peri-implantitis. These aspects have to be addressed for the efficient primary/secondary prevention of the disease, and also for the precise management of peri-implantitis.

The aim of treatment in peri-implantitis is to resolve the soft tissue inflammation and arrest progressive bone loss. Therefore, given the shortcomings of nonsurgical therapy, surgical access is often

advocated to efficiently remove the biofilm adhered to the contaminated implant surface. In fact, various surgical modalities have been proposed according to the peri-implantitis bone configuration or soft tissue characteristics, among other aspects.<sup>3</sup> Nevertheless, it is worth noting that evidence on the superiority of any given strategy is sparse. On the other hand, long-term tissue stability after the lesions have been treated does not seem to be completely foreseeable. Hence, caution must be exercised in establishing the treatment prognosis based on local and systemic characteristics.

A major drawback in the management of periodontal and peri-implant bone lesions is referred to the esthetic sequelae—namely mucosal recession. Volumetric studies have demonstrated that the peri-implant mucosa undergoes considerable changes no matter what

This is an open access article under the terms of the [Creative Commons Attribution](https://creativecommons.org/licenses/by/4.0/) License, which permits use, distribution and reproduction in any medium, provided the original work is properly cited.

© 2022 The Authors. *Journal of Esthetic and Restorative Dentistry* published by Wiley Periodicals LLC.

type of strategy is used to manage peri-implantitis.<sup>4,5</sup> In fact, it is often clinically desired to induce soft tissue recession with the aim of reducing the depth of the pathogenic pocket. However, this could lead to esthetic disharmony and represent a major concern in the anterior zone.<sup>6,7</sup> Thus, it is of crucial relevance to critically evaluate the factors in the management of peri-implantitis that may impact upon the esthetic outcome.

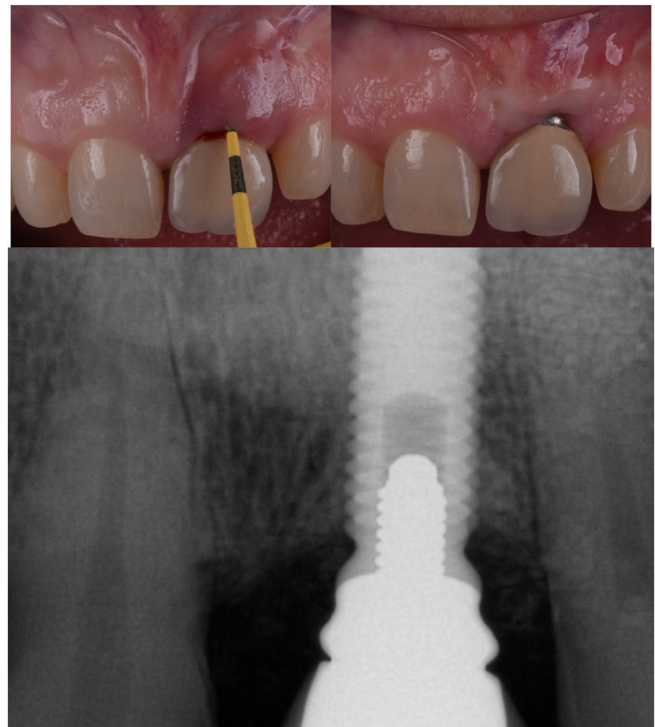
The objective of this paper is to illustrate the potential limitations and clinical sequelae of peri-implantitis and its management, along with the patient-, prosthetic-, implant- and site-specific features to be considered for the effective clinical resolution of peri-implantitis, without compromising esthetic satisfaction on the part of the patient.

## 2 | CLINICAL SEQUELAE OF PERI-IMPLANTITIS

Peri-implantitis courses with soft tissue breakdown and progressive bone loss.<sup>1</sup> Interestingly, approximately 55% of all peri-implantitis bone defects exhibit 2/3-wall defect morphology, where the buccal bone is often the missing wall. In terms of severity, peri-implantitis lesions often (approximately 50%) exhibit moderate (>25%–50%) bone loss.<sup>8</sup> The clinical significance of these findings is that tissue is thickened due to inflammation in the area where bone has been resorbed. This may mask the inflammatory process. For this reason, periodic probing is encouraged to identify bone loss as a consequence of peri-implantitis.<sup>9</sup> It must be kept in mind that in the case where the implant is positioned outside of the bony housing or below the critical buccal bone thickness, peri-implantitis may lead to mucosal recession/dehiscence.<sup>10</sup> In fact, experimental and clinical studies have demonstrated that peri-implantitis is often associated with mucosal recession. Obreja et al. (2021)<sup>11</sup> showed that 31% of all implant sites exhibit mucosal recession in subcrestally placed implants. In turn, Romandini et al.<sup>12</sup> noted that implants with peri-implantitis had significantly greater mean mucosal recession than healthy/mucositis implants (20.3%). Tavelli et al.<sup>13</sup> showed the presence of an adjacent implant, a longer time of the implant in function, limited mucosal thickness, reduced keratinized mucosa, and inadequate implant position to be significantly associated to the presence of mucosal recession. A preclinical study by Monje et al.<sup>10</sup> validated that implants that exhibit inadequate buccal bone thickness (<1.5 mm) tend to exhibit greater mucosal recession when peri-implantitis is experimentally induced.

## 3 | CLINICAL SEQUELAE OF THE MANAGEMENT OF PERI-IMPLANTITIS

The therapeutic aim in the management of peri-implantitis is the resolution of soft tissue inflammation (i.e.,  $\leq 5$  mm probing pocket depth, with no profuse bleeding/suppuration on probing) and the arresting of progressive bone loss.<sup>14</sup> The therapeutic strategy is defined according to the defect morphology, among other factors. In the case of (partially) contained defects, reconstructive measures using regenerative strategies might be indicated. In these scenarios, however, the idea is to



**FIGURE 1** The surgical treatment of peri-implantitis often results in mucosal recession once the disorder is resolved. Esthetic disharmonies are not necessarily inconsistent with successful anti-infective outcomes. Features such as the unwillingness of the patient to modify the prosthesis or inadequate buccolingual or apico-coronal implant positions may dictate the esthetic outcome. (A) Baseline examination showing profuse bleeding on probing and a pocket depth incompatible with health. (B) Disease resolution at 15-month follow-up. Note the abutment resulting in esthetic disharmony. (C) Radiographic bone filling is noted after reconstructive treatment.

resolve inflammation and augment peri-implant support. No matter what therapeutic modality is used, however, the reduction of probing pocket depth should be seen as the primary endpoint. In this sense, it is well understood that after periodontal or peri-implant therapy, recession as a consequence of the resolution of inflammation is to be expected (Figure 1).<sup>15</sup> Ramanauskaite et al.,<sup>5</sup> in a preclinical canine study, underlined that the treatment of peri-implantitis is associated to soft tissue changes (i.e., mucosal recession), which can be further aggravated in surgical versus nonsurgical therapeutic modalities. The horizontal soft tissue dimensions, nonetheless, do not differ between different surgical therapeutic strategies (implantoplasty and/or reconstructive therapy).<sup>4</sup> In this context, it seems that the presence/lack of keratinized mucosa at the buccal aspect of the peri-implantitis implants plays a pivotal role in soft tissue dimensional changes.<sup>13</sup>

## 4 | DEFINING THE PROBLEM

To sum up the above, peri-implantitis often leads to mucosal recession, and the management of peri-implantitis further contributes to

**TABLE 1** Factors to be assessed when assigning a prognosis in peri-implantitis implants in the esthetic area.

| Factor             | Favorable feature                     | Unfavorable feature                            |
|--------------------|---------------------------------------|--|
| Patient-related    | Low smile line                        | High smile line                                |
|                    | Willingness to treat                  | Unwillingness to treat                         |
|                    | Esthetic unawareness                  | Esthetic awareness                             |
| Implant-related    | Within the bony housing               | Outside the bony housing                       |
|                    | ≥3 mm apical to adjacent CEJ          | Shallow compared to adjacent CEJ               |
| Site-related       | Type I defect morphology <sup>a</sup> | Type II or III defect morphology <sup>a</sup>  |
|                    | Mild severity (<25%)                  | Moderate (25%–50%) or advanced (≥50%) severity |
|                    | No mucosal deformity                  | Buccal soft tissue dehiscence                  |
|                    | Keratinized mucosa (≥2 mm)            | No keratinized mucosa (<2 mm)                  |
|                    | Thick mucosa (≥2 mm)                  | Thin mucosa (<2 mm)                            |
|                    | Interproximal attachment integrity    | Interproximal attachment loss                  |
| Prosthesis-related | Hybrid or removable prosthesis        | Fixed non-hybrid prosthesis                    |
|                    | Adequate emergence profile            | Excessive convex/concave emergence profile     |

Abbreviation: CEJ, cementoenamel junction.

<sup>a</sup>Defect morphology classification according to Monje et al. (2019).<sup>8</sup>

such recession. While this event is often desired in posterior areas in order to assist in probing pocket depth reduction and in generating sufficient room for interproximal access during self-performed oral hygiene measures, it constitutes an undesired and limiting event in the esthetic area.

## 5 | CLINICAL ASPECTS TO CONSIDER IN THE ESTHETIC AREA

A number of patient-,<sup>16</sup> implant-,<sup>7,17</sup> site-related,<sup>7,18</sup> and prosthetic-related<sup>19</sup> factors have to be considered prior to establishing an esthetic therapeutic prognosis when managing peri-implantitis. These factors are incorporated to decision making of the cases illustrated below (Table 1, Figure 2). In order to identify the leading features, comprehensive intra- and extra-oral assessments must be carried out. Moreover, the patient perspectives, including willingness to treat and esthetic concerns, should be identified during the initial anamnesis in order to define the prognosis and treatment planning accordingly.

As aforementioned, the first factor to check is patient's willingness. If the patient manifests unwillingness or has a high esthetic demand, it is not recommended to manage peri-implantitis by surgical

means, unless the vast majority of the favorable factors listed in Table 1 are met. If, on the contrary, the patient favors treatment, the implant exhibits a type I defect configuration and it is within the alveolar envelope and in an adequate apico-coronal implant position, surgical therapy is advocated (if unresolved the lesion after the non-surgical phase). Defect configurations type II and III are more prone to exhibit esthetic disharmonies after therapy. The situations where can be managed without altering significantly the esthetic outcome is when the given infected implants support a hybrid fixed prosthesis or retain an overdenture that could mask the mucosal sequelae. Then, the clinician must assess defect severity. Advanced lesions do not predictably resolve,<sup>20</sup> thus in these scenarios it is recommended to remove the implant and start over at a later stage.<sup>21</sup> Regardless defect severity, if the interproximal periodontal/peri-implant hard tissue attachment is missing, a tendency to soft tissue collapse is anticipated. Therefore, this feature also plays a relevant role in the decision-making process. Thereafter, the soft tissues must be thoroughly explored. While the management of a soft tissue dehiscence is not indicated simultaneous to the surgical therapy of peri-implantitis, the lack of keratinized mucosa and the presence of a thin mucosal phenotype can be orchestrated simultaneously to the reconstructive therapy by means of a connective tissue graft.<sup>22</sup> It must be noted that the use of barrier membranes may limit minimal invasiveness and thus, their use may lead to greater mucosal recession while not enhancing the reconstructive outcomes.<sup>23</sup> Last but not least important, prosthesis must be assessed to guarantee an harmonious and cleansable emergence profile. If this factor is not achievable, prosthesis modification is recommended.

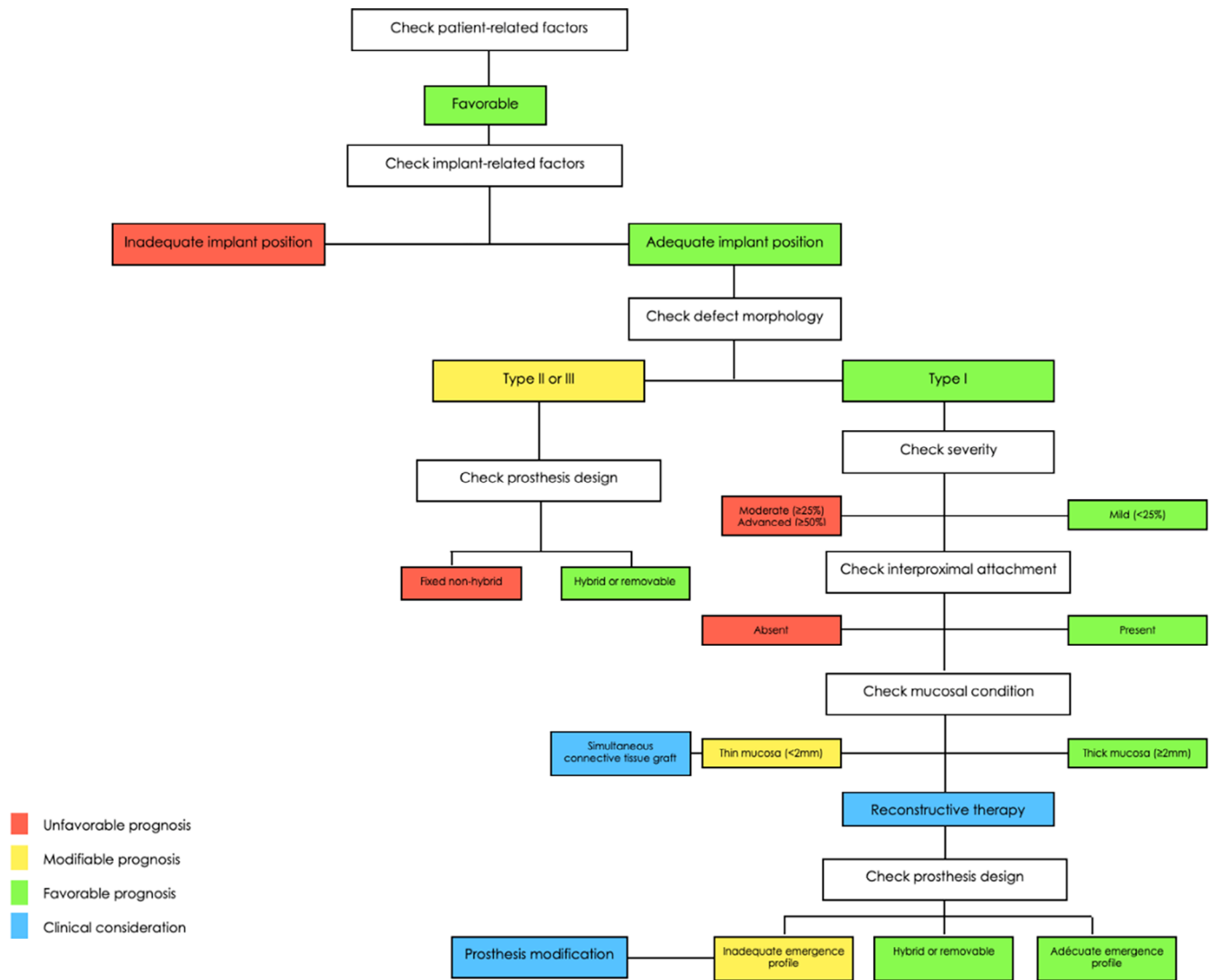
## 6 | CASE SCENARIO #1

### 6.1 | Case presentation

An implant located in the central incisor (bone level implant) and exhibiting recurrent events of spontaneous suppuration upon palpation. Based on comprehensive radiographic and clinical analyses, a class Ib peri-implantitis bone defect<sup>8</sup> within the alveolar envelope was noted. A mild bone defect as a consequence of peri-implantitis was observed. No mucosal deformity was noted.

### 6.2 | Management

A papilla preservation flap and intra-sulcular incisions of the adjacent teeth were performed to gain access. The crown was removed during the surgical procedure to enhance visibility. Granulation tissue was removed with curesttes. Considering the position of the implant within the bony envelope, surface detoxification was applied by means of a plastic-tip ultrasonic device and ethylenediaminetetraacetic acid (EDTA) for 2 min. After this procedure, the crown was tightened to the implant to reduce soft tissue



**FIGURE 2** Decision making illustrating the factors to be assessed in establishing an esthetic prognosis in the therapy of peri-implantitis in the anterior area.

alterations in the inter-proximal area. Autogenous bone harvested from the maxillary tuberosity was used as bone grafting material. Enamel matrix derivative (Straumann Emdogain®, Straumann Institut AG, Basel, CH) was applied on top to promote soft tissue healing and assist the integration of the connective tissue graft. Primary wound closure was achieved by means of single interrupted sutures. Uneventful healing was noted.

### 6.3 | Surgical outcome

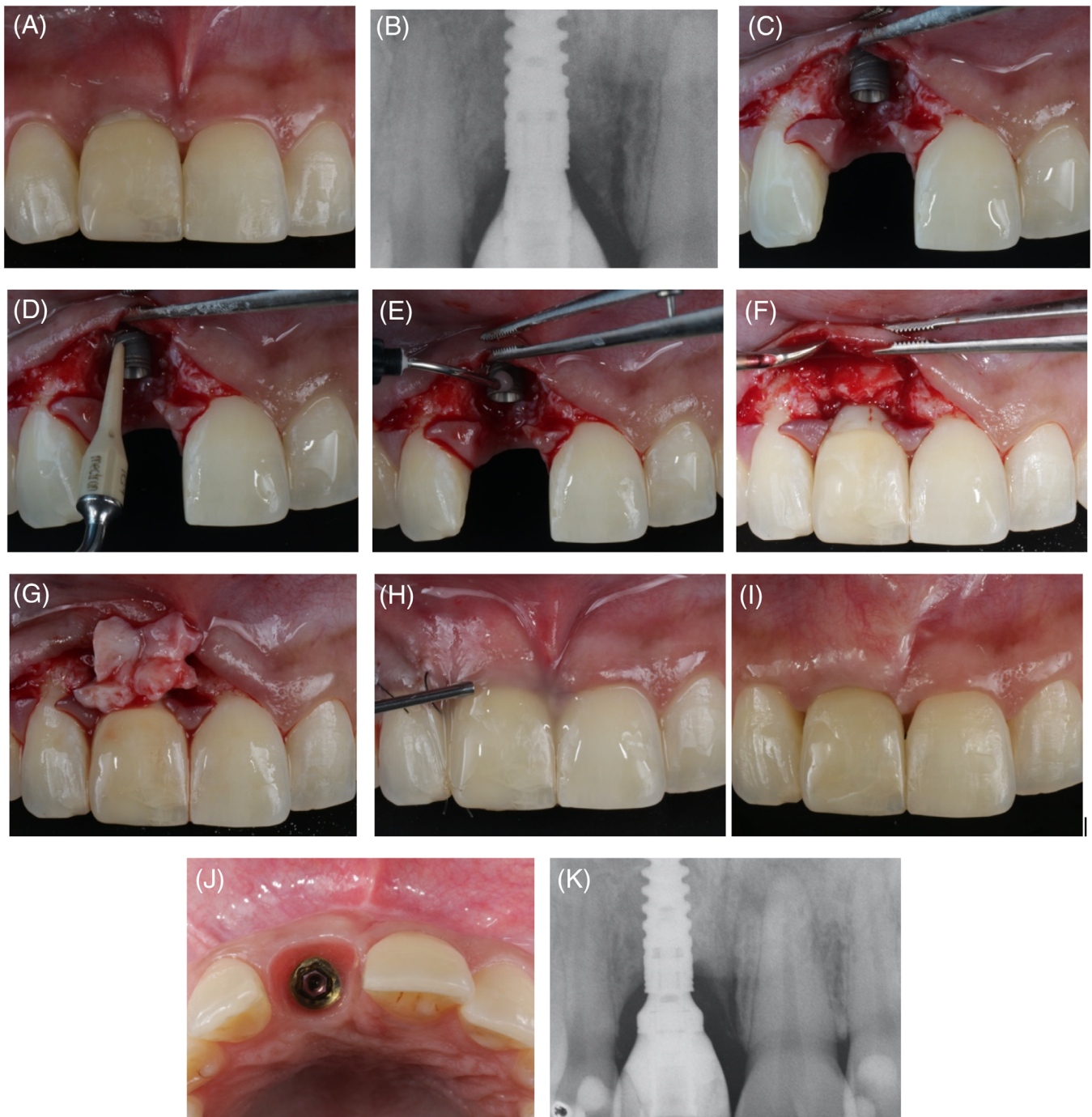
At two-year follow-up, the disease was resolved. No bleeding on probing or suppuration was present. Probing pocket depth was consistent with health. The radiographic analysis demonstrated bone filling. Disease resolution was not inconsistent with the maintenance of the esthetic emergence profile, and there were no

disharmonious features. Papilla between the two central incisors and the central and lateral incisor were classified as grade II.<sup>24</sup> Nevertheless, no mucosal recession whatsoever was noted in the mid-zone (Figure 3).

## 7 | CASE SCENARIO #2

### 7.1 | Case presentation

An implant located in the central incisor (tissue level implant) exhibiting abscess and moderate bone loss as a consequence of peri-implantitis. Based on comprehensive radiographic and clinical analyses, a class Ib<sup>4</sup> peri-implantitis bone defect within the alveolar envelope was noted. No mucosal deformity was observed, though the level of local inflammation was high.

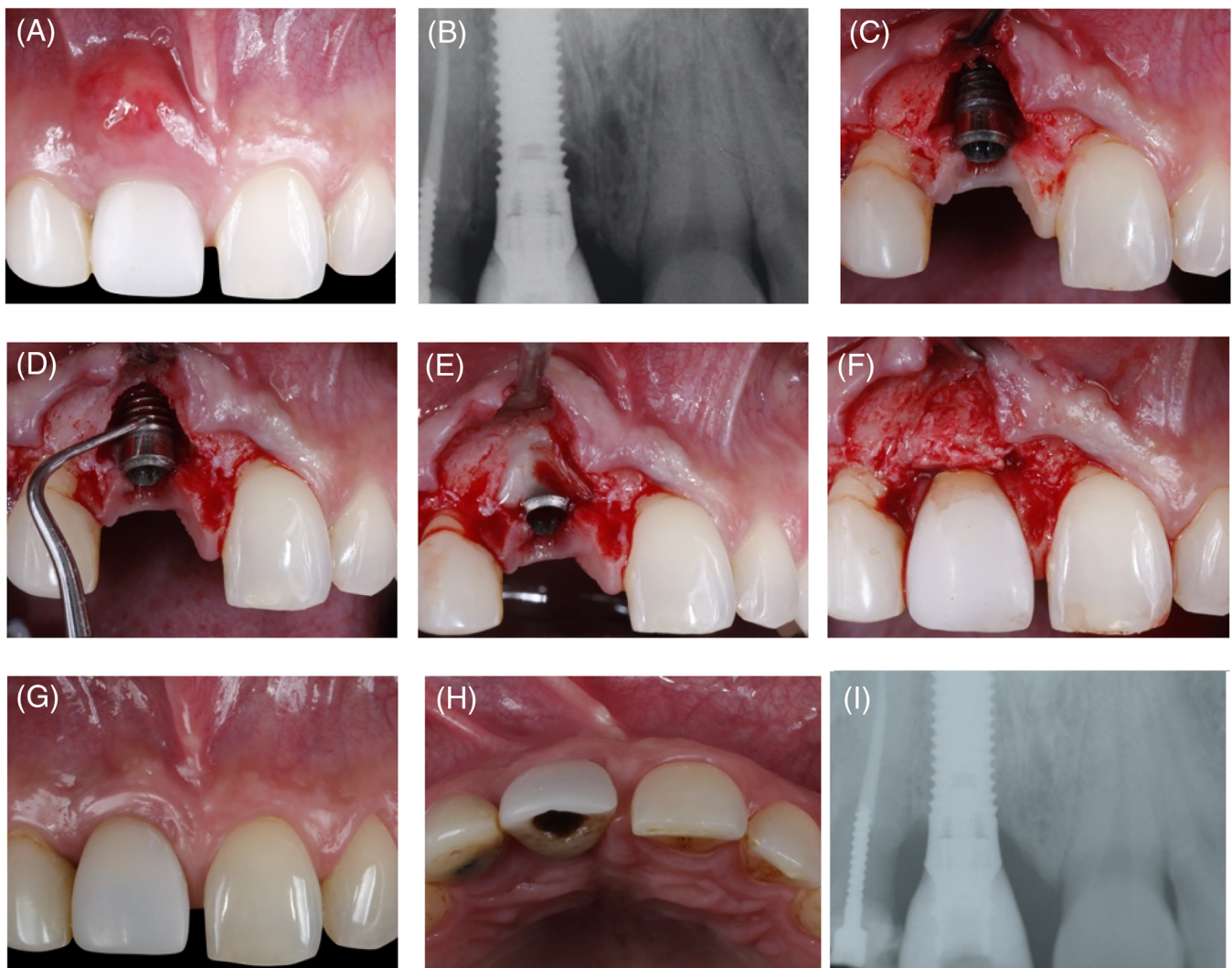


**FIGURE 3** (A) Bone level implant located in the central incisor (exhibiting recurrent events of spontaneous suppuration under palpation). (B) Periapical x-ray showing peri-implant bone loss (C) Note the class Ib peri-implantitis bone defect where the implant is within the alveolar envelope. A papilla preservation flap and intra-sulcular incisions of the adjacent teeth are performed to gain access. (D-E) Surface detoxification is applied by means of a plastic-tip ultrasonic device and ethylenediaminetetraacetic acid (EDTA) for 2 min. (F) Autogenous bone harvested from the maxillary tuberosity is used as bone grafting material. (G) A connective tissue graft is used to compensate the thin mucosal phenotype (H) Enamel matrix derivative was applied on top to promote soft tissue healing. (I-J) Disease resolution at two-year follow-up is noted (buccal and occlusal views), without significant esthetic sequelae. (K) Radiographic analysis showing bone filling.

## 7.2 | Management

A papilla preservation flap and intra-sulcular incisions of the adjacent teeth were performed to gain access. The crown was removed during

the surgical procedure to enhance visibility. Granulation tissue was removed with curettes. Considering the position of the implant within the bony envelope, surface detoxification was applied by means of a plastic-tip ultrasonic device and ethylenediaminetetraacetic acid



**FIGURE 4** (A) Tissue level implant located in the central incisor, exhibiting abscess and moderate bone loss as a consequence of peri-implantitis. (B) Periapical x-ray exhibiting bone loss (C) Note the flap elevation class Ib peri-implantitis bone defect with an implant within the alveolar envelope. A papilla preservation flap and intra-sulcular incisions of the adjacent teeth are performed to gain access. (D-E) Considering the position of the implant within the bony envelope, surface detoxification is applied by means of an ultrasonic device and ethylenediaminetetraacetic acid (EDTA) for two minutes. (F) Autogenous bone harvested from the maxillary tuberosity is used as bone grafting material. (G) Frontal and (H) occlusal views showing disease resolution without major esthetic alterations. (I) Bone filling was achieved as evidenced by the radiographic analysis.

(EDTA) for 2 min. After this procedure, the crown was tightened to the implant to reduce soft tissue alterations in the inter-proximal area. Autogenous bone harvested from the maxillary tuberosity was used as bone grafting material. Primary wound closure was achieved by means of single interrupted sutures. Uneventful healing was noted.

### 7.3 | Surgical outcome

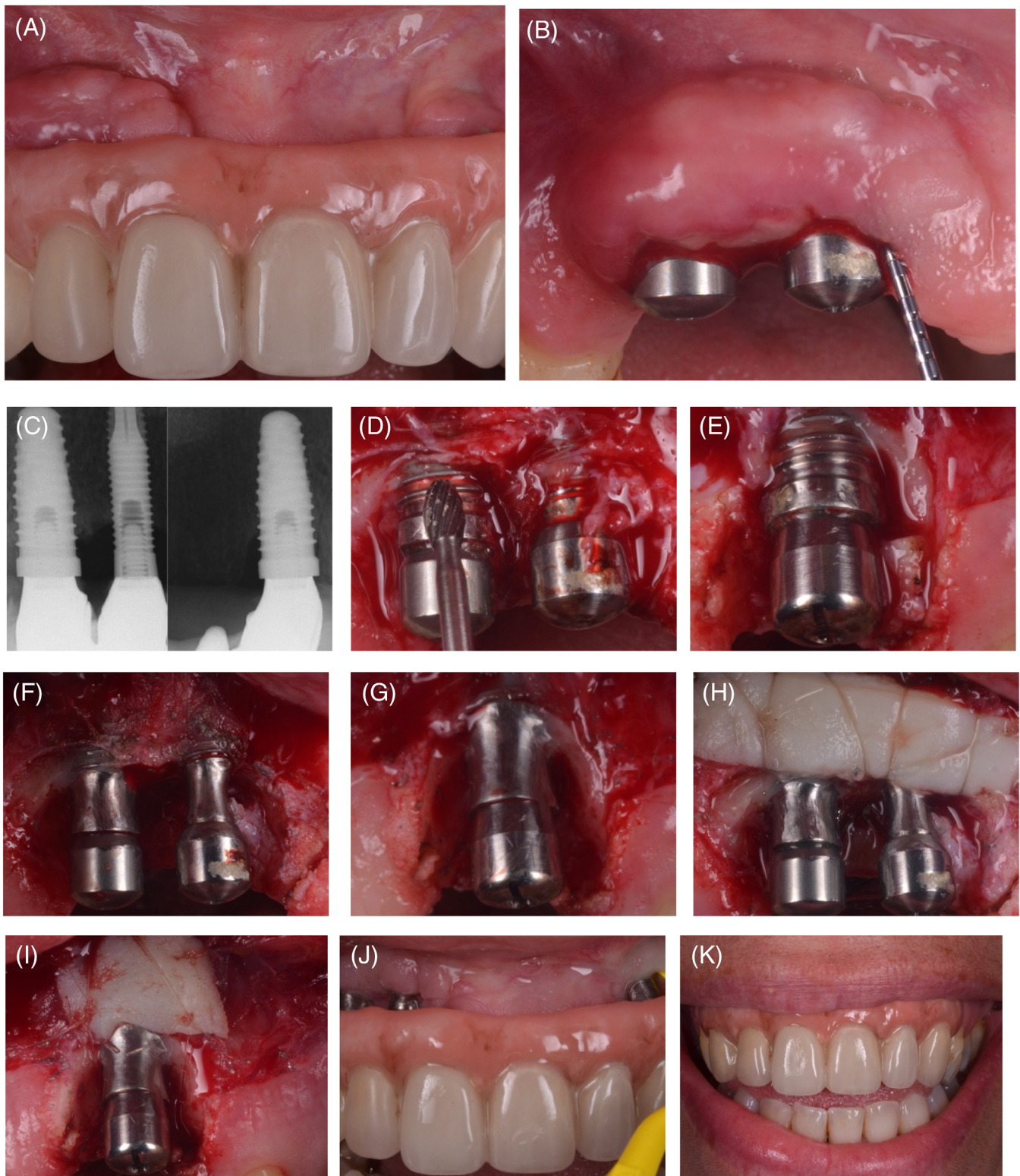
At 6-year follow-up, the disease was completely resolved. No bleeding on probing or suppuration was present, and probing pocket depth was consistent with health. Bone filling was achieved according to the radiographic analysis. No mucosal recession in the mid-zone was

noted. The interproximal papilla between the two central incisor was designated as grade I, while the distal papilla corresponded to grade II (Figure 4).<sup>24</sup> The patient reported complete satisfaction.

## 8 | CASE SCENARIO #3

### 8.1 | Case presentation

Implants supporting an implant-supported fixed hybrid prosthesis for the replacement of the anterior teeth, exhibiting peri-implantitis and granulomatous lesions. Note that the prosthesis design was inconsistent with self-performed oral hygiene. Radiographic analysis revealed



**FIGURE 5** (A–C) Implants supporting an implant-supported fixed hybrid prosthesis for replacement of the anterior teeth, exhibiting peri-implantitis and granulomatous lesions. Note that the prosthesis design is inconsistent with self-performed oral hygiene. (D–G) Flap access revealed class II peri-implantitis bone defect morphology in implants slightly outside of the bony housing. Osteotomy and osteoplasty to flatten the bone architecture and implantoplasty in the supra-crestal defect were performed. Implantoplasty was performed with tungsten carbide burs followed by Arkansas and silicone polishing burs. (H–I) Soft tissue conditioning is carried out by means of free epithelialized mucosal grafts, as described elsewhere. Surgical outcome: (J) Disease resolution was noted at one-year follow-up. Note that the buccal band of keratinized mucosa and vestibular depth are significantly increased. (K) Smile analysis showed no interference with patient satisfaction due to the presence of a hybrid prosthesis. Source: Reprinted with permission from Monje et al.<sup>28</sup>

moderate bone loss, and class II peri-implantitis bone defect morphology was noted. The implants were slightly outside of the bony housing.

## 8.2 | Management

The prosthesis was removed, and healing abutments were placed to enhance visibility. Due to the nature of the defects, minor osteotomy and osteoplasty to flatten the bone architecture and implantoplasty in the supra-crestal defect were performed. Implantoplasty was indicated to reduce bacterial recolonization during follow-up and to foster a healthier ecosystem. It was performed with tungsten carbide burs (Hager & Meisinger GmbH, Neuss, Germany), followed by Arkansas and silicone polishing burs. The flap was then apically repositioned. Simultaneously, soft tissue conditioning was carried out by means of free epithelialized mucosal grafts, as described elsewhere.<sup>25</sup> These were secured by means of single interrupted and subperiosteal mattress sutures.

## 8.3 | Surgical outcome

At one-year follow-up, the disease was completely resolved. No bleeding or suppuration was present. The buccal band of keratinized mucosa and buccal depth were significantly increased. Sufficient space for self-performed oral hygiene was noted. Smile analysis revealed no interference with patient satisfaction due to the presence of a hybrid prosthesis. The patient was completely satisfied (Figure 5).

## 9 | DISCUSSION

The resolution of inflammation is associated with mucosal changes. In fact, from the biological perspective, mucosal recession is desired to reduce peri-implant pocket depth. Nevertheless, this may alter patient satisfaction and proves critical in the anterior area in patients with high esthetic demands. Therefore, comprehensive assessment and the accurate designation of a prognostic score are crucial to success. The purpose of this technical note was to describe the factors and features associated with the esthetic prognosis when surgically managing peri-implantitis.

### 9.1 | Patient-related factors

During the initial interview, it is crucial to inform the patient about the potential interferences with esthetics as part of the sequelae when managing peri-implantitis. If the esthetic demands are high and the patient is not in favor of altering the mucosa, the prognosis is hopeless. Accordingly, the advocated treatment plan is to remove the implant and start over hard and soft tissue reconstruction for implant site development.<sup>21</sup> Other factors that must be cautiously evaluated if

the patient is willing to treatment is the smile line. If the smile line is high, it may lead to severe disturbances with esthetics. Hence, if this is indeed the case, then clinicians should encourage the patient to have the implant removed, even if the desire is to maintain the implant - particularly in scenarios where other implant-, site- and prosthetic-related factors cause significant mucosal disharmony to be expected.

### 9.2 | Implant-related factors

The implant position must be assessed based on two-dimensional or preferably three-dimensional radiographic analysis. In scenarios exhibiting implants outside of the bony housing or too shallow in position, achieving esthetic outcomes is challenging, since there is no reparative potential, and approaches seeking to displace the mucosal margin apically should be indicated in order to reduce pocket depth. Hence, implant removal is recommended in these scenarios. It must be noted that implants outside of the bony housing are often manageable with a satisfactory esthetic outcome by means of angled and customized abutments and connective tissue grafts combined with coronally advanced flaps.<sup>7,17</sup> In order to address the prognosis in implants placed in an inadequate buccolingual position, four factors must be evaluated: vestibular depth, the width of keratinized mucosa, and defect morphology and severity. Moderate and advanced forms of peri-implantitis in implants placed outside of the bony housing have an unfavorable prognosis in terms of esthetics. Likewise, the lack of keratinized mucosa and vestibular depth may limit the maneuvers to maintain the mucosal margin in a harmonious position.

### 9.3 | Site-related factors

Defect morphology and severity dictate the sequelae in the management of peri-implantitis. Class II and III defect morphologies are characterized by inter-proximal bone loss, as they exhibit a supracrestal defect,<sup>8</sup> while class I defects are characterized by various bony peaks coronal to or at the same level of the implant shoulder. Therefore, reconstructive therapy is suitable in these scenarios, and the potential to minimize apical mucosal migration is greater. Class I defects therefore are prone to exhibit favorable clinical and radiographic outcomes applying reconstructive measures.<sup>26</sup> In these scenarios, the use of barrier membranes might not be encouraged considering the following facts: (1) type I defect configuration often provide sufficient stability to bone graft, (2) the surgical invasiveness demanded to establish a barrier membrane is often higher, and (3) the benefit of using barrier membranes in the reconstructive therapy of peri-implantitis is not evidence-based supported.<sup>23</sup>

Moreover, existing mucosal defects such as papilla loss or marginal recession are associated to poorer outcomes.<sup>7</sup> These clinical findings are often aligned with the mucosal phenotype.<sup>18</sup> Therefore, it is encouraged to assess mucosal thickness and the band of keratinized mucosa. While it is proposed that the prognosis from the esthetic



perspective is poorer in the lack of these elements, the use of soft tissue grafts to modify the peri-implant phenotype may lead of more favorable outcomes (see Figure 3). Other strategy to consider in these scenarios is prosthesis modification to compensate the mucosal collapse. Otherwise, esthetics and phonetics may be impaired.

## 9.4 | Prosthesis-related factors

These are the most flexible factors, as they often allow for modifications if the patient is willing to accept them in the case of an inadequate emergence profile. In fact, convex prosthesis designs are associated with mucosal recession<sup>19</sup> and peri-implantitis.<sup>27</sup> Hence, if the above is the scenario and other factors are favorable, it is convenient to modify the prosthesis emergence profile to improve the esthetic outcome and prevent disease recurrence. In addition, hybrid prostheses frequently offer the opportunity to perform respective approaches as long as the patient is not exhibiting a high smile line. If peri-implantitis is associated to an inadequate prosthesis that precludes effective self-performed oral hygiene measures, the prosthesis should be subjected to modifications in order to enhance access.

## 10 | CONCLUSIONS

The surgical management of peri-implantitis often results in mucosal recession as part of disease resolution, and which may interfere with esthetics. Therefore, the clinician must be aware of the key features that condition the esthetic outcome when managing peri-implantitis.

## DISCLOSURE

The authors declare that they do not have any financial interest in the companies whose materials are included in this article.

## DATA AVAILABILITY STATEMENT

The authors confirm that the data supporting the findings of this study are available within the article [and/or] its supplementary materials.

## ORCID

Alberto Monje  <https://orcid.org/0000-0001-8292-1927>

## REFERENCES

- Schwarz F, Derks J, Monje A, Wang HL. Peri-implantitis. *J Periodontol*. 2018;89(Suppl 1):S267-S290.
- Rakic M, Galindo-Moreno P, Monje A, et al. How frequent does peri-implantitis occur? A systematic review and meta-analysis. *Clin Oral Investig*. 2018;22:1805-1816.
- Suarez F, Monje A, Galindo-Moreno P, Wang HL. Implant surface detoxification: a comprehensive review. *Implant Dent*. 2013;22:465-473.
- Ramanauskaitė A, Schwarz F, Sader R, Becker J, Obreja K. Assessment of peri-implant tissue dimensions following surgical therapy of advanced ligature-induced peri-implantitis defects. *Int J Implant Dent*. 2021;7:4.
- Ramanauskaitė A, Obreja K, Sader R, Becker J, Schwarz F. Assessment of soft and hard tissue dimensions following different treatment approaches of ligature-induced peri-implantitis defects. *Clin Oral Implants Res*. 2021;32:394-400.
- Gamborena I, Avila-Ortiz G. Peri-implant marginal mucosa defects: classification and clinical management. *J Periodontol*. 2021;92:947-957.
- Zucchelli G, Tavelli L, Stefanini M, et al. Classification of facial peri-implant soft tissue dehiscence/deficiencies at single implant sites in the esthetic zone. *J Periodontol*. 2019;90:1116-1124.
- Monje A, Pons R, Insua A, Nart J, Wang HL, Schwarz F. Morphology and severity of peri-implantitis bone defects. *Clin Implant Dent Relat Res*. 2019;21:635-643.
- Monje A, Amerio E, Farina R, et al. Significance of probing for monitoring peri-implant diseases. *Int J Oral Implantol (Berl)*. 2021;14:385-399.
- Monje A, Chappuis V, Monje F, et al. The critical Peri-implant buccal Bone Wall thickness revisited: an experimental study in the beagle dog. *Int J Oral Maxillofac Implants*. 2019;34:1328-1336.
- Obreja K, Ramanauskaitė A, Begic A, et al. The prevalence of peri-implant diseases around subcrestally placed implants: a cross-sectional study. *Clin Oral Implants Res*. 2021;32:702-710.
- Romandini M, Lima C, Pedrinaci I, Araoz A, Costanza Soldini M, Sanz M. Clinical signs, symptoms, perceptions, and impact on quality of life in patients suffering from peri-implant diseases: a university-representative cross-sectional study. *Clin Oral Implants Res*. 2021;32:100-111.
- Tavelli L, Barootchi S, Majzoub J, et al. Prevalence and risk indicators of midfacial peri-implant soft tissue dehiscence at single site in the esthetic zone: a cross-sectional clinical and ultrasonographic study. *J Periodontol*. 2021. <https://doi.org/10.1002/JPER.21-0402>. Epub ahead of print. PMID: 34787892.
- Renvert S, Giovannoli JL, Roos-Jansaker AM, Rinke S. Surgical treatment of peri-implantitis with or without a deproteinized bovine bone mineral and a native bilayer collagen membrane: a randomized clinical trial. *J Clin Periodontol*. 2021;48:1312-1321.
- Stavropoulos A, Bertl K, Sculean A, Kantarci A. Regenerative periodontal therapy in intrabony defects and long-term tooth prognosis. *Dent Clin N Am*. 2022;66:103-109.
- Kourkouta S. Implant therapy in the esthetic zone: smile line assessment. *Int J Periodontics Restorative Dent*. 2011;31:195-201.
- Tarnow DP, Chu SJ. When to save or remove implants in the smile zone: a clinical report of maxillary lateral incisor implants in malposition. *J Esthet Restor Dent*. 2021;33:194-201.
- Avila-Ortiz G, Gonzalez-Martin O, Couso-Queiruga E, Wang HL. The peri-implant phenotype. *J Periodontol*. 2020;91:283-288.
- Steigmann M, Monje A, Chan HL, Wang HL. Emergence profile design based on implant position in the esthetic zone. *Int J Periodontics Restorative Dent*. 2014;34:559-563.
- de Waal YC, Raghoobar GM, Meijer HJ, Winkel EG, van Winkelhoff AJ. Prognostic indicators for surgical peri-implantitis treatment. *Clin Oral Implants Res*. 2016;27:1485-1491.
- Monje A, Nart J. Management and sequelae of dental implant removal. *Periodontol 2000*. 2000;2022(88):182-200.
- Mazzotti C, Stefanini M, Felice P, Bentivogli V, Mounssif I, Zucchelli G. Soft-tissue dehiscence coverage at peri-implant sites. *Periodontol 2000*. 2000;2018(77):256-272.
- Roos-Jansaker AM, Persson GR, Lindahl C, Renvert S. Surgical treatment of peri-implantitis using a bone substitute with or without a resorbable membrane: a 5-year follow-up. *J Clin Periodontol*. 2014;41:1108-1114.
- Jemt T. Regeneration of gingival papillae after single-implant treatment. *Int J Periodontics Restorative Dent*. 1997;17:326-333.

25. Monje A, Blasi G, Nart J, Urban IA, Nevins M, Wang HL. Soft tissue conditioning for the surgical therapy of Peri-implantitis: a prospective 12-month study. *Int J Periodontics Restorative Dent*. 2020;40: 899-906.
26. Khoshkam V, Chan HL, Lin GH, et al. Reconstructive procedures for treating peri-implantitis: a systematic review. *J Dent Res*. 2013;92: 131S-138S.
27. Yi Y, Koo KT, Schwarz F, Ben Amara H, Heo SJ. Association of prosthetic features and peri-implantitis: a cross-sectional study. *J Clin Periodontol*. 2020;47:392-403.
28. Monje A, Rasperini G, Sanz-Sanchez I. *Unfolding peri-implantitis*. Quintessence Publishing (Monje A & Wang HL); 2022:731.

**How to cite this article:** Monje A, Mesquita PF. Clinical considerations in the surgical management of peri-implantitis lesions in the esthetic zone. *J Esthet Restor Dent*. 2023;35(3): 457-466. doi:[10.1111/jerd.12921](https://doi.org/10.1111/jerd.12921)