

## CLINICAL ARTICLE

# Comparison of the minimally-invasive roll-in envelope flap technique to the holding suture technique in implant surgery: A prospective case series

Behnam Shakibaie DDS, MS<sup>1</sup> | Hamoun Sabri DMD, PgC<sup>2,3</sup>  |  
 Marcus B. Blatz DMD, PhD<sup>4</sup>  | Shayan Barootchi DMD, MS<sup>2</sup> 

<sup>1</sup>Specialized Clinic in Microscopic Dentistry, Tehran, Iran

<sup>2</sup>Department of Periodontics and Oral Medicine, University of Michigan Dental School, Ann Arbor, Michigan, USA

<sup>3</sup>Periodontal and Implant Microsurgery Academy (PiMA), University of Michigan Dental School, Ann Arbor, Michigan, USA

<sup>4</sup>Chairman Department of Preventive and Restorative Science, School of Dental Medicine, University of Pennsylvania, Philadelphia, Pennsylvania, USA

## Correspondence

Behnam Shakibaie, Specialized Clinic in Microscopic Dentistry, Unite 23, No 122, West Soleimani Street, Andarzgon Blvd, Farmanieh, Tehran, Iran.  
 Email: [drbshakibaie@yahoo.com](mailto:drbshakibaie@yahoo.com)

## Abstract

**Objective:** The peri-implant soft tissue phenotype plays a role in the long-term success of dental implants, thus, creating the need for the application of different techniques for the management of its adjacent soft tissues. The aim of this case series was to describe and evaluate the clinical outcomes of the microsurgical roll-in-envelope flap (RIE) approach, in comparison with a more commonly used method for manipulation of the peri-implant soft tissues, namely the holding-suture flap (HS) technique.

**Materials and Methods:** 10 posterior dental implants in 10 healthy individuals were selected and randomly assigned treatment by each of the mentioned groups relative to the flap design. Mucosal thickness was measured at the time of the surgery and at 6 and 12 weeks, serving as the main outcome.

**Results:** The healing was uneventful at all sites without any patient drop-outs. The comparison of two groups revealed a three-fold reduction in the mucosal thickness in HS group compared to RIE.

**Conclusions:** In presence of sufficient periimplant supporting tissues and when indicated, the RIE flap seems to yield superior outcomes reducing pain/discomfort compared to connective tissue grafts.

## KEYWORDS

dental implant, implant microsurgery, microscope, soft tissue augmentation, tissue graft

## 1 | INTRODUCTION

With tooth loss, and regardless of its etiology, the alveolar ridge inevitably undergoes a certain amount of ridge alteration, which can cause negative effects in the local hard and soft tissues and complicate desired tooth replacement therapy.<sup>1-4</sup> Consequently, numerous challenges can occur in the accomplishment of successful implant placement and/or rehabilitation of its natural structures.<sup>5,6</sup>

The long-term success of implant therapy is a multi-factorial phenomenon with cornerstones such as implant bone level stability and the adjacent soft tissues among pertinent factors.<sup>7,8</sup> Moreover, the role

of the soft tissue phenotype has also been highlighted more in the recent years relative to its influential effect on the long-term outcomes of therapy.<sup>9,10</sup> The presence of a stable mucosal margin as well as a thicker phenotype would render positive results and decreases the chance for the occurrence of a peri-implant soft tissue dehiscence or deficiency (PSTD).<sup>11</sup> In contrast to the concept of osseointegration or an implant's secondary stability, which has shown high predictability in recent years, the prediction of the level of the peri-implant soft tissues and its response to different stimuli is still challenging.<sup>12,13</sup>

While the autogenous connective tissue graft remains the gold standard approach for increasing soft tissue thickness and

management of PSTDs,<sup>14–16</sup> in specific cases, delicate and precise manipulation of the original peri-implant soft tissues can yield the desired outcomes, in terms of providing sufficient mucosal thickness, and crucially, eliminating the need for a secondary surgical site and the resultant post-operative morbidity.<sup>17,18</sup> Therefore, the aim of this report was to describe the minimally-invasive application and modification of the roll-in-envelope flap (RIE) approach relative to a more commonly utilized holding suture (HS) method at the time of implant placement in the posterior region.

## 2 | MATERIALS AND METHODS

### 2.1 | Study design and subject recruitment

The present research was designed as a prospective pilot case series, in which a total of 10 single, posterior dental implants were placed through a one-stage approach in 10 systemically healthy and non-smoking adults. The patients were equally and randomly divided to either receive the Roll-in-Envelope Flap (RIE, group A), or the Holding Suture Flap approach (HS, group B) at the time of implant placement. Each of the participants was randomly allocated to the RIE or HS group using a computer-generated randomization list, which was performed with the aid of the clinical research staff designated in the office, which was then communicated to the clinician (B.S.).

All implant surgeries were digitally planned upon radiographic (via cone-beam computed tomography) confirmation of sufficient alveolar bone ridge on average 3.5 months after following a minimally invasive tooth extraction protocol with alveolar ridge preservation using a xenogenic bone substitute (Bio-Oss Granules, Geistlich Pharma AG, Bahnhofstrasse 40, 6110 Wolhusen, Switzerland) and a Stypro Gelatin sponge (Curasan AG, Lindigstrasse 4, 63801 Kleinostheim, Germany).<sup>19</sup>

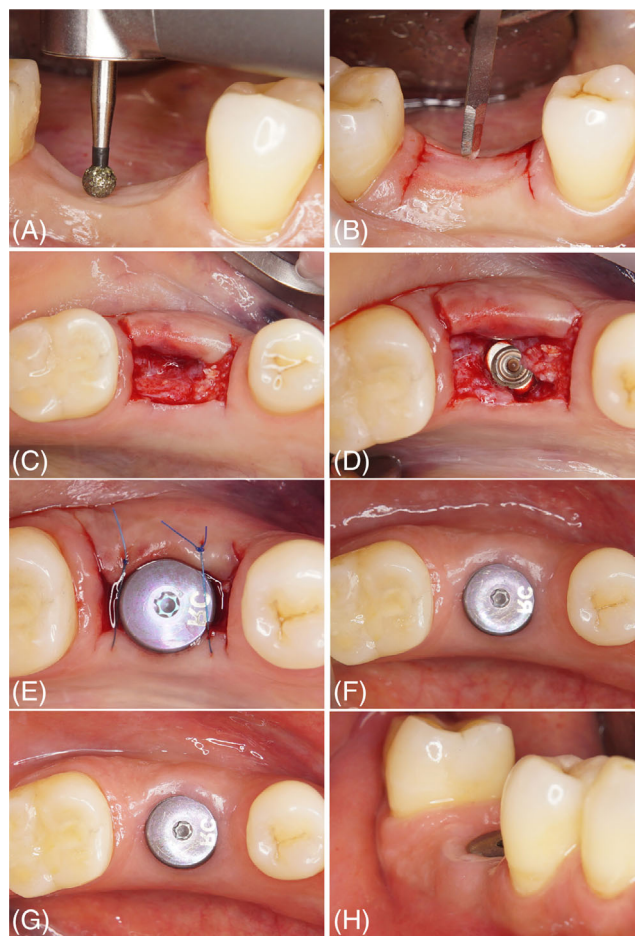
The utilized implant systems consisted of either Straumann Bone Level Tapered (Institut Straumann AG, Peter Merian Weg 12, 4002 Basel, Switzerland), or Dentsply XIVE (Dentsply Sirona, 13320 Ballantyne Corporate Place, Charlotte, North Carolina 28277, USA) implants, and took place between December 2019 to December 2021. All recruited patients provided their informed consents, and the study was conducted in accordance with the ethical boundaries and guidelines of the declaration of Helsinki on research involving human subjects.

### 2.2 | Surgical procedure

As previously described, patients were equally divided into two groups of 5 individuals to be assigned either into the RIE Flap group, or the HS Flap approach.

All surgical steps for both groups were performed under the same magnification of a surgical microscope (Zeiss Extaro 300, Oberkochen, Germany) by the same experienced operator (B.S.).

After successful administration of local anesthesia and determination of the exact position of the implants, for sites allocated to the RIE



**FIGURE 1** The roll-in-envelope flap technique. (A) Pre-operative image of the patient, requiring a single dental implant on maxillary first premolar region and precise de-epithelialization of the soft tissue with a round diamond bur (B) outlines of the flap is defined (C) the mucosal flap is rolled in to the vestibularly prepared envelope and kept in place safely (D) the roll-in-envelope mucosa Flap remains in position safely throughout surgery and implant placement (E) micro Fixation of mucosal flap with 6–0 sutures after inserting healing screw (F) 6-week follow-up (G) 12-week follow-up (H) 12-week follow-up buccal view.

Flap approach, the technique was applied as follows (Figure 1): initially, prior to incision, the soft tissues overlying the desired position of the implants were de-epithelialized using a 1 mm diameter round diamond bur (Figure 1A). Subsequently, a microsurgical blade (Swann Morton LTD., Sheffield, England) was used to dissect the tissues in a square shape by means of two bucco-lingual and one mesiodistal (at the palatal/lingual ends of the two parallel incisions) incisions (Figure 1B) as to design the outline of the flap. The bucco-lingual incisions are made from the buccal line angle of the adjacent teeth with a safety margin of 1–2 mm from the adjacent sulci and are performed with the aim of preserving the papillae. Moreover, the bucco-lingual extension of the flap is approximately 3 mm over the sagittal midline of the crest in order to gain sufficient tissue for performing the “roll-in maneuver”. The vestibular extension is 1–2 mm over the crest-vestibular border. The flap is also extended sagittally on average

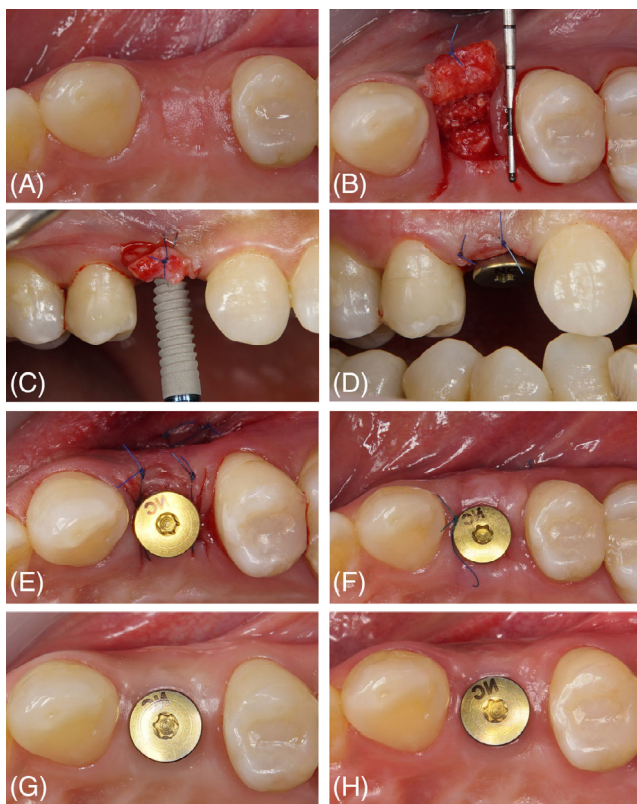
2 mm greater than the planned implant diameter, 1 mm to both mesial and the distal sides. The split-thickness flap is then elevated using a micro-elevator instrument (Figure 1C). Next, by means of the same micro-elevator, the flap is rolled-in underneath the buccal soft tissue, and the implant is placed as planned (Figure 1D). Following implant placement, the RIE flap is stabilized using two vertical mattress sutures with a 6-0 Seralon material (Serag-Wiessner, 95,119 Naila, Germany) (Figure 1E). The suture passes through both two layers of the rolled tissues on the vestibular aspect, penetrating the exact corresponding point of crest-oral mucosa, for fixing the RIE in position on both mesial and distal sides of the implant.

For the 5 implant sites allocated to the HS Flap Technique (Figure 2A), a split thickness mucosal incision was placed perpendicular to the tissue with a Micro Blade (Swann Morton LTD., Sheffield, England) according to a vestibularly pedicled rectangular flap design having a similar outline to the RIE group. The oral extension of the flap was 1–2 mm over the sagittal midline of the crest allowing to obtain sufficient tissue for “rolling” the raised flap. In contrast to the RIE group,

hereby the split-thickness flap was raised and folded backwards to be held by a 6-0 micro-suture passing beneath the two layers of the soft tissues, holding the flap at the position (Figure 2B). Next, the implant was placed and subsequently (Figure 2C), the held flap was released by removing the suture and the free-soft-tissue rolled into the buccal aspect of the soft tissue, stabilized with the same suturing sequence as those previously described in the RIE group (Figure 2D,E).

After thorough irrigation and cleansing of the internal implant fixtures, the healing abutments were placed in 1% CHX gel (GlaxoSmithKline Consumer Healthcare GmbH & Co. KG, 80258 Munich, Germany) and inserted into the implant fixtures (Figures 1E and 2D).

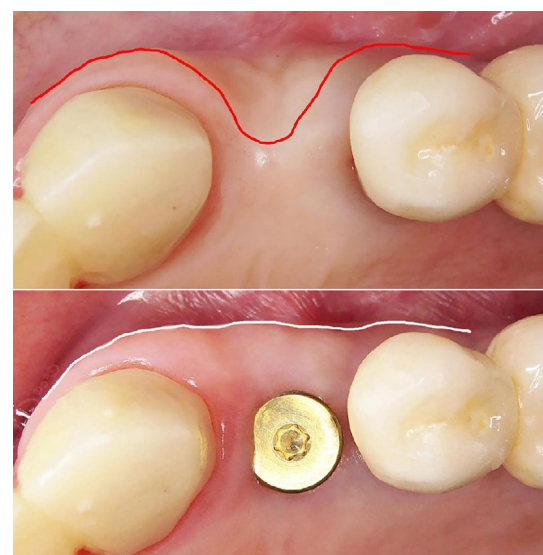
Post-operative instructions for all patients included antibiotic therapy (Clindamycin 300 mg, Ratiopharm GmbH, Graf-Arco-Str. 3, 89079 Ulm, Germany) for 3 days, as well as analgesic consumption as needed (Ibuprofen 400 mg, Ratiopharm GmbH, Graf-Arco-Str. 3, 89079 Ulm, Germany). All patients were also instructed on post-operative care and provided complete oral hygiene instructions. In all patients, sutures were removed 10 to 14 days after surgery.



**FIGURE 2** (A) pre-operative image of the upper first premolar area, requiring dental implant placement. (B) The holding suture, stabilizing the backwardly folded soft tissue in place. (C) Implant placement procedure, while the soft tissue is held by the Holding Suture safely throughout the surgery (D) healing abutment is inserted and the flap is closed after rolling into the buccal soft tissue (Occlusal aspect) (E) post-operative buccal image of the placed implant (F) 10 days after the surgery, displaying the proper healing of the soft tissue wound (occlusal view) (G) 6-week time point. The amount of keratinized tissue in the buccal aspect (H) 12-week visit.

### 2.3 | Study Outcomes and the assessment of peri-implant soft tissue thickness

All patients were recalled at equal time points of 6 and 12 weeks after the procedure to assess the healing of the adjacent soft tissues (Figures 1F-H and 2F-H). The aim was to observe and compare the mean changes in the horizontal dimension of the peri-implant mucosal tissues (in the vestibule-marginal direction) across both groups. This was termed the peri-implant buccal mucosal thickness, and assessed under standardized, direct microscopy at all time points by a single operator (B.S), using a specified periodontal probe (UNC-15, Hu-Friedy, Chicago, IL, USA) (Figure 3).



**FIGURE 3** The comparison of the conditions of the vestibulo-gingival soft tissue before and 12 weeks after the implant placement (using RIE technique).

Due to the pilot design of the current study and its comparative technical note, all clinical measurements were reported descriptively without statistical inferences.

### 3 | RESULTS

As per the study protocol, a total of 10 dental implants (either in the posterior mandible or maxilla) were successfully placed in 10 healthy patients (6 females and 4 males, with a mean age of  $38.2 \pm 15.4$  years). Post-operative healing was uneventful at all sites without any reported adverse events or major complications. Consequently, all implants received final prostheses successfully as planned.

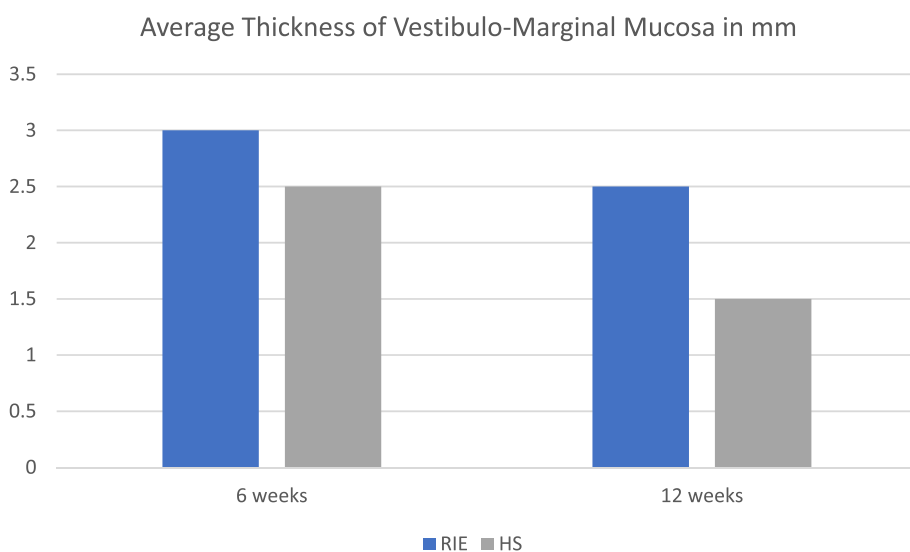
The average mucosal thickness at baseline was 3.2 mm in the RIE, and 2.4 mm in HS group. The measurements at the 6-week time-point, showed 3 and 2.5 mm for the RIE and HS groups, respectively (Figure 4). These amounts decreased on average by 0.4 mm in the RIE and 1.2 mm in the HS groups at the 12-week visit, reaching a final value of 2.5 mm thickness in the RIE, and 1.5 mm in HS group. Thus,

the average changes in the (horizontal) mucosal thickness of implants in the HS group was about twice as much as those observed in the RIE group at the 6-week follow-up (0.4 vs. 0.2 mm, respectively), approximately three times greater in the HS group at the 12-week visits (1.2 vs. 0.4 mm respectively) (Figure 5).

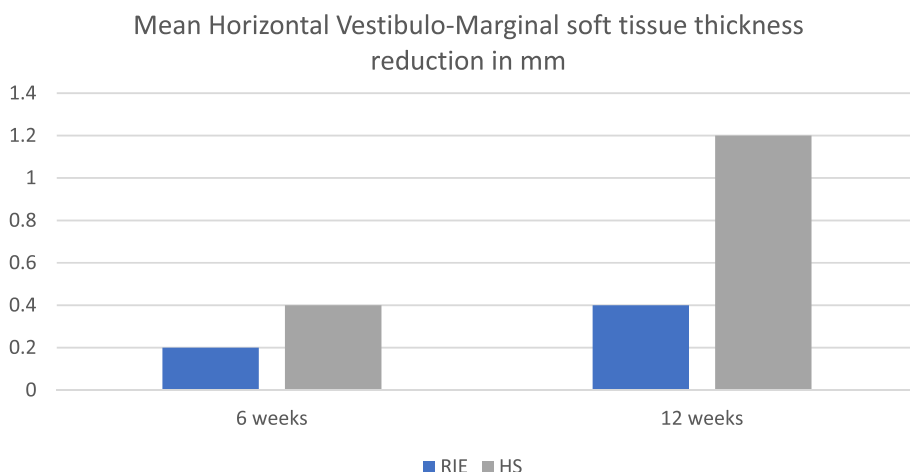
All implants received customized healing abutments and cemented CAD/CAM zirconia crowns in order to obtain an ideal shape and emergence profile. Approximately 8 months after the implant procedures, all patients received their final all-ceramic layered supra-structures after the development of the ideal emergence profiles with the fabricated provisional restorations, as previously described.

### 4 | DISCUSSION

Obtaining an adequate ridge morphology and soft tissue dimension is crucial for implant therapy and can be achieved by performing contour augmentation using hard or soft tissue grafting at implant sites. This leads to an improvement not only in esthetics but also in the function



**FIGURE 4** The average absolute mucosal thickness in mm, at 6 and 12 weeks after the procedure for the roll-in-envelope technique (RIE) and holding-suture-group (HS).



**FIGURE 5** Comparison of the mean changes in buccal soft tissue thickness at different time points of the study.



of the peri-implant tissues.<sup>14,20</sup> Specifically, the important role of soft tissue augmentation at implant sites has been emphasized by numerous studies as it contributes to optimum treatment outcomes and their stability.<sup>14,21-23</sup> In fact, it is suggested that a soft tissue thickness of at least 2 mm can prevent discoloration of the mucosa overlying a restorative material.<sup>24-28</sup> Moreover, evidence supports the benefits of autogenous soft tissue grafts or their substitutes in terms of the marginal bone stability.<sup>14,22,23</sup>

Indeed, various approaches and biomaterials have been proposed throughout the literature for manipulating and augmenting the peri-implant soft tissues.<sup>14</sup> The autogenous connective tissue graft (CTG) is known as the treatment of choice as it presents the most predictable outcomes in terms of phenotype modification.<sup>23,29</sup> However, morbidity and patient discomfort, due to the necessity of a palatal donor site, prolonged surgical time, and the invasiveness of this approach, have created a need for more minimally-invasive approaches and the employment of autogenous graft substitutes.<sup>23</sup> Fundamentally, various surgical techniques have been introduced aimed at reconstruction and augmentation of the peri-implant soft tissues at the time of implant placement, eliminating the use of autogenous grafts or biomaterials, solely with the utilization of the present and existing soft tissues at the implant site within the framework of specific incision and surgical designs.<sup>30-34</sup>

In the present study, we described a modification of the conventional roll flap, introduced in the 1980s by Abrams<sup>30</sup> which can be utilized at implant placement or at the second stage surgery, and observed the clinical outcomes of this minimally-invasive microsurgical approach (the RIE flap) compared to that of a more commonly performed HS flap technique. Indeed, other approaches have also been introduced for this delicate management of the peri-implant soft tissues with the same aim in mind.<sup>30,33,34</sup> Nonetheless, readers are to bear in mind that the described approaches in this report are to be performed in the presence of adequate peri-implant soft and hard tissue tissues. The intent of the described methods is not to overcome the need for soft or hard tissue grafting in cases with significant deficiencies. In cases and sites with an apparent deficiency in mucosal thickness or keratinized mucosa, soft tissue grafting procedures via either autogenous or non-autogenous grafts (depending on the indication) should be performed.<sup>35,36</sup>

Previously proposed techniques typically required a palatal extension of the flap, however, a potential advantage of this RIE flap over the previous techniques would potentially be less trauma and minimal manipulation of the soft tissues. When performing vestibular soft tissue augmentation, either during the implant placement or the second stage surgery, holding the microsurgical flap (3-5 mm length) is challenging. However, the use of a micro-elevator, as demonstrated in this report, can overcome this hurdle. Indeed, studies have described significant improvements in vascularization during the healing process, as well as enhanced soft tissue outcomes of microsurgical approaches compared to conventional surgeries.<sup>19,37-39</sup> As such, a vital step of the RIE technique, is the de-epithelialization process, which requires delicate execution and precision in order to adequately remove the superficial epithelium, while preventing perforation of the tissues. Undoubtedly

achieving this aim is an easier task to accomplish, if performed under the enhanced vision and magnification of a dental operating microscope. Thus, the emphasis of the current report and the described technique on employment of the microsurgical approach. It should be noted that as a necessity to, and prior to employment of this approach, thorough pre-operative assessment of the surgical site is a must. This consists of careful evaluation of the underlying bone and digital planning to ensure the absence of any concavities, or requirements of additional bone or substantial soft tissue augmentation, which would require additional surgical steps. As such it should be mentioned that not all implants would be a candidate for performing the stated approach. As a limitation of the current study as well, its limited sample size and therefore the lack of a formal statistical analysis is to be acknowledged. We emphasize that the aim of this study was not to compare efficacy or effectiveness of two approaches, rather to describe a slight modification of soft tissue manipulation (using minimally-invasive microscopic approaches) relative to a more commonly technique. The present study and its preliminary data can serve as basis for future clinical trials with adequate sample size, or to encourage future research in the path of minimal invasiveness and patient-centered therapies. As such, we encourage larger, adequately-designed and powered, independent studies to further corroborate these preliminary results, and ideally with more robust and sophisticated measures of outcome assessment (such as three-dimensional optical scanners, ultrasonography, etc.).

## 5 | CONCLUSION

Within the limitations of the pilot study, in this article a microsurgical RIE flap technique was described as a minimally invasive alternative for securing the flap and compared to a more commonly used flap securing technique of HS, for the implant placement surgery. Based on presented results and in the presence of sufficient peri-implant supporting tissues, the RIE technique seems to be superior and more recommendable compared to utilization of a flap holding suture technique. This microsurgical technique can be employed as a minimally invasive approach which leads to higher predictability and better outcomes. And seems to enhance patient-centered outcomes (pain/discomfort), compared with autogenous grafts.

## DISCLOSURE

The authors declare that they do not have any financial interest in the companies whose materials are included in this article.

## DATA AVAILABILITY STATEMENT

The data that support the findings of this study are available on request from the corresponding author.

## ORCID

Hamoun Sabri  <https://orcid.org/0000-0001-6581-2104>

Marcus B. Blatz  <https://orcid.org/0000-0001-6341-7047>

Shayan Barootchi  <https://orcid.org/0000-0002-5347-6577>

## REFERENCES

1. Barootchi S, Wang HL, Ravid A, et al. Ridge preservation techniques to avoid invasive bone reconstruction: a systematic review and meta-analysis: Naples Consensus Report Working Group C. *Int J Oral Implantol (Berl)*. 2019;12:399-416.
2. Araujo MG, da Silva JCC, de Mendonca AF, Lindhe J. Ridge alterations following grafting of fresh extraction sockets in man. A randomized clinical trial. *Clin Oral Implants Res*. 2015;26:407-412.
3. Araujo MG, Lindhe J. Dimensional ridge alterations following tooth extraction. An experimental study in the dog. *J Clin Periodontol*. 2005;32:212-218.
4. Avila-Ortiz G, Elangovan S, Kramer KW, Blanchette D, Dawson DV. Effect of alveolar ridge preservation after tooth extraction: a systematic review and meta-analysis. *J Dent Res*. 2014;93:950-958.
5. Barakat K, Ali A, Abdel Meguid A, Abdel MM. Modified roll flap a handy technique to augment the peri-implant soft tissue in the esthetic zone: a randomized controlled clinical trial. *Tanta Dent J*. 2013;10:123-128.
6. Sabri H, Sarkarat F, Mortezaagholi B, Aghajani D. Non-surgical management of oro-antral communication using platelet-rich fibrin: a review of the literature. *Oral Surg*. 2022;15(3):455-464.
7. Zucchelli G, Barootchi S, Tavelli L, Stefanini M, Rasperini G, Wang HL. Implant soft tissue dehiscence coverage esthetic score (IDES): a pilot within- and between-rater analysis of consistency in objective and subjective scores. *Clin Oral Implants Res*. 2021;32:349-358.
8. Stefanini M, Marzadori M, Sangiorgi M, Rendon A, Testori T, Zucchelli G. Complications and treatment errors in peri-implant soft tissue management. *Periodontol 2000*. 2023;1-15. doi:10.1111/prd.12470
9. Barootchi S, Tavelli L, Di Gianfilippo R, et al. Soft tissue phenotype modification predicts gingival margin long-term (10-year) stability: longitudinal analysis of six randomized clinical trials. *J Clin Periodontol*. 2022;49:672-683.
10. Thoma DS, Gil A, Hammerle CHF, Jung RE. Management and prevention of soft tissue complications in implant dentistry. *Periodontol 2000*. 2000;2022(88):116-129.
11. Zucchelli G, Tavelli L, Stefanini M, et al. Classification of facial peri-implant soft tissue dehiscence/deficiencies at single implant sites in the esthetic zone. *J Periodontol*. 2019;90:1116-1124.
12. Tabanella G. The buccal pedicle flap technique for periimplant soft tissue boosting. *Int J Esthet Dent*. 2019;14:18.
13. Buser D, Sennerby L, De Bruyn H. Modern implant dentistry based on osseointegration: 50 years of progress, current trends and open questions. *Periodontol 2000*. 2000;2017(73):7-21.
14. Tavelli L, Barootchi S, Avila-Ortiz G, Urban IA, Giannobile WV, Wang HL. Peri-implant soft tissue phenotype modification and its impact on peri-implant health: a systematic review and network meta-analysis. *J Periodontol*. 2021;92:21-44.
15. Cairo F, Barbato L, Tonelli P, Batalocco G, Pagavino G, Nieri M. Xenogeneic collagen matrix versus connective tissue graft for buccal soft tissue augmentation at implant site. A randomized, controlled clinical trial. *J Clin Periodontol*. 2017;44:769-776.
16. Vallecillo C, Toledano-Osorio M, Vallecillo-Rivas M, Toledano M, Rodriguez-Archilla A, Osorio R. Collagen matrix vs. autogenous connective tissue graft for soft tissue augmentation: a systematic review and meta-analysis. *Polymers (Basel)*. 2021;13(11):1810.
17. Tavelli L, Barootchi S, Di Gianfilippo R, et al. Patient experience of autogenous soft tissue grafting has an implication for future treatment: a 10- to 15-year cross-sectional study. *J Periodontol*. 2021;92:637-647.
18. Gobbato L, Nart J, Bressan E, Mazzocco F, Paniz G, Lops D. Patient morbidity and root coverage outcomes after the application of a sub-epithelial connective tissue graft in combination with a coronally advanced flap or via a tunneling technique: a randomized controlled clinical trial. *Clin Oral Investig*. 2016;20:2191-2202.
19. Shakibaie-M B. Uses of the operating microscope in minimally invasive implantology. *Quintessenz*. 2010;61:293-308.
20. Hosseini M, Worsaae N, Gotfredsen K. Tissue changes at implant sites in the anterior maxilla with and without connective tissue grafting: a five-year prospective study. *Clin Oral Implants Res*. 2020;31:18-28.
21. Rocuzzo M, Grasso G, Dalmaso P. Keratinized mucosa around implants in partially edentulous posterior mandible: 10-year results of a prospective comparative study. *Clin Oral Implants Res*. 2016;27:491-496.
22. Giannobile WV, Jung RE, Schwarz F. Groups of the 2nd osteology foundation consensus M. evidence-based knowledge on the aesthetics and maintenance of peri-implant soft tissues: osteology foundation consensus report part 1-effects of soft tissue augmentation procedures on the maintenance of peri-implant soft tissue health. *Clin Oral Implants Res*. 2018;29(Suppl 15):7-10.
23. Thoma DS, Naenni N, Figuero E, et al. Effects of soft tissue augmentation procedures on peri-implant health or disease: a systematic review and meta-analysis. *Clin Oral Implants Res*. 2018;29(Suppl 15):32-49.
24. Wang II, Barootchi S, Tavelli L, Wang HL. The peri-implant phenotype and implant esthetic complications. Contemporary overview. *J Esthet Restor Dent*. 2021;33:212-223.
25. Khorshed A, Vilarrasa J, Monje A, Nart J, Blasi G. Digital evaluation of facial peri-implant mucosal thickness and its impact on dental implant aesthetics. *Clin Oral Investig*. 2022;27:581-590.
26. Jung RE, Holderegger C, Sailer I, Khraisat A, Suter A, Hammerle CH. The effect of all-ceramic and porcelain-fused-to-metal restorations on marginal peri-implant soft tissue color: a randomized controlled clinical trial. *Int J Periodontics Restorative Dent*. 2008;28:357-365.
27. Jung RE, Sailer I, Hammerle CH, Attin T, Schmidlin P. In vitro color changes of soft tissues caused by restorative materials. *Int J Periodontics Restorative Dent*. 2007;27:251-257.
28. Bressan E, Paniz G, Lops D, Corazza B, Romeo E, Favero G. Influence of abutment material on the gingival color of implant-supported all-ceramic restorations: a prospective multicenter study. *Clin Oral Implants Res*. 2011;22:631-637.
29. Zucchelli G, Tavelli L, McGuire MK, et al. Autogenous soft tissue grafting for periodontal and peri-implant plastic surgical reconstruction. *J Periodontol*. 2020;91:9-16.
30. Abrams L. Augmentation of the deformed residual edentulous ridge for fixed prosthesis. *Compend Contin Educ Gen Dent*. 1980;1:205-213.
31. Scharf DR, Tarnow DP. Modified roll technique for localized alveolar ridge augmentation. *Int J Periodontics Restorative Dent*. 1992;12:415-425.
32. Nemcovsky CE, Artzi Z. Split palatal flap. I. A surgical approach for primary soft tissue healing in ridge augmentation procedures: technique and clinical results. *Int J Periodontics Restorative Dent*. 1999;19:175-181.
33. Pandolfi A. A modified approach to horizontal augmentation of soft tissue around the implant: omega roll envelope flap. Description of surgical technique. *La Clin Ter*. 2018;169:e165-e169.
34. Park SH, Wang HL. Pouch roll technique for implant soft tissue augmentation: a variation of the modified roll technique. *Int J Periodontics Restorative Dent*. 2012;32:e116-e121.
35. Thoma DS, Gasser TJW, Jung RE, Hammerle CHF. Randomized controlled clinical trial comparing implant sites augmented with a volume-stable collagen matrix or an autogenous connective tissue graft: 3-year data after insertion of reconstructions. *J Clin Periodontol*. 2020;47:630-639.
36. Artzi Z, Renert U, Netanel E, Thoma DS, Vered M. Histologic composition of marginal mucosal tissue augmented by a resorbable volume-stable collagen matrix in soft tissue thickening procedures in humans: a morphometric observational study. *Clin Oral Investig*. 2022;26:427-435.

37. Shakibaie-M B. Microscope-guided external sinus floor elevation (MGES)—a new minimally invasive surgical technique. *IMPLANTOLOGIE*. 2008;16:21-31.
38. Zuhr O, Fickl S, Wachtel H, Bolz W, Hurzeler M. Covering of gingival recessions with a modified microsurgical tunnel technique: case report. *Int J Periodont Restor Dent*. 2007;27:457-463.
39. Burkhardt R, Lang NP. Coverage of localized gingival recessions: comparison of micro-and macrosurgical techniques. *J Clin Periodontol*. 2005;32:287-293.

**How to cite this article:** Shakibaie B, Sabri H, Blatz MB, Barootchi S. Comparison of the minimally-invasive roll-in envelope flap technique to the holding suture technique in implant surgery: A prospective case series. *J Esthet Restor Dent*. 2023;35(4):625-631. doi:[10.1111/jerd.13027](https://doi.org/10.1111/jerd.13027)