

**THE 50TH MOYERS SYMPOSIUM ANNIVERSARY MONOGRAPH:
REFLECTIONS AND ADVANCES ON 100 YEARS IN ORTHODONTICS**

This volume includes the proceedings of the
Fiftieth Annual Moyers Symposium and the Forty-eighth
Annual International Conference on Craniofacial Research
March 3-5, 2023
Ann Arbor, Michigan

Co-Editors

Nan Hatch
G. Thomas Kluemper
Hera Kim-Berman

Copy Editor

Dawn Bielawski

Volume 59
Craniofacial Growth Series

Department of Orthodontics and Pediatric Dentistry
School of Dentistry

The University of Michigan
Ann Arbor, Michigan

©2024 by the Department of Orthodontics and Pediatric Dentistry,
School of Dentistry, University of Michigan Ann
Arbor, MI 48109

Publisher's Cataloguing in Publication Data

Department of Orthodontics and Pediatric Dentistry
Craniofacial Growth Series
The 50th Moyers Symposium
Anniversary Monograph:
Reflections and Advances on 100 Years
in Orthodontics
Volume 59

ISSN 0162 7279

ISBN 0-929921-00-3

No part of this publication may be reproduced, stored in a retrieval system, or transmitted in any form by any means, electronic, mechanical, photocopying, recording, or otherwise, without the prior written permission of the Editor-in-Chief of the Craniofacial Growth Series or designate

CONTRIBUTORS

ALYAA ALDOHAN, Associate Consultant, Orthodontics Section, King Faisal Specialist Hospital and Research Centre, Riyadh, Saudi Arabia.

NAJLA AL TURKESTANI, Department of Orthodontics and Pediatric Dentistry, School of Dental Medicine, University of Michigan, Ann Arbor, MI; Department of Restorative and Aesthetic Dentistry, Faculty of Dentistry, King Abdulaziz University, Jeddah, Saudi Arabia.

ARON ALIAGA DEL CASTILLO, Clinical Assistant Professor, Department of Orthodontics and Pediatric Dentistry, University of Michigan, Ann Arbor, MI; Private practice, Birmingham, MI.

LUC ANCHLING, Department of Orthodontics and Pediatric Dentistry, School of Dental Medicine, University of Michigan, Ann Arbor, MI; CPE Lyon, Lyon, France.

BAPTISTE BAQUERO, Department of Orthodontics and Pediatric Dentistry, University of Michigan, Ann Arbor, MI; CPE Lyon, Lyon, France.

SELENE BARONE, Department of Orthodontics and Pediatric Dentistry, School of Dental Medicine, University of Michigan, Ann Arbor, MI; Department of Health Science, School of Dentistry, Magna Graecia University of Catanzaro, Italy.

JULIANA BATISTA MELO DA FONTE, PhD Candidate, Division of Oral Radiology, Department of Oral Diagnosis, Piracicaba Dental School, University of Campinas (UNICAMP), Sao Paulo, Brazil.

PATRICIA BEALS, Co-Director, Phoenix Children's Center for Cleft and Craniofacial Care, Phoenix, AZ.

STEPHEN BEALS, Phoenix Children's Center for Cleft and Craniofacial Care, Phoenix, AZ.

JONAS BIANCHI, Department of Orthodontics, University of the Pacific, San Francisco, CA.

ROSARIA BUCCI, Assistant Professor, School of Orthodontics, Department of Neurosciences, Reproductive Sciences and Oral Sciences, University of Naples Federico II, Naples, Italy.

PETER H. BUSCHANG, Regents Professor Emeritus, Texas A&M University School of Dentistry, Dallas, TX.

LUCIA CEVIDANES, Department of Orthodontics and Pediatric Dentistry, School of Dental Medicine, University of Michigan, Ann Arbor, MI.

HSUN-LIANG CHAN, Clinical Associate Professor of Periodontics, Periodontics and Oral Medicine, School of Dentistry, University of Michigan, Ann Arbor, MI.

JADE COOK, 3rd Year Resident of Orthodontics, Orthodontic and Pediatric Dentistry, School of Dentistry, University of Michigan, Ann Arbor, MI.

JOHN DASKALOGIANNAKIS, Associate Professor, Department of Orthodontics, University of Toronto, Honorary Staff, SickKids Hospital; Private practice orthodontist, Toronto, Ontario, Canada.

HUGO DE CLERCK, Adjunct Professor, Department of Orthodontics, School of Dentistry, University of North Carolina, Chapel Hill, NC; Orthodontist, private practice, Brussels, Belgium.

JEAN-CHARLES DOUCET, Professor and Division Head, Department of Oral and Maxillofacial Surgery, Dalhousie University, and Staff Oral and Maxillofacial Surgeon, Cleft Palate Team, IWK Health Centre, Halifax, Nova Scotia, Canada.

LILY ETEMAD, Resident, Division of Orthodontics, Ohio State University College of Dentistry, Columbus, OH.

LORENZO FRANCHI, Professor, Department of Experimental and Clinical Medicine, Graduate Orthodontic Program, University of Florence, Florence, Italy; and Thomas M. Graber Visiting Scholar, Department of Orthodontics and Pediatric Dentistry, School of Dentistry, University of Michigan, Ann Arbor, MI.

MAXIME GILLOT, Department of Orthodontics and Pediatric Dentistry, School of Dental Medicine, University of Michigan, Ann Arbor, MI; CPE Lyon, Lyon, France.

VERONICA GIUNTINI, Assistant Professor, Graduate Orthodontic Program, Department of Experimental and Clinical Medicine, Orthodontics, University of Florence, Florence, Italy.

CHRISTIAN GROTH, Adjunct Clinical Assistant Professor, Department of Orthodontics and Pediatric Dentistry, University of Michigan, Ann Arbor; Private practice, Birmingham, MI.

MARCELA GURGEL, Department of Orthodontics and Pediatric Dentistry, School of Dental Medicine, University of Michigan, Ann Arbor, MI.

RONALD R. HATHAWAY, Adjunct Clinical Associate Professor, University of Michigan, Orthodontics and Pediatric Dentistry, Ann Arbor, MI.

YANJIE HUANG, Department of Orthodontics and Pediatric Dentistry, School of Dental Medicine, University of Michigan, Ann Arbor, MI.

NATHAN HUTIN, Department of Orthodontics and Pediatric Dentistry, School of Dental Medicine, University of Michigan, Ann Arbor, MI; CPE Lyon, Lyon, France.

LAURA R. IWASAKI, Professor & Chair, Department of Oral and Craniofacial Sciences, Oregon Health & Science University, School of Dentistry, Portland, OR.

NEGIN KATEBI, Director of Pre-doctoral Orthodontics, Instructor in Developmental Biology, Harvard School of Dental Medicine, Boston, MA.

HERA KIM-BERMAN, Clinical Associate Professor, Robert W. Browne Professor of Dentistry in Orthodontics, Graduate Orthodontic Program Director, Department of Orthodontics and Pediatric Dentistry, School of Dentistry, University of Michigan, Ann Arbor, MI.

CHING-CHANG KO, Professor and Vig/Williams Endowed Chair, Division of Orthodontics, Ohio State University College of Dentistry, Columbus, OH.

OLIVER KRIPFGANS, Research Associate Professor of Radiology, Department of Radiology, University of Michigan Medical School; Department of Biomedical Engineering, College of Engineering, University of Michigan, Ann Arbor, MI.

ROSS E. LONG, JR., Director Emeritus, Lancaster Cleft Palate Clinic, Lancaster, PA.

MOHAMED MASOUD, Associate Professor in Developmental Biology, Harvard School of Dental Medicine, Boston, MA.

JAMES A. MCNAMARA JR., Graber Endowed Professor Emeritus, Department of Orthodontics and Pediatric Dentistry; Professor Emeritus, Department of Cell and Developmental Biology, School of Medicine; and Research Professor Emeritus, Center for Human Growth and Development, University of Michigan, Ann Arbor, Michigan; Private practice of orthodontics, Ann Arbor, MI.

ANA MERCADO, Clinical Associate Professor, Division of Orthodontics, College of Dentistry at The Ohio State University and Member of the Cleft Palate-Craniofacial Team, Nationwide Children's Hospital, Columbus, Ohio.

AMBRA MICHELOTTI, Full Professor, School of Orthodontics, Department of Neurosciences, Reproductive Sciences and Oral Sciences, University of Naples Federico II, Naples, Italy.

SUMEET MINHAS, Resident, Division of Orthodontics, Ohio State University College of Dentistry, Columbus, OH.

FELICIA MIRANDA, Department of Orthodontics and Pediatric Dentistry, School of Dental Medicine, University of Michigan, Ann Arbor, MI; Bauru Dental School, University of São Paulo, Bauru, São Paulo, Brazil.

JEFFREY C. NICKEL, Professor, Director of the Advanced Education Program in Orthodontics and Dentofacial Orthopedics, Department of Oral and Craniofacial Sciences, Oregon Health & Science University, School of Dentistry, Portland, OR.

JUAN PRIETO, Department of Psychiatry, University of North Carolina, Chapel Hill, NC.

DEBORAH QUEIROZ FREITAS, Professor, Division of Oral Radiology, Department of Oral Diagnosis, Piracicaba Dental School, University of Campinas (UNICAMP), Sao Paulo, Brazil.

SAMUEL I. ROLDÁN, Assistant Professor & Director, Center for Studies of Craniofacial Growth and Development, CES University, Medellín, Colombia; Private practice, Medellín, Colombia.

ROBERTO RONGO, Assistant Professor, School of Orthodontics, Department of Neurosciences, Reproductive Sciences and Oral Sciences, University of Naples Federico II, Naples, Italy.

ANTONIO RUELLAS, Department of Orthodontics, Federal University of Rio de Janeiro, Rio de Janeiro, Brazil.

KATHLEEN RUSSELL, Professor and Head, Division of Orthodontics, Dalhousie University, and Staff Orthodontist and Chair, Cleft Palate Team, IWK Health Centre, Halifax, Nova Scotia, Canada.

VALENTINA RUTILI, Resident, Graduate Orthodontic Program, Department of Experimental and Clinical Medicine, Orthodontics, The University of Florence, Florence, Italy.

HINA SHAH, Department of Psychiatry. University of North Carolina, Chapel Hill, NC.

BELLA SHEN GARNETT, Private practice, San Francisco; Adjunct Clinical Assistant Professor, Department of Orthodontics, University of the Pacific, Arthur A. Dugoni School of Dentistry, San Francisco, CA.

SERGIO SICILIANO, Max-Fac Surgeon, Department of Oral and Maxillofacial Surgery, Cliniques de l'Europe, Brussels, Belgium; Private practice, Brussels, Belgium.

FABIANA SOKI, Clinical Assistant Professor of Radiology, Periodontics and Oral Medicine, School of Dentistry, University of Michigan, Ann Arbor, MI.

SAULO SOUSA MELO, Associate Professor, Department of Oral and Craniofacial Sciences, Oregon Health & Science University, School of Dentistry, Portland, OR.

LEAH STETZEL, Resident, Division of Orthodontics, Ohio State University College of Dentistry, Columbus, OH.

ESTHER SUH, 2nd Year Resident, Department of Orthodontics and Pediatric Dentistry, School of Dentistry, University of Michigan, Ann Arbor, MI.

HEEYEON SUH, Assistant Professor, Department of Orthodontics, University of the Pacific, Arthur A. Dugoni School of Dentistry, San Francisco, CA.

HILDE TIMMERMAN, Private practice, Hulst, The Netherlands.

TAI-HSIEN WU, Solutions Engineering Consultant, Division of Orthodontics, Ohio State University College of Dentistry, Columbus, OH.

JENNIFER XU, 2nd Year Resident of Orthodontics, Orthodontic and Pediatric Dentistry, School of Dentistry, University of Michigan, Ann Arbor, MI.

MARILIA YATABE, Clinical Assistant Professor of Orthodontics, Orthodontic and Pediatric Dentistry, School of Dentistry, University of Michigan, Ann Arbor, MI.

PREFACE

It is an honor to be Chair of the Department of Orthodontics and Pediatric Dentistry during our Centennial Celebration of Orthodontics at Michigan, which serendipitously corresponded with our 50th Moyers Symposium. The goal of the 50th Symposium therefore combined a desire to recruit experts in our field from around the world to provide evidence-based presentations of relevance to orthodontic practice, with the desire to celebrate the Michigan Graduate Orthodontic Program's continued expectations for excellence and critical thinking in orthodontic residency and practice.

The Moyers Symposium honors Dr. Robert E. Moyers, former chair of the Department of Orthodontics and founding Director of the Center for Human Growth and Development, an interdisciplinary research unit on the Ann Arbor University of Michigan campus. The Moyers Symposium has always been a place for presentation of clinically relevant evidence, and lively discussion by speakers and attendees. In hindsight, I am thrilled to describe the 50th Moyers Symposium and long weekend of celebratory events as educational, spirited, and fun.

Given the variety of topics presented, this preface is written to provide a brief summary of the speaker topics provided in this book. I hope that this preface will further motivate you to dive deep into the chapters of this monograph, as much important and up to date evidence-based information is provided on multiple topics of direct applicability to the every-day practice of orthodontics. I thank Drs. Hera Kim-Berman and G. Thomas Kluemper for their strong work as co-editors. These two individuals were also speakers, such that their contributions were essential to the overall success of the 50th Moyers Symposium and associated proceedings.

I also thank Dawn Bielawski, PhD for her invaluable work on this book as Copy Editor and I-tsen Weng for verifying all citations and references.

Chapters are provided by each of the three keynote speakers who began each day of talks.

Friday morning began with a keynote presentation by **Dr. Peter Buschang** on the use of miniscrews (MSIs, otherwise referred to as temporary anchorage devices/TADs) for improved biomechanics and treatment outcomes for anterior-posterior discrepancies and tooth intrusion for vertical control. This presentation was based upon evidence from his and others' numerous studies of MSI function in large animal models and in humans, and thus was a very important contribution and most definitely in the Moyers Symposium style. Importantly, Dr. Buschang also introduced a new MSI design of 3 mm in length for use in younger patients and in areas of diminished bone thickness. The chapter presented herein provides a full review of biomechanical techniques, MSI placement, and case types in which the use of MSIs will facilitate a successful outcome.

Saturday morning commenced with a keynote presentation by **Dr. Lucia Cevitanes** on 3D imaging and use of artificial intelligence (AI) for interpreting such images for use in orthodontic planning, and interpretation of treatment results. The chapter presented within provides a useful update

on the development and use of novel AI based tools, and the need for further model training and validation for ultimate use in orthodontics. It is notable that Dr. Cevitanes works with an international group of scholars using open-source software to advance these technologies.

Sunday morning began with a keynote presentation by **Dr. Ambra Michelotti**, who provided an objective and evidence-based overview of the relationship (or lack thereof) between occlusion, orthodontics, and temporomandibular joint disorders (TMJD). Her talk and chapter also include recommendations for the diagnosis and management of TMJD patients in an orthodontic practice. Her chapter provides very important information that all orthodontists should know, to better inform and support their TMJD patients.

Numerous other important topics were presented by additional speakers throughout the weekend, who also provided chapters for this book. These topics include:

- Commentary from an orthodontist who has been associated with the Moyers Symposium since its inception.
- Optimal clear aligner treatment planning, including timing of tooth movements, focused upon open bite treatment.
- A new adjunctive technique involving the use of light wire through tubes (tunnel attachments) bonded to teeth in conjunction with clear aligner therapy.
- Advances in materials and printing technologies for 3D printing of orthodontic appliances, including metal appliances.
- Use of practice-based evidence from multiple craniofacial centers resulting in the Americleft Project, which has led to a health care learning system for craniofacial orthodontists to standardize approaches and optimize successful treatment outcomes.
- Advances in the use of intraoral ultrasound imaging for improved imaging and diagnosis in craniofacial orthodontic patients.
- Optimization of digital workflow and of AI techniques to revolutionize orthodontic patient care.
- Use of virtual and augmented reality techniques for training and learning.
- True mandibular growth (pure translation) and true mandibular rotation (pure rotation) effects on chin position in orthodontic patients.
- Growth effects and treatment options for Class III malocclusion.

- Changes in temporomandibular joint (TMJ) compressive stress resulting from mandibular orthognathic surgery.

I would be remiss not to mention the University of Michigan Alumni and Friends Celebration of 100 Years of Orthodontics at Michigan in this summary of the 50th Moyers Symposium weekend. The reception was held at the Jack Roth Stadium Club of Michigan Stadium and included Moyers Symposium attendees and UM alumni. It was the largest gathering of Michigan Orthodontic Alumni ever. The room was full of energy and people toasting this auspicious occasion with signature cocktails, “The Tweed Old Fashioned” and the “Moyers Martini”. Class reunions were held, old friends were reunited, and new friendships were formed. Past trainees offered thanks to their teachers including in particular Drs. Lysle Johnson and Jim McNamara. It was a celebratory event not to be missed, and icing on the cake for the 50th Moyers Symposium weekend.

I thank Michelle Jones of the Office of Continuing Dental Education and Cassandra White of the Department of Orthodontics and Pediatric Dentistry for coordinating and managing the Symposium. I also thank Gretchen Hannah, Carrie Towns, and Jeff Freshcorn of the Office for Alumni Relations and Development for assistance and facilitation of the Alumni and Friends Celebration of 100 Years of Orthodontics at Michigan event.

Finally, I thank the speakers and participants of the 50th Moyers Symposium. I appreciate their attendance and support throughout the 50 years of history of the meeting.

A digital version of this book and all prior volumes of the Craniofacial Growth Series/Moyers Monographs/Moyers Proceedings are publicly available through the University of Michigan Deep Blue Repository at: <https://deepblue.lib.umich.edu/handle/2027.42/146667>.

Nan E. Hatch
Co-Editor and Department Chair
February, 2024



TABLE OF CONTENTS

Contributors	iii
Preface	vii
<i>Reflections on My 50 Years With the Moyers Symposium</i> James A. McNamara Jr. University of Michigan, Private Practice	1
<i>Miniscrew Implants (MSIs) and Orthopedics: Their Influence on Present and Future Orthodontic Practice</i> Peter H. Buschang & Samuel I. Roldán Texas A&M University; CES University, Medellín, Colombia; Private Practice	12
<i>Management of Anterior Open Bite With Clear Aligners in Adults</i> Bella Shen Garnett & Heeyeon Suh University of the Pacific, Private Practice	33
<i>Tunnel Attachments</i> Alyaa Aldohan, Negin Katebi, Mohamed Masoud King Faisal Specialist Hospital and Research Centre, Saudi Arabia; Harvard School of Dental Medicine	58
<i>3D Printing 2.0: The Next Generation of Printing in Orthodontics</i> Christian Groth & Aron Aliaga Del Castillo University of Michigan; Private Practice	73
<i>The Americleft Project: A Roadmap for Audits, Quality Assurance, and Improvement in Cleft Care Through Comparative Effectiveness Research Using Practice-Based Evidence</i> Ronald R. Hathaway, Ross E. Long, Jr., Kathleen Russell, Ana Mercado, John Daskalogiannakis, Jean-Charles Doucet, Stephen Beals, Patricia Beals University of Michigan; Lancaster Cleft Palate Clinic; Dalhousie University; IWK Health Centre, Halifax, Canada; Ohio State University; Nationwide Children's Hospital; University of Toronto; Phoenix Children's Center for Cleft and Craniofacial Care; Private Practice	82
<i>Innovations in Craniofacial Care: A Future With Intra-Oral Ultrasound?</i> Marilia Yatabe, Fabiana Soki, Hsu-Liang Chan, Jade Cook, Jennifer Xu, Oliver Kripfgans University of Michigan	103

<i>The Impact of 3D Imaging on Orthodontics</i>	114
<p>Lucia Cevidanes, Felicia Miranda, Selene Barone, Aron Aliaga, Marilia Yatabe, Antonio Ruellas, Marcela Gurgel, Najla Al Turkestani, Luc Anchling, Yanjie Huang, Nathan Hutin, Maxime Gillot, Baptiste Baquero, Hina Shah, Juan Prieto, Jonas Bianchi University of Michigan; University of São Paulo, Brazil; Magna Graecia University of Catanzaro, Italy; Federal University of Rio de Janeiro, Brazil; King Abdulaziz University, Saudi Arabia; CPE Lyon, France; University of North Carolina; University of the Pacific</p>	
<i>When Artificial Intelligence Meets Digital Orthodontics</i>	128
<p>Tai-Hsien Wu, Leah Stetzel, Sumeet Minhas, Lily Etemad, Ching-Chang Ko Ohio State University</p>	
<i>Extended Reality Technology in Orthodontics and Dentistry</i>	143
<p>Esther Suh & Hera Kim-Berman University of Michigan</p>	
<i>Three-Dimensional Imaging of Mandible Growth During Class II Orthopedics</i>	156
<p>Hugo De Clerck, Hilde Timmerman, Sergio Siciliano University of North Carolina; Cliniques de l'Europe, Belgium; Private Practice</p>	
<i>Early Treatment of Class III Malocclusion: A 30-Year Perspective</i>	165
<p>Lorenzo Franchi, Valentina Rutili, Veronica Giuntini, James A. McNamara Jr. University of Florence, Italy; University of Michigan; Private Practice</p>	
<i>Orthodontics, Malocclusion, and Temporomandibular Joint Pain: Where is the Association?</i>	180
<p>Ambra Michelotti, Rosaria Bucci, Roberto Rongo University of Naples Federico II, Italy</p>	
<i>Orthognathic Surgery-Associated Condylar Displacement and Change in Contact Mechanics</i>	195
<p>Juliana Batista Melo da Fonte, Laura R. Iwasaki, Saulo Sousa Melo, Deborah Queiroz Freitas, Jeffrey C. Nickel University of Campinas (UNICAMP), Brazil; Oregon Health & Science University</p>	

REFLECTIONS ON MY 50 YEARS WITH THE MOYERS SYMPOSIUM

James A McNamara, Jr.

ABSTRACT

This opening chapter is written as a memoir by an orthodontist who has been associated with the Moyers Symposium since its inception. He provides a personal perspective on how the Symposium has evolved over time, including the restructuring of the scientific program with the addition of the Presymposium in the second year. He also describes how the *Craniofacial Growth Series* of publications has documented the proceedings of each Moyers meeting. The second part of the chapter is intended to help guide the reader through the substantial Symposium-based literature *now available online and free of charge*. In the opinion of the author only, the two most memorable speakers to appear on the Symposium program were David Sackett MD and Vince Kokich. The author then provides a somewhat lengthy but not all-inclusive list of other memorable presenters, listing them by year and briefly describing the topics of their talks.

KEY WORDS: Orthodontics, Craniofacial, Moyers Symposium, Craniofacial Growth Series

INTRODUCTION

It is rare to have the opportunity to provide personal commentary on a unique series of events—the Moyers Symposia with its lifespan now at 50 years. What started as a modest tribute to Professor Robert Edison Moyers in 1974 has grown to become a special scientific meeting attended each year by clinicians and researchers from around the world.

Overall attendance usually averages 300-450 participants, and at times has exceeded 600 attendees if the topic chosen is particularly timely (e.g., temporomandibular disorder (TMD) controversies, interdisciplinary treatment, three-dimensional (3D) imaging, implants and temporary anchorage devices (TADs), obstructive sleep apnea). As many as 200 orthodontic residents participate in the Symposium and/or the Presymposium each year. Without a doubt, the Moyers Symposium is the most well-known and more importantly well-documented meeting of its kind. The evidence-based subject matter has resulted in biological and technical improvements in orthodontics and dentofacial orthopedics, within the growing discipline of craniofacial biology.

My academic career at the University of Michigan roughly parallels the emergence and maturation of the Moyers Symposium. My chronological journey started when I was a newly minted 30-year-old assistant professor when the Symposium began in 1974. Through the next five decades, that person gradually transitioned to becoming a not-so-young professor emeritus who turned 80 years of age this past summer. Fifty years is a long time, more than a professional lifetime, and much has transpired. Orthodontics has changed immeasurably since the early 1970s, and many of these changes have their roots at least in part in Moyers Symposia.

What was the academic environment at Michigan like when you first arrived in Ann Arbor?

In the early 1970s, the intellectual environment at the Center for Human Growth and Development (CHGD or Growth Center), the interdisciplinary unit that Bob Moyers founded in 1964, was wonderful. One of Bob's greatest strengths was his ability to attract world-class faculty from other universities to spend their sabbaticals in Ann Arbor. For example, Takayuki Kuroda from Japan, Frans van der Linden from the Netherlands, Alexandre Petrovic from France, Jose Carlos Elgoyhen from Argentina, and Kalevi Koski from Finland were visiting professors at various times in the 1970s. All had a lasting impact on the intellectual environment of the Growth Center.

A younger generation of orthodontists and craniofacial biologists also emerged during this time, including Lee Graber, who later led both the American Association of Orthodontists (AAO) and the World Federation of Orthodontists (WFO), Rolf Behrents, who chaired four orthodontic programs and now is the editor-in-chief of the *American Journal of Orthodontics and Dentofacial Orthopedics*, and anthropologist David Carlson, who just retired as Vice President of Research at Texas A&M Health Science Center. The four of us were the "youngsters" who took advantage of the intellectual milieu of the Growth Center. It was a stimulating time to be at Michigan.

ORIGINS OF THE MOYERS SYMPOSIUM

It is my intention to provide the reader with the insights of someone who helped plan and was present at all 50 Moyers Symposia to date and who edited or co-edited the majority of Moyers Symposium books.

How did the Symposium start?

The Moyers Symposium was created to honor Bob Moyers, Founding Director of the Center for Human Growth and Development and former chair of the Department of Orthodontics at Michigan. The driving force behind the development of the Symposium was Verne Primack, a former dental student of Bob's who received Dr. Moyers mentorship and advice at a critical time in his career. General dentist Verne Primack of Saginaw, Michigan, and his wife Naomi subsequently contacted university officials and proposed the idea of what would eventually become the Moyers Symposium. This new continuing education program was approved for the spring of 1974.

The inaugural event was held in Kellogg Auditorium, located within the School of Dentistry, with the scientific program relatively traditional in design. The Symposium lasted 1.5 days and was attended by about 200 residents, faculty, and clinicians (a very satisfactory turnout). Almost all subsequent Moyers Symposia have been held in the spacious and elegant Rackham Auditorium in the graduate school.

How was the scientific program structured?

It is interesting to look back five decades and examine the initial Moyers program. The first Symposium featured seven speakers, comprised of four orthodontists (including the younger version of me presenting my doctoral thesis material) and three researchers from other health science disciplines.

I mention the initial scientific program because the tradition of including non-orthodontists as part of the Moyers Symposium was established from the beginning. In subsequent Symposia, physicians,

general dentists, other dental specialists, psychologists, physiologists, radiologists, computer specialists, and even art historians have spoken.

The Moyers Symposium is steeped in tradition. We learned much from organizing the initial Symposium, but we also recognized that some changes would improve the event. These alterations included the establishment of the Presymposium and the creation of the Craniofacial Growth Series of monographs.

THE PRESYMPOSIUM

When and how did the “Presymposium” come into existence?

After the initial Symposium, we realized that many prominent researchers and clinicians who were not on the program—but who easily could have been—attended the first Symposium. So, as part of the second Moyers Symposium we added a day to hold what always has been called the “Presymposium,” a one-day meeting held the day before the Symposium.

By design, this meeting was structured to be smaller in attendance and much less formal in atmosphere than the Symposium. The Presymposium has evolved to typically feature 14-16 20-minute talks given by both senior researchers and junior investigators. Networking among attendees always was encouraged, especially among younger academics. Presenting at the Presymposium has been a starting point for many fledgling orthodontic educators and researchers.

The formal title of the Presymposium is *The International Conference on Craniofacial Research*, now in its 47th year. Adding the Presymposium to the schedule made the Moyers Symposium experience much more interactive, with many of these Presymposium meetings being remembered for lively interactions and more than a few forceful “discussions” among participants who held differing opinions.

THE CRANIOFACIAL GROWTH SERIES

What is the Craniofacial Growth Series?

The *Craniofacial Growth Series* (CGS) of monographs, *now available online free of charge*, contains annually published books based on the topic of each Moyers Symposium (see the table at the end of this chapter for a listing of volumes). Other books also are part of the CGS, including several cephalometric and dental cast atlases and doctoral theses. The current volume is the 59th book in the series.

How did the book publication process start?

In 1971, Bob Moyers, Don Enlow, and I, along with others in our research group at CHGD, gave a one-day course in New York at the request of Richard Sands, a major force behind the *New-Conn Orthodontic Study Group*. Part of the proceeds from that course were given to the Center for Human Growth and Development. These modest funds were used to enable publishing an annual volume that contained the transactions of the Symposium of that year. After a few volumes, the editors invited some Presymposium speakers who presented talks that were relevant to the specific topic at hand to prepare a chapter for that year’s volume, thus increasing the size and scope of each publication.

To illustrate, the first Moyers Symposium book contained seven chapters and was 131 pages in length. The volume containing the papers given at the 40th Anniversary of the Moyers Symposium contains 16 chapters and was 474 pages long. I highly recommend reading the latter volume.

A few years ago, under the guidance of Nan Hatch (Chair of Orthodontics and Pediatric Dentistry) and harnessing the digitizing technology of Google, the entire Craniofacial Growth Series was made available online at deepblue.lib.umich.edu/handle/2027.42/146667, which also is available via a link on the moyerssymposium.org site. From my perspective, the easiest way to access the Craniofacial Growth Series, however, is simply to enter “Craniofacial Growth Series/Moyers” in a Google search. The Moyers books are a substantial subseries of the Craniofacial Growth Series. The rest is self-explanatory.

To date, over 1,200 authors have contributed over 14,000 pages of text to the Moyers Symposium book series. Now, the text and illustrations are downloadable worldwide.

YEARLY SELECTION OF TOPIC

Who selects the topic for the Moyers Symposium each year?

Picking the topic for the Moyers Symposium was relatively easy during the first decade but is not so anymore. Over a 50-year span, people come and go, directors and department chairs are named, serve for 10 or so years and then move on or retire. The same goes for tenured and non-tenured faculty. So, over a given decade or 2, there usually is great flux within the planning committee. Now there is an even wider choice of possible topics, especially with the obvious improvements in technology that have occurred during the last few decades. Ideally there should be two to three topics under consideration each year, with some of these topics discussed two or three years ahead of their expected use.

As the support for the Symposium gradually shifted from the Center for Human Growth and Development to the Orthodontic Department beginning in the early 1980s, the influence of the Chair of Orthodontics on the Symposium increased. The following five Chairs of Orthodontics had a significant influence: Peter Vig, Jim McNamara (Interim Chair for 4 years during the dental school restructuring), Lysle Johnston, Sunil Kapila, and Nan Hatch. The interests of each chair often were reflected in the choice of topics and speakers, as can be seen in the attached list of Symposium topics during the last 50 years.

Currently, the Moyers Symposium primary planning committee includes Nan Hatch, Hera Kim-Berman, Lucia Cevitanes, Marilia Yatabe, Aron Aliaga and me.

MEMORABLE SPEAKERS

Which Moyers speakers are most memorable to you personally?

This question is a tough one to answer, because each year we were able to secure the participation of almost all the speakers we wanted concerning a specific topic. I first want to mention my two top choices, Drs. David Sackett and Vincent Kokich.

In my opinion, the single Moyers Symposium speaker who had the greatest impact on the orthodontic specialty is the late David Sackett MD, an American Canadian and a pioneer in evidence-based medicine. David participated in three Symposia that spanned nearly 30 years. Bob Moyers met David in the early 1980s and realized that his expertise in evidence-based medicine would be an excellent topic to discuss at

the 1985 Symposium, the theme of which was “Science and Clinical Judgment in Orthodontics.” Sackett was critical of the lack of randomized clinical trials conducted by orthodontists, saying that in his view most clinical decisions in orthodontics were based more on rhetoric than on science.

David Sackett returned in 1994 and gave a much more positive appraisal of evidence-based orthodontic treatment, much to his surprise and delight. At the 40th anniversary meeting in 2013, the topic of his presentation was “The Vanishing Need for MD Randomized Trialists at Moyers Symposia,” indicating that in his judgment, the orthodontic specialty had transitioned from rhetoric-based to evidence-based clinical decision making.

David Sackett often has been called the *father of evidence-based medicine*. He similarly had an impact on the quality of orthodontic therapy by providing a pathway forward that today seems a common-sense approach to orthodontic diagnosis and treatment planning, based on evidence provided by a myriad of clinical trial methodologies and a pyramid of evidence.

The second Moyers Symposium speaker worthy of particular mention is the late Vincent Kokich from the University of Washington. When planning the 40th anniversary celebration in 2013, Vince was the first speaker to be contacted by the planning committee because of his worldwide reputation as a lecturer, interdisciplinary clinician and educator. His presentations always were clear and to the point. Over the years I have heard many presentations by Vince Kokich; his style and eloquence were at the top.

Vince first spoke at the Moyers Symposium over 30 years ago at the conference entitled “Bone Biodynamics in Orthodontic and Orthopedic Treatment.” He prognosticated the use of implants as anchorage in orthodontics long before this therapeutic approach became a clinical reality.

His second appearance was in 2000 when he presented the now classic research that he and his son Vince Jr. conducted on the perception of orthodontists, dentists, and the lay public. His final presentation in 2013 was as keynote speaker at the 40th anniversary celebration, where he outlined a clinical roadmap to deal with the adult patient that Vince said should be understood by all dental specialists and generalists.

I have many good memories of Vince, having known him for at least four decades. My last interaction with him was two days before he passed away unexpectedly on July 24, 2013. I served as the editor of the 40th anniversary volume. Vince and I had a brief conversation about his chapter, which as usual needed minimal changes. We then moved on to a long and comfortable discussion about his plans for future projects. Vince was an excellent resource for not only Moyers Symposium speakers but also for Annual Session and Midwinter AAO Meeting presenters. He was the Editor-in Chief of the *American Journal of Orthodontics and Dentofacial Orthopedics* (AJODO), so he felt perhaps earlier than most orthodontists the pulse of current and future clinical treatments and research directions.

OTHER OUTSTANDING SPEAKERS

Which other Moyers Symposium speakers are on your list?

In preparation for writing this chapter, I once again have gone through all the Moyers books in detail and have identified speakers who—to me alone—were memorable for a variety of reasons. *The scientific method was not applied to this one-person selection process*. Below are my choices.

- 1975 **Alexandre Petrovic**, The University of Strasbourg, France. A physician and bone biologist whose research led to a better understanding as to how the mandibular condyle responded to changes in the biomechanical and hormonal environment. His emergence as a respected scientist in our specialty paralleled the emergence of the Symposium itself as a forum for intellectual thought and debate concerning timely topics in orthodontics and craniofacial biology.
- 1976 **Lysle Johnston**, Orthodontics, St Louis University. One of the more famous controversies/debates was that between Lysle and **Melvin Moss** (Anatomy, Columbia University) on how the face grows. Lysle and Mel both have made many other contributions to the Craniofacial Growth Series. I refer the reader to Lysle's Preface in Volume 41, Growth and Treatment: A Meeting of the Minds (2003).
- 1976 **Arne Björk**, Copenhagen, Denmark. At that time, I was carrying out rhesus monkey research using Björk tantalum implants as bone markers when measuring the growth of the mandibular condyle, and Arne Björk was one of my heroes. Having Arne Björk sitting next to Alex Petrovic in the living room of our home the night before the 1976 Symposium was memorable, as later was the case for many other notable researchers and clinicians on other occasions.
- 1979 **Egil Harvold**, Center for Craniofacial Anomalies, University of California, San Francisco (UCSF). Norwegian-born orthodontist who presented his now classic studies of forced nasal breathing in rhesus monkeys, illustrating how the growth of the face can be altered by respiratory blockage. (I had a particular connection to Egil in that he was one of my instructors at UCSF, and his daughter Ingun was one of my orthodontic classmates.)
- 1982 **Rolf Fränkel**, Orthopedic Clinic, Zwickau, German Democratic Republic. Shortly before this Symposium, Rolf was notified by the government of then East Germany that he could not travel abroad (for political reasons). I presented his paper at the Symposium, and Rolf provided us with the text and figures so that his chapter could be included in the annual monograph. Early in my career, Rolf had the biggest impact on my thinking concerning functional jaw orthopedics.
- 1983 **Björn Zachrisson**, Orthodontics and Periodontics, University of Oslo, Norway. Addressed periodontal changes that occur during orthodontic treatment. One of the best speakers that I ever have had the pleasure to hear. A very practical clinician. When I was put in charge of Orthodontic Continuing Education at Michigan, Björn was the first speaker I contacted.
- 1984 **JMH (Jos) Dibbets**, Orthodontics, University of Groningen, the Netherlands. Provided an excellent perspective concerning temporomandibular joint (TMJ) dysfunction and craniofacial growth in children. Jos spent two one-year sabbaticals with us, and we soon realized how insightful he was in addressing and solving complex problems.
- 1988 **Rolf (Buzz) Behrents**, Orthodontics, University of Tennessee, Memphis. This speaker literally "wrote the book" concerning skeletal and soft tissue changes that occur in late adolescents and adults. This work was based on long-term follow-up studies gathered through the Bolton-Brush Growth Study at Case Western Reserve University. Buzz remains a close friend.
- 1992 **Clifford Olds**, Artist and art historian, Bowdoin College, Brunswick, ME. The 1992 Moyers Symposium wandered far from its roots in biology with the addition of several art historians who discussed facial esthetics, with citations of Cicero, Galen, and Plato in the references. Olds' chapter is an interesting read as is the entire volume.
- 1993 **Samuel Dworkin**, Departments of Oral Medicine and Psychiatry and Behavioral Sciences, University of Washington, Seattle. Presented a model for understanding chronic pain that

- includes the integration of biological, psychological, and social/cultural influences on the chronic pain experience.
- 1994 **Sheldon Baumrind**, Department of Growth and Development and Craniofacial Research Instrumentation Laboratory, UCSF. Shelly was a frequent participant in the Moyers Symposium and at the Presymposium, and he is the father of the AAO Foundation Legacy Collections Cephalometric Project. This chapter is from an outstanding volume on evidence-based treatment. An excellent monograph in total.
- 1995 **Peter Frensch**, Max-Planck Institute for Human Development and Education, Berlin, Germany. Presented an interesting discussion on why people make mistakes from the perspective of a cognitive psychologist. He provides an interesting perspective on the nature and sources of human error. An excellent chapter from a non-orthodontic expert.
- 1997 **Mikhail Samchukov**, Biological Sciences, Baylor College of Dentistry, Dallas. I remember this lecture very well. The speaker presented a straightforward discussion of the biological basis of distraction osteogenesis. He discussed how this technique was developed historically and described a series of animal experiments that define the biological mechanisms involved in this process. Well worth the read.
- 1998 **Lee Graber**, Private practice of orthodontics, Kenilworth, IL. This volume celebrated the 25th anniversary of the Moyers Symposium. Even though I had been the editor of that volume, I had forgotten that Lee had volunteered to write a Preface for this special edition. I refer the reader to Lee's Preface, which not only provides a nice summary of the volume, but he also addresses indirectly the culture that has arisen since the Symposium began. Lee also remains a close friend from our early days at the Center for Human Growth and Development.
- 1999 **William Proffit**, Orthodontics, University of North Carolina. Bill was a long-time supporter of the Moyers Symposium and helped with the selection of speakers on many occasions. Bill made an important contribution to our discussion of the vertical dimension by writing a concise initial chapter on the development of vertical dentofacial problems.
- 2000 **David Sarver**, Private practice, Vestavia Hills, AL. A good friend of mine, David has provided a lengthy chapter replete with high-quality illustrations on understanding how the soft tissue interrelates with treatment for functional problems. He provides many clinical pearls to help the clinician maximize both esthetic and functional treatments. See the initial chapter written by Vince Kokich as well.
- 2001 **Hans Pancherz**, Orthodontics, University of Giessen, Giessen, Germany. The late Hans Pancherz is the father of modern Herbst appliance therapy. In my opinion, because of the clinical studies of Pancherz and his many colleagues, more is known about the treatment effects produced by the Herbst appliance than of any other orthodontic or orthopedic approach to Class II treatment.
- 2003 **Harold Slavkin**, Craniofacial Molecular Biology, Dentistry, University of Southern California. Hal presented a memorable lecture on "Biological Solutions to Biological Problems." He explained to the non-molecular biologists in the audience the importance of the Human Genome Project. This presentation was thought provoking, especially given the level of available knowledge on this subject 20 years ago.
- 2004 **Birte Melsen**, Orthodontics, University of Aarhus, Aarhus, Denmark. Birte has been a prolific clinical researcher in many aspects of treatment. Her chapter deals with specific indications for skeletal anchorage in orthodontic treatment, both in actively growing and minimally growing patients.

- 2005 **David Hatcher**, Radiology and Oral and Maxillofacial Surgery, UCSF, and private practice of radiology, Sacramento CA. When digital radiology became available, David stepped forward as a very knowledgeable radiologist with an ability to make this new technology understandable to dental specialists and generalists. His chapter covers the role of cone beam computed tomography (CBCT) in orthodontics and imaging goals and strategies. The performance and responsibilities of the companies providing the units also are considered.
- 2006 **Tiziano Baccetti**, Orthodontics, University of Florence, Italy. Tiziano, a close friend who died tragically in 2011, made many contributions to the Craniofacial Growth Series, including two chapters in the 2006 volume. Tiziano had a strong interest in evidence-based orthodontics. He also was one of the principal researchers who modified the Cervical Vertebral Maturation method, originally described by Don Lamparski in his 1972 thesis.
- 2007 **Hee-Moon Kyung**, Orthodontics, Kyungpook University, Daegu, Korea. He was an early adopter of the microimplant treatment method. He and his colleagues provide a thorough overview of site selection and implantation methods. Their chapter includes excellent color illustrations that clarify the points that the authors are making. Overall, this lengthy volume is an excellent clinical resource.
- 2008 **Christian Stohler**, Dean, Oral and Maxillofacial Surgery and Prosthodontics, University of Maryland. Christian was at Michigan from 1979 to 2002. His chapter on “Temporomandibular Joint Diseases and Disorders” introduces the reader to future TMJD treatments. This 488-page book provides a variety of perspectives on a perplexing group of temporomandibular problems.
- 2009 **Sean Edwards**, Oral and Maxillofacial Surgery, The University of Michigan. Sean presents an overview of computer-assisted surgery in the treatment of craniomandibular disharmonies, incorporating CBCT imaging into the diagnostic and treatment planning process. He has been a leader in adapting CBCT imaging to routine orthognathic surgery and well as to the management of more complex problems. Excellent illustrations.
- 2013 **Lorenzo Franchi**, Orthodontics, University of Florence. A close friend of mine. Lorenzo reports the results of a meta-analysis concerning the use of functional jaw orthopedics in skeletal Class II patients. Results show that such treatment has favorable effects on mandibular growth only when treatment is performed during the pubertal growth phase. See also Lorenzo’s chapter in the current volume that considers the same topic in greater depth. Lorenzo and I have collaborated for nearly 30 years.
- 2020 **Nan Hatch**, Orthodontics, University of Michigan. Nan provides a thorough discussion of the intersection of basic science with clinical practice as it pertains to moving teeth clinically. Tooth movement requires the conversion of mechanical forces into biological signals by mechanosensitive cells. She explains how this phenomenon of cell recruitment happens in detail and how this knowledge might be translated into orthodontic patients.
- 2023 **Lucia Cevidanes**, Orthodontics, The University of Michigan. Lucia's chapter marks a pivotal shift in orthodontic diagnostics, detailing the integration of artificial intelligence (AI) with CBCT imaging to enhance decision-making processes. Her work underscores a transformative approach, where AI algorithms interpret complex craniofacial data, offering clinicians sophisticated diagnostic support systems that promise precision and efficiency in treatment planning.

There are many other speakers who deserve to be mentioned in this list, but I have chosen to stop here. Many of the choices are based on what I heard during their lectures and also on editing or reading the chapter that each submitted to the volume.

I am sure that if I repeated the selection process two weeks or two years from now, some new speakers would be added, and some previous choices would be deleted. I apologize to anyone whom I have offended. But the reader now knows my opinion as of very late 2023.

This piece is unlike any other paper I have submitted for publication. There is no way a person could sit through 50 years of the Moyers Symposia and not understand the importance of evidence-based research. My career has been based in great part on that premise.

In many respects, the listings that I have provided above can be considered the “art” side of the “art and science” of research. My impressions are based on not only what I have heard and read personally but also on the experience of others, such as those memorable speakers mentioned above.

This evaluation process has been an interesting and enlightening experience. I hope the reader uses my comments as a guide when trying to evaluate what to read first when beginning to undertake the *Craniofacial Growth Series/Moyers* search.

FINAL COMMENTS

Timing is everything! This simple statement is so true when I look back over my career. I was at the right place at the right time, and those in charge recognized something in me, and in Buzz Behrents, Lee Graber, and David Carlson, to let us each blossom and prosper in our own way. They gave us the freedom to find our own space, and because we all worked together, we continued to succeed, as did the Moyers Symposium.

Today, the Moyers Symposium is so much more than a scientific meeting. It is an annual reunion not only of Michigan alumni, but of the friends of Michigan Orthodontics who have become an extended part of the Michigan family. That statement may sound trite, but it is accurate in my opinion.

At each Symposium at noon just before lunch on the first day, we ask the audience to rise. By their presence, they have attended one Symposium. The audience then is asked to remain standing if they have attended 2 Symposia, then 3 Symposia, then 4, 5, 10, 20, 30, and 40 Symposia. The number of attendees still standing at 10 Symposia and above is remarkable.

The most recent addition to the Symposium program is the occasional use of the Skyboxes at Michigan Stadium for the Saturday night reception. Adding such a grand event space has made the Moyers Symposium even more special.

With these comments I close my personal recollection of the events that occurred during my personal journey from 30 to 80—years that is. The Moyers Symposium has been integral to my development both professionally and personally. It has occurred to me many times over the last 50 years that I have benefitted more than anyone else from my continuous involvement with the Moyers Symposium.

It has been a memorable journey! Thanks for reading this memoir. Jim McNamara

Moyers Symposium Books (1974 – 2023)

Year	Symp	CGS Vol#	
1974	1	3	Control Mechanisms in Craniofacial Growth
1975	2	4	Determinants of Mandibular Form and Growth
1976	3	6	Factors Affecting the Growth of the Midface
1977	4	7	The Biology of Occlusal Development
1978	5	8	Muscle Adaptation in the Craniofacial Region
1979	6	9	Naso-respiratory Function and Craniofacial Growth
1980	7	11	Psychological Aspects of Facial Form
1981	8	12	Effect of Surgical Intervention on Craniofacial Growth
1982	9	14	Clinical Alteration of the Growing Face
1983	10	15	Malocclusion and the Periodontium
1984	11	16	Developmental Aspects of Temporomandibular Disorders
1985	12	19	Science and Clinical Judgment in Orthodontics
1986	13	20	Craniofacial Growth during Adolescence
1987	14	21	Craniofacial Morphogenesis and Dymorphogenesis
1988	15	22	Orthodontics in an Aging Society
1989	16	23	Craniofacial Growth Theory and Orthodontic Treatment
1990	17	25	Clinical Research as the Basis of Clinical Practice
1991	18	27	Bone Biodynamics in Orthodontic and Orthopedic Treatment
1992	19	28	Esthetics and the Treatment of Facial Form
1993	20	29	Biological and Psychological Aspects of Orofacial Pain
1994	21	30	Orthodontic Treatment: Outcome and Effectiveness
1995	22	31	Orthodontic Treatment: Management of Unfavorable Sequelae
1996	23	33	Creating the Compliant Patient
1997	24	34	Distraction Osteogenesis and Tissue Engineering
1998	25	35	Growth Modification: What Works, What Doesn't, and Why
1999	26	36	The Enigma of the Vertical Dimension
2000	27	38	Frontiers in Dental and Facial Esthetics
2001	28	39	Treatment Timing: Orthodontics in Four Dimensions
2002	29	40	Information Technology and Orthodontic Treatment
2003	30	41	Growth and Treatment: A Meeting of the Minds
2004	31	42	Implants, Microimplants, Onplants and Transplants: New Answers to Old Questions
2005	32	43	Digital Radiography and Three-dimensional Imaging
2006	33	44	Early Orthodontic Treatment: Is the Benefit Worth the Burden?
2007	34	45	Microimplants as Temporary Orthodontic Anchorage
2008	35	46	Temporomandibular Disorders and Orofacial Pain: Separating Controversy from

			Consensus
2009	36	47	Surgical Enhancement of Orthodontic Treatment
2010	37	48	Effective and Efficient Orthodontic Tooth Movement
2011	38	49	Taking Advantage of Emerging Technologies in Clinical Practice
2012	39	N/A	CBCT in Orthodontics: Indications, Insights & Innovations (Not available; volume published elsewhere)
2013	40	50	The 40 th Moyers Symposium: Looking Back...Looking Forward
2014	41	51	Expedited Orthodontics: Improving the Efficiency of Orthodontic Treatment Through Novel Technologies
2015	42	52	Interdisciplinary Therapy: Using Contemporary Approaches for Complex Cases
2016	43	53	Anecdote, Expertise and Evidence: Applying New Knowledge to Everyday Orthodontics
2017	44	54	Sleep Apnea: What Every Clinician (and Patient) Should Know
2018	45	55	Effective, Efficient and Personalized Orthodontics: Patient-centered Approaches and Innovations
2019	46	56	Embracing Novel Technologies in Dentistry and Orthodontics
2020	47	57	Controversial Topics in Orthodontics: Can We Reach Consensus?
2021	48	---	<i>Cancelled – COVID-19</i>
2022	49	58	Management of Deep Bite and Posterior Open Bite in Clinical Practice
2023	50	59	The 50th Moyers Symposium Anniversary Monograph: Reflections and Advances on 100 Years in Orthodontics

MINISCREW IMPLANTS (MSIs) AND ORTHOPEDICS: THEIR INFLUENCE ON PRESENT AND FUTURE ORTHODONTIC PRACTICE

Peter H. Buschang, Samuel I. Roldán

ABSTRACT

The advent of miniscrew implants (MSIs) has changed orthodontics in profound and long-lasting ways. They provide direct and indirect skeletal anchorage, allowing orthopedic forces to move bones rather than teeth. For patients in the permanent dentition, MSIs have successfully been used to expand the dental arches, with minimal dentoalveolar bending and little or no dental tipping. They have been used in hyperdivergent retrognathic Class IIs to control vertical tooth movements and produce true forward mandibular rotation, which makes orthopedic correction of the patients' anteroposterior and vertical skeletal problems possible. For Class IIIs in the permanent dentition, MSIs have produced skeletal changes like those previously only possible with miniplates or surgery. Since facial skeletal discrepancies in all three dimensions develop early and worsen over time, shorter MSIs are needed for early treatment during the primary and mixed dentitions. To this end, 3 mm long MSIs have been developed. They substantially decrease the possibility of tooth contacts during and after insertion; they have also been shown to be stable clinically and experimentally. These shorter MSIs have been recently redesigned to enhance their secondary stability by increasing surface area and new insertion tools have been developed to facilitate the insertion process.

KEY WORDS: Orthopedics, Miniscrew implants, Craniofacial growth, Skeletal modeling

INTRODUCTION

The American Journal of Orthodontics changed its name to the American Journal of Orthodontics and Dentofacial Orthopedics in July 1986. That was when the profession officially decided that orthodontists should be guiding facial growth and development (i.e., definition of orthopedics). For most orthodontists, orthopedics has been limited to the midface, to guiding the growth of the maxillary sutures through expansion and protraction. Importantly, orthopedics is not restricted to the midfacial sutures. It also involves the reshaping of bones by cortical surface modeling. It has been well established that the skeletal adaptation of bone depends directly on the stresses placed upon them. When bones are loaded in compression, tension, or torsion, they deform. The strains associated with the deformations cause the fluid within bone to move past the cell membranes of osteocytes, which in turn produce signaling molecules to model bone. This is how mechanical signals are turned into biochemical signals - a process called mechanotransduction.

The major determinants of sutural growth and midfacial bone modeling are rotation and translation. Both displace the midface, which in turn triggers the sutural growth and modeling that occurs during growth. Displacements are the causes, and the sutural growth and surface modeling are the effects (Figure 1). Similarly, anything that prevents the translation and rotation of the midface prevents sutural growth and surface modeling. For example, genetically and traumatically associated synostoses, achondroplasias,

surgically repaired cleft lips and palates, and nasal septum surgery can limit midfacial displacements, which will inhibit sutural growth and surface modeling, causing midfacial deficiencies.

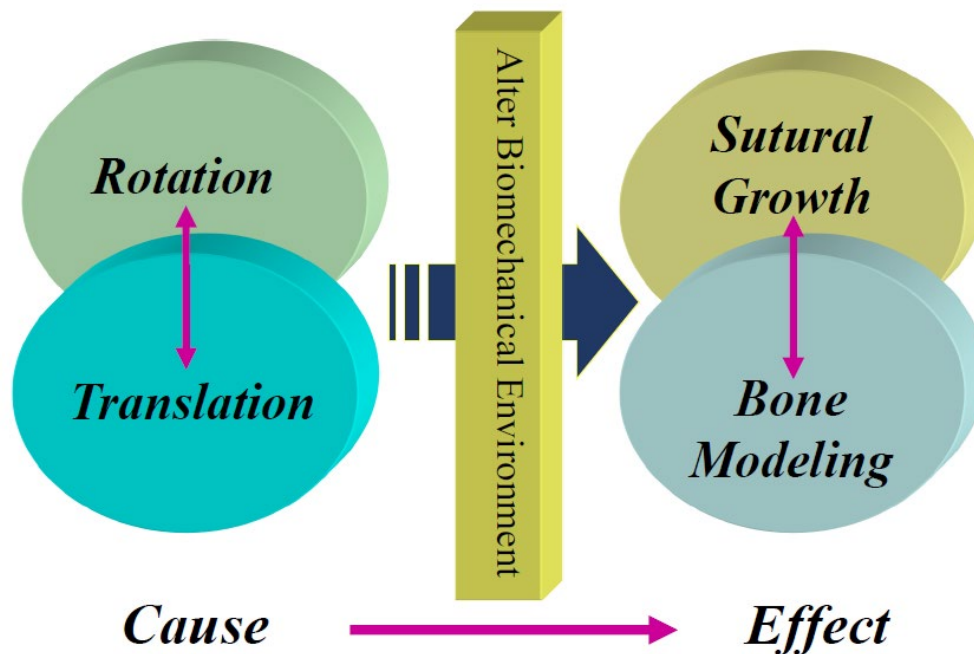


Figure 1. Maxillary rotation and translation altering the biomechanical environment and causing sutural growth and bone modeling.

Orthodontists are typically more sanguine about mandibular orthopedics. A long-held belief in orthodontics is that it is not possible to change mandibular growth. This notion was started by the apical base school of thought, and propagated by orthodontic leaders, including Mershon, Broadbent, Thompson, and Brody. They and their students have had profound long-lasting effects on orthodontists' views concerning mandibular orthopedics.

Mandibular bone, just like any other type of bone, is capable of adapting. The mandible is best thought of as a bar of bone extending from the condylar neck to the chin, surrounded by various functional processes. These processes, including the condylar, coronoid, dentoalveolar, and gonial process, respond to functional loads. The functional loads are produced by the muscles of mastication and dentition. The amounts and directions of load change during growth due to growth of the muscles and changes in muscle orientation due to mandibular displacements. In addition, the processes adapt when the functional loads increase or decrease. For example, unilateral removal of the temporalis muscle causes the coronoid process to resorb [1]. Resorption occurs when muscle forces are eliminated, which alters bone strain and reduces unnecessary bone mass. As with the midface, mandibular growth adapts whenever the mandible is rotated or translated. Displacements alter the strain patterns, which in turn alter the condylar growth and surface modeling of the mandible.

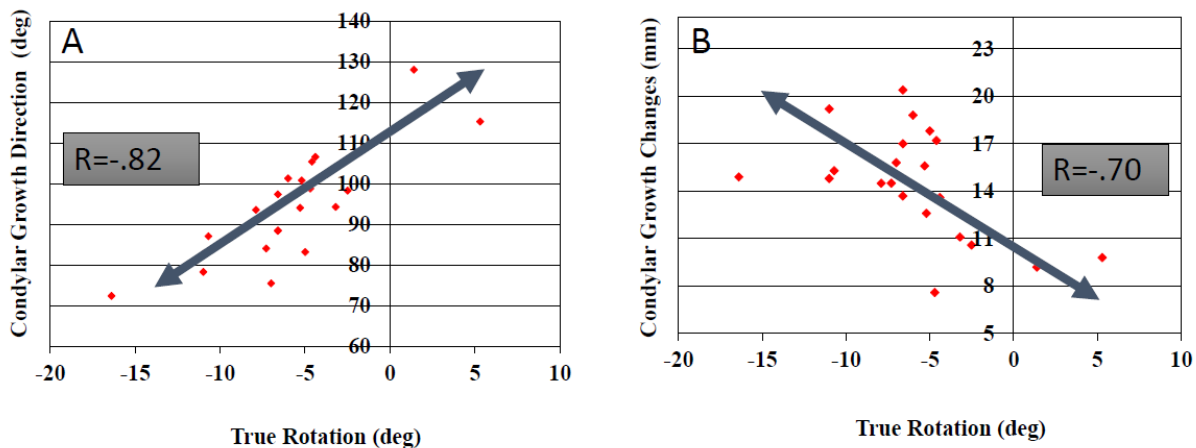


Figure 2. True mandibular rotation (negative and positive values denote forward and backward rotation, respectively) is related A) positively to condylar growth direction, and B) negatively to the rate of condylar growth (adapted from Björk and Skieller, 1972).

True rotation and translation are directly associated with growth and modeling changes of the mandible. Björk and Skieller [2] showed a direct relationship between true rotation and condylar growth. Untreated subjects who exhibit greater true forward rotation of the mandible have condyles that grow in more superoanterior directions (Figure 2A) and at greater rates (Figure 2B). True rotation is also related to the modeling pattern on the lower border of the mandible, with greater amounts of resorption along the inferior ramus being associated with greater true forward rotation of the mandible (Figure 3). These relationships have been confirmed on larger samples; importantly, these adaptive changes apply to the entire ramus, not just the condyle (Figure 4). Pure translation of the mandible also produces predictable growth changes, with greater anterior translation associated with greater amounts of posterior growth of the superior ramus and less modeling on the inferior ramus [3].

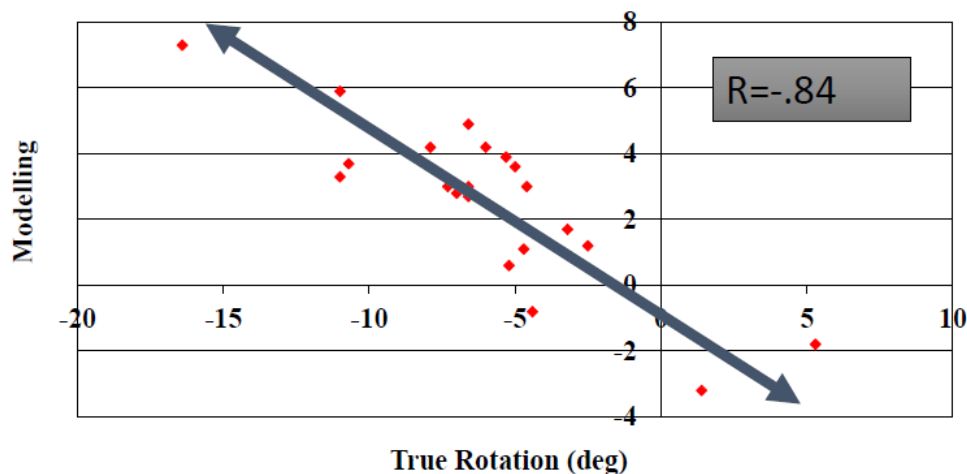


Figure 3. True mandibular rotation (negative and positive values denote forward and backward rotation, respectively) is related negatively to modeling of the mandible's lower border (adapted from Björk and Skieller, 1972).

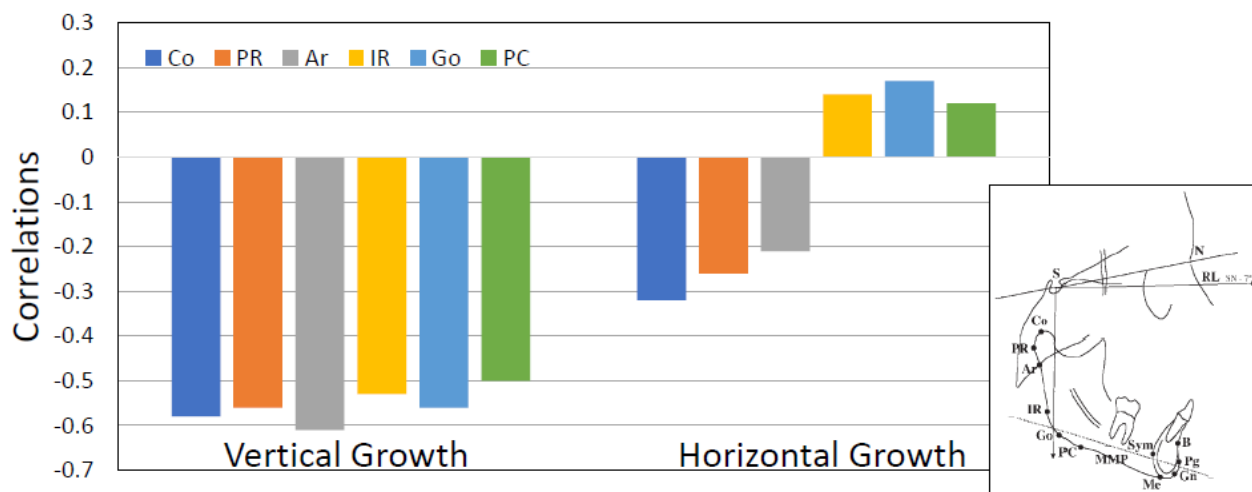


Figure 4. Correlations between true mandibular rotation and the A) vertical, and B) horizontal growth of the ramus (adapted from Buschang and Gandini 2002).

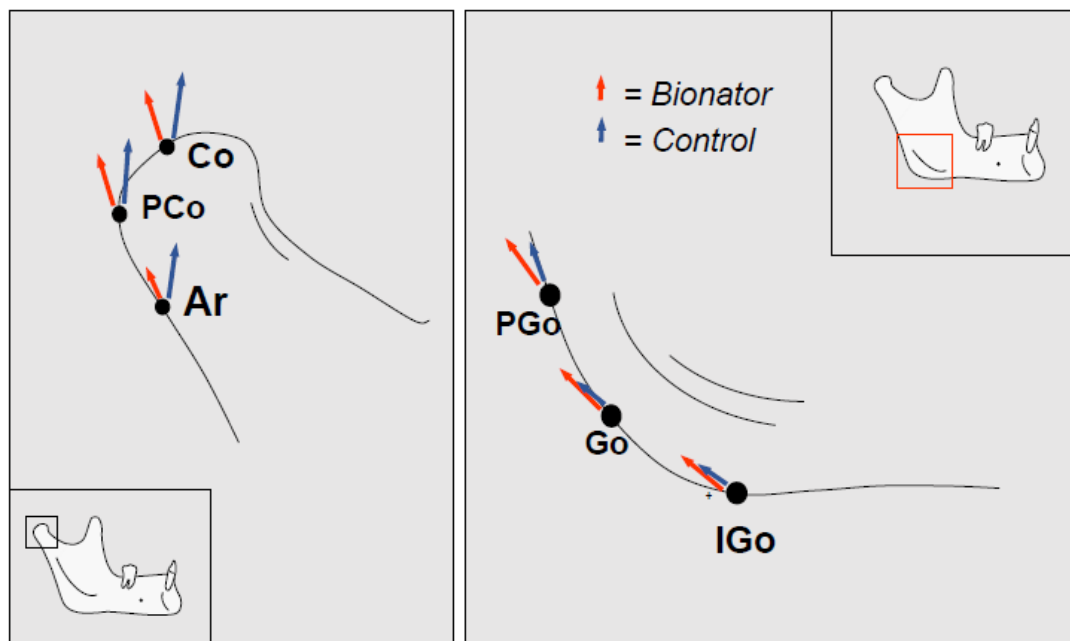


Figure 5. Condylar growth and mandibular modeling changes associated with bionator therapy (adapted from Araujo et al 2004).

The associations relating mandibular rotation and translation to the growth and modeling changes that occur provide principles to better understand growth and treatment effects. In 1979, McNamara and Carlson [4] demonstrated that the mandibular condyle can be predictably influenced by changing the biomechanical and biophysical environment of the temporomandibular joint (TMJ). They showed that functional appliances alter the direction of condylar growth in a more posterior direction, which the

principles tell us should be expected when the mandible is protracted and rotated down slightly. Since then, it has been well established that functional appliances alter condylar growth direction. And, again according to the principles, the effects are not limited to the condyles. A randomized controlled trial (RCT) comparing Bionator patients to controls showed that the entire ramus responded in a predictable manner to the functional appliance treatment [5]; the condyles grew in a more superoposterior direction, as did other modeling sites on the ramus (Figure 5). Based on these principles, treatments that rotate the mandible forward would be expected to change the growth direction in the opposite – more superoanterior - direction, and this is exactly what happens. Growing patients with vertical maxillary excess who underwent Leforte surgery and forward mandibular auto-rotation changed condylar growth and ramus modeling toward a more superoanterior direction after surgery [6]. With the advent of skeletal anchorage, it has become possible to more reliably control maxillary and mandibular rotation and translation, and thereby better control the orthopedic changes that occur.

THE USE OF MSIs FOR TREATING TRANSVERSE DEFICIENCIES

Currently, the most common orthopedic procedure performed by orthodontists is maxillary expansion. While slow expansion is performed in younger children, rapid maxillary expansion (RME) is more common among older children, adolescents, and adults. RME produces sutural expansion, dental alveolar bending, and dental tipping. The goal is to maximize sutural separation, which is more stable than dentoalveolar bending and dental tipping. This can be accomplished with skeletal anchorage. The miniscrew-assisted rapid palatal expander (MARPE) appliance, which is a modified rapid palatal expander (RPE) that incorporates miniscrew implants (MSIs) to enhance the expansion of basal bone, minimizes dentoalveolar bending and dental tipping (Figure 6).

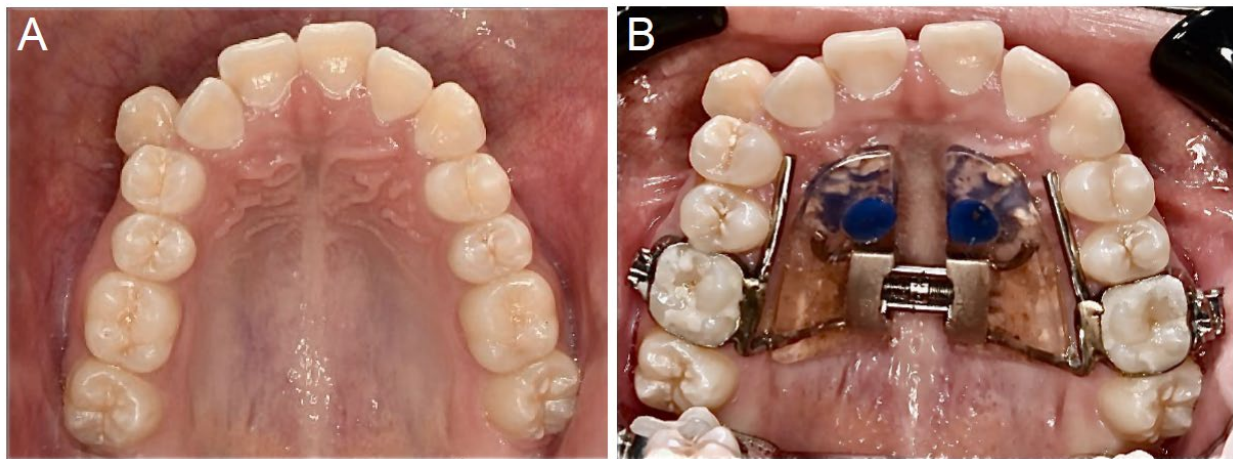


Figure 6. Transverse maxillary deficiency in a female adolescent patient treated with MARPE. A) Pretreatment at 14.2 years and B) postexpansion at 14.3 years (Courtesy Drs. Jaime Vera-Giovanni Oberti).

A recent umbrella review of four systematic reviews including 792 patients reported a mean success rate of 92.5% for MARPE appliances [7]. It showed that the MARPE appliances produced greater amounts of skeletal expansion than the RPE, but less expansion than the surgically assisted rapid palatal expansion (SARPE). It also has been shown that there is less apical root resorption with MARPEs than RPEs [8]. A recent RCT showed that MARPEs produced almost three times as much sutural expansion (3.6 vs 1.3 mm posteriorly; 3.1 versus 1.1 mm anteriorly) as RPEs [9]. In contrast, RPEs produce significantly more buccal bone bending and greater buccal proclination of teeth. MARPEs

also appear to be effective for midpalatal expansion of at least some adults. Based on 78 young adults evaluated prior to treatment and again three weeks post-expansion, Almqrami and coworkers reported 3.1 mm and 3.4 mm of expansion in the posterior and anterior aspects of the midpalatal suture, respectively [10], which are similar to the amounts of expansion achieved in growing patients.

THE USE OF MSIs FOR TREATING HYPERDIVERGENT RETROGNATHIC CLASS IIs

Hyperdivergent retrognathic Class II patients have a host of skeletal and dental problems that make them among the most difficult to treat (Figure 7), including supraerupted teeth, transverse maxillary deficiencies, retrognathic and hyperdivergent mandibles, posterior deficiencies and anterior vertical excesses, larger gonial angles, and more posterior directed condylar growth [11]. Funded by the National Institutes of Health, the Baylor Intrusion Protocol was developed to treat these growing patients by controlling the vertical eruption of their teeth. The basic idea is to intrude or prevent the eruption of the posterior segments, which causes the mandible to rotate forward. True forward rotation advances the chin and the mandibular dentition, reduces lower facial height, and changes condylar growth in a more superoanterior direction. This treatment approach is based on the basic growth principles that associate true mandibular rotation with condylar growth and mandibular modeling in growing subjects [2, 3].

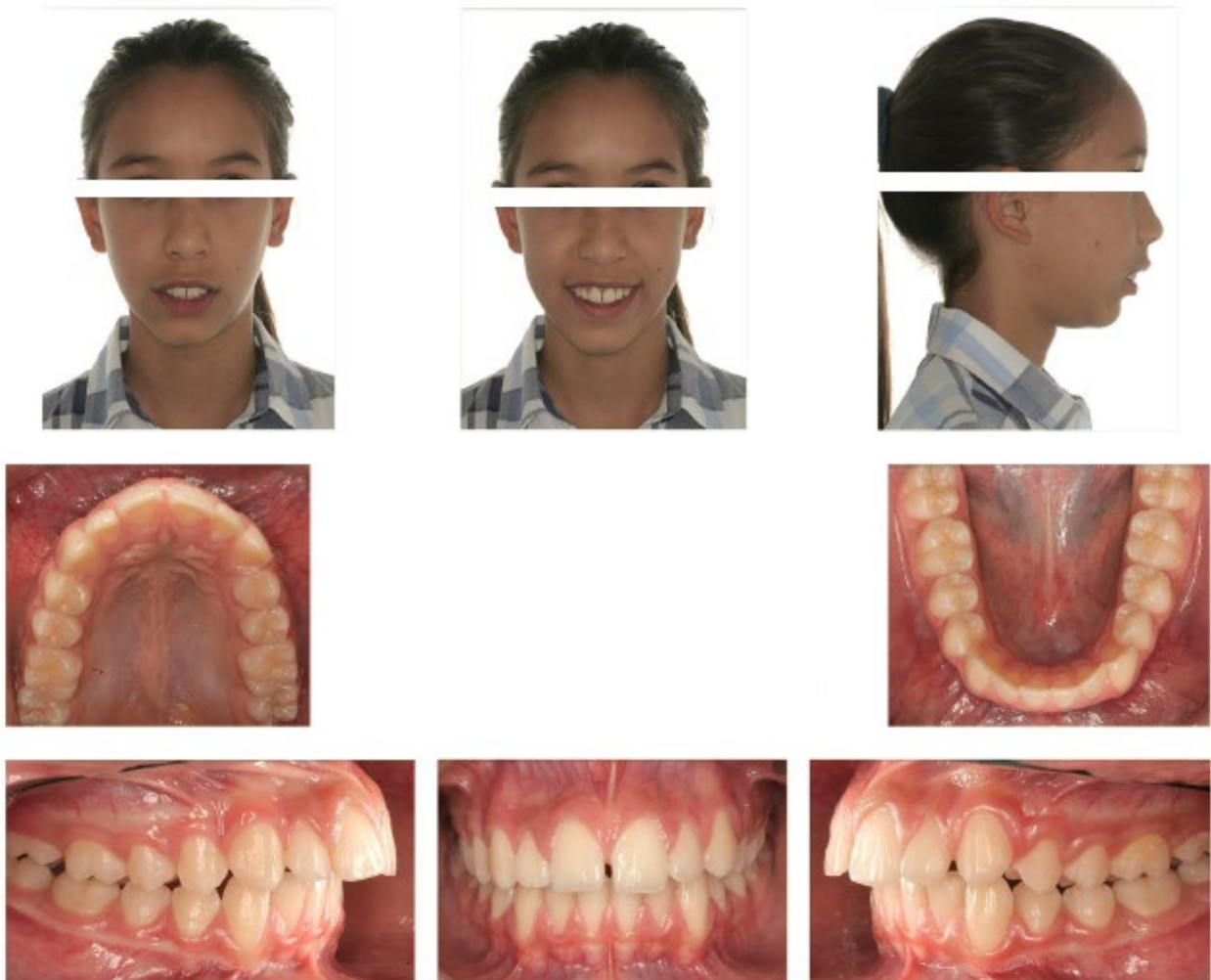


Figure 7. Extra and intraoral photographs of a prepubertal Class II hyperdivergent 12.8 year old female patient.

A Dentaurem Variety SP® RPE is used initially as an expander, and later as a rigid segmental unit for the intrusion of the posterior teeth. To allow for intrusion, the expander's screws and arms must be maintained at least 3 mm from the palatal tissues. The expander is activated twice daily until the maxillary palatal cusps contact the mandibular buccal cusps. Once expansion and retention are completed, two 8 mm long MSIs are placed bilaterally (without pilot holes or tissue punches) between the apices of the 5s and 6s where the palatal roof and lingual walls meet. They are placed after a 30 second chlorhexidine rinse, followed by topical anesthesia and local infiltration. Coil springs calibrated to 150 g are extended from the MSIs to the RPE frame (Figure 8A). The upper anterior teeth are used to assess leveling of the occlusal plane and are therefore not initially bonded. Braces are placed on the first and second premolars and an archwire extends from the first premolar to the first molar band, forming a segment. Occlusal rests extend from the RPE frame to the second molars to prevent their eruption. After intrusion is complete, the RPE is removed, a transpalatal arch (TPA) is inserted for torque control, and fixed appliances are bonded. The MSIs are tied to the TPA with ligatures to control the vertical positions of the teeth during the rest of treatment.

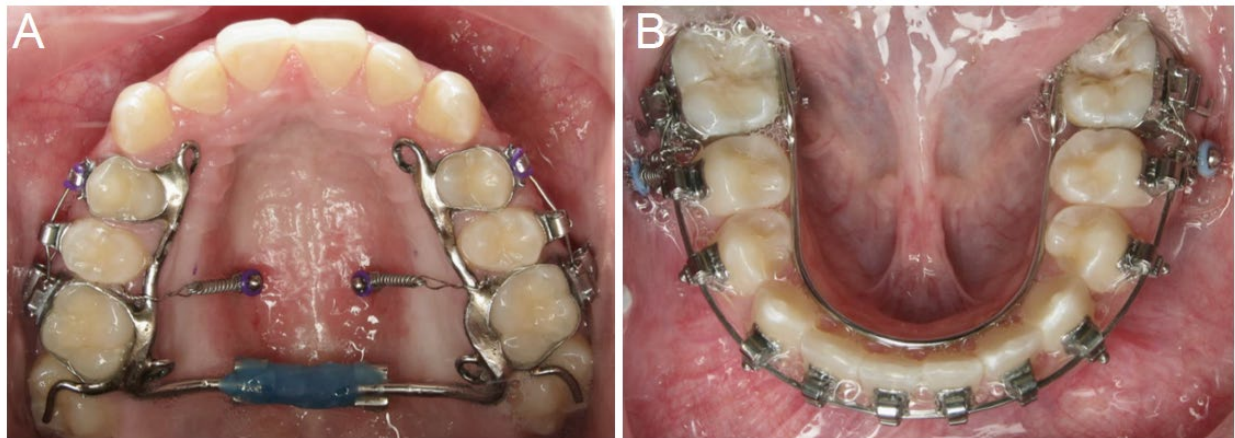


Figure 8. The Baylor Intrusion Protocol uses skeletal miniscrew anchorage to intrude and/or hold the vertical eruption of teeth in growing patients.

In the mandibular arch, bands are placed on the molars and fixed appliances are placed on the remaining teeth (Figure 8B). At least 4 mm of space is needed between the second premolars and first molars to make room for the MSIs. Once the spaces are created and the arch is sufficiently leveled to place a .016 X .022 inch stainless steel wire, two 8 mm MSIs are inserted (without pilot holes or tissue punches) using the two-step insertion technique [12]. For individuals with little or no growth potential, Sentalloy coil springs delivering 150 g forces are extended from the MSIs to the molar bands and a lingual arch is placed to prevent the tipping of teeth being intruded. No active intrusive forces are needed for the mandibular teeth of growing patients. Relative intrusion is accomplished by ligating the MSIs to the first molar bands. Intrusion and control of eruption must be continued until the orthopedic corrections are completed. To prevent relapse, anterior open bites must be treated with the intrusion protocol rather than extrusion of anterior teeth. In growing patients, the protocol produces true forward rotation of the mandible, which redirects condylar growth, improves the profile, and helps with the correction of the Class II malocclusion (Figures 9 and 10). In addition, the protocol makes it possible to personalize the treatment by altering the force system in accordance with the morphological and biomechanical needs of the individual hyperdivergent patient (Figure 11).

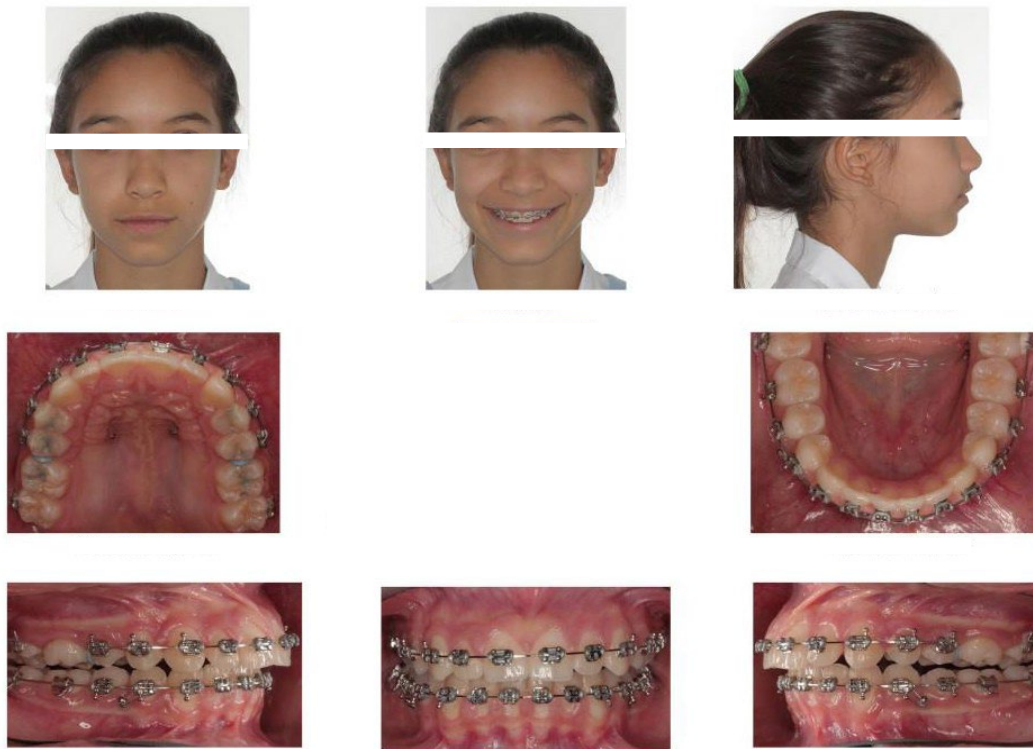


Figure 9. Class II hyperdivergent prepubertal (12.2 year-old) female patient with unfavorable growth potential after alignment, leveling, and 14 months of the Baylor intrusion protocol.

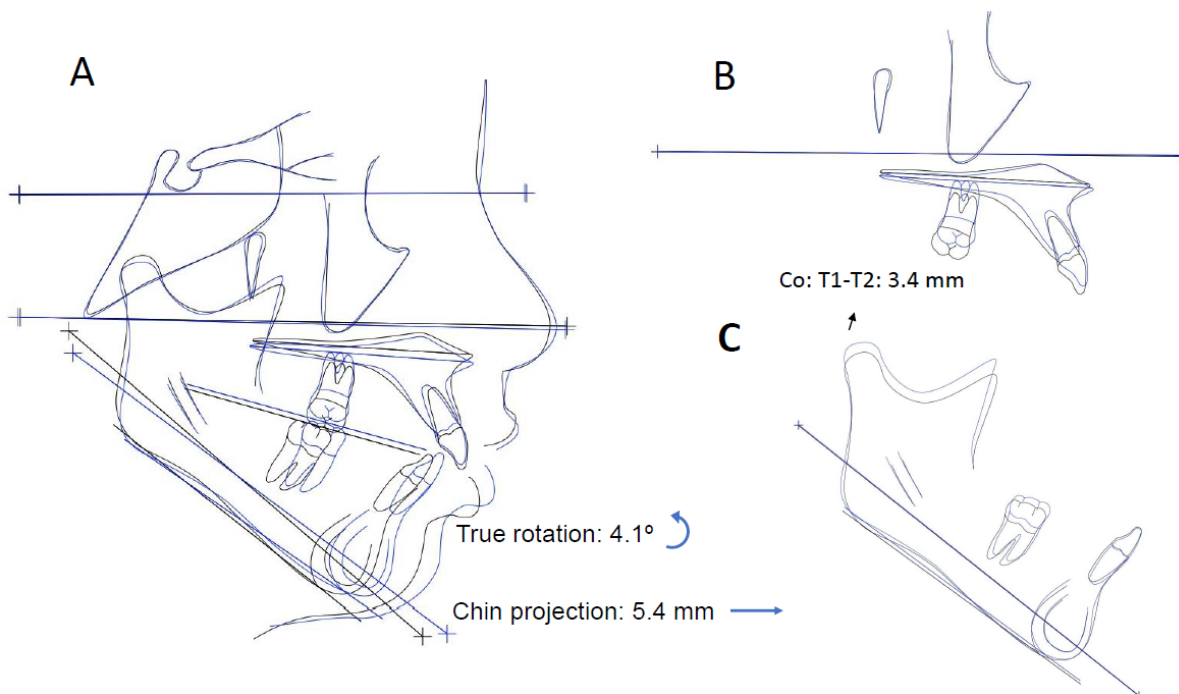


Figure 10. A) Cranial base, B) maxillary, and C) mandibular superimpositions of a Class II hyperdivergent prepubertal 12.2 year-old female patient with unfavorable growth potential (T1). Posttreatment (T2) records taken 2.3 years after alignment, leveling, and the Baylor intrusion protocol were performed.

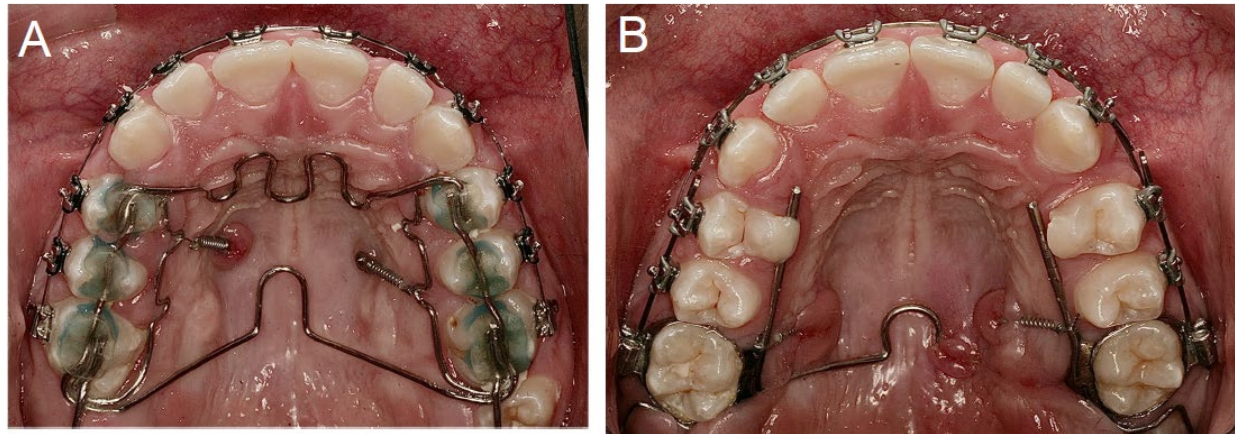


Figure 11. Variation in the application of the Baylor intrusion protocol with A) asymmetrically installed vertical springs, and B) extensions to the premolars that apply vertical and AP forces.

The Baylor intrusion protocol produces remarkable, predictable, and stable orthopedic effects [13, 14]. In a sample of consecutively treated patients, the mandibular plane angle decreased an average of 2.8°, compared to a 0.1° decrease in the controls. SNPg increased 1.9° and 0.3° for the treated and control groups, respectively. Lower anterior face height increased 1.7 mm in the treated group and 4.6 mm in the control group. There was no more apical root resorption than typically seen with other orthodontic tooth movements and the orthopedic corrections were stable 3.5 years post-treatment.

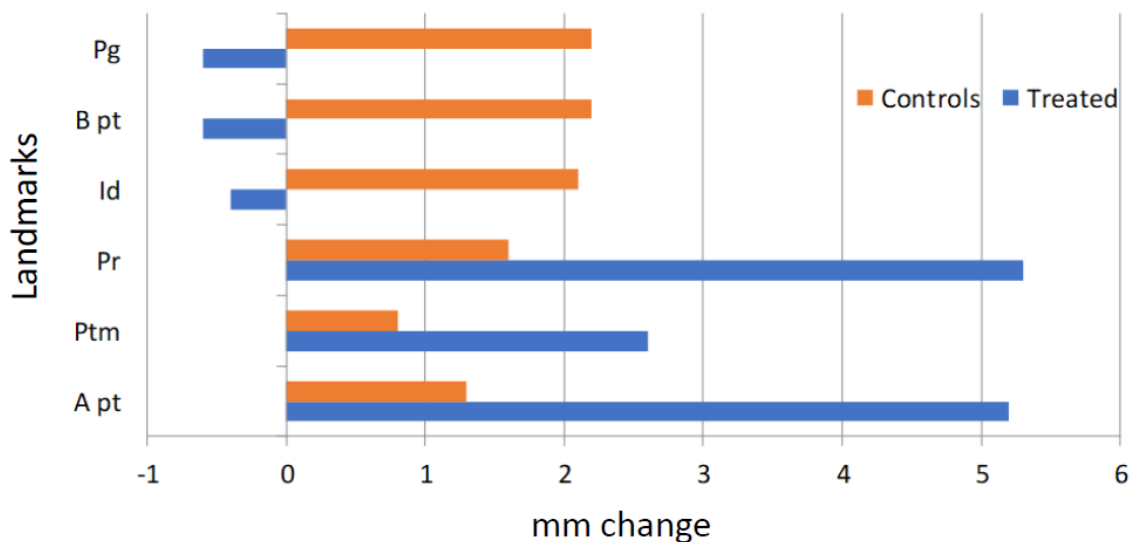


Figure 12. Horizontal changes of three maxillary and three mandibular landmarks following bone-anchored maxillary protraction (adapted from DeClerck et al 2010).

THE USE OF MSIs FOR TREATING CLASS IIIs

Most individuals with Class III malocclusion have mandibles that are protrusive and hyperdivergent, and maxillae that are slightly recessive [15]. Such individuals are best treated with downward and forward-directed forces applied to the maxilla and upward and backward-directed forces applied to the mandible. The bone-anchored maxillary protraction protocol developed by De Clerck and coworkers provides an excellent means of correcting such Class IIIs [16]. Extending elastics from bone plates placed in the zygoma

and the anterior mandible, this approach can produce, on average, a 2.5 mm anteroposterior (AP) correction of the mandible and a 3.5 mm AP correction of the maxilla (Figure 12). Importantly, the growth of ramus height and corpus length remained unaffected, but the gonial and mandibular plane angles decreased, and overall mandibular length increased only half as much as in the untreated controls (Figure 13). In other words, this approach alters the modeling pattern of the mandible and direction of condylar growth.

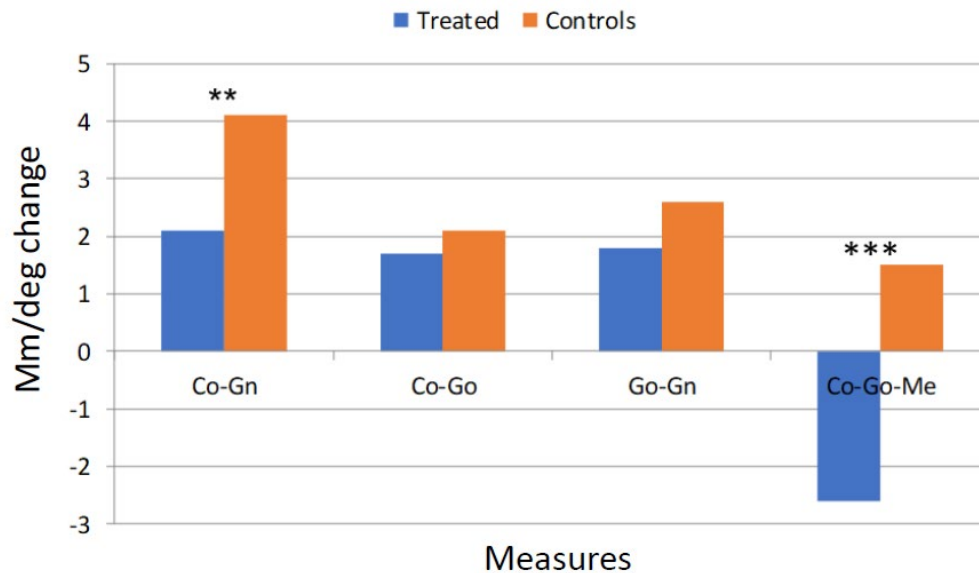


Figure 13. Changes in overall mandibular length, ramus height, corpus length, and gonial angulation produced with bone-anchored maxillary protraction (adapted from DeClerck et al 2010).

Due to the cost of the two surgeries required for inserting and removing the bone plates, as well as the cost of the bone plates, the bone-anchored maxillomandibular orthopedic (BAMO) protocol was developed by us to treat Class IIIs. The method is less invasive, it is fixed, and it is less costly. The patients are prepared for maxillary protraction using a Hyrax expander and the nine-week expansion/contraction protocol [17]. After expansion, the BAMO protocol places 8 mm MSIs bilaterally in the palate and mandible. In the maxilla, the MSIs placed in the palate behind the expander between the apices of the 5s and 6s (5 mm from the raphe), with ligatures extending vertically and horizontally to prevent extrusion and mesial tooth movements. In the mandible, spaces are first created between the first and second premolars, MSIs are placed in the spaces created, and ligatures are extended from the MSIs to the first molars to prevent distal movement of the dentition, and vertical ligatures to the first premolars to control extrusion of anterior teeth. Lower fixed appliances are placed using a .016 inch stainless steel passive wire. Saif® Springs, calibrated to 150 gm, are placed bilaterally to provide the necessary forces applied indirectly to the MSIs.

BAMO can produce remarkable orthopedic changes over relatively short time periods. MJ, for example, was treated between 11.2 and 12.9 years of age. She initially underwent the nine-week expansion/contraction protocol (Figures 14 and 15). Over the following four months, her maxilla was advanced 2 mm to 3 mm, while the AP position of her mandible was maintained, resulting in a 3 mm and 4 mm orthopedic effect (Figure 16). The maxillary and mandibular superimpositions showed that the tooth positions were maintained. Longitudinal pretreatment, start of treatment, and post-treatment superimpositions show a clear redirection of condylar growth towards a more superoanterior direction (Figure 17).

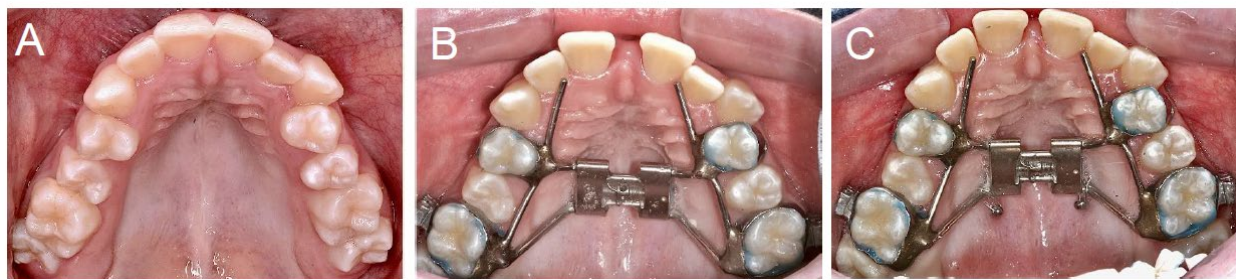

Figure 14. Maxillary arch photographs A) pretreatment, B) nine weeks after expansion contraction protocol was applied, and C) after 4 months of treatment with second generation BAMO appliances.

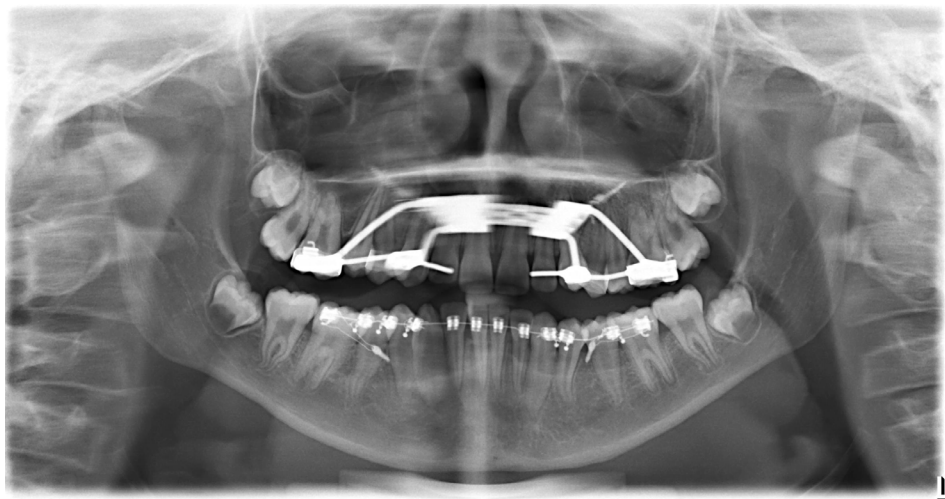


Figure 15. Panorex 9 weeks after the open-close RME protocol was performed to loosen the circummaxillary sutures. Note upper and lower 8 mm MSIs, the Hyrax, ligature wires, and lower braces.

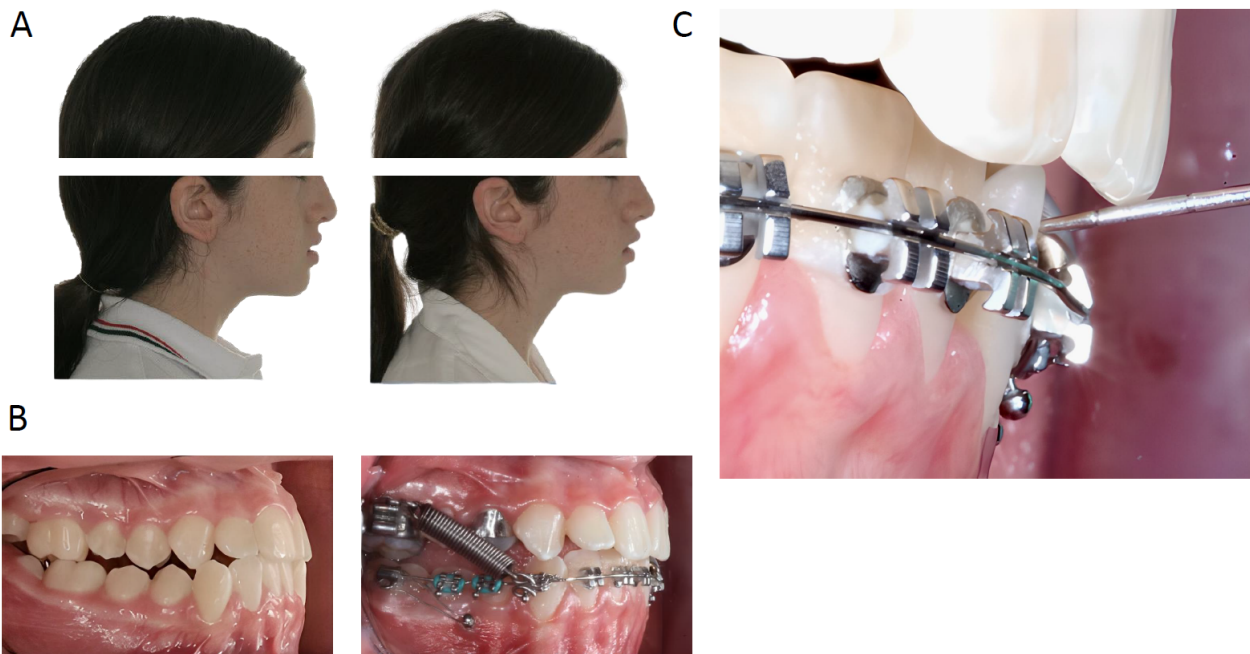


Figure 16. A) Pretreatment and post-treatment A) extraoral and B) intraoral photographs, and C) post-treatment overjet of Class III female treated with second generation BAMO appliances.

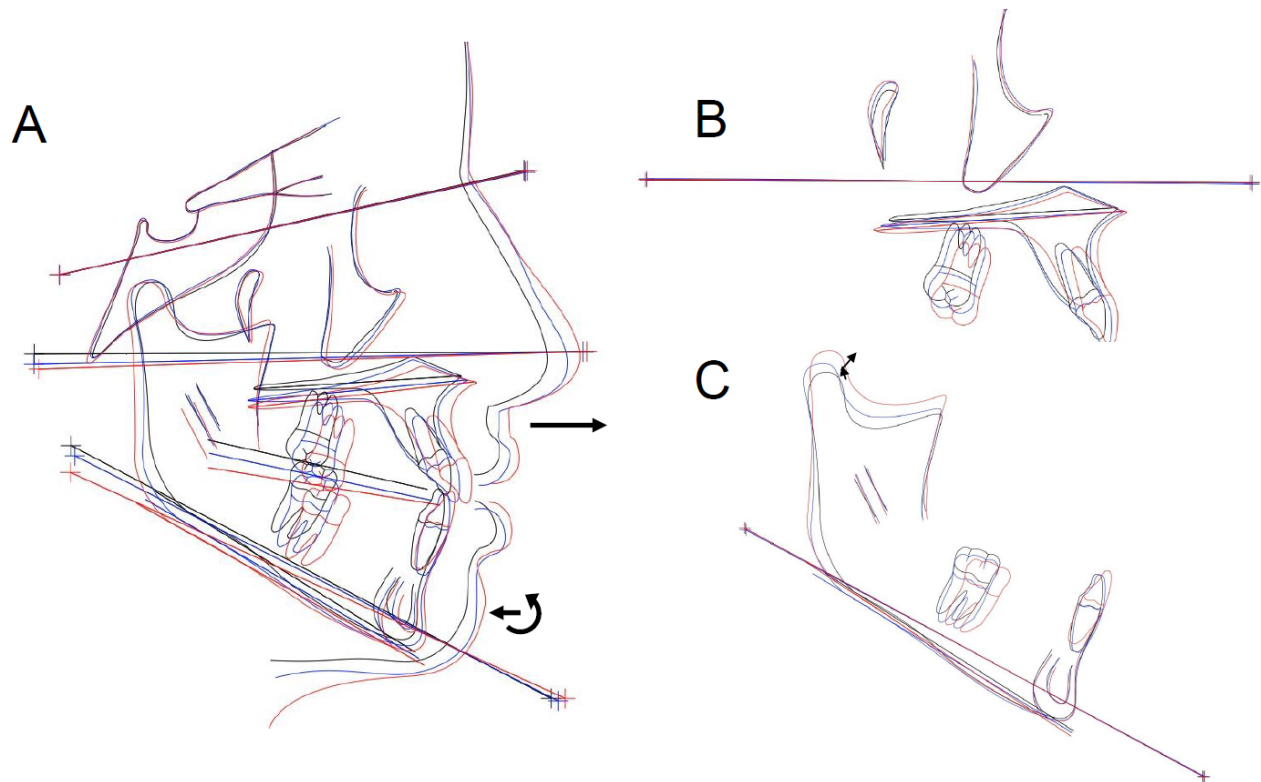


Figure 17. A) Overall, B) maxillary, and C) mandibular superimposition of MJ before treatment (T0) at 10.7 years (black), just before BAMO treatment was started (T1) at 11.2 years (blue), and after BAMO (T2) at 12.9 years (red).

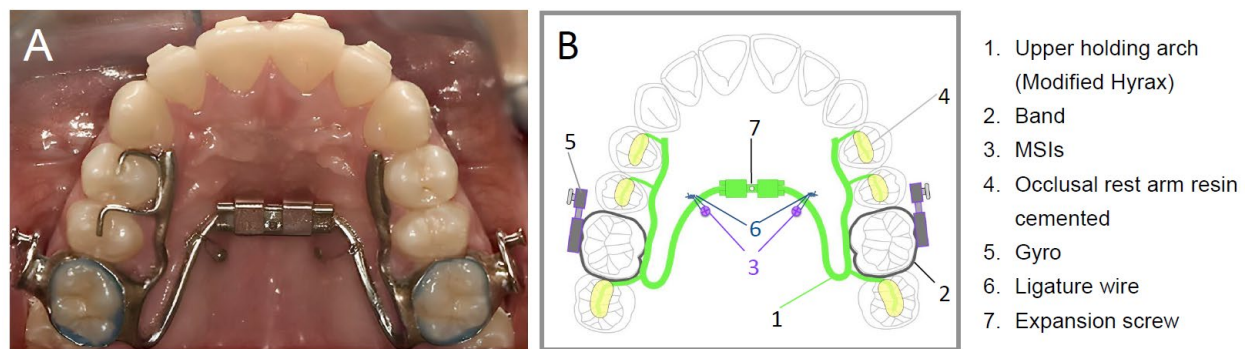


Figure 18. A) Upper arch view of fourth generation BAMO appliance system in place, along with B) diagram and description of the components.

Since 2009, when BAMO was introduced, there have been several improvements (new materials and an improved biomechanical setup) to better control AP orthopedic corrections. The newest generation of BAMO includes four components. The first component is a holding arch system, which consists of a Hyrax expander soldered to the maxillary first molars (Figure 18), and a mandibular lingual arch with occlusal rest arms bonded onto the premolars and second molars (Figure 19). The second component addresses bony anchorage. In the maxilla, 8 mm long MSIs are placed in the palate 5 mm lateral to the rugae between the first molars and second premolars (Figure 18). In the mandible, 8 mm long MSIs are placed between the first and second premolars (Figure 20). The third component pertains to the ligatures, which extend from the MSIs to the closest aspect of lateral bar of the Hyrax in the upper

arch, or to the premolar brackets when placed buccally. In the mandible, the ligatures extend to the premolar brackets (Figures 19 and 20). This creates an indirect bone anchored system when the forces are applied. The forces should be limited to approximately 50 grams (n.b. the ligature should ping when stroked with an explorer) when tightening the ligature ties. For the fourth component, a specially designed polymer, Gralaria® (Figure 20), was developed to provide the orthopedic forces (approximately 150 grams) and connect the variable moment control device (Gyro) to the lower brackets (Figure 20). The description of force vector direction selection is beyond the scope of this paper. After the four components of the BAMO system are in place, the expansion/protraction protocol is started and the intermaxillary force system is initiated, producing the AP and vertical growth control of the maxilla and the mandible via indirect anchorage. The BAMO protocol should be continued until the clinical objectives have been attained (e.g., Class I molar and canine relations, normal overjet, and orthopedic corrections).

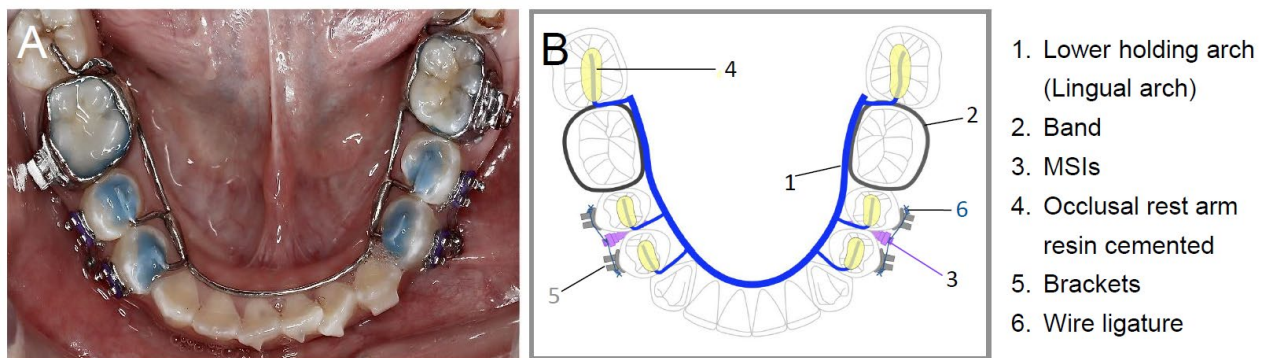


Figure 19. A) Lower arch view of fourth generation BAMO appliance system in place, along with B) diagram and description of the components.

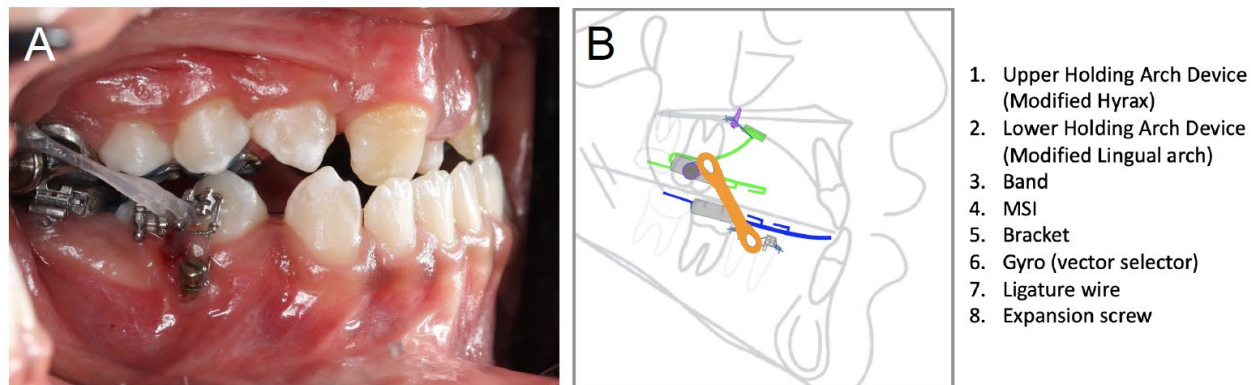


Figure 20. A) Lateral occlusion view of BAMO appliance system in place, and B) diagram of BAMO components.

THE NEED FOR EARLY TREATMENT

Ideally, Class IIIs and hyperdivergent Class IIs should be treated as early as possible. Both problems can be identified early, and the skeletal problems usually worsen over time. Their skeletal and dental malocclusions produce functional deficits and esthetic problems that can seriously impact the quality of the subjects' lives. Various authors have shown that Class III malocclusion starts as early as the deciduous dentition [18, 19]. The molar relations, the Wits relationship, and the maxillomandibular differential of Class IIIs have all been shown to worsen with age. Similarly, it has been well established that the hyperdivergent Class II phenotype starts to develop early, often before the eruption of the first permanent molars, and it also usually worsens over time. Importantly, there is greater potential for orthopedic changes at younger ages. Because they are less complex, the mid-palatal and other maxillary sutures respond much more favorably to treatments in younger than older patients [20, 21]. There is also greater potential for mandibular growth changes. Greater AP orthopedic changes have been reported in both jaws when treating during the deciduous than mixed dentitions [22]. There is greater potential for a favorable growth response to mechanical loading among younger individuals [23] because mechanosensitivity of human bone declines with age [24, 25]. Because the malocclusion has not fully developed and younger patients have greater growth potential, the amount of correction needed is lessened and there is greater potential for orthopedic shape changes.

SHORTER MSIs MAKE EARLY ORTHOPEDIC TREATMENTS POSSIBLE

While longer MSIs can be placed in the palates of younger patients, they are problematic when placed in the mandible. MSIs placed into teeth can cause serious damage [26, 27]. While normal healing can be expected approximately 64.3% of the time, lack of normal PDL development (10.7%), bony degeneration (8.9%), ankylosis (3.5%), and pulp damage (12.5%) have all been shown to occur when MSIs are placed into the PDL and teeth. There is also a real potential for the teeth of younger children moving into longer miniscrews. To prevent damage prior to the permanent dentition and increase the number of potential insertion sites, shorter 3 mm long MSIs must be used to achieve skeletal anchorage.

There are three reasons why 3 mm MSIs are ideally suited for deciduous and mixed dentitions. First, there is little or no risk of damaging the teeth because the gingival tissues are 1.0 mm to 1.5 mm thick [28, 29] and the buccal cortex is 1 mm to 2 mm thick [30, 31]. When using radiographs for verification and judicious placement protocols, there should be little or no risk of a 3 mm long MSI contacting any tooth between the premolars and second molars. Second, 3 mm MSIs have been shown to be relatively stable clinically [32], with failure rates like those reported for longer MSIs [33, 34]. Experimental studies using 3 mm long MSIs have shown even lower failure rates [35-37]. While most in vitro studies suggest greater stability for longer than shorter MSIs [38-40], clinical studies often show only small statistically insignificant differences [41].

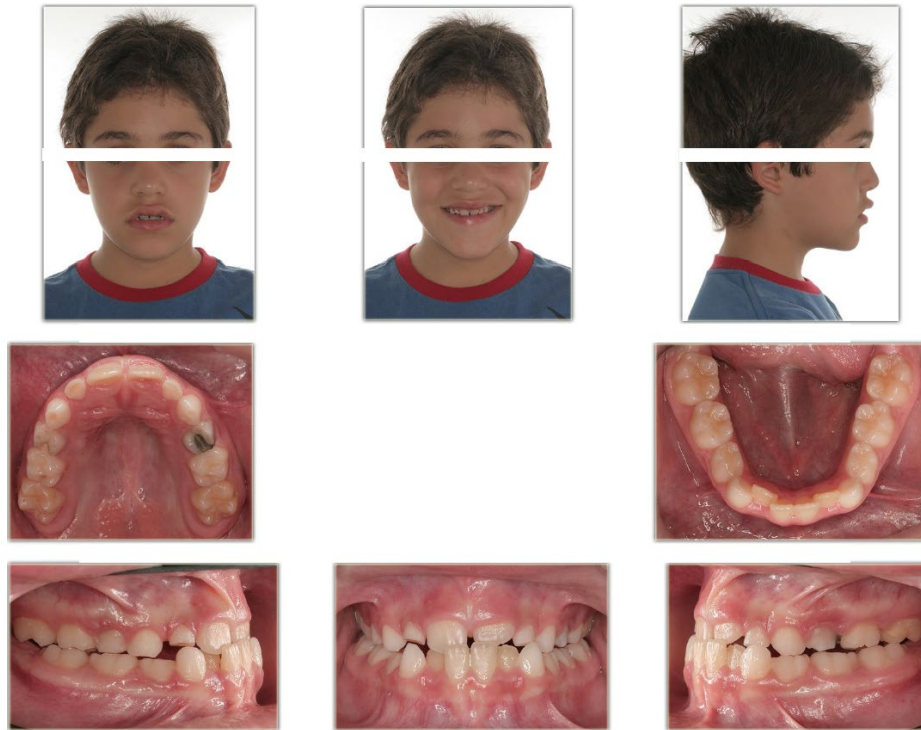


Figure 21. Pretreatment photographs of a 7.9 year-old Class III male patient treated early with first generation BAMO appliances.

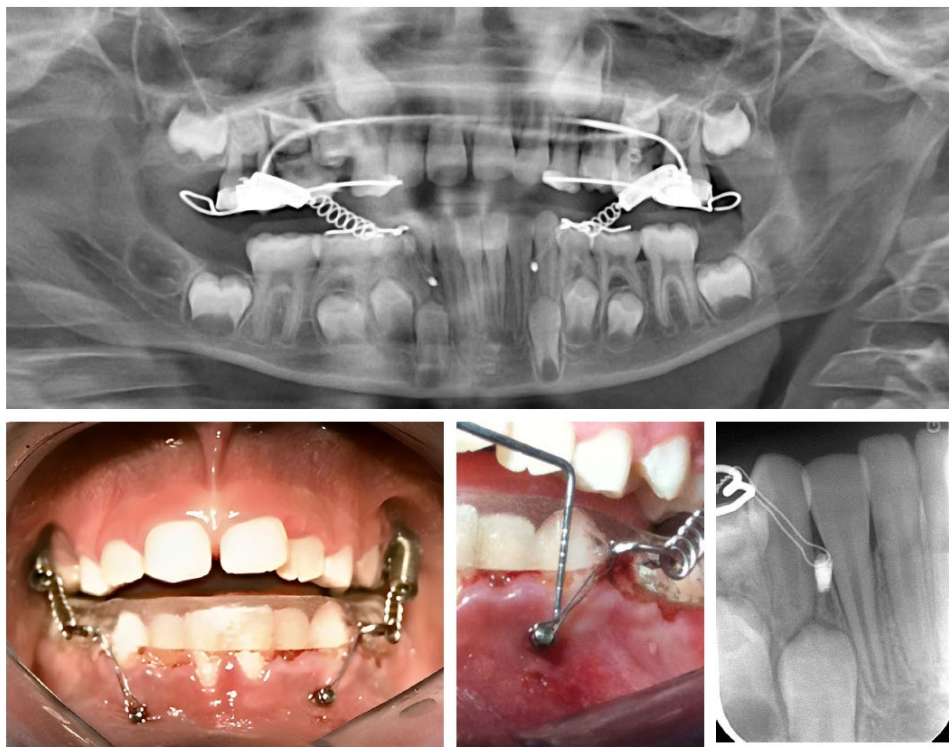


Figure 22. Panorex and intraoral images showing MSIs, transpalatal bar used for maxillary anchorage, and the full-coverage splint used for mandibular anchorage, with ligature wires extending from the maxillary MSIs to the lateral wires of the transpalatal bar and hooks in the mandibular splint.

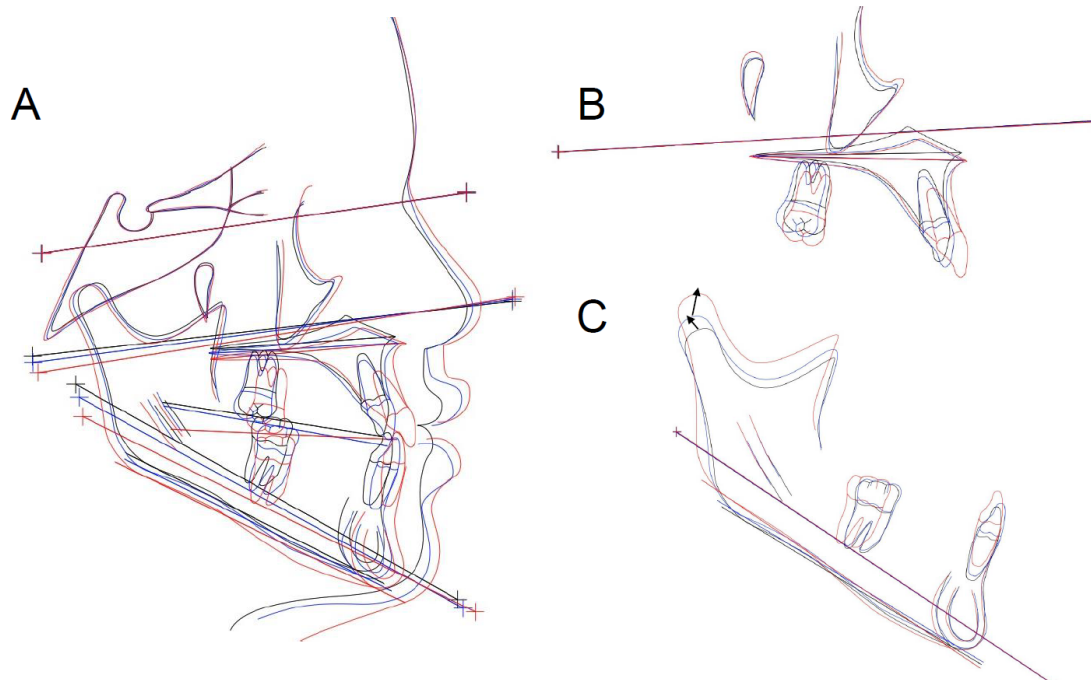


Figure 23. A) Overall, B) maxillary, and C) mandibular superimpositions of a young hyperdivergent Class III male patient treated with first generation BAMO appliances, along with 3 mm mandibular MSIs and 8 mm maxillary MSIs. Records were taken prior to treatment (7.1 years), immediately before the start of BAMO treatment (7.9 years), and after treatment (9.3 years).

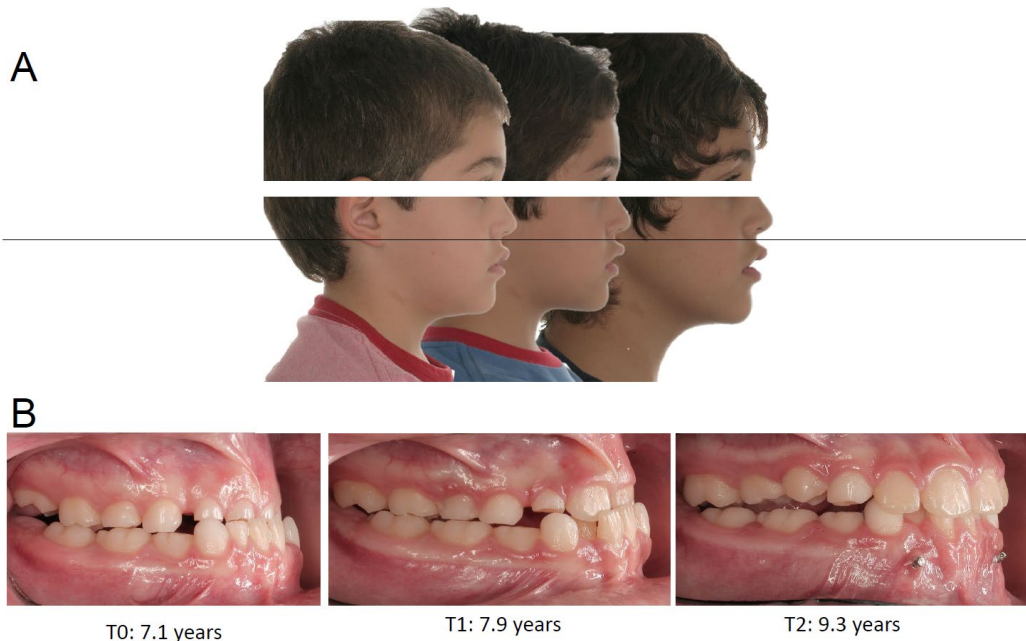


Figure 24. Lateral A) extraoral and B) intraoral photographs taken prior to treatment (T0), at the start of BAMO treatment (T1), and after BAMO treatment(T2).

Finally, shorter 3 mm MSIs should be considered because they have been successfully and repeatedly used clinically [42]. For example, TL was treated at 7.9 years of age with 8 mm long Dentos palatal MSIs and 3 mm long mandibular MSIs (Figure 21). He had a transpalatal bar with extensions cemented to the canines lingually and a mandibular acrylic plate with hooks cemented with Ultra Band-Lok® (Figure 22). Ligatures were tied from the MSIs to the upper canines and the plate hooks. After 13 months, the maxilla

had been protracted 3 mm to 4 mm and the AP position of the mandible was maintained (Figures 22 to 24). Mandibular superimpositions showed a remarkable redirection of condylar growth in a more anterosuperior direction (Figure 23).

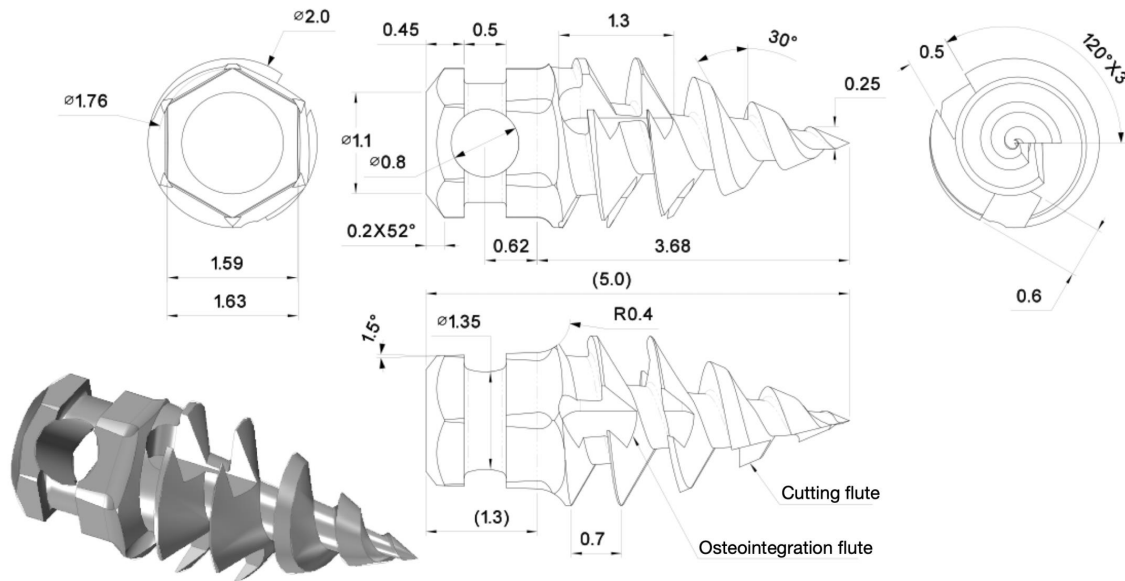


Figure 25. Recently developed 3 mm MSI that had its surface area increased by adding three longitudinal flutes down its entire shaft, having SLA surface treatment, and increasing its outer diameter. (Patents Pending)

The stability of 3 mm long MSI can be further enhanced by increasing their surface area and minimizing movements during insertion. Experimental evidence shows significantly greater amounts of bone around sandblasted, large-grit, and acid-etched MSIs than machined MSIs [43]. It has also been shown that longitudinal flutes running down the entire shaft of 3 mm MSIs increase removal torque after 6 weeks by 37% [44]. Depending on cortical thickness and density, removal torque can be increased 15% to 27% by increasing the outer diameter of 3 mm MSIs by as little as 0.25 mm [45]. We have developed a new 3 mm MSI that incorporates all these features, which should provide even greater MSI stability in the future (Figure 25). Future testing will be needed to fully understand the effects of increasing surface area.

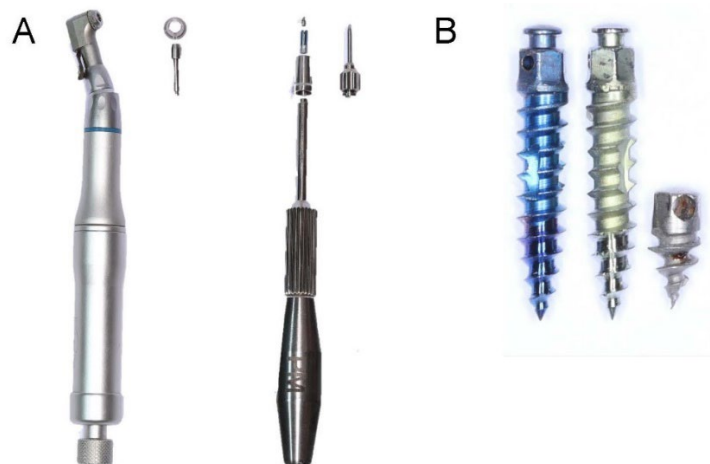


Figure 26. A) Dentos contra-angle and screwdriver, along with the instruments developed to minimizing wobbling when inserting the MSIs, and B) recently developed 8 mm and 3 mm MSIs. (Patents Pending)

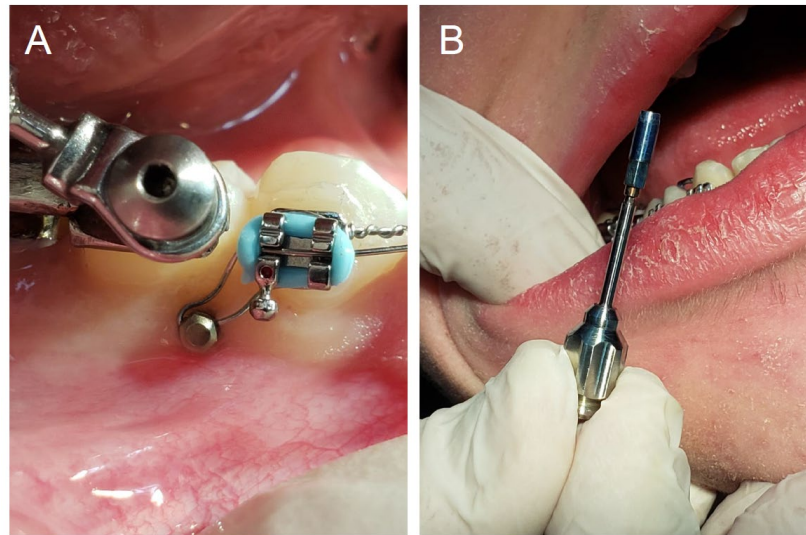


Figure 27. A) 3 mm MSI with the ligature wire in place prior to insertion, and B) miniscrew driver designed to facilitate MSIs removal.

Operator-related factors that reduce wobble during insertion might also be expected to further enhance the stability of 3 mm MSIs. Post-insertion movements of the MSIs can be minimized by attaching the ligature or elastic thread to the MSI prior to insertion. Movements can be further reduced by using a smaller driver with a built-in system that automatically decouples from the MSI after insertion. Such auxiliary tools have recently been developed to make the insertion of the new 3 mm MSIs easier and more effective (Figure 26 and 27).

CONCLUSIONS

In the future, orthopedic corrections of skeletal problems will become an increasingly important component of the orthodontist's repertoire. The biological and clinical basis for performing orthopedics is well established. Skeletal anchorage has made such corrections possible for older children and adolescents. MSIs have made orthopedic treatments simpler and less costly. The treatments are more effective and efficient than traditional approaches; they produce more predictable results and require only limited patient cooperation. Since most skeletal malocclusions develop early and worsen over time, new skeletal anchorage devices are needed for treating children in the primary and early mixed dentition stages of development. Recently developed and redesigned 3 mm long MSIs enhance the orthodontist's ability to treat early. Three mm long MSIs will also open new possibilities for more effective and efficient treatments of older patients.

REFERENCES

1. Schumacher GH, Bokládál M. On the different secondary changes in the skull following resection of the masticatory muscles. *Acta Anat (Basel)* 1968; 69(3):378-392.
2. Björk A, Skieller V. Facial development and tooth eruption: an implant study at the age of puberty. *Am J Orthod* 1972; 62(4): 339-383.
3. Buschang PH, Gandini LG Jr. Mandibular skeletal growth and modeling between 10- and 15 years of age. *Eur J Orthod* 2002; 24(1):69-79.

4. McNamara JA Jr, Carlson DS. Quantitative analysis of temporomandibular joint adaptations to protrusive function. *Am J Orthod* 1979; 76(6):593-611.
5. Araujo AM, Buschang PH, Melo AC. Adaptive condylar growth and mandibular remodeling changes with bionator therapy – an implant study. *Eur J Orthod* 2004; 26(5):515-522.
6. Mojdehi M, Buschang PH, English JD, Wolford LM. Postsurgical mandibular growth changes of adolescents with vertical maxillary excess growth patterns. *Am J Orthod Dentofacial Orthop* 2001; 119(2): 106-116.
7. Ventura V, Botelho J, Machado V, Mascarenhas P, Pereira FD, Mendes JJ, Delgado AS, Pereira PM. Miniscrew-assisted rapid palatal expansion (MARPE): An umbrella review. *J Clin Med* 2022; 11(5):1287.
8. Abu Arqub SA, Gandhi V, Iverson MG, Alam MK, Allareddy V, Liu D, Yadav S, Mehta S. Radiographic and histological assessment of root resorption associated with conventional and mini-screw assisted rapid palatal expansion: a systematic review. *Eur J Orthod* 2022; 44(6):679-689.
9. Celenk-Koca T, Erdinc AE, Hazar S, Harris L, English JD, Akyalcin S. Evaluation of miniscrew-supported rapid maxillary expansion in adolescents: A prospective randomized clinical trial. *Angle Orthod* 2018; 88(6):702-709.
10. Almaqrami BS, Ngan P, Alhammadi MS, Al-Somairi MAA, Xiong H, Hong H. Three-dimensional craniofacial changes with maxillary expansion in young adult patients with different craniofacial morphology. *APOS Trends Orthod* 2022 (In press).
11. Buschang PH. The development, phenotypic characteristics, and etiology of Class II malocclusion. In: Araujo EA and Buschang PH, eds. *Recognizing and Correcting Developing Malocclusions – A Problem-Oriented Approach to Orthodontics*. Hoboken, New Jersey: Wiley; 2015: pp 90-107.
12. Carrillo R, Buschang PH. Palatal and mandibular miniscrew implant placement techniques. *J Clin Orthod* 2013; 47(12):737-743.
13. Buschang PH, Carrillo R, Rossouw PE. Orthopedic correction of growing hyperdivergent, retrognathic patients with miniscrew implants. *J Oral Maxillofac Surg* 2011; 69(3):754-762.
14. Rice AJ, Carrillo R, Campbell PM, Taylor RW, Buschang PH. Do orthopedic corrections of growing retrognathic hyperdivergent patients produce stable results? *Angle Orthod* 2019; 89(4):552-558.
15. Buschang PH. The development, phenotypic characteristics, and etiology of Class III malocclusion. In: Araujo EA and Buschang PH, eds. *Recognizing and Correcting Developing Malocclusions – A Problem-Oriented Approach to Orthodontics*. Hoboken, New Jersey: Wiley; 2015: pp 137-151.
16. De Clerck H, Cevidanes L, Baccetti T. Dentofacial effects of bone-anchored maxillary protraction: A controlled study of consecutively treated Class III patients. *Am J Orthod Dentofacial Orthop* 2010; 138(5):577-581.
17. Liou EJ, Tsai WC. A new protocol for maxillary protraction in cleft patients: repetitive weekly protocol of alternate rapid maxillary expansions and constrictions. *Cleft Palate Craniofac J*. 2005; 42(2):121–127.
18. Guyer EC, Ellis EE 3rd, McNamara JA, Behrents RG. Components of Class III malocclusion in juveniles and adolescents. *Angle Orthod* 1986; 56(1):7-30.
19. Krneta B, Primozic J, Zhurov A, Richmond S, Ovsenik M. Three-dimensional evaluation of facial morphology in children aged 5-6 years with a Class III malocclusion. *Eur J Orthod*. 2014; 36(2):133-139.
20. Krebs A. Midpalatal suture expansion studies by the implant method over a seven-year period. *Rep Congr Eur Orthod Soc* 1964; 40:131-142.
21. Kim JH, Viana MA, Graber TM, Omerza FF, BeGole EA. The effectiveness of protraction face mask therapy: a meta-analysis. *Am J Orthod Dentofacial Orthop* 1999; 115(6):675-685.

22. Kajiyama K, Murakami T, Suzuki A. Comparison of orthodontic and orthopedic effects of a modified maxillary protractor between deciduous and early mixed dentitions. *Am J Orthod Dentofacial Orthop* 2004; 126(1):23-32.
23. Hemmatian H, Bakker AD, Klein-Nulend J, van Lenthe GH. Aging, osteocytes, and mechanotransduction. *Curr Osteoporos Rep* 2017; 15(5):401-411.
24. Umemura Y, Ishiko T, Yamauchi T, Kurono M, Mashiko S. Five jumps per day increase bone mass and breaking force in rats. *J Bone Miner Res* 1997; 12(9):1480-1485.
25. Lieberman DE, Pearson OM, Polk JD, Demes B, Crompton AW. Optimization of bone growth and remodeling in response to loading in tapered mammalian limbs. *J Exp Biol* 2003; 206(Pt18): 3125-3138.
26. Brisceno CE, Rossouw PE, Carrillo R, Spears R, Buschang PH. Healing of the roots and surrounding structures after intentional damage with miniscrew implants. *Am J Orthod Dentofacial Orthop* 2009; 135(3):292-301.
27. Hembree M, Buschang PH, Carrillo R, Spears R, Rossouw PE. Effects of intentional damage of the roots and surrounding structures with miniscrew Implants. *Am J Orthod Dentofacial Orthop* 2009; 135(3):280.e1-281.
28. Goaslind GD, Robertson PB, Mahan CJ, Morrison WW, Olson JV. Thickness of facial gingiva. *J Periodontol* 1977; 48(12):768-771.
29. Eger T, Müller HP, Heinecke A. Ultrasonic determination of gingival thickness. Subject variation and influence of tooth type and clinical features. *J Clin Periodontol*. 1996; 23(9):839-845.
30. Farnsworth D, Rossouw PE, Ceen RF, Buschang PH. Cortical bone thickness at common mini-screw implant placement sites. *Am J Orthod Dentofacial Orthop* 2011; 139(4):495-503.
31. Horner KA, Behrents RG, Kim KB, Buschang PH. Cortical bone and ridge thickness of hyperdivergent and hypodivergent adults. *Am J Orthod Dentofacial Orthop* 2012; 142(2):170-178.
32. Geshay D, Campbell P, Tadlock L, Schneiderman E, Kyung HM, Buschang P. Stability of immediately loaded 3 mm long miniscrew implants: a feasibility study. *Dental Press J Orthod* 2021; 26(1):e2119155.
33. Papageorgiou SN, Zogakis IP, Papadopoulos MA. Failure rates and associated risk factors of orthodontic miniscrew implants: a meta-analysis. *Am J Orthod Dentofacial Orthop* 2012; 142(5):577-595.e7.
34. Crismani AG, Bertl MH, Celar AG, Bantleon HP, Burstone CJ. Miniscrews in orthodontic treatment: review and analysis of published clinical trials. *Am J Orthod Dentofacial Orthop* 2010; 137(1):108-113.
35. Liu SS, Opperman LA, Buschang PH. Effects of recombinant human bone morphogenetic protein-2 on midsagittal sutural bone formation during expansion. *Am J Orthod Dentofacial Orthop* 2009; 136(6):768.e1-e8, discussion 768-769.
36. Liu SS, Kyung HM, Buschang PH. Continuous forces are more effective than intermittent forces in expanding sutures? *Eur J Orthod* 2010; 32(4):371-380.
37. Liu, SS, Opperman LA, Kyung HM, Buschang PH. Is there an optimal force level for sutural expansion? *Am J Orthod Dentofacial Orthop* 2011; 139(4):446-455.
38. Chen CH, Chang CS, Hsieh CH, Tseng YC, Shen YS, Huang IY, Yang CF, Chen CM. The use of microimplants in orthodontic anchorage. *J Oral Maxillofac Surg* 2006; 64(8):1209-1213.
39. Pithon MM, Figueiredo DS, Oliverra DD. Mechanical evaluation of orthodontic mini-implants of different lengths. *J Oral Maxillofac Surg* 2013; 71(3):479-486.
40. Sarul M, Lis J, Park HS, Rumin K. Evidence-based selection of orthodontic miniscrews, increasing their success rates in the mandibular buccal shelf. A randomized prospective clinical trial. *BMC Oral Health* 2022; 22(1):414.

41. Kuroda S, Yamada K, Deguchi T, Hashimoto T, Kyung HM, Takano-Yamamoto T. Root proximity is a major factor for screw failure in orthodontic anchorage. *Am J Orthod Dentofacial Orthop* 2007; 131(4 Suppl): S68-S73.
42. Roldán SI, Martinez Smit RM, Isaza JF, Isaza C, Buschang PH. Novo sistema para tratamento de Classe III esquelética: Ortopedia Maxilomandibular com Ancoragem Óssea (BAMO) em mini-implantes de 3 mm. *Rev Clin Ortod Dental Press* 2015; 14(3);96-109.
43. Ikeda H, Rossouw PE, Campbell PM, Kontogiorgos E, Buschang PH. Three-dimensional analysis of peri-bone-implant contact of rough surface mini-screw implants. *Am J Orthod Dentofacial Orthop* 2011; 139(2):e153-163.
44. Truong PA, Campbell PM, Kontogiorgos ED, Taylor RW, Kyung HM, Buschang PH. Effect of longitudinal flutes on miniscrew implant stability and 3-dimensional bone formation. *Am J Orthod Dentofacial Orthop* 2016; 150(6):950-957.
45. Shah AH, Behrents RG, Kim KB, Kyung HM, Buschang PH. Effect of screw and host factors on insertion torque and pullout strength. *Angle Orthod* 2012; 82(4):603-610.

MANAGEMENT OF ANTERIOR OPEN BITE WITH CLEAR ALIGNERS IN ADULTS

Bella Shen Garnett & Heeyeon Suh

ABSTRACT

Clear aligners are an effective treatment option to control vertical dimension and correct mild to moderate anterior open bites. It is important to understand that a computer program alone cannot replace the need for a thoughtful diagnosis of the skeletal and dental patterns, as well as careful consideration of the interaction between the sagittal and vertical dimensions. It is essential to recognize that the treatment plan for skeletal and dental open bites should differ, and that the treatment mechanism for a Class III open bite is different from that of a Class I or Class II open bite. Comprehensive diagnosis and treatment planning are crucial to ensure treatment success.

KEY WORDS: Clear aligners, Anterior open bite, Adults, Vertical dimension, Sagittal jaw discrepancy

INTRODUCTION

Anterior open bite is defined as the lack of contact between the incisal edges of the maxillary and mandibular anterior teeth [1]. It is a difficult condition to treat because it can be caused by skeletal, dental, functional, and habitual factors [2-4]. Anterior open bites can be classified as either skeletal or dental. Skeletal open bite is characterized by increased mandibular plane angle and increased lower facial height. In contrast, dental open bite is characterized by proclined incisors, under-erupted anterior teeth, normal or slightly excessive molar height, and thumb or finger sucking habits [5].

In adults, treatment options to correct anterior open bites are limited [1, 6-8]. Orthognathic surgery is the most effective option for severe skeletal open bites. Non-surgical fixed appliance therapy with vertical elastics and sometimes extractions can be an alternative for less severe cases. Skeletal temporary anchorage devices (TADs) have made it possible to correct a broader range of anterior open bite cases with orthodontic treatment alone [9, 10].

Clear aligners have gained popularity as an alternative treatment option for open bites in adult orthodontic patients who prefer to avoid more invasive treatment options such as surgery or TADs [11-13]. Previous studies have shown that they are effective at treating open bites due to better vertical dimension control [11-16]. Some of the previous studies reported both intrusion of molars and extrusion of incisors [12, 16, 17], while others have reported mainly correcting open bites by extruding incisors [18]. In this chapter, we will focus on how clear aligners can be used to correct anterior open bites in adult patients.

REVIEW OF LITERATURE

Etiology

The prevalence of anterior open bite ranges from 1.5% to 11% and varies across ethnic groups and ages [19]. As children develop, the incidence of anterior open bite decreases, as it tends to self-correct during the mixed dentition phase. From 8 to 17 years of age, a prevalence of approximately 3.5% was reported [20]. While genetics play a role in open bite, environmental factors such as tongue thrust, thumb and finger sucking, and macroglossia can also contribute to development of open bite [21, 22]. The clinician should carefully evaluate the function and anatomy of the tongue in causing an open bite [22]. Mouth breathing, skeletofacial and dentoalveolar trauma, muscle weakness, and degenerative diseases involving the condyles can also contribute to the development of anterior open bite [22-24].

Diagnosis

Anterior open bite can be the result of a dental discrepancy, skeletal discrepancy, or a combination of the two. Dental open bite occurs when the patient has a normal craniofacial pattern, but with maxillary incisor proclination, undererupted anterior teeth, or reduced dentoalveolar height within the area of the cuspids and incisors [22]. This type of open bite can be caused by thumb or digit habit and improper tongue posture. On the other hand, skeletal open bite is characterized by steeper mandibular plane, larger gonial angle, increased lower anterior facial height, decreased posterior facial height, smaller ramus height, flatter palatal plane angle, narrow maxilla, and excessive dentoalveolar height [22, 25, 26]. Sassouni described skeletal classification of basic facial types by vertical disproportions (skeletal deep bite/open bite) and anteroposterior disproportions (skeletal Class II/Class III) [27]. Skeletal Class II open bites are mainly caused by a backward downward rotated mandible. This can be improved by rotating the mandible in a closing direction [27]. On the other hand, skeletal Class III open bite cases are more challenging to treat and may require surgery [27].

Treatment

Identifying and addressing etiology

To effectively treat and prevent relapse of an anterior open bite, it is important to address the underlying causes, which can be multifactorial and include skeletal, dental, muscular malfunctions, and habits. Previous studies have suggested that a series of simple exercises can be taught to the patient with a tongue thrust, which can help address muscle habits and promote long-term orthodontic stability of the correction of an open bite malocclusion [28]. These include positioning the tip of the tongue in the click position and pushing it upwards, which should be done in sets of 10, three times a day [28]. Another exercise, known as the "3-S's", includes slurp, squeeze, and swallow: the patient collects saliva (slurp), brings the teeth together and activates muscles of closure (squeeze), and swallows with the tongue in the click position (swallow) [28].

When dealing with degenerative diseases involving the condyles, it is essential to make a correct diagnosis and determine whether the condylar resorption is active or inactive before planning orthodontic treatment, as active condylar resorption can undo the treatment [29]. The point at which the resorption stops varies on a case-by-case basis, and there are currently no ways to predict it. Serial imaging, including cone beam computed tomography (CBCT), Technetium 99m-methyl diphosphonate (^{99m}Tc-MDP), and

magnetic resonance imaging (MRI), can be used to determine whether idiopathic condylar resorption is active or inactive [29].

Vertical control

Treatment with a fixed appliance can extrude posterior teeth and increase vertical dimension. A retrospective study of 60 cases, with pretreatment age ranging from 10 to 32 years (mean age 13 years), reported that when treated with fixed appliances, there was at least a 1.5° increase Y-axis to SN and the mean was 2.43° [30]. Many appliances have been used for vertical control: posterior bite block [31], low hanging TPA, MEAW (multiloop edgewise archwire technique) [32,33], high pull headgear, vertical chin cup [34], lower lingual holding arch [35], posterior magnets [36], surgical plates [9], and TADs.

Clear aligners have become a popular treatment option for adult open bite patients. Boyd, in 2008, observed that posterior open bites developed at the end of Invisalign treatment due to posterior coverage and thickness of plastic, which could be helpful for vertical control especially for adult anterior open bite patients [37]. Over the past few years, with advances through a series of ClinCheck algorithms (G series), technology has expanded the scope of clear aligner therapy from the treatment of simple malocclusions to more complex ones that include anterior open bites [13]. In 2011, Invisalign introduced G4, which incorporated posterior intrusion into its ClinCheck software algorithms. Previous studies have shown that they are effective at treating open bites due to better vertical dimension control [11-16]. Previous studies reported intrusion of molars as well as extrusion of incisors in treatment of anterior open bites with clear aligners [12, 16, 17].

ANTERIOR OPEN BITE TREATMENT WITH CLEAR ALIGNERS

Correction of anterior open bite can be accomplished through incisor extrusion, molar intrusion, or a combination of both. A thorough evaluation of the skeletal and dental patterns is essential for successful correction of the anterior open bite. It is crucial for clinicians not to rely solely on software or technicians to determine how to close the open bite, as this may result in treatment plans that only involve extrusion of anterior teeth in skeletal open bite patients.

In hyperdivergent anterior open bite cases, the incisors are often already naturally extruded as a compensatory mechanism. Excessive extrusion of anterior teeth to camouflage the existing skeletal deformity should be avoided, as it can produce an unnatural appearance and unstable result [38-40]. To determine the treatment plan, factors such as vertical pattern, anterior facial height, incisal display, and lip competency should be considered.

Vertical correction

Clear aligners correct anterior open bite through a combination of anterior extrusion and posterior intrusion. Anterior extrusion can be achieved through absolute or relative extrusion, with the latter involving retroclination of incisors. When anterior teeth are extruded, the posterior teeth experience a reaction force that results in posterior teeth intrusion, which is beneficial for correcting anterior open bite.⁴¹ To close anterior open bite, optimized extrusion attachments are utilized to extrude anterior teeth as a unit using the posterior teeth as anchorage (Figure 1).

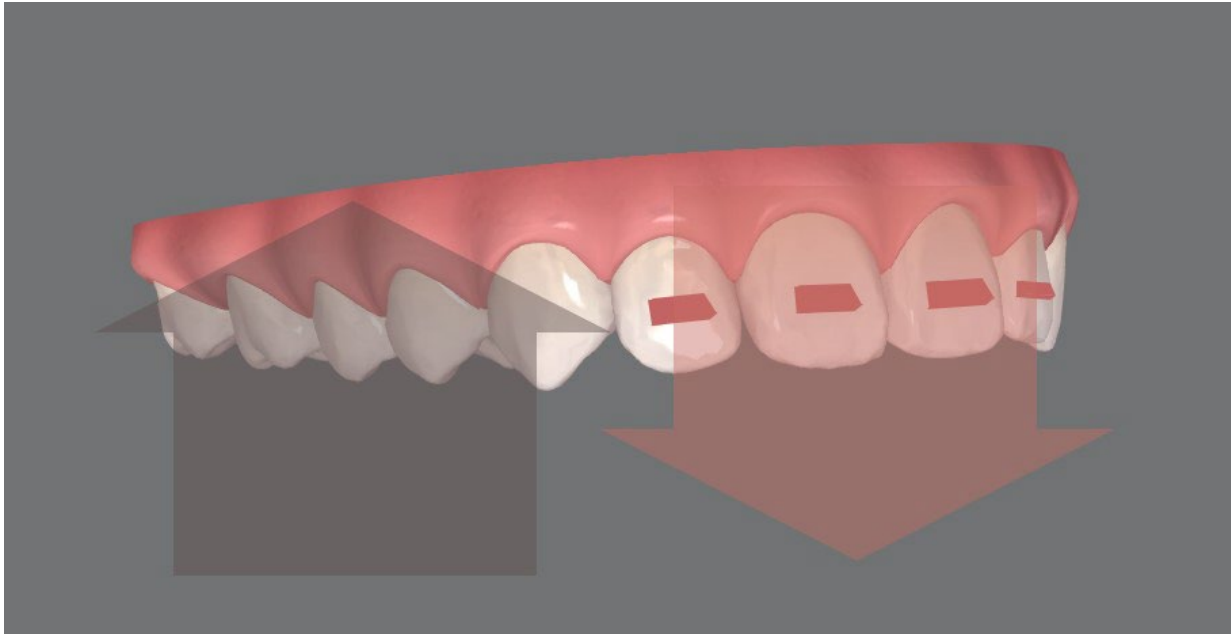


Figure 1. Multi-tooth anterior extrusion leveraging the posterior teeth as anchorage for anterior open bite correction in the Invisalign G4 protocol.

Good vertical control, and even intrusion of molars, can decrease the need for excessive anterior extrusion to correct anterior open bite with clear aligners. Although up to 2 mm of maxillary molar intrusion was possible with clear aligners, it is important to note that the intrusion amount is not predictable [16]. Achieving predictable molar intrusion can be challenging, especially in hyperdivergent skeletal open bite patients due to their weak musculature and difficulty using “Chewies”, a biting aid to better fit the aligners to the teeth. As the clinician tends to plan more intrusion of the molars in hyperdivergent patients, the amount achieved can vary from what was planned. To facilitate molar intrusion using clear aligners in hyperdivergent patients, a clinician may recommend vibration therapy. Although there is no scientific literature on the matter, our clinic has observed that vibration therapy has helped in aligner seating and molar intrusion. Further studies are necessary to verify these findings.

Clear aligner treatment can benefit patients with mild to moderate skeletal open bite, who can afford some anterior extrusion. As the posterior intrusion with clear aligners is not always predictable, ClinCheck treatment plans often involve over-intrusion of maxillary molars and overtreatment of the occlusion with heavy anterior contacts. If more than 1 to 2 mm posterior intrusion is needed, microimplant anchorage is recommended (Figures 2-1 through 2-4). Studies on molar intrusion with skeletal anchorage have reported about 2 to 3 mm maxillary molar intrusion [42]. It is also important to consider the lower molars during treatment, as lower molars can erupt or extrude significantly after upper molar intrusion and decrease the amount of autorotation [43].

A case is presented below where a considerable bite closure was achieved using microimplant anchorage. To attain positive overbites for all four incisors, we incorporated vibration therapy towards the end of the treatment.

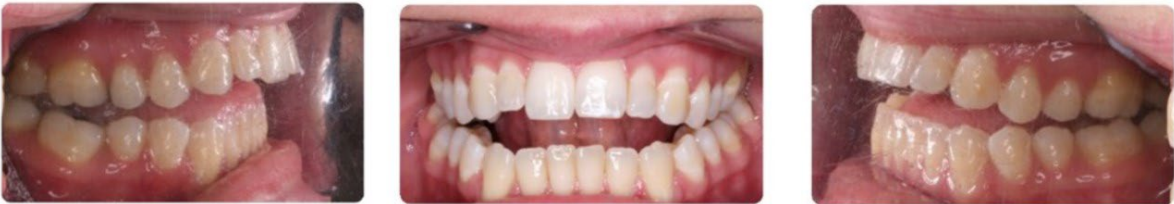
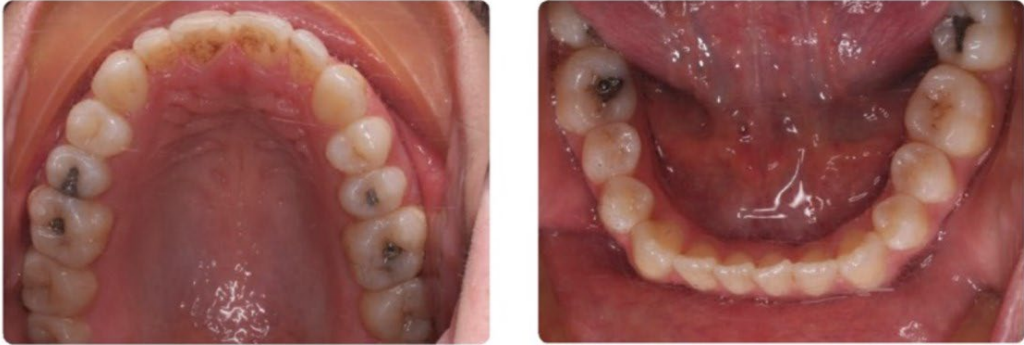
Figure 2-1. Before treatment intraoral photos.

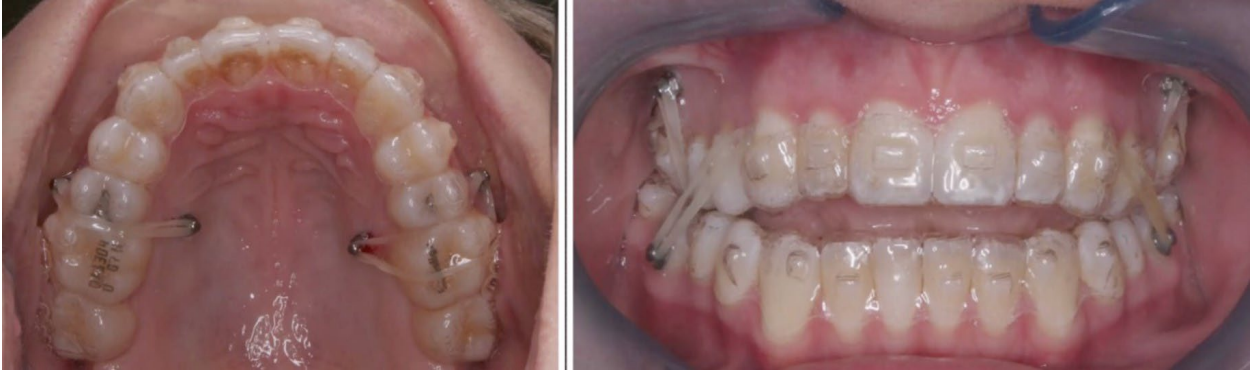

Figure 2-2. Microimplant anchorage for molar intrusion.

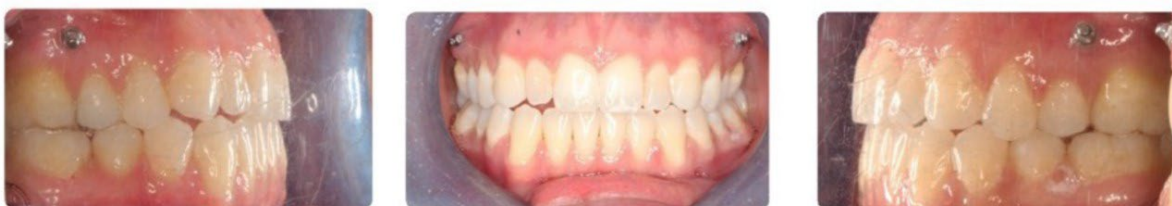
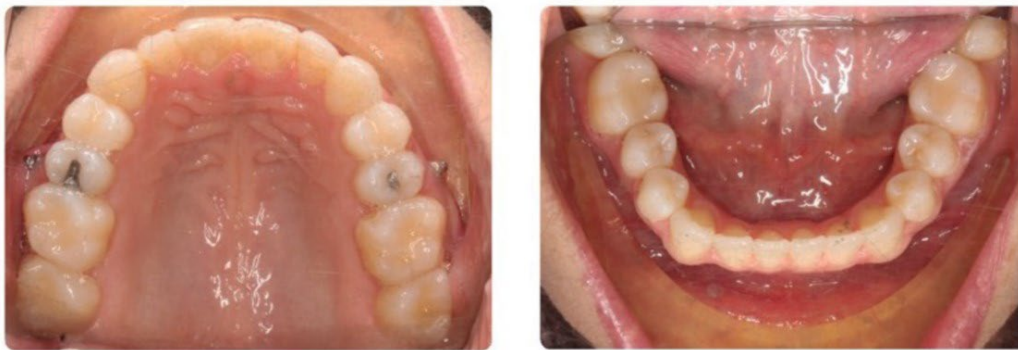
Figure 2-3. Twenty-two-month progress intraoral photos.

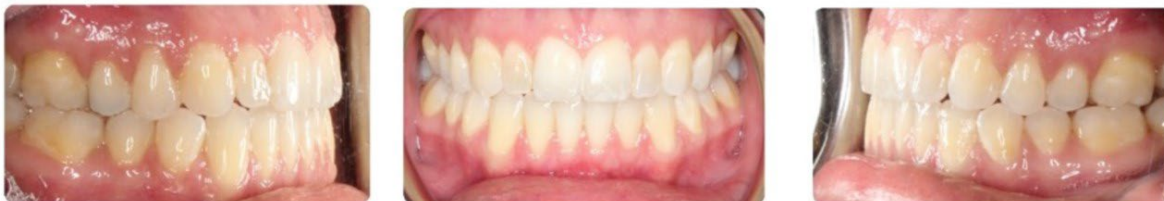
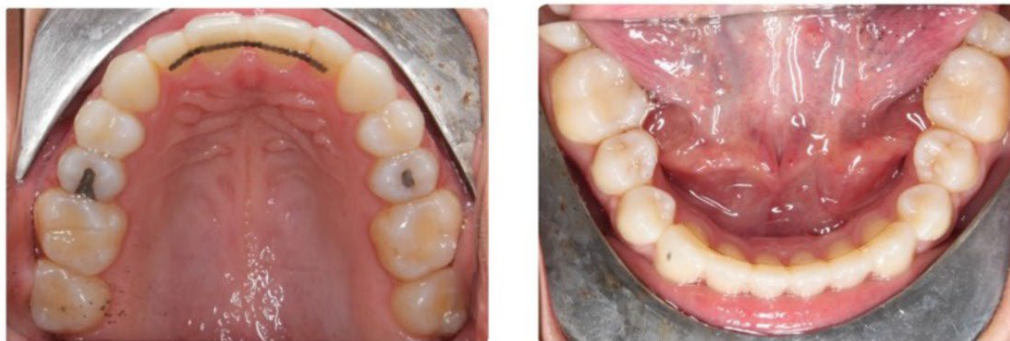
Figure 2-4. After treatment intraoral photos.

A retrospective study of 69 adult open bite patients treated with clear aligners found an average overbite correction of 3.3 mm with clear aligners [16]. The study showed 36% of the open bite closure was achieved through maxillary incisor extrusion, 33% through lower incisor extrusion, and 15% through maxillary molar intrusion, while lower molars were held vertically (Figure 3) [16].

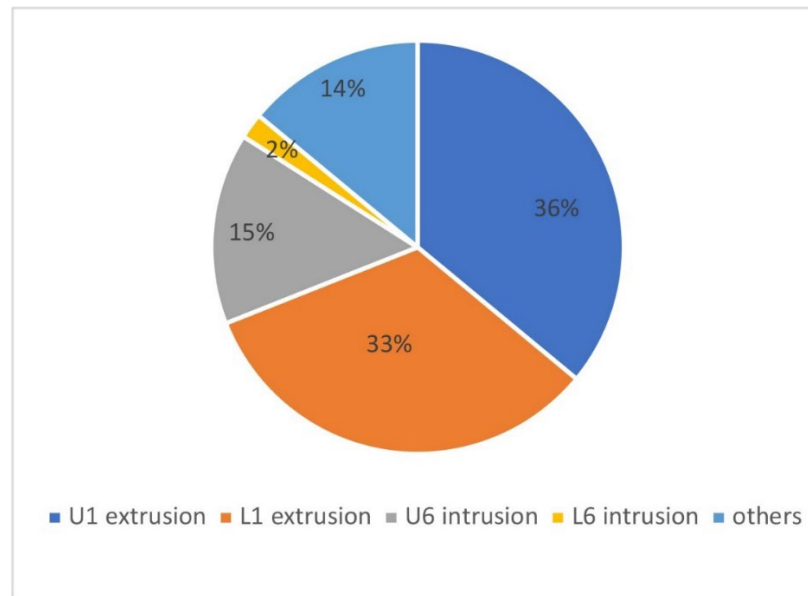


Figure 3. Dental change during anterior open bite correction with clear aligners.

Mandibular molars may also be intruded with clear aligner treatment, but typically more maxillary molar intrusion is planned and achieved to autorotate the mandible while holding mandibular molars vertically. In severe anterior open bite patients, additional lower molar intrusion may help to increase overbite.

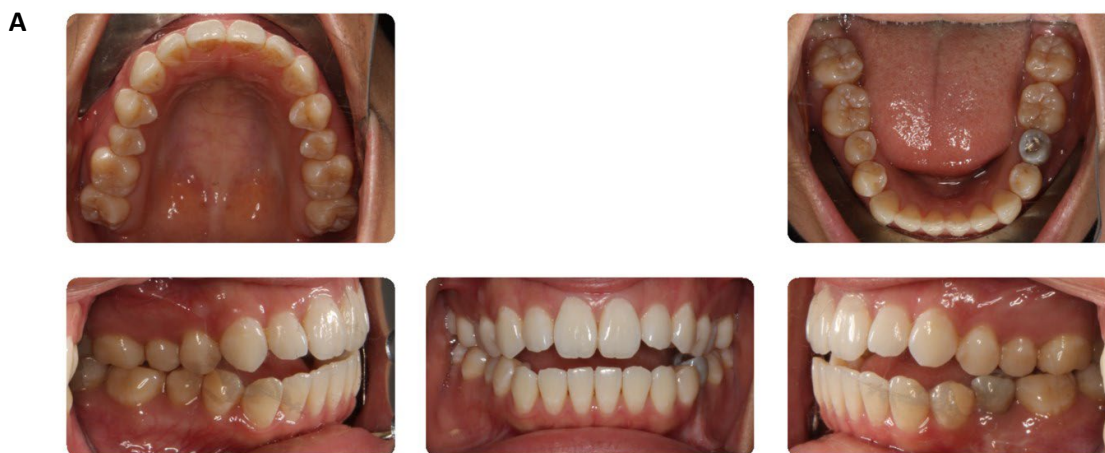When treatment planning for anterior open bite cases, the Curve of Spee needs to be leveled in all patients. The anterior teeth are extruded only if it was necessary to level the occlusal plane, and the rest of the open bite is closed through molar intrusion. To assist intrusion, horizontal attachments are placed on all premolars and molars, and attachments on maxillary incisors serve as anchorage. During the refinement stage, over-intrusion of maxillary molars can be planned. For patients with dental open bites and a reverse Curve of Spee, optimized attachments programmed on the incisors can assist in anterior extrusion to level the Curve of Spee. However, if interproximal reduction is planned to help reduce dental protrusion and black triangles, attachments may not be necessary on all the incisors. Relative extrusion through retroclination might be sufficient to close the bite. Additionally, it is recommended that patients have their third molars removed prior to undergoing clear aligner therapy.

Anterior posterior consideration

Clinicians need to consider sagittal jaw discrepancies and Angle Class I, II, and III molar relationships when treating anterior open bites. Intruding the posterior teeth, which results in reduction of the mandibular plane angle and lower face height through counterclockwise rotation of the mandible, is advantageous in correcting skeletal anterior open bites with retrognathic mandibles, Class II molar relationships, and large overjets. However, not all anterior open bites should be treated by posterior intrusion, especially in Class III open bite cases, as this may worsen the existing buccal occlusion and negative overjet or even cause a Class III molar relationship to develop in a Class I patient. Therefore, accurate diagnosis of an open bite is crucial in determining the appropriate biomechanics for clear aligner therapy, which depends on the severity of the molar relationship as well as the vertical skeletal pattern.

Class I open bite

In Class I open bite malocclusions, the vertical dimension plays an important part in skeletal diagnosis. For example, a patient with a Class I molar relationship, normal ANB angle and overjet, but a severe hyperdivergent skeletal pattern, may have a large mandible with a long lower face height, and this case should be diagnosed as a Class III skeletal pattern (Figure 4-1). Thus, when the molars are intruded and the mandible autorotates, the patient may have a more Class III relationship. In such cases, Class III elastics and additional mandibular incisor retraction are needed. Treatment for these patients would be planned with molar intrusion, Class III elastics, and possibly interproximal reduction (IPR) in the lower arch to negate forward movement of the mandibular incisors resulting from counterclockwise rotation of the mandible (Figures 4-2 through 4-4). The treatment plan for the patient shown in Figure 4 involved the use of 26 aligners, followed by a refinement stage that required an additional 21 aligners.

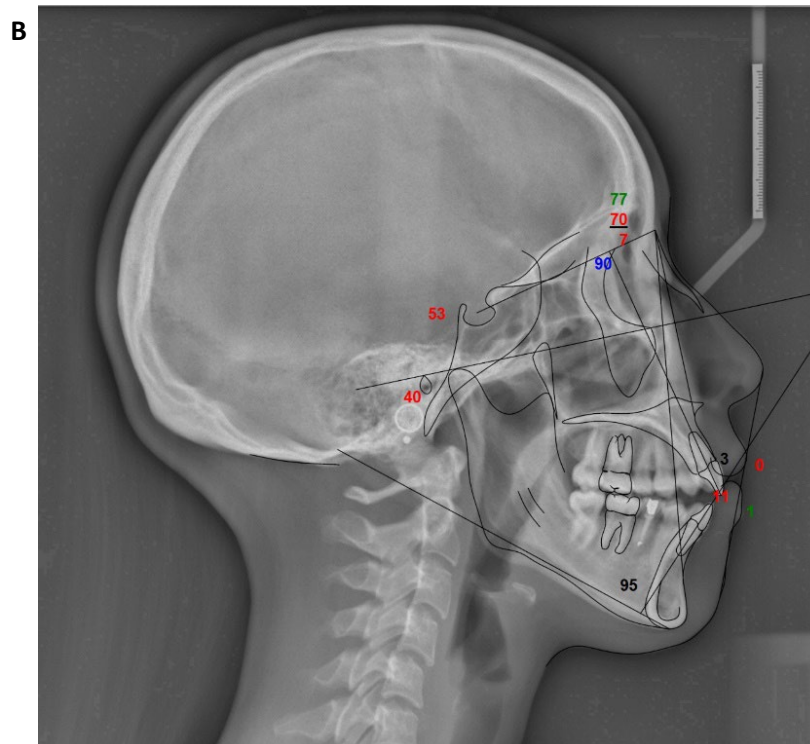

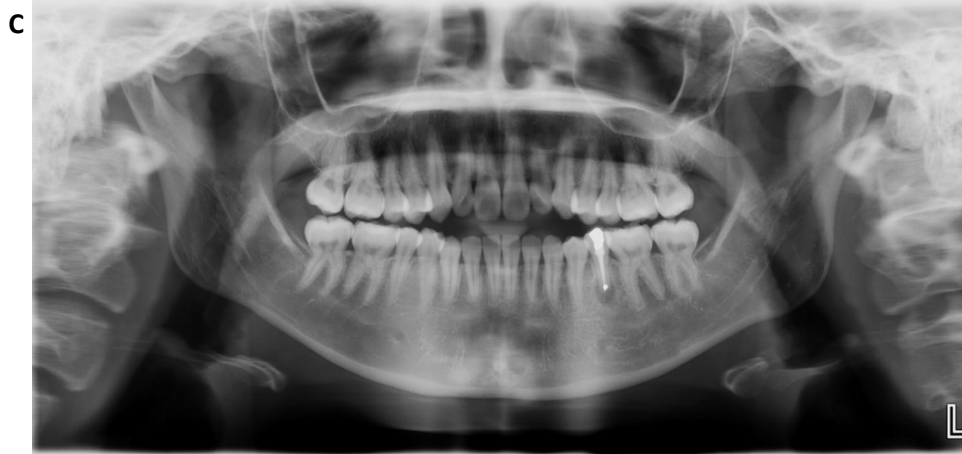


Figure 4-1. Before treatment records of a skeletal open bite patient with Angle Class I malocclusion. A) intraoral photos, B) traced lateral cephalogram, C) panoramic radiograph.

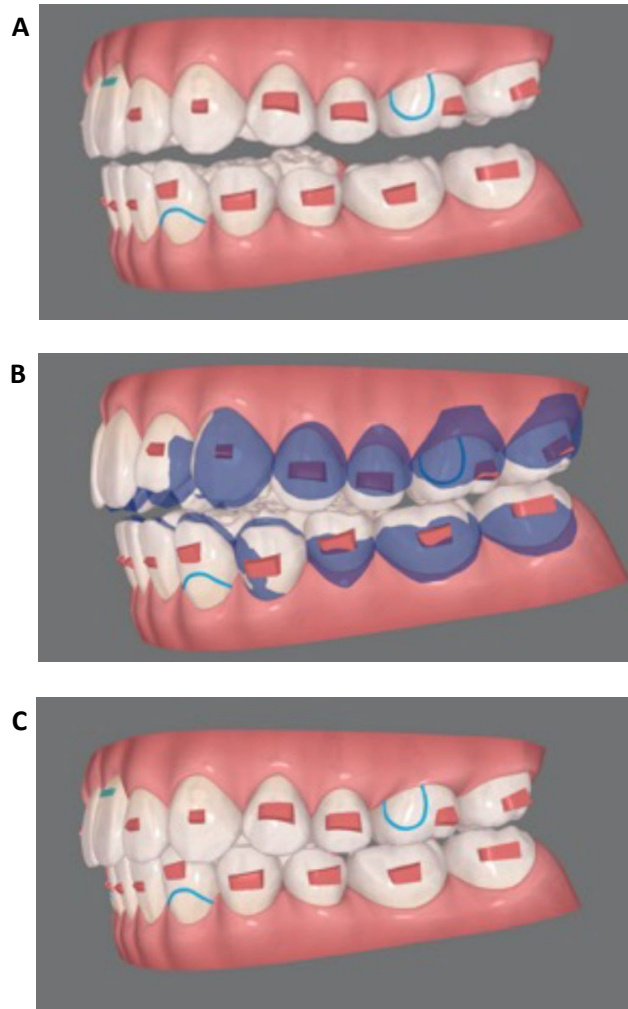


Figure 4-2. Tooth movement treatment plan. A) superimposition of initial and treatment plan (blue) showing planned tooth movement. Class III elastics and additional incisor retraction were planned, B) before bite jump, C) after bite jump.

A

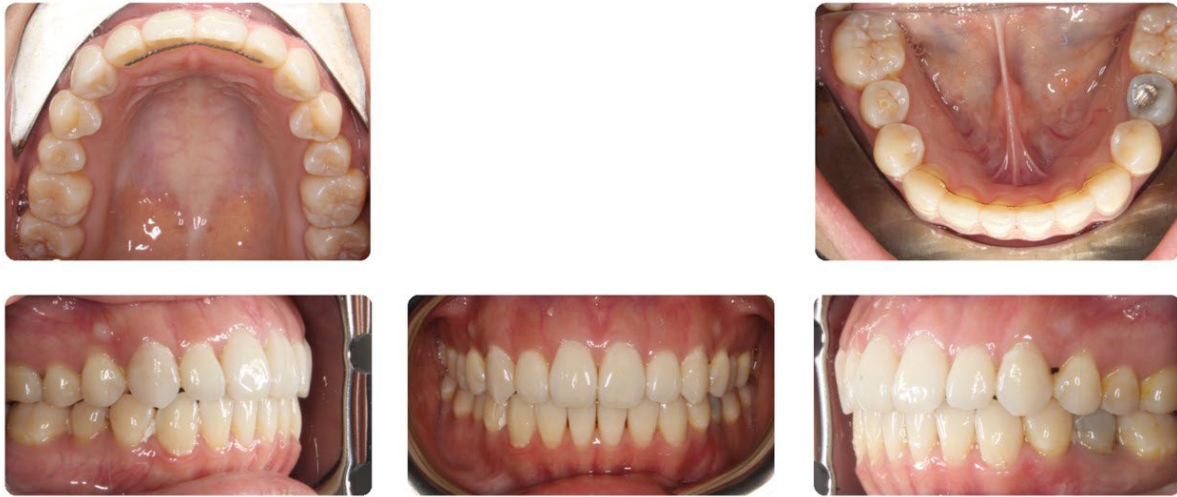


Fig. 40

B

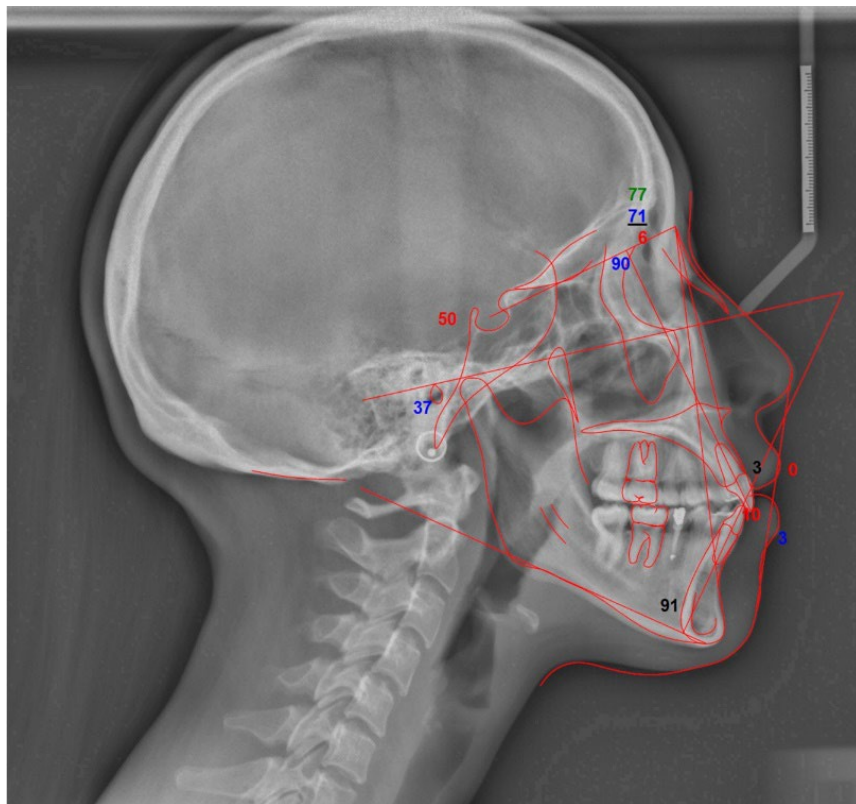

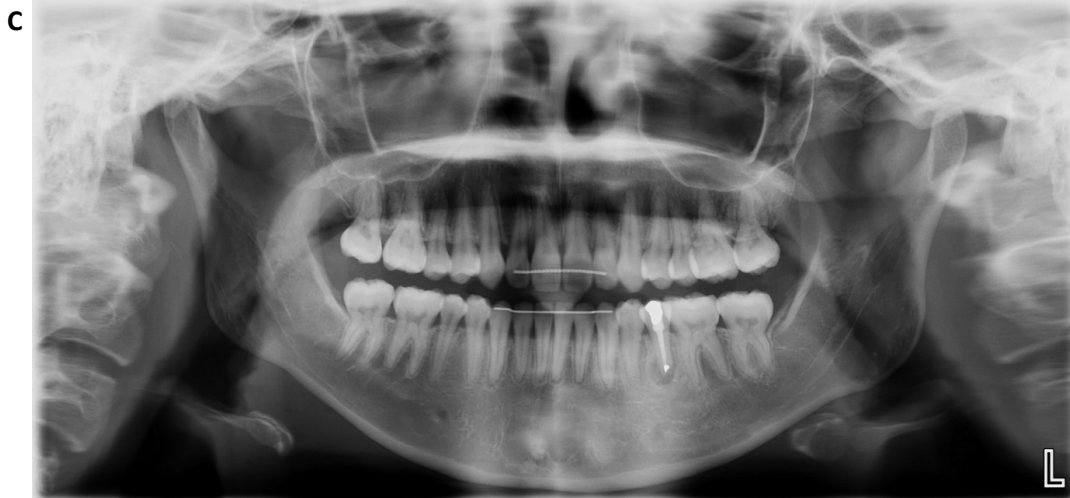


Figure 4-3. After treatment records of the skeletal open bite patient with Angle Class I malocclusion. A) intraoral photos, B) traced lateral cephalogram, C) panoramic radiograph.

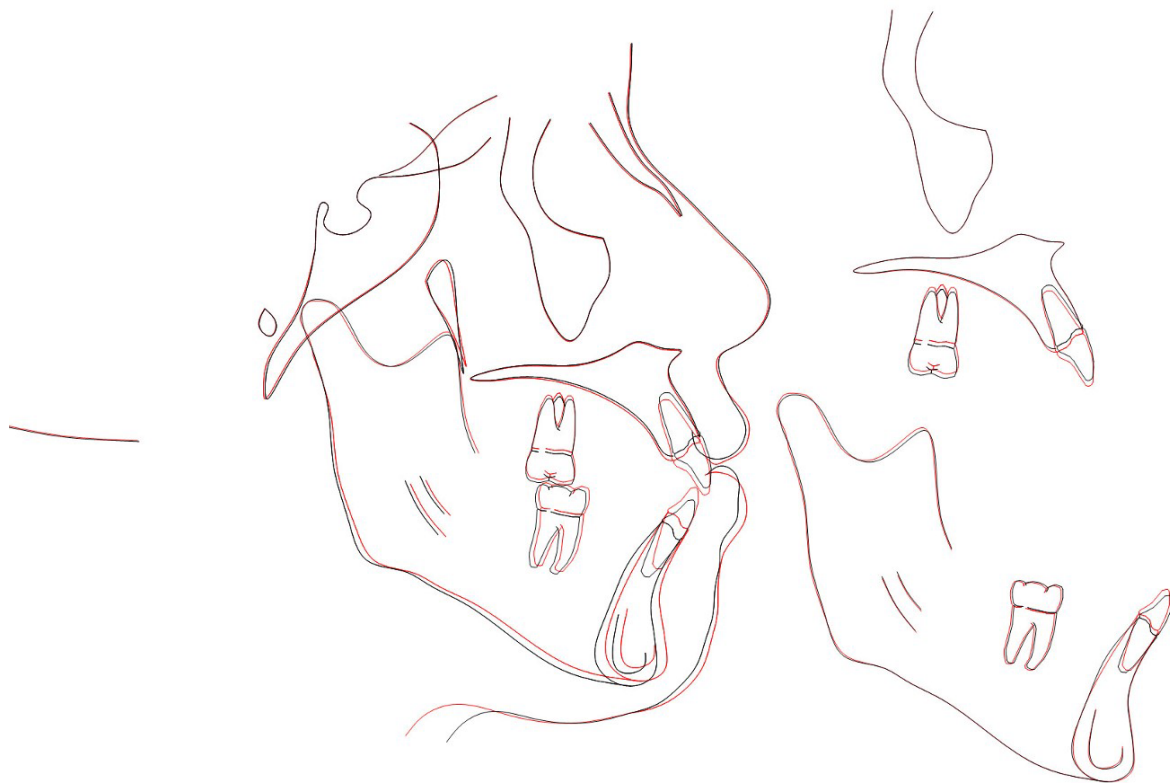


Figure 4-4. Before and after treatment superimposition of the skeletal open bite patient with Angle Class I malocclusion. Treatment duration was 1 year and 1 month. This patient's open bite was corrected with molar intrusion, Class III elastics, and IPR in the lower arch to negate forward movement of the lower incisors resulting from counterclockwise rotation of the mandible.

Figures 5-1 through 5-3 show a patient with a less hyperdivergent vertical pattern compared to the patient in Figure 4. This patient also has a dental component contributing to her open bite. As a result, less intrusion of the molars was planned compared to the previous patient, and instead, more extrusion of the anterior teeth was planned to level the maxillary and mandibular arches. On the other hand, a Class I open bite with a low mandibular plane angle is most likely a dental open bite. In such cases, minimal molar intrusion is planned, and more optimized extrusion attachments are placed to extrude the anterior teeth.

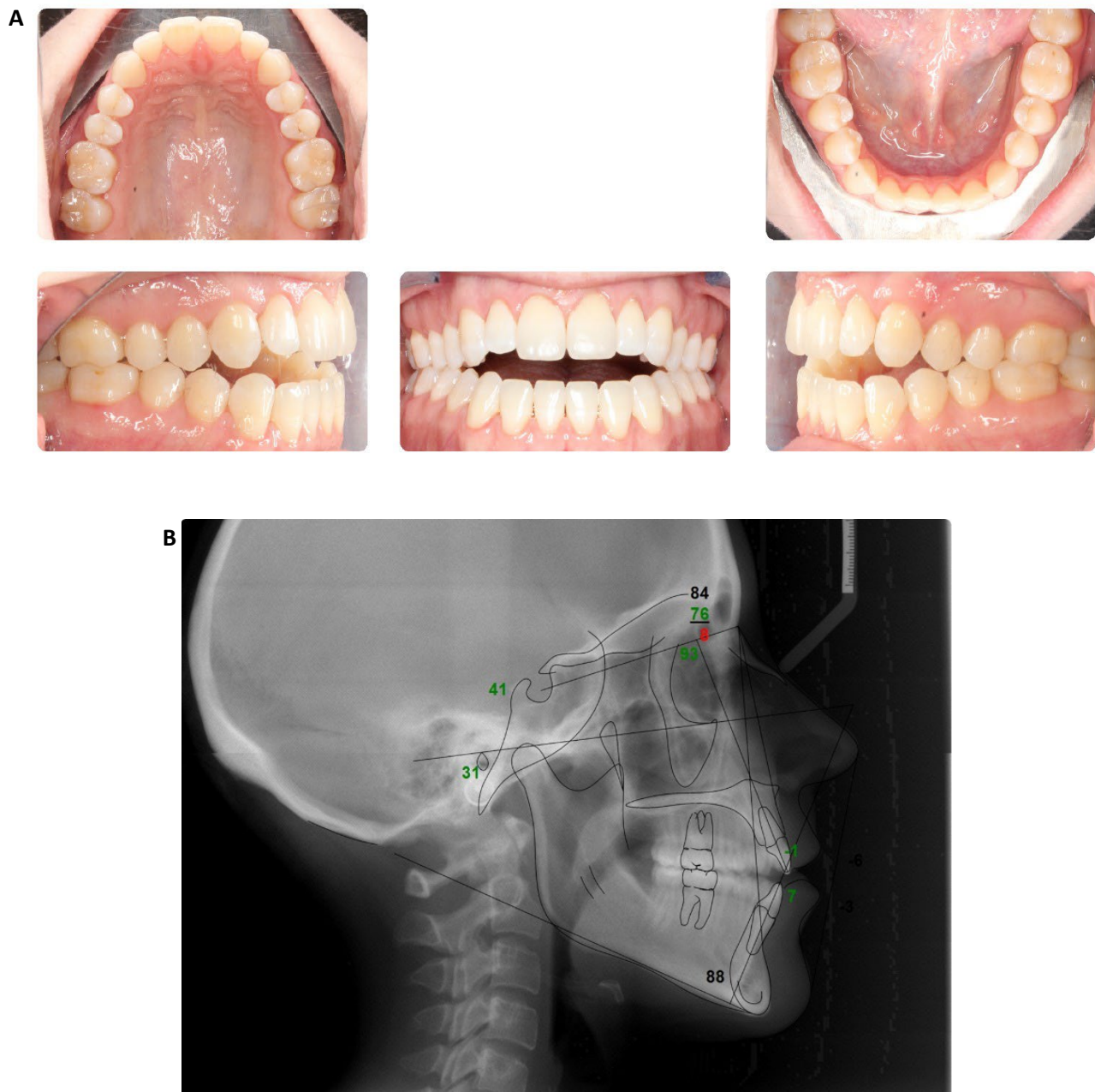


Figure 5-1. Before treatment records of a skeletal and dental open bite patient. A) intraoral photos, B) traced lateral cephalogram.

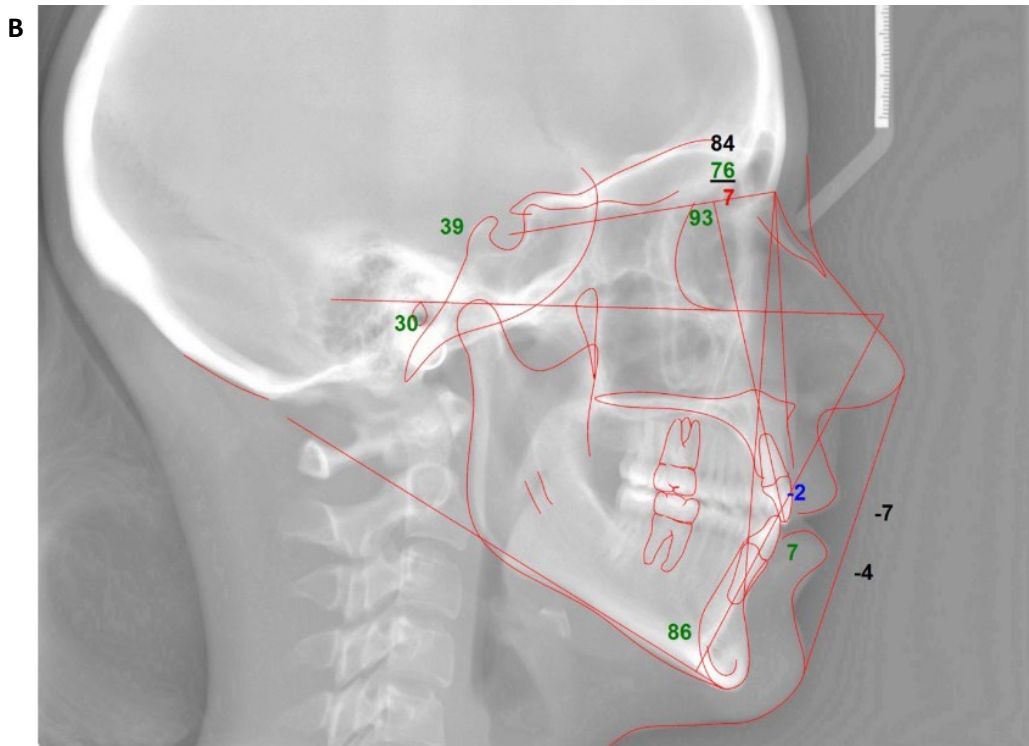
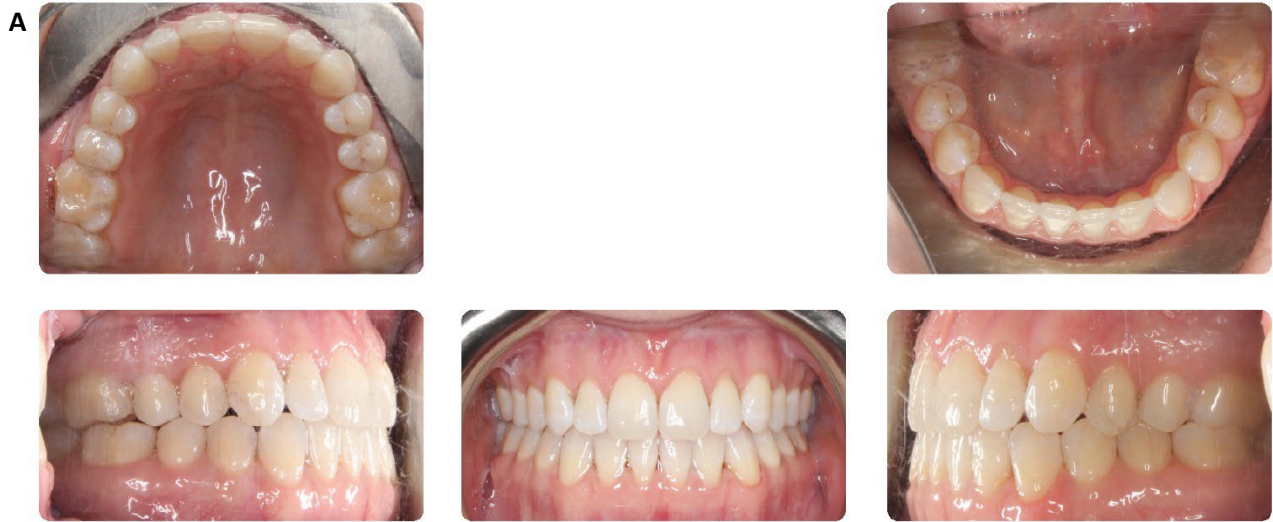

Figure 5-2. After treatment records of the skeletal and dental open bite patient. A) intraoral photos, B) traced lateral cephalogram.

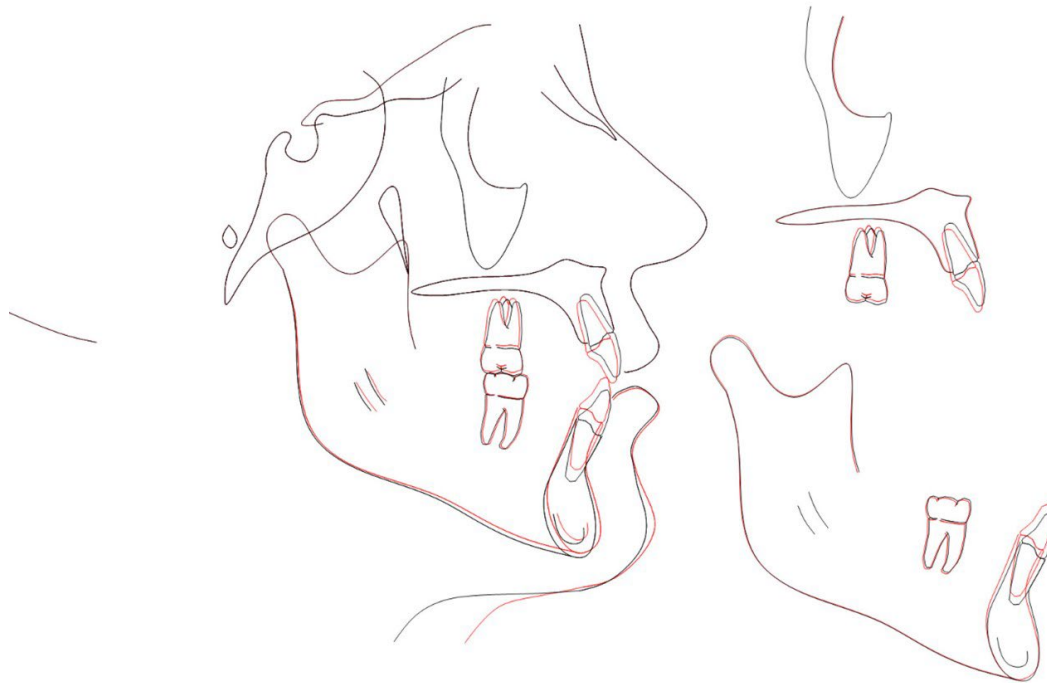


Figure 5-3. Before and after treatment superimposition of the patient. In this patient, less molar intrusion and more anterior extrusion with extrusion attachments were planned.

Class II open bite

For Class II patients with open bite, greater molar intrusion is planned than for Class I and Class III open bite patients. The clinician can plan to close the open bite through molar intrusion and autorotation of the mandible. In a previous study that assessed 69 patients, the greatest upper molar intrusion (-0.8 ± 0.91 mm) was reported in Class II group (Figure 6A,B) [16].

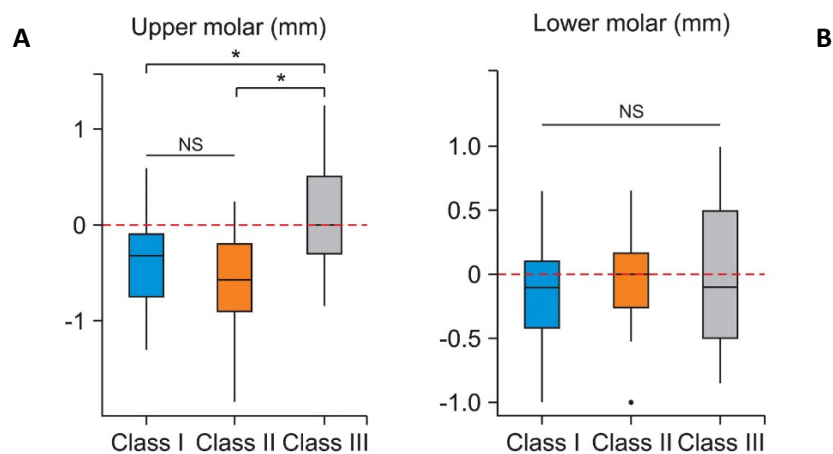
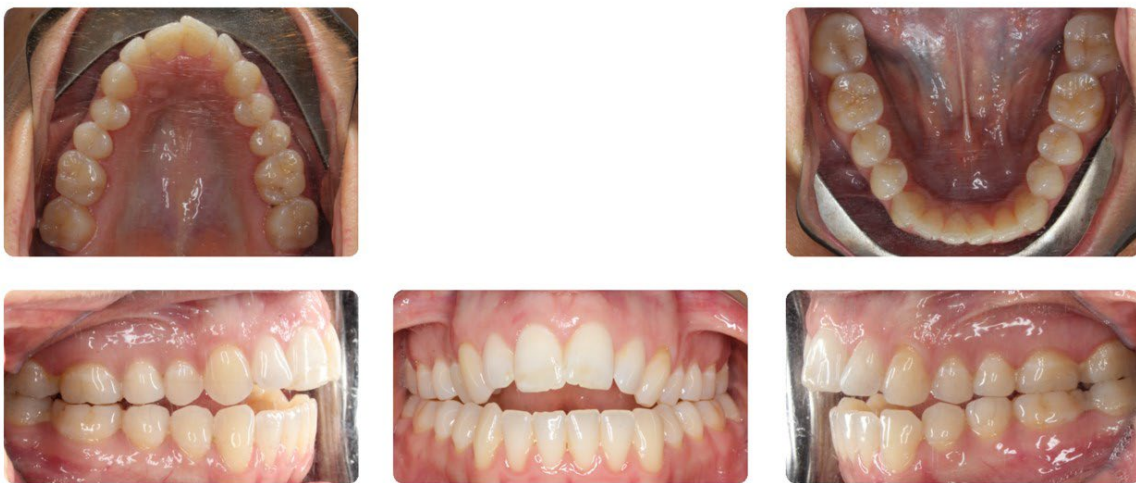

Figure 6. Vertical changes by Angle class groups. A) Upper first molar change, B) Lower first molar change. Dental intrusion presented as negative value; dental extrusion presented as positive value. NS, not significant. * Represents significant difference between the groups. Statistical significance set at $p < 0.05$. [16](Reproduced with permission)

The treatment plan for Class II open bite patients may vary based on the severity of the malocclusion. In cases where the molar relationship is about half a cusp Class II or less, Class II correction can be achieved using only Class II elastics and no upper molar distalization. Molar intrusion and autorotation of the mandible are used to correct the anterior open bite (Figures 7-1 through 7-6). The patient in Figures 7-1 through 7-6 received a total of 27 aligners as part of her treatment. Additionally, a refinement was done which involved the use of an additional 18 aligners. For Class II patients with greater than end-on Class II molar relationship, upper molar intrusion and distalization are planned to achieve Class I correction. This is achieved through sequential distalization and intrusion of the upper molars using conventional 4 to 5 mm horizontal beveled attachments on all the premolars and molars, along with Class II elastics. Class II elastics were applied from precision cuts in the maxillary canines and buttons on the mandibular first molars. In growing full cusp Class II patients, molar relationship is corrected by mandibular growth and autorotation through molar intrusion.

A



B

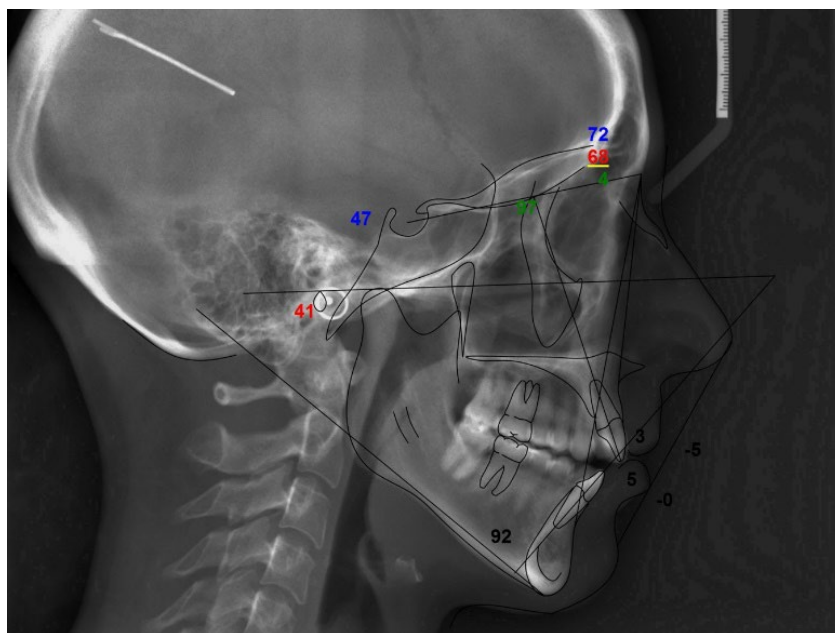

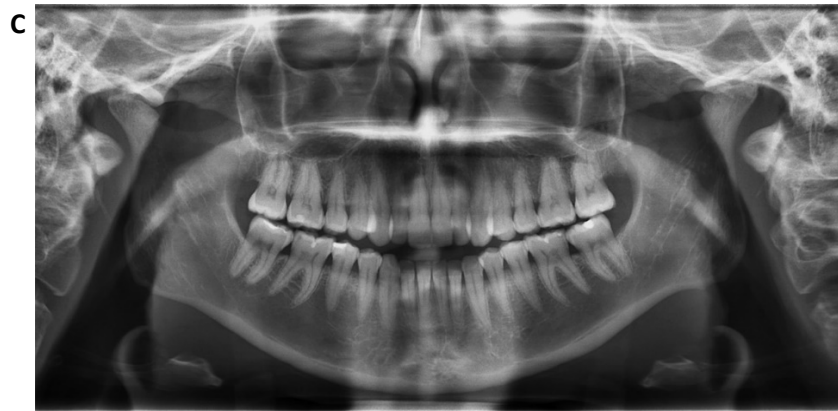


Figure 7-1. Before treatment records of a Class II open bite patient. Patient presented with half cusp Class II molar and canine relationship. A) intraoral photos, B) traced lateral cephalogram, C) panoramic radiograph.

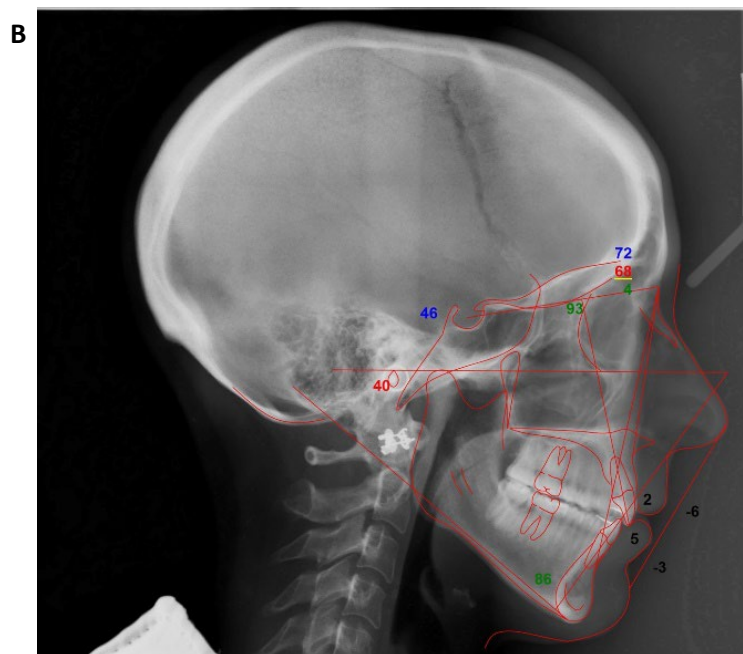
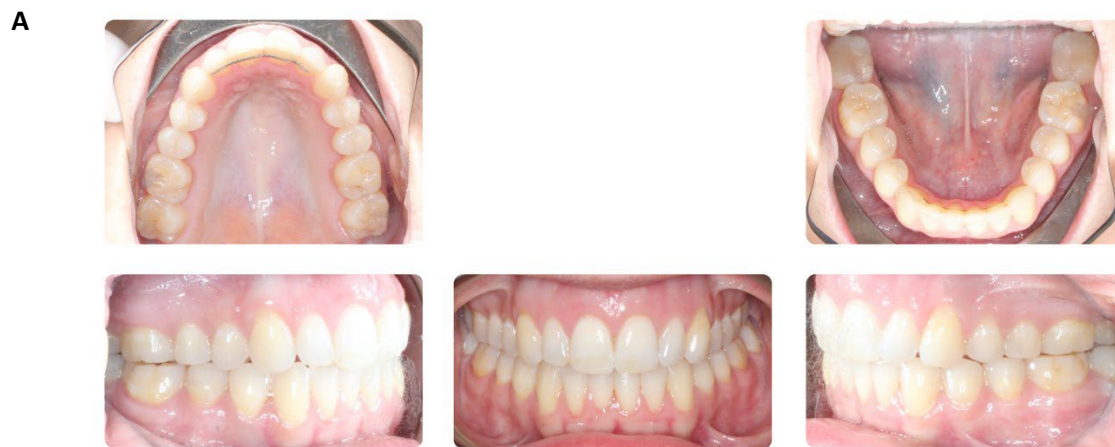

Figure 7-2. After treatment records of the Class II open bite patient. A) intraoral photos, B) traced lateral cephalogram.

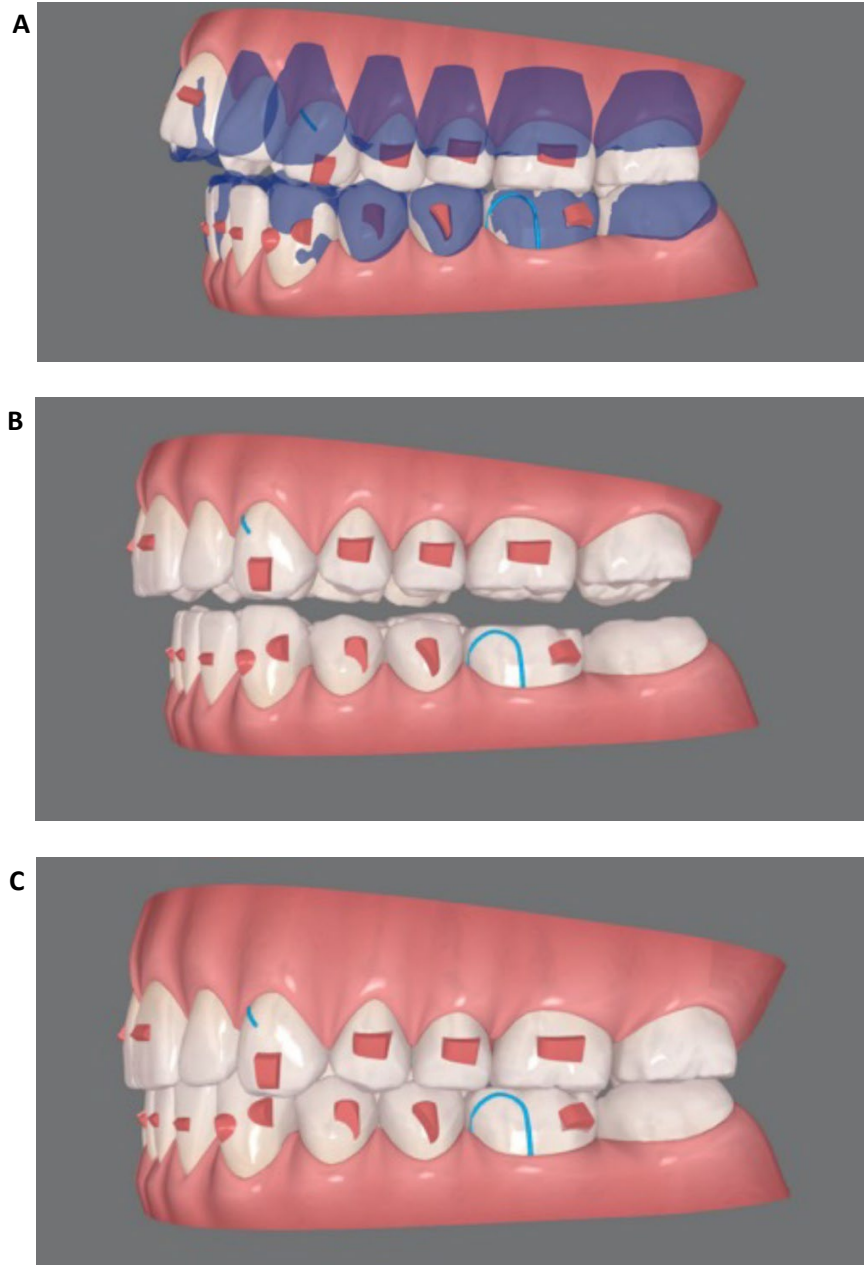


Figure 7-3. Tooth movement treatment plan. A) Superimposition of initial and treatment plan (blue) showing planned tooth movement. Posterior teeth intrusion and autorotation of the mandible are planned to correct the anterior open bite. Over 2 mm of maxillary molar intrusion was planned, B) before bite jump, C) after bite jump.

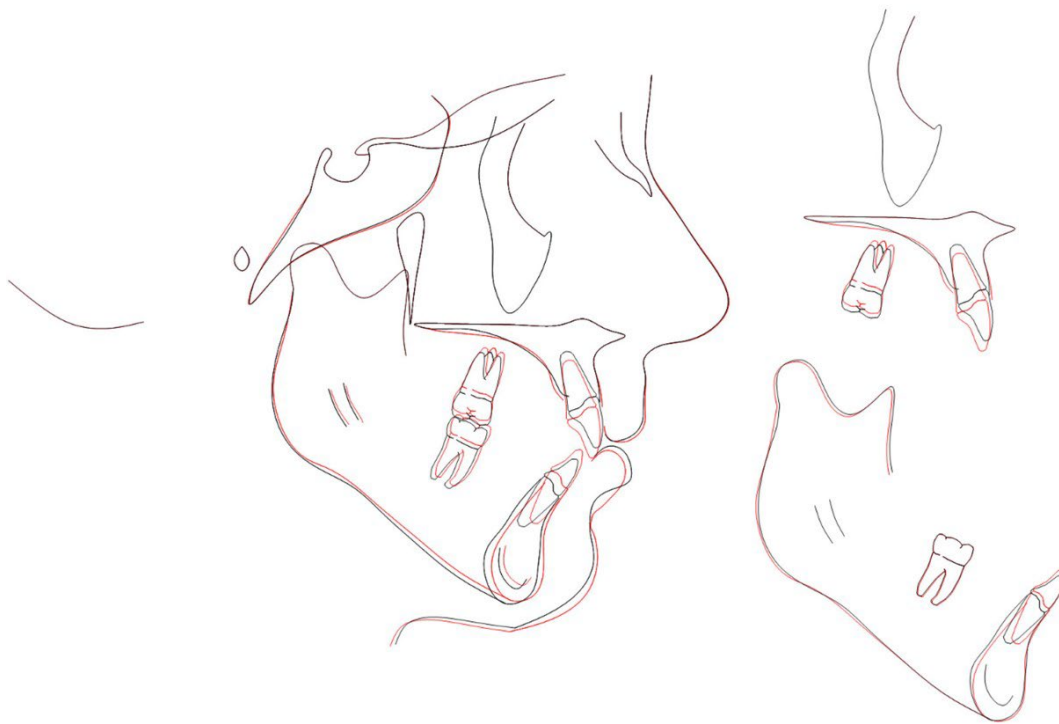


Figure 7-4. Before and after treatment superimposition of the patient. Treatment duration was 1 year and 10 months. Class II correction was achieved using only Class II elastics and no upper molar distalization. Molar intrusion of 1.3 mm was achieved, and autorotation of the mandible helped correcting the anterior open bite.

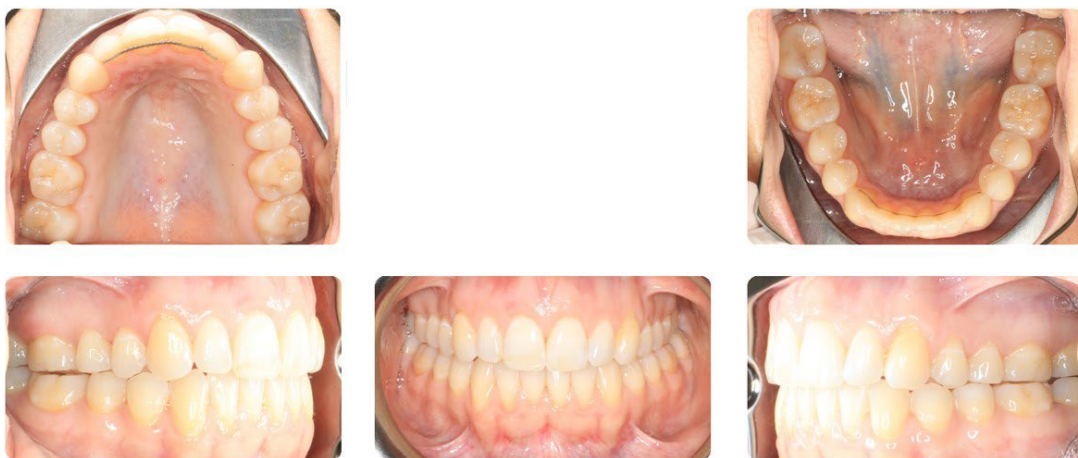

Figure 7-5. One-year retention photos.

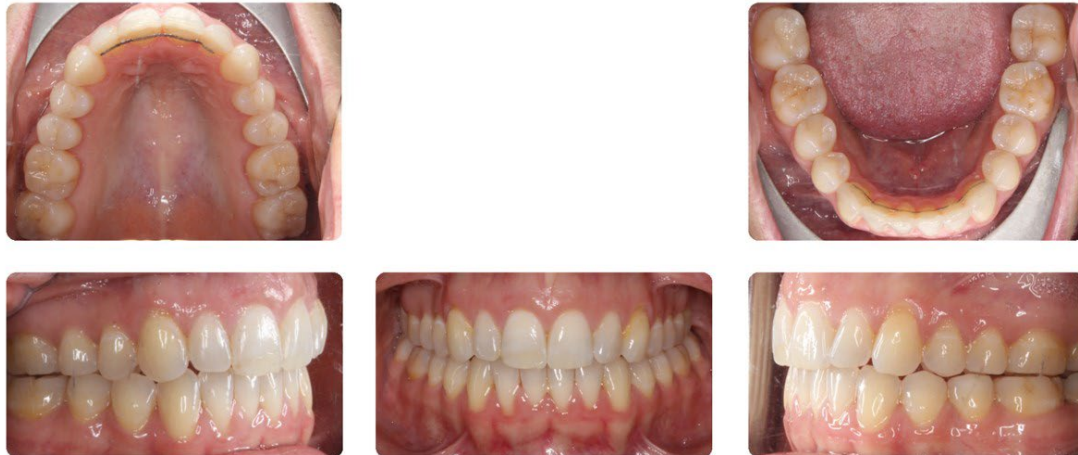
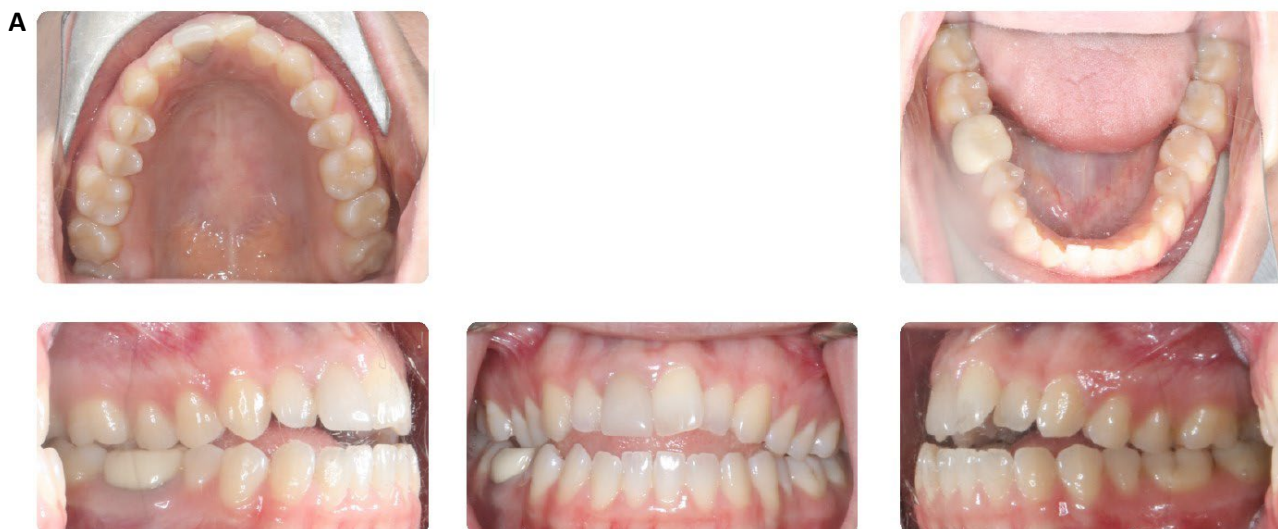
Figure 7-6. Five-year retention photos.

Class III open bite

Class III malocclusions in severely hyperdivergent patients are the most difficult to treat with orthodontic treatment alone, often requiring orthognathic surgery. A previous study reported that even with extensive use of Class III elastics to correct the anterior crossbite and Class III molar relationship, the vertical dimension was well maintained in clear aligner treatment [16]. Good vertical control is crucial for successful treatment of Class III hyperdivergent patients because any molar extrusion would result in an increase in open bite and require further incisor extrusion, which often leads to unaesthetic gummy smiles. Thus, the key to successful open bite correction in Class III patients is good vertical control with mandibular incisor retroclination and extrusion. Molar intrusion is planned in Class III patients with skeletal open bite to maintain the vertical dimension while Class III elastics are used. In some Class III skeletal open bite patients, more molar intrusion is needed to decrease lower facial height. In these cases, lower sequential distalization can be planned to achieve Class I molar relationship (Figures 8-1 through 8-4).



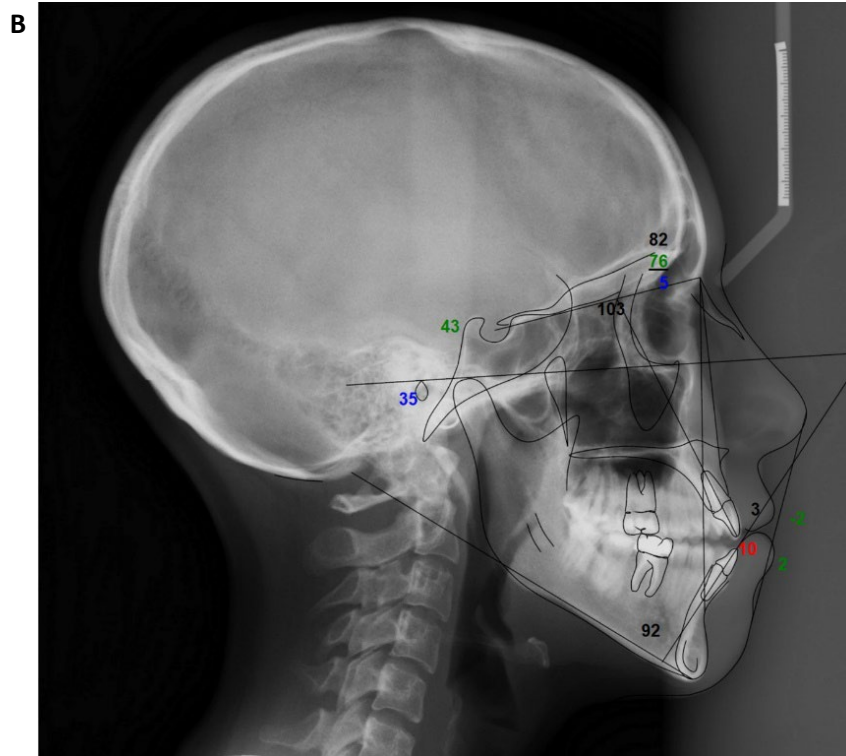


Figure 8-1. Before treatment records of an anterior open bite patient with Angle Class III malocclusion. A) intraoral photos, B) traced lateral cephalogram.

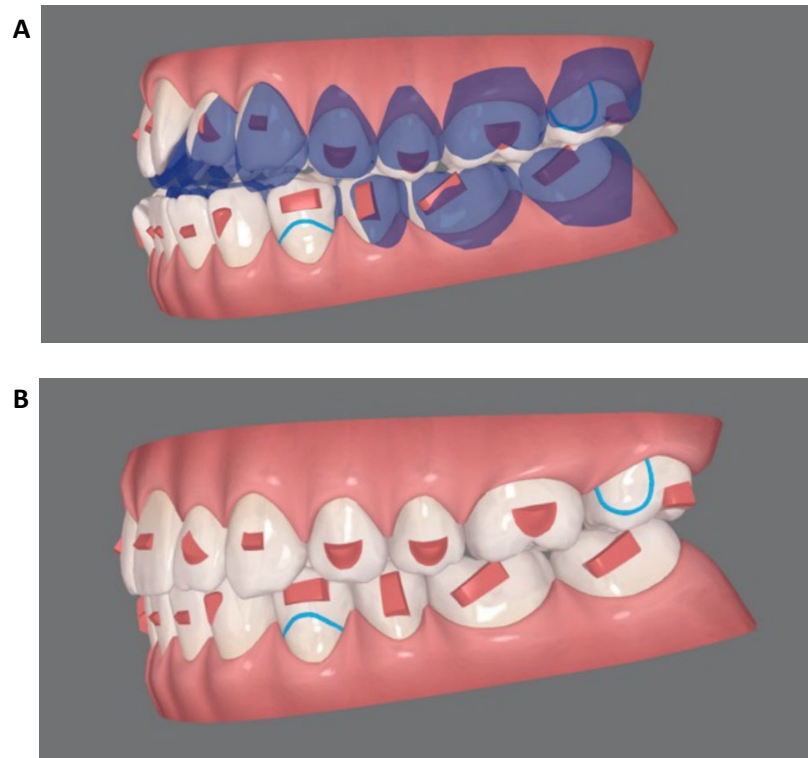


Figure 8-2. Tooth movement treatment plan. A) Superimposition of initial and treatment plan (blue) showing planned tooth movement. Less than 1 mm of upper molar intrusion planned to maintain the vertical dimension while

Class III elastics were used. Sequential distalization of mandibular dentition was planned, B) treatment plan after bite jump.

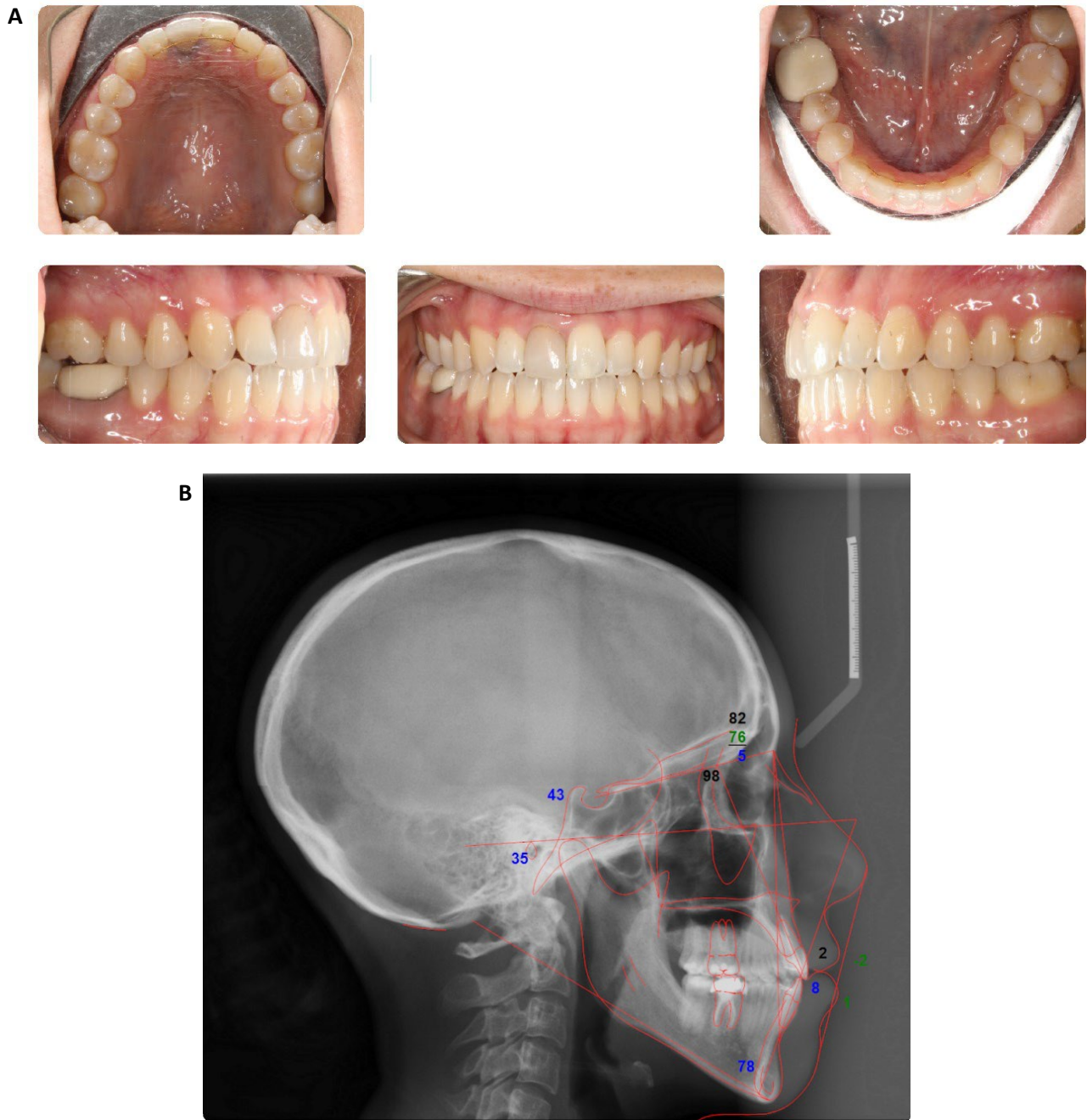


Figure 8-3. After treatment records of the open bite with Angle Class III malocclusion. A) intraoral photos, B) traced lateral cephalogram.

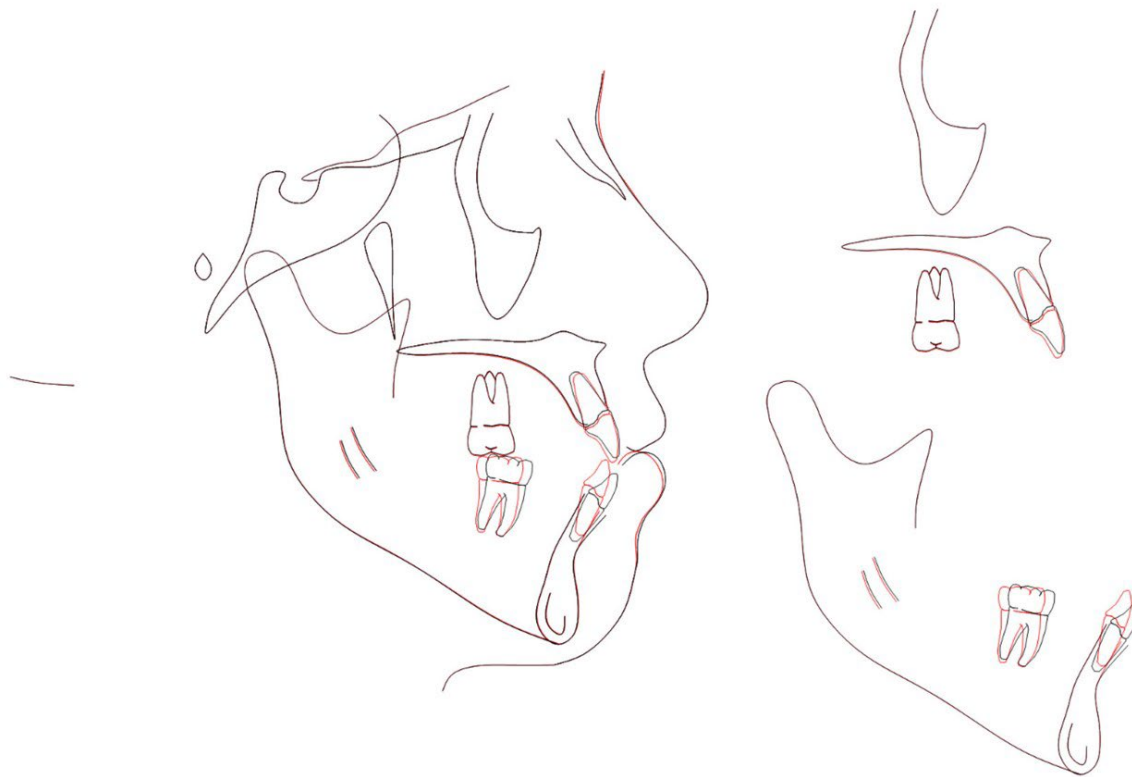


Figure 8-4. Before and after treatment superimposition of the patient. Treatment duration was 2 years and 11 months. In this Angle Class III malocclusion patient, open bite was closed through good vertical control with lower incisor retroclination and extrusion. Molar intrusion was planned to maintain the vertical dimension while Class III elastics were used. Lower dentition was distalized to achieve Class I molar and canine relationship.

On the other hand, Class III patients with dental open bite are treated by extrusion of the maxillary molars and mandibular incisors using Class III elastics. More IPR is programmed in the mandibular arch as the Curve of Spee is flattened. In addition, less molar intrusion is treatment planned for these patients as it causes the mandible to rotate forward and worsen the Class III malocclusion with a more prognathic profile, making correction more difficult. In most Class III dental open bite cases, the sagittal relationship is corrected using Class III elastics, which results in extrusion of the mandibular incisors and maxillary molars that increases the mandibular plane angle and improves the patient's profile. Most of the time, anterior attachments are not needed on the mandibular incisors as some relative extrusion results from retraction of the mandibular incisors.

Clear aligners can effectively manage the vertical dimension and achieve molar intrusion, which helps close the anterior open bites. This contrasts with fixed appliances, where the use of Class II or Class III elastics can lead to molar extrusion if TADs are not used. While fixed appliance therapy requires archwire

stiffness to minimize the vertical side effects of interarch elastics, clear aligners allow clinicians to incorporate interarch elastics from the start of treatment.

Retention protocol

After completing orthodontic treatment, all patients can be retained with bonded upper 2-2 and lower 3-3 bonded retainers to maintain anterior alignment. Overlay Essix-type retainers, which are worn only at night, provide posterior coverage and help maintain molar intrusion. After one year, the bonded retainers can be removed, and the patients can continue wearing the removable retainers at night only.

CONCLUSIONS

For effective treatment planning and successful treatment, it is crucial to identify the cause of the anterior open bite and understand the interaction between sagittal and vertical factors, particularly in skeletal open bite cases. Therefore, it is imperative to take a CBCT or lateral cephalometric radiograph image prior to treatment for accurate diagnosis of the sagittal and vertical skeletal dimensions. This will enable the orthodontist to plan proper treatment mechanics utilizing incisor extrusion, molar intrusion, distalization, protraction, or a combination of these techniques based on open bite diagnoses in different malocclusions.

REFERENCES

1. Subtelny JD, Sakuda M. Open-bite: Diagnosis and treatment. *American Journal of Orthodontics* 1964; 50(5):337-358.
2. Todoki LS, Finkleman SA, Funkhouser E, Greenlee GM, Choi KW, Ko HC, Wang HF, Shapiro PA, Khosravi R, Baltuck C, Allareddy V, Dolce C, Kau CH, Shin K, de Jesus-Vinas J, Vermette M, Jolley C, National Dental Practice-Based Research Network Collaborative Group, Huang GJ. The National Dental Practice-Based Research Network Adult Anterior Open Bite Study: Treatment success. *Am J Orthod Dentofacial Orthop*. 2020; 158(6):e137-e150.
3. Remmers D, Van't Hullenaar RW, Bronkhorst EM, Bergé SJ, Katsaros C. Treatment results and long-term stability of anterior open bite malocclusion. *Orthod Craniofac Res*. 2008;11(1):32-42.
4. Ngan P, Fields HW. Open bite: a review of etiology and management. *Pediatr Dent* 1997; 19(2):91-98.
5. Beane RA Jr. Nonsurgical management of the anterior open bite: a review of the options. *Semin Orthod* 1999; 5(4):275-283.
6. Dung DJ, Smith RJ. Cephalometric and clinical diagnoses of open bite tendency. *Am J Orthod Dentofacial Orthop* 1988; 94(6):484-490.
7. Nielsen IL. Vertical malocclusions: etiology, development, diagnosis and some aspects of treatment. *Angle Orthod* 1991; 61(4):247-260.
8. Greenlee GM, Huang GJ, Chen SS, Chen J, Koepsell T, Hujoel P. Stability of treatment for anterior open-bite malocclusion: a meta-analysis. *Am J Orthod Dentofacial Orthop* 2011; 139(2):154-69.
9. Kuroda S, Sakai Y, Tamamura N, Deguchi T, Takano-Yamamoto T. Treatment of severe anterior open bite with skeletal anchorage in adults: comparison with orthognathic surgery outcomes. *Am J Orthod Dentofacial Orthop* 2007; 132(5):599-605.
10. Deguchi T, Kurosaka H, Oikawa H, Kuroda S, Takahashi I, Yamashiro T, Takano-Yamamoto T. Comparison of orthodontic treatment outcomes in adults with skeletal open bite between

- conventional edgewise treatment and implant-anchored orthodontics. *Am J Orthod Dentofacial Orthop* 2011; 139(4 Suppl):S60-S68.
11. Boyd RL, Waskalic V. Three-dimensional diagnosis and orthodontic treatment of complex malocclusions with the invisalign appliance. *Seminars in Orthodontics* 2001; 7(4):274-293.
 12. Moshiri S, Araújo EA, McCray JF, Thiesen G, Kim KB. Cephalometric evaluation of adult anterior open bite non-extraction treatment with Invisalign. *Dental Press J Orthod* 2017; 22(5):30-38.
 13. Garnett BS, Mahood K, Nguyen M, Al-Khateeb A, Liu S, Boyd R, Oh H. Cephalometric comparison of adult anterior open bite treatment using clear aligners and fixed appliances. *Angle Orthod* 2019; 89(1):3-9.
 14. Dayan W, Aliaga-Del Castillo A, Janson G. Open-bite treatment with aligners and selective posterior intrusion. *J Clin Orthod* 2019; 53(1):53-54.
 15. Guarneri MP, Oliverio T, Silvestre I, Lombardo L, Siciliani G. Open bite treatment using clear aligners. *Angle Orthod* 2013; 83(5):913-919.
 16. Suh H, Garnett BS, Mahood K, Mahjoub N, Boyd RL, Oh H. Treatment of anterior open bites using non-extraction clear aligner therapy in adult patients. *Korean J Orthod* 2022; 52(3):210-219.
 17. Harris K, Ojima K, Dan C, Upadhyay M, Alshehri A, Kuo CL, Mu J, Uribe F, Nanda R. Evaluation of open bite closure using clear aligners: a retrospective study. *Prog Orthod* 2020; 21(1):23.
 18. Khosravi R, Cohanime B, Hujuel P, Daher S, Neal M, Liu W, Huang G. Management of overbite with the Invisalign appliance. *Am J Orthod Dentofacial Orthop* 2017; 151(4):691-699.e2.
 19. Ng CS, Wong WK, Hagg U. Orthodontic treatment of anterior open bite. *Int J Paediatr Dent* 2008; 18(2):78-83.
 20. Proffit WR, Fields HW Jr, Moray LJ. Prevalence of malocclusion and orthodontic treatment need in the United States: estimates from the NHANES III survey. *Int J Adult Orthodon Orthognath Surg* 1998; 13(2):97-106.
 21. Harris EF, Johnson MG. Heritability of craniometric and occlusal variables: a longitudinal sib analysis. *Am J Orthod Dentofacial Orthop* 1991; 99(3):258-268.
 22. Uribe F, Nanda R. Management of Open Bite Malocclusion. In: Nanda R, ed. *Biomechanics and Esthetic Strategies in Clinical Orthodontics*. St. Louis, MO: Elsevier Saunders; 2005: Ch 8; 156-176.
 23. Buschang PH, Jacob H, Carrillo R. The Morphological Characteristics, Growth, and Etiology of the Hyperdivergent Phenotype. *Seminars in Orthodontics* 2013; 19(4):212-226.
 24. Proffit WR. The Etiology of Orthodontic Problems. In: Proffit WR, Fields HW, Larson B, Sarver DM, eds. *Contemporary orthodontics*. Philadelphia, PA: Elsevier, 2018: Ch 5; 107-139.
 25. Cangialosi TJ. Skeletal morphologic features of anterior open bite. *Am J Orthod* 1984; 85(1):28-36.
 26. Buschang PH, Sankey W, English JP. Early treatment of hyperdivergent open-bite malocclusions. *Seminars in Orthodontics* 2002; 8(3):130-140.
 27. Sassouni V. A classification of skeletal facial types. *Am J Orthod* 1969; 55(2):109-123.
 28. Alexander CD. Open bite, dental alveolar protrusion, class I malocclusion: A successful treatment result. *Am J Orthod Dentofacial Orthop* 1999; 116(5):494-500.
 29. Young A. Idiopathic condylar resorption: The current understanding in diagnosis and treatment. *J Indian Prosthodont Soc* 2017; 17(2):128-135.
 30. Ryan MJ, Schneider BJ, BeGole EA, Muhl ZF. Opening rotations of the mandible during and after treatment. *Am J Orthod Dentofacial Orthop* 1998; 114(2):142-149.
 31. Kuster R, Ingervall B. The effect of treatment of skeletal open bite with two types of bite-blocks. *Eur J Orthod* 1992; 14(6):489-499.
 32. Kim YH. Anterior openbite and its treatment with multiloop edgewise archwire. *Angle Orthod* 1987; 57(4):290-321.

33. Freitas BV, Abas Frazão MC, Dias L, Fernandes Dos Santos PC, Freitas HV, Bosio JA. Nonsurgical correction of a severe anterior open bite with mandibular molar intrusion using mini-implants and the multiloop edgewise archwire technique. *Am J Orthod Dentofacial Orthop* 2018; 153(4):577-587.
34. Işcan HN, Dinçer M, Gültan A, Meral O, Taner-Sarisoy L. Effects of vertical chin cap therapy on the mandibular morphology in open-bite patients. *Am J Orthod Dentofacial Orthop* 2002; 122(5):506-511.
35. Villalobos FJ, Sinha PK, Nanda RS. Longitudinal assessment of vertical and sagittal control in the mandibular arch by the mandibular fixed lingual arch. *Am J Orthod Dentofacial Orthop* 2000; 118(4):366-370.
36. Noar JH, Shell N, Hunt NP. The performance of bonded magnets used in the treatment of anterior open bite. *Am J Orthod Dentofacial Orthop* 1996; 109(5):549-557.
37. Boyd RL. Esthetic orthodontic treatment using the Invisalign appliance for moderate to complex malocclusions. *J Dent Educ* 2008; 72(8):948-967.
38. Ellis E 3rd, McNamara JA Jr. Components of adult Class III open-bite malocclusion. *Am J Orthod* 1984; 86(4):277-290.
39. Ellis E 3rd, McNamara JA Jr, Lawrence TM. Components of adult Class II open-bite malocclusion. *J Oral Maxillofac Surg* 1985; 43(2):92-105.
40. Swinnen K, Politis C, Willems G, De Bruyne I, Fieuws S, Heidbuchel K, van Erum R, Verdonck A, Carels C. Skeletal and dento-alveolar stability after surgical-orthodontic treatment of anterior open bite: a retrospective study. *Eur J Orthod* 2001; 23(5):547-557.
41. Tai S. *Clear Aligner Technique*. Hanover Park, IL: Quintessence Publishing Co, Inc; 2018; 114-117.
42. Buschang PH, Carrillo R, Rossouw PE. Orthopedic correction of growing hyperdivergent, retrognathic patients with miniscrew implants. *J Oral Maxillofac Surg* 2011; 69(3):754-762.
43. Scheffler NR, Proffit WR, Phillips C. Outcomes and stability in patients with anterior open bite and long anterior face height treated with temporary anchorage devices and a maxillary intrusion splint. *Am J Orthod Dentofacial Orthop* 2014; 146(5):594-602.

TUNNEL ATTACHMENTS

Alyaa Aldohan, Negin Katebi, Mohamed Masoud

ABSTRACT

Clear aligner therapy has yet to overcome limitations in achieving certain orthodontic tooth movements including rotations of conical teeth, vertical movements, plus correcting tooth angulation and inclination. This chapter formally describes a novel hybrid method that incorporates a wire into computer-designed tunnel attachments used in conjunction with clear aligners to overcome these limitations. The size, geometry, and orientation of tunnel attachments, as well as the transfer method and archwires used when virtually planning the hybrid system are described. This method is effective in improving non-tracking teeth and can be used to address limitations of standalone clear aligner therapy, and customize approaches to treat malocclusions.

KEY WORDS: Aligners, Indirect bonding, Hybrid mechanics, Invisalign®, In-house aligners

INTRODUCTION

Clear aligner therapy became a feasible treatment approach with the advances in computer-aided design/computer-aided manufacturing (CAD/CAM) stereolithographic technology combined with laboratory techniques. Using these technologies, the clinician prospectively formulates a precise treatment plan by modifying a virtual set-up generated by a software program before approval for manufacturing of an aligner series. Each aligner is staged to move teeth in increments of 0.25 to 0.3 mm per aligner [1, 2]. As orthodontists began to appreciate the advantages that virtual 3D imaging brings to diagnosis, treatment planning, and patient education, intraoral scanners began to replace traditional impressions, and digital models took the place of plaster models for virtual treatment planning and appliance fabrication [3-7]. While aligners were initially limited to treating cases of mild to moderate crowding and mild spacing cases [8-10], ongoing research and overall appeal have facilitated their use to treat a more diverse range of cases, including more severe and complex cases.

Since the breakthrough of clear aligner therapy, an abundant set of features have been developed and improved to assist in accomplishing virtually planned tooth movements: incorporation of a variety of tooth-bonded resin attachment configurations for the purpose of increasing contact surface area and creating undercuts, altered clear aligner geometries such as power ridges and bite ramps, attempting to alter force-moment ratio by the addition of power arms and elastics, in addition to more flexible aligner materials that allow delivery of more constant forces throughout the duration of wear [10-12]. Despite continued growth in consumer demand for a more esthetic and comfortable treatment option over fixed appliances, the biomechanical limitations of clear aligners for producing desired outcomes remain the biggest drawback to their use, and arguments regarding limitations are commonly raised [11-15]. This often leads to the need to build in overcorrection and go through multiple rounds of aligners, which increases the overall treatment time.

Digital model superimpositions have long been used to quantify the success level of aligners producing the desired outcomes [16-23]. Results have been reported as a percent accuracy by superimposing pretreatment and posttreatment digital models to quantify achieved values and comparing these values to planned values obtained by superimposing pretreatment and predicted models. A 2021 study found that Invisalign® (Align Technology®, Santa Clara, CA), the leading aligner company, had an overall mean tooth movement accuracy of 50%, and concluded that aligner weaknesses remained the same throughout the years. Controlling rotations, primarily of canines, premolars, and molars, as well as intrusion and extrusion in varying parameters, were difficult to achieve [16-18]. These limitations restrict clear aligner therapy use because the prospectively created plans cannot be modified by the clinician, which allows very little influence on ongoing clear aligner treatment rounds. This can lead to switching to full or partial fixed appliance mid-treatment to assist in moving lagging teeth.

The ongoing development of digital model technology indeed created a new paradigm in individualized orthodontic treatment, similar to how the straight wire appliance previously revolutionized orthodontic care with a set of pre-programmed values built-in to bracket slots. Digital model technology presently allows for virtual design of a patient's final occlusion, whereby bracket slots are customized to accommodate a straight wire that moves each tooth to its virtually planned final position.

The tunnel attachment system utilizes advances in CAD/CAM technology to incorporate fixed appliance concepts into clear aligner therapy for the purpose of overcoming their commonly faced limitations [24]. Tunnel attachments consist of tubes integrated into virtually planned resin attachments. These small attachments are indirectly bonded on a selected segment of teeth in the same manner traditional aligner attachments are bonded. The tubes allow the accommodation of a superelastic straight wire, providing the advantage of springback and shape memory characteristics to move each tooth towards achieving the same computer simulated goal for the clear aligners (Figure 1) [25, 26].

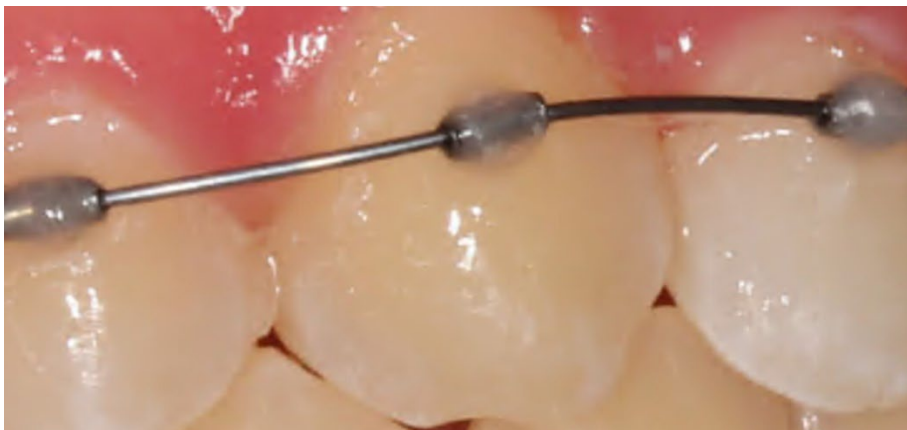

Figure 1. Tunnel attachments bonded to support canine tip.

TUNNEL ATTACHMENTS

Incorporating wire threaded custom tunnel attachments into clear aligner therapy is a novel approach developed to address commonly faced shortcomings of currently available orthodontic systems. The concept utilizes a light arch wire engaged through virtually oriented tunnel attachments to achieve better control of three-dimensional (3D) tooth movements not achievable by clear aligners alone. This hybrid system is anticipated to take advantage of the benefits and overcome many of the limitations of traditional fixed buccal/lingual appliances and clear aligner therapy.

This chapter formally describes this novel hybrid method using custom tunnel attachment paired with clear aligner therapy. The custom tunnel attachment system paired with clear aligners includes the only computer-designed and chairside-fabricated attachments that use wires for more precise 3D orthodontic tooth movements. The utilization of auxiliary superelastic wire facilitates more complicated movements to be achieved while delivering light continuous forces considered optimal for orthodontic tooth movement [27]. We aim to describe a method that pairs computer-designed, chairside-fabricated tunnel attachments with clear aligner therapy for the purpose of improving their achieved outcomes.

Successful treatment of many malocclusions is possible with clear aligner therapy when a sound knowledge of tooth movement biomechanics and aligner properties is combined with careful treatment planning and clinical execution [11-14]. However, clear aligner therapy is yet to be considered a viable alternative to fixed appliances due to commonly faced limitations in achieving predicted outcomes [16-18]. To our knowledge, no previous study has formally described a hybrid system aimed to systematically address clear aligner tooth movement limitations, while simultaneously taking the advantage of their benefits. Tunnel attachments can be paired with any aligners. A virtual occlusal set-up is completed on the aligner software where cutouts are requested on the buccal or lingual surfaces of teeth to provide clearance for the segment of teeth receiving tunnel attachments before approving aligner manufacturing by the company, or in-house aligners.

Position

Tunnel attachments can be bonded facially or lingually. This is based on esthetic demand, function, and clinician's preference.

Number

One or more teeth on either side of the non-tracking tooth or teeth can be included in a segment to support the desired movements. Based on clinical judgment, additional tunnel attachments can be bonded on adjacent teeth to assist with a particularly difficult tooth movement (Figure 1).

Orientation

Tunnel attachment positions are determined virtually when using the initial and predicted stereolithography (STL) models. Their orientation follows a nickel-titanium archwire 3D replica at the final occlusion (Figure 1). Each attachment is transferred to the initial pretreatment model with this orientation preserved relative to each tooth. Since the tubes are standardized, the conventional bracket offset (1st order bends) and base inclination (3rd order bends) are compensated for by the thickness of resin used when clinically bonding the tunnel attachments (Figure 1).

Dimensions

Initial testing of the concept utilized archwire stops from RMO® (Denver, CO). These 2 mm long tubes have a round cross-section, outside diameter of 0.032", and inside diameter of 0.019", which allowed the use of round wires up to 0.018" in diameter (Figure 1 and 2). A 3D prototype for a tunnel attachment was later created with a square cross-section and the following dimensions: external cross-section of 0.03" x 0.03", internal cross-section of 0.019" x 0.019", 2 mm length (Figure 3). The final prototype was custom ordered from Zhejiang Yahong Medical Apparatus Co., Ltd (China) to be manufactured in stainless-steel

with smoother outer corners and rough external surface finish to improve bonding to resin material (Figure 4). These square cross-section tubes can receive round or square wires up to 0.018" x 018".



Figure 2. Round cross-section archwire stops

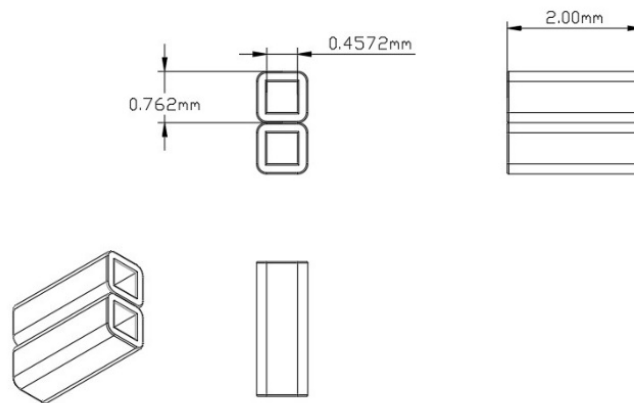


Figure 3. Tunnel attachment dimensions in millimeters



Figure 4. Square cross-section tunnel attachments with rougher outer surface for improved bond strength.

Archwires

Replicas of buccal and lingual nickel-titanium archwires of varied sizes and arch forms were modeled in 3D using Blender® (Blender Foundation, Netherlands). These 3D replicas stand for commonly used archwires to be selected on a case-by-case basis decided by arch size, form, and buccal or lingual placement.

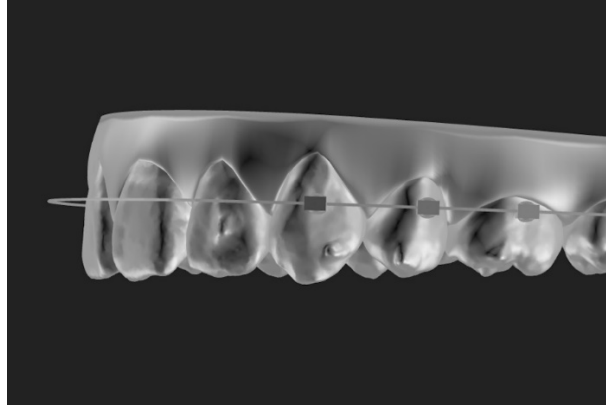


Figure 5. Final stage: tunnel attachments oriented to follow a passive wire.

Virtual planning

Initial testing of the use of tunnel attachments was performed by importing both initial and clear aligner therapy final predicted STL files into Blender®, followed by segmentation of the initial model. A manual superimposition process was done for each tooth at the initial stage onto corresponding positions at the predicted stage. The most suitable archwire was manually selected and adapted to the teeth. Tubes were individually added and oriented so the wire would go through them passively and surrounded with what represented composite resin (Figure 5). Teeth were moved back to their position at the initial stage while tube positions were maintained relative to their surfaces, and that STL file was exported for 3D printing and transfer (Figure 6).

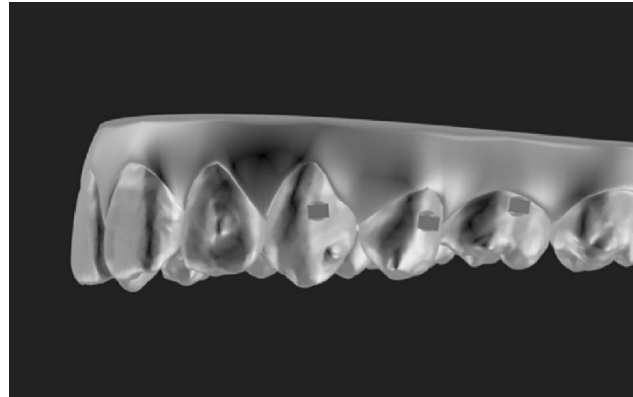


Figure 6. Initial stage: tunnel attachments maintain their final stage orientation to each corresponding tooth.

A secure software, Titan®, was specifically developed to automatically segment and recognize individual teeth at both initial and predicted stages. The user only needs to select the buccal or lingual surfaces of the segment of teeth to receive tunnel attachments and that prompts the software to select the best fitting archwire. The initial model containing tunnel attachments is then exported to be 3D printed for fabrication of an indirect bonding template (Figure 7)

If the tunnels are planned for use with Invisalign® (Align Technology®, Santa Clara, CA) aligners, button cutouts or gingival margin modifications need to be used to clear the tunnel attachments. Alternatively, a tunnel attachment interface has been incorporated into the clear aligner planning platform of Titan®. Dental Design® which has licensed the patent and allows the tunnels to be integrated

with the clear aligners appropriated blocking out for the tunnels and the wire while fully covering the tooth for added patient comfort and better control of tooth movement (Figure 8).

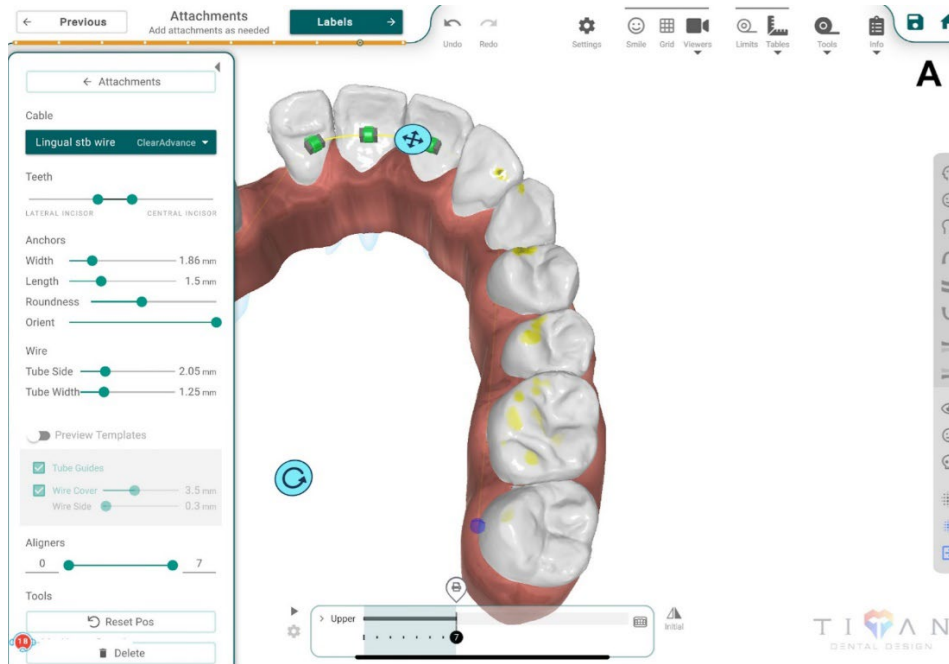


Figure 7. Titan software: best-fitting wire is automatically selected upon choosing a segment of teeth to receive tunnel attachments.

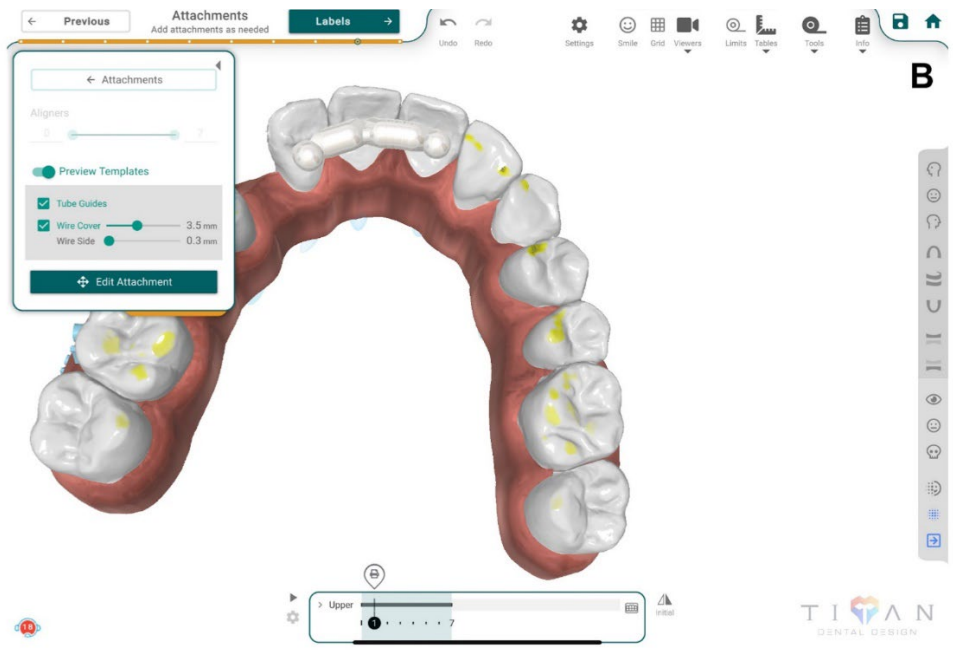

Figure 8. Titan software allows exporting models which block-out the selected tunnel attachment segment for more comfortable and effective aligners to be fabricated.

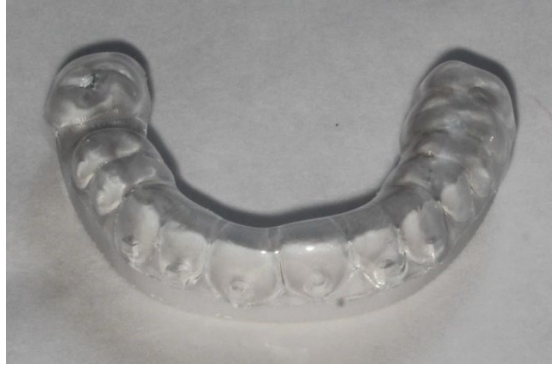

Figure 9. Vacuum-formed indirect bonding template cut at gingival margin level for transfer of tunnel attachments.




Figure 10. Tunnel attachment tubes embedded into their predetermined positions to be covered by composite prior to bonding onto teeth.

Indirect bonding

The STL model can be 3D printed and used for fabrication of a vacuum-formed indirect bonding template. A 3 mm thick thermoplastic material, such as Bioplast® (Scheu Dental, Germany), is vacuum-formed over the printed model using the positive pressure machine and trimmed to the gingival level to create the indirect bonding template (Figure 9). Tubes are then embedded into their predetermined positions in the template (Figure 10) and covered with a light cure adhesive paste composite. After preparing teeth surfaces for micromechanical retention of the attachment, the template is placed into the patient's mouth and light cured in a manner similar to that of conventional attachments. Once the bonding template is removed, leaving tunnel attachments in place, they can be further coated with flowable composite for better comfort and esthetics (Figure 11).

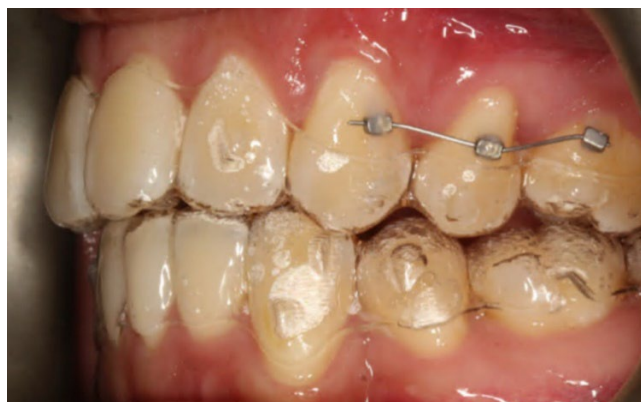

Figure 11. Initial wire threaded through tunnel attachments and aligner with cutout worn.

Wire protocol

An initial small diameter nickel-titanium wire, 0.012" or 0.014", can be threaded through tunnel attachments, which undergoes elastic deformation in response to applied stress. This results in activation of the distorted wire to move the teeth to the same planned position working to achieve the same goal as the aligners (Figure 11). This is gradually replaced throughout appointments by a heavier nickel-titanium wire, such as 0.016", to achieve the desired movements. Square wires such as 0.016" x 0.016" and up to 0.018" x 0.018" are used when torque control is needed.

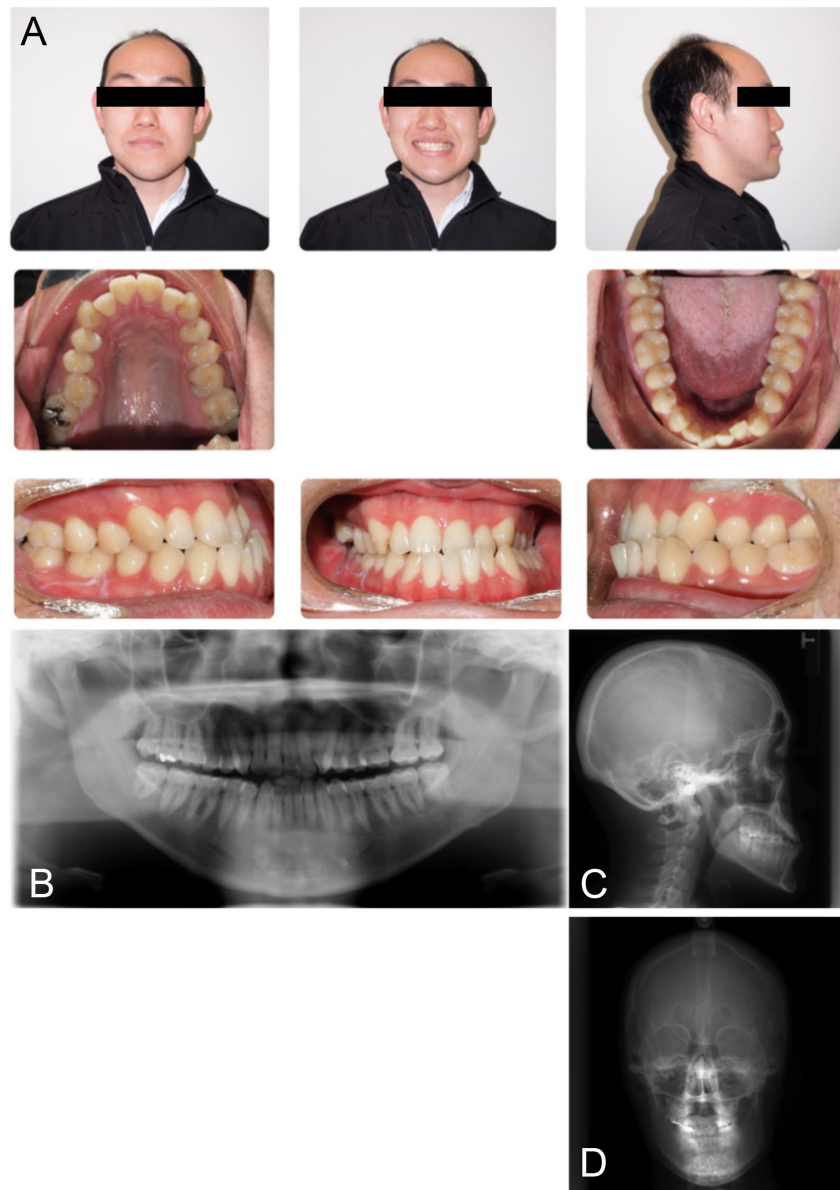
CLINICAL APPLICATION

Figure 12. Initial orthodontic records. A) Facial and intraoral photographs, B) initial panoramic radiograph, C) lateral cephalogram, and D) PA cephalogram.

A 31-year-old Asian male sought treatment for his uneven smile and dental crowding. He presented with a skeletal class III related to a combination of a retrognathic maxilla and a prognathic mandible, as well as maxillary cant and yaw deformities, and mandibular asymmetry. He had upper and lower crowding and anterior as well as left posterior crossbite along with non-coincident midlines (Figure 12). This patient elected to undergo clear aligner therapy despite understanding that a significant amount of tipping would likely require fixed appliances. Presurgical orthodontic treatment was initially planned and carried out using Invisalign® (Figure 13).

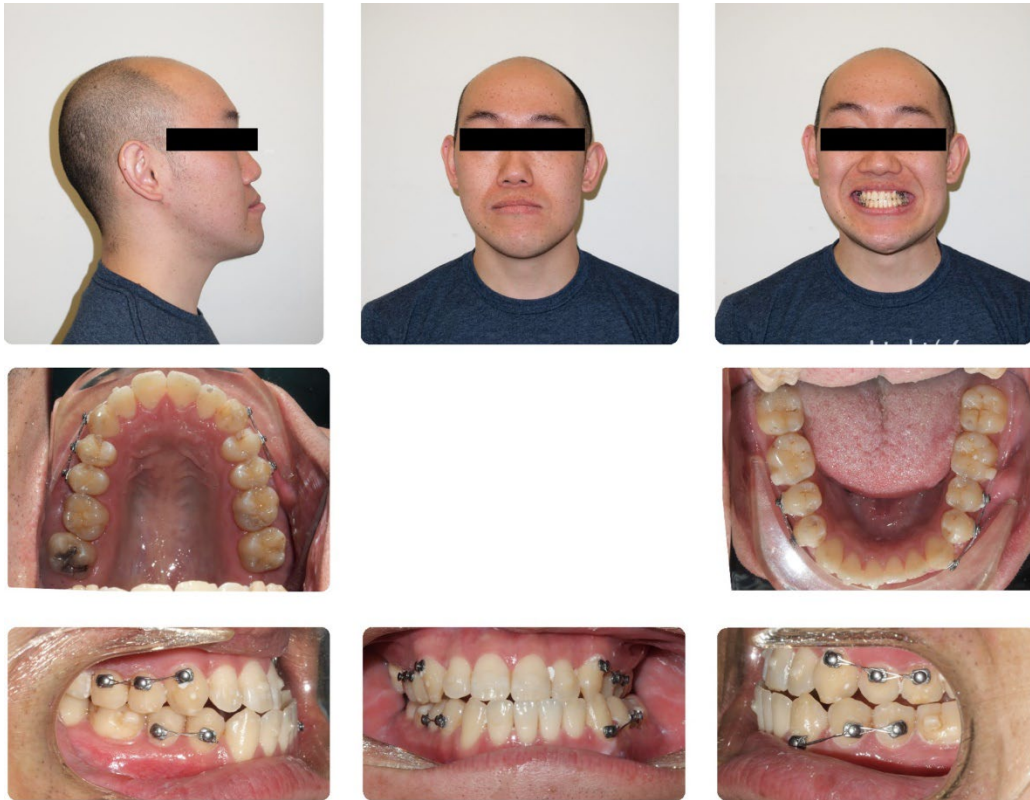

Figure 13. Presurgical records.

The patient underwent maxillary advancement, clockwise yaw, and cant rotation, followed by rotation of proximal segments of the mandible. Despite a few rounds of refinement post-surgically, his upper canines were still mesially tipped and did not track as planned (Figure 14) without using some kind of a fixed appliance. A new intraoral scan was obtained to initiate a refinement round and the patient was presented with the tunnel attachments approach and agreed due to their small size and insignificant impact on esthetics.

After a new Clincheck® plan was finalized, cutouts on first premolars and canines, as well as adjustment of aligner margin on the labial surfaces of the upper incisors and first premolars, were requested to allow placement of tunnel attachments (Figure 15). Pretreatment and predicted STL files were exported then imported into Titan software, which segmented and matched teeth in both stages upon identifying corresponding teeth in both arches. After each tooth in the segment was selected, the software determined the best fitting archwire and aligned the attachments to fit a straight wire at the predicted stages. The orientation of tunnel attachments remained the same relative to each tooth at the pretreatment stage, and the STL file was exported and 3D printed.

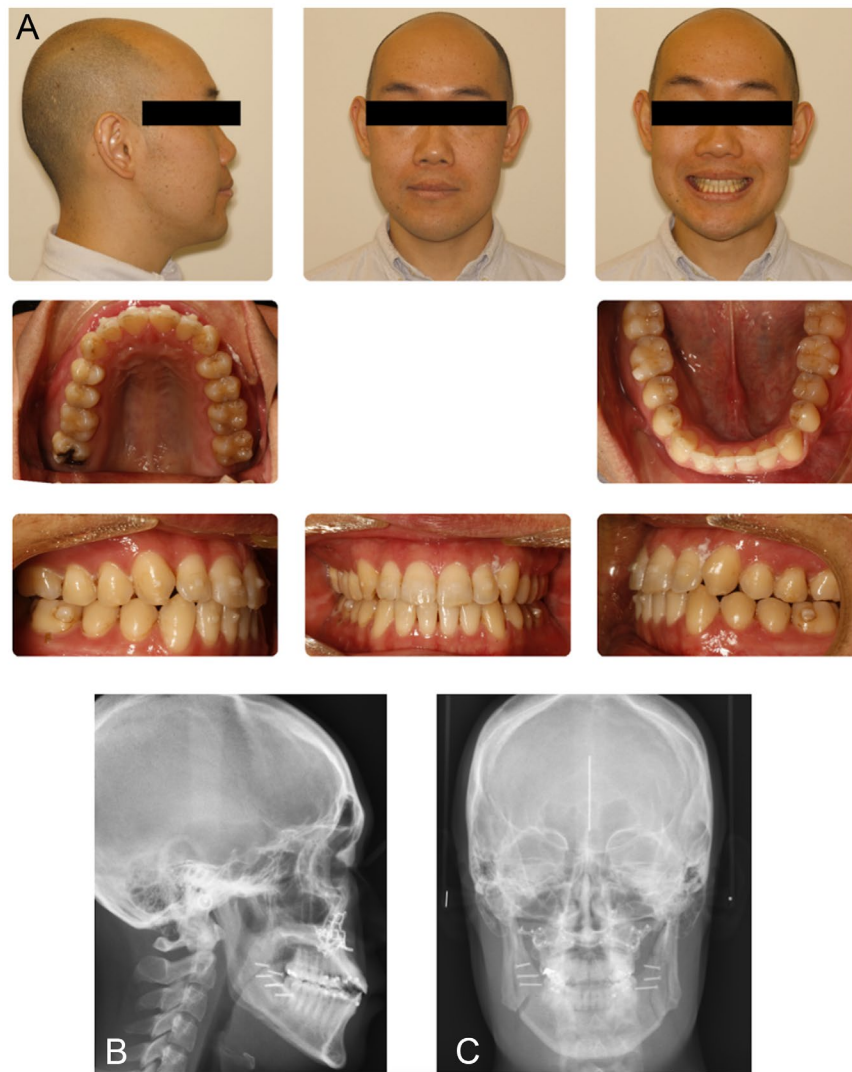

Figure 14. A) Postsurgical facial and intraoral photographs, B) postsurgical lateral cephalogram, and C) PA cephalogram.

A 3 mm mouthguard sheet was vacuum-formed over the printed model and trimmed to the gingival margin to create the indirect bonding template. Three tubes were inserted into their predetermined positions in the template and coated with GoTo light cure adhesive paste composite (Reliance® Orthodontic Products, Inc.). Teeth were prepared with 3M™ Transbond™ Plus Self Etching Primer. The indirect bonding template was placed into the patient's mouth and light cured. After the template was removed, composite was added over the tubes for comfort. Any remaining Invisalign attachments were bonded, and excess composite was cleaned, with close attention to the gingival margins.

An 0.014" nickel-titanium archwire segment was threaded through the tubes and the patient was instructed to wear the first aligner (Figure 16). He was evaluated throughout visits to step up to a heavier

wire. A 0.016" nickel-titanium wire was placed 6 weeks after the initial visit. At the completion of the aligner round, canine tipping was achieved (Figure 17).

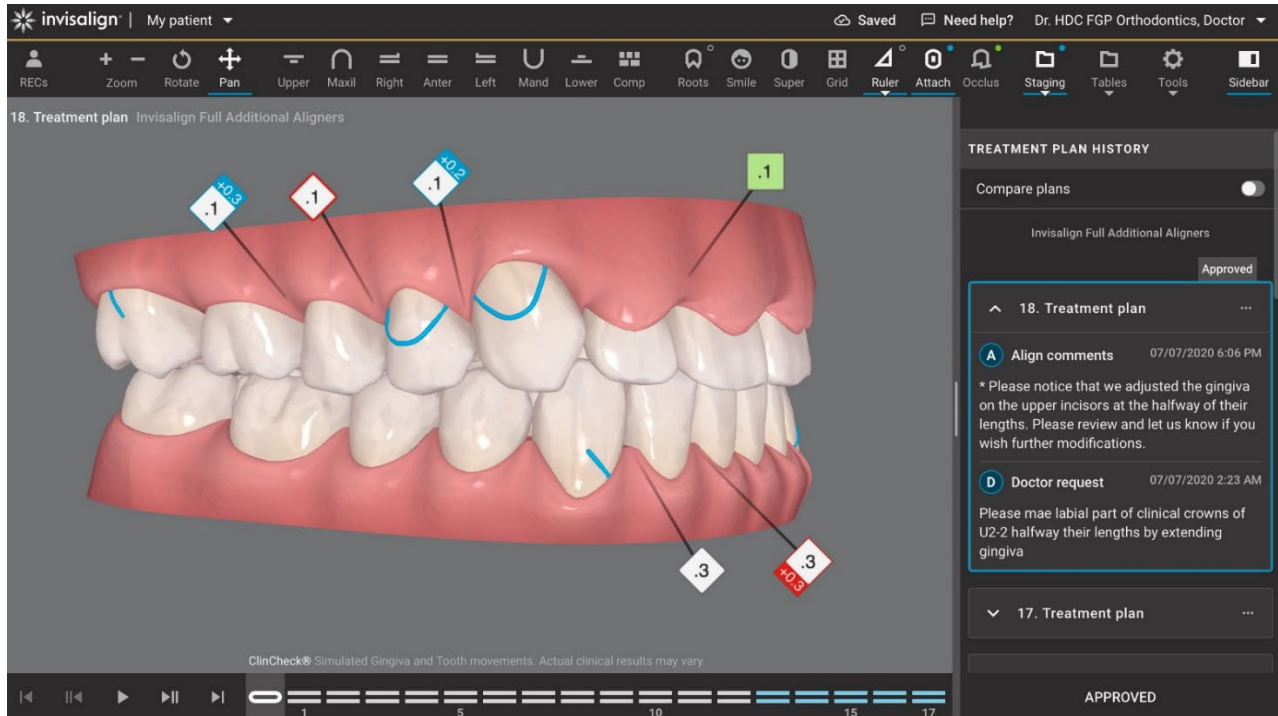


Figure 15. Modifying levels of aligner coverage on Clincheck® requires requesting a change in the gingival margin level or addition of cutouts to teeth planned to receive tunnel attachments.

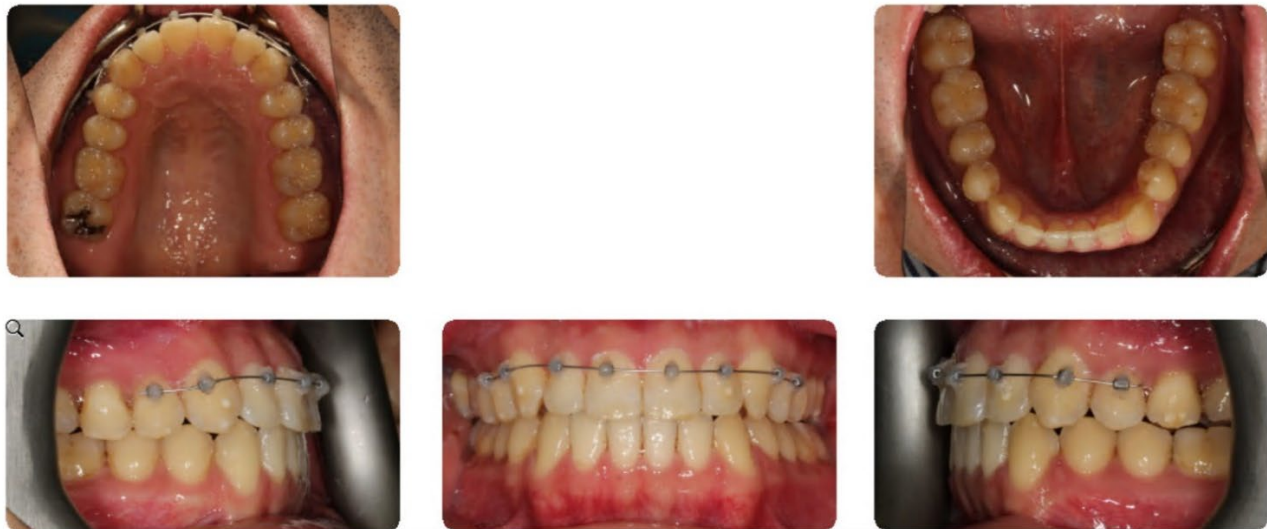

Figure 16. Tunnel attachments bonded and wire threaded to tip canines.

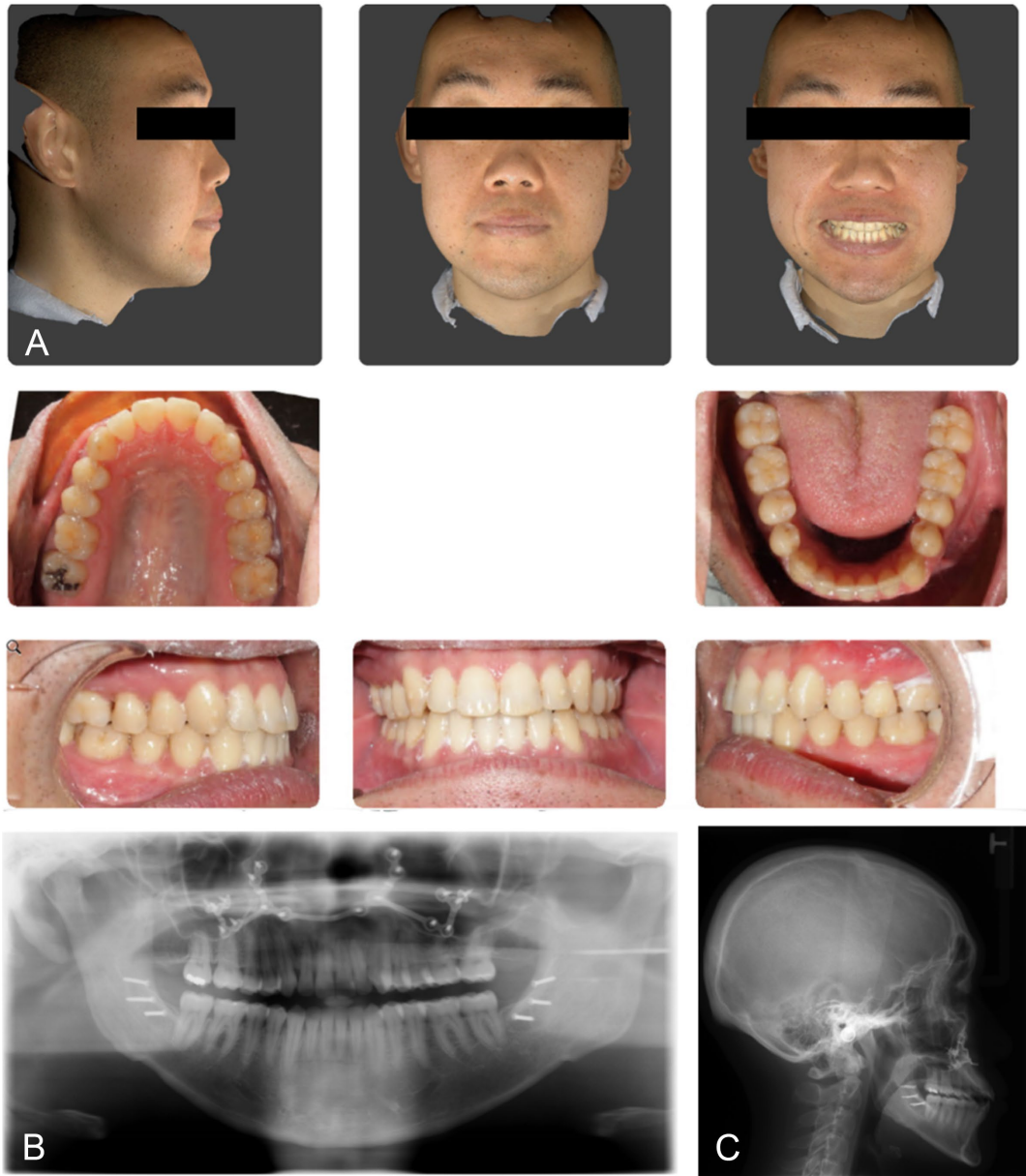

Figure 17. Final records upon completion of tunnel attachments treatment. A) Facial and intraoral photographs, B) final panoramic radiograph, and C) final lateral cephalogram.

BENEFITS AND INDICATIONS

Most orthodontists do not recommend using clear aligner therapy alone for patients requiring extractions, surgery, or difficult tooth movements [28]. Movements such as extrusion, correction of severe rotations, uprighting, and closure of extraction spaces are known to be challenging to accomplish with clear aligner therapy [29]. Clinicians have attempted to improve tracking over the years, which is the movement of teeth in accordance with their respective goals of each aligner stage. One of the most common approaches is to build in overcorrection stages to account for movements that generally do not track well. Multiple rounds of additional aligners are necessary to approach the desired outcome, which adds to the overall treatment time. Tunnel attachments are designed to allow clinicians to take the

advantage of using round and square nickel-titanium wires in conjunction with clear aligners. The larger and stronger the wire, the better control of described movements can be achieved. This allows translational movements and root torque correction. Tunnel attachments can be placed on the buccal of the teeth for easier access or the lingual surfaces to allow optimal esthetics without being as cumbersome as lingual orthodontics. Additionally, the superelastic feature of the nickel-titanium archwires allows delivery of more continuous forces than clear aligner therapy alone.

Supplementing conventional clear aligner therapy with tunnel attachments can provide a superior alternative to clear aligner therapy for various reasons. Patients are often willing to choose a more esthetic treatment option even if it costs more [14]. Although lingual orthodontics present an attractive treatment option for patients who are not candidates for clear aligner therapy and desire an esthetic treatment option, there are several limitations including reduced interproximal distance, challenges with torque control, and patient discomfort [30].

This described novel approach is anticipated to achieve a tooth position that is closer to the virtually planned position, shorter overall treatment time by reducing the need for refinement rounds and aligner stages, and potentially shorter duration of the recommended aligner wear during orthodontic treatment. This technique can be successfully used in conjunction with any in-house clear aligner therapy. This method has been assessed and, in our experience, provides better results than aligners alone. It has the potential to treat more complex cases involving severe rotations, crowding, spacing, and extraction by allowing the use of heavier square wires to achieve better control of movement parameters, including root torque and translational movements.

CONCLUSIONS

A hybrid method using custom tunnel attachments in conjunction with clear aligner therapy was developed and described. Tunnel attachments can be successfully incorporated into clear aligner therapy to improve achieved results. This novel method can be used to overcome limitations of clear aligner therapy in addressing movements difficult for clear aligners alone.

ACKNOWLEDGEMENTS

This study was reviewed and approved by the Institutional Review Board for the Longwood Campus at Harvard University (IRB#18-0615). Informed consent has been obtained from all patients.

REFERENCES

1. Bouchez R. Clinical Success in Invisalign Orthodontic Treatment. Paris; Chicago: Quintessence Publishing; 2011.
2. Kuo E, Miller RJ. Automated custom-manufacturing technology in orthodontics. *Am J Orthod Dentofacial Orthop* 2003;123(5):578-581.
3. Al Mortadi N, Jones Q, Eggbeer D, Lewis J, Williams RJ. Fabrication of a resin appliance with alloy components using digital technology without an analog impression. *Am J Orthod Dentofacial Orthop* 2015;148(5):862-867.

4. Rossini G, Parrini S, Castroflorio T, Deregibus A, Debernardi CL. Diagnostic accuracy and measurement sensitivity of digital models for orthodontic purposes: A systematic review. *Am J Orthod Dentofacial Orthop* 2016;149(2):161-170.
5. Fleming PS, Marinho V, Johal A. Orthodontic measurements on digital study models compared with plaster models: a systematic review. *Orthod Craniofac Res* 2011;14(1):1-16.
6. Quimby ML, Vig KW, Rashid RG, Firestone AR. The accuracy and reliability of measurements made on computer-based digital models. *Angle Orthod* 2004;74(3):298-303.
7. Zilberman O, Huggare JA, Parikakis KA. Evaluation of the validity of tooth size and arch width measurements using conventional and three-dimensional virtual orthodontic models. *Angle Orthod* 2003;73(3):301-306.
8. Vlaskalic V, Boyd R. Orthodontic treatment of a mildly crowded malocclusion using the Invisalign System. *Aust Orthod J* 2001;17(1):41-46.
9. McKenna S. Invisalign: technology or mythology? *J Mass Dent Soc* 2001;50(2):8-9.
10. Joffe L. Invisalign: early experiences. *J Orthod* 2003;30(4):348-352.
11. McNamara JA, Brudon WL, Kokich VG. *Orthodontics and Dentofacial Orthopedics*. Ann Arbor, MI: Needham Press; 2001.
12. Vlaskalic V, Boyd RL. Clinical evolution of the Invisalign appliance. *J Calif Dent Assoc* 2002; 30(10):769-776.
13. Prescott TM, Miller R. Interview with Align Technology executives. Interview by David L Turpin. *Am J Orthod Dentofacial Orthop* 2002;122(2):19A-20A.
14. Rosvall MD, Fields HW, Ziuchkovski J, Rosenstiel SF, Johnston WM. Attractiveness, acceptability, and value of orthodontic appliances. *Am J Orthod Dentofacial Orthop* 2009;135(3):276.e1-277.
15. Schupp W, Haubrich J. *Aligner Orthodontics: Diagnostics, Biomechanics, Planning, and Treatment*. Chicago, IL: Quintessence Publishing; 2016.
16. Kravitz ND, Kusnoto B, Agran B, Viana G. Influence of attachments and interproximal reduction on the accuracy of canine rotation with Invisalign. A prospective clinical study. *Angle Orthod* 2008; 78(4):682-687.
17. Kravitz ND, Kusnoto B, BeGole E, Obrez A, Agran B. How well does Invisalign work? A prospective clinical study evaluating the efficacy of tooth movement with Invisalign. *Am J Orthod Dentofacial Orthop* 2009;135(1):27-35.
18. Haouili N, Kravitz ND, Vaid NR, Ferguson DJ, Makki L. Has Invisalign improved? A prospective follow-up study on the efficacy of tooth movement with Invisalign. *Am J Orthod and Dentofacial Orthop* 2020;158(3):420-425.
19. Grünheid T, Loh C, Larson BE. How accurate is Invisalign in nonextraction cases? Are predicted tooth positions achieved? *Angle Orthod* 2017;87(6):809-815.
20. Krieger E, Seiferth J, Marinello I, Jung BA, Wriedt S, Jacobs C, Wehrbein H. Invisalign® treatment in the anterior region: were the predicted tooth movements achieved? *J Orofac Orthop* 2012; 73(5):365-376.
21. Charalampakis O, Iliadi A, Ueno H, Oliver DR, Kim KB. Accuracy of clear aligners: A retrospective study of patients who needed refinement. *Am J Orthod Dentofacial Orthop* 2018;154(1):47-54.
22. Chisari JR, McGorray SP, Nair M, Wheeler TT. Variables affecting orthodontic tooth movement with clear aligners. *Am J Orthod Dentofacial Orthop* 2014;145(4 Suppl):S82-S91.
23. Simon M, Keilig L, Schwarze J, Jung BA, Bourauel C. Treatment outcome and efficacy of an aligner technique – regarding incisor torque, premolar derotation and molar distalization. *BMC Oral Health* 2014;14:68.
24. Masoud MI. Custom-designed chair-side fabricated tunnel attachments for moving teeth. (US patent Number US20220323181). United States of America; 2022.

25. Proffit WR, Fields HW, Larson BE, Sarver DM. Contemporary Orthodontics, 6th ed. Philadelphia, PA: Elsevier; 2018.
26. Nanda R. Biomechanics in clinical orthodontics. Philadelphia, PA: WB Saunders Company; 1997.
27. Oppenheim A. Biologic orthodontic therapy and reality. *The Angle Orthodontist* 1936; 6(2):69-116.
28. Ko HC, Liu W, Hou D, Torkan S, Spiekerman C, Huang GJ. Recommendations for clear aligner therapy using digital or plaster study casts. *Prog Orthod* 2018;19(1):22.
29. Tamer İ, Öztaş E, Marşan G. Orthodontic Treatment with clear aligners and the scientific reality behind their marketing: a literature review. *Turk J Orthod* 2019;32(4):241-246.
30. Riolo CS, Finkleman SA, Kaltschmidt C. Lingual orthodontics: understanding the issues is the key to success with lingual mechanics. *Seminars in Orthodontics* 2018;24(3):271-285.

3D PRINTING 2.0: THE NEXT GENERATION OF 3D PRINTING IN ORTHODONTICS

Christian G. Groth, Aron Aliaga Del Castillo

ABSTRACT

Three-dimensional (3D) printing has become a topic of great interest to orthodontists that decided to embrace and establish a 3D workflow in their offices. New advancements in material properties, 3D printers, and printing ecosystems have been developed quickly during the last few years, as usually happens with new technologies. The use of 3D printing has evolved, and more options of appliances and adjuncts are currently available for use in the dental office. This chapter offers an overview on some updates on the uses of 3D printing in orthodontics.

KEY WORDS: 3D printing, Dental technology, Orthodontic appliance design.

INTRODUCTION

Three-dimensional (3D) printing was first defined approximately 40 years ago. In 1983, an engineer named Chuck Hull unknowingly changed the world forever when he had the idea to build objects in sequential two-dimensional (2D) layers to form a 3D object. Hull was putting ultraviolet (UV) cured layers on tabletops when the idea struck. This process, patented in 1986, was termed additive manufacturing and later called 3D printing [1]. For more than a decade, 3D printing was mostly utilized in research and development, for rapid prototyping of parts for testing purposes. It was not until 1997, when Zia Chishti decided to start a company called Align Technology, that 3D printing was used to create custom orthodontic appliances.

The concept of clear aligners was not new to the world of orthodontics [2-4], but no one had yet digitized the process or mass produced the appliances. Invisalign, the product produced by Align Technology (Santa Clara, CA), was the first fully customized orthodontic appliance [5, 6]. While by today's standards, the system was rudimentary, at the turn of the century, the feat of being able to digitize the dentition, move teeth on a computer, and then produce models to be used for thermoforming was an incredible feat. Software had to be written, manufacturing systems created, and a whole new era of the US Food and Drug Administration (FDA) oversight was born. These two innovations have birthed countless ideas that would have been impossible without the technology that Hull invented. Thankfully, original patents are expired, which has allowed for the market to innovate and expand.

3D printing is now something that almost every orthodontic practice utilizes in some form – directly or indirectly. In this chapter, we review some of the most up-to-date uses of 3D printing as it pertains to orthodontics.

CUSTOM METAL APPLIANCES

Soon after Hull patented stereolithography (SLA), Drs. Carl Deckard and Joe Beaman patented a process termed selective laser sintering (SLS). This process involves the use of high powered lasers to fuse small particles of metal, plastic, glass, or ceramic. SLS allows the fabrication of both prototype

and end use parts and appliances out of a variety of materials with a wide range of material properties [7]. Unlike vat polymerization printing, SLS uses high powered lasers in a controlled environment, which has resulted in the technology being too expensive for practical use in the dental office.

In orthodontics, the first documented use of SLS was made by Graf for the fabrication of lab appliances [8]. While the technology to fabricate the appliances has been established, the software necessary to design the appliances has taken some time to develop. Benefits of using 3D printed appliances include improved appliance fit, fewer overall visits, no separators for bands, and fully customized appliances [8-11]. These appliances are not without downsides, however [11]. The most common metal used in the printing process is chrome cobalt, a long-used metal for restorative frameworks. Unlike stainless steel, chrome cobalt is a brittle metal and thus cannot be bent in the event that the appliance must be adjusted. Further, some appliances require adjustment or activation before or after having been installed, such as an active transpalatal arch used for molar rotation [12].

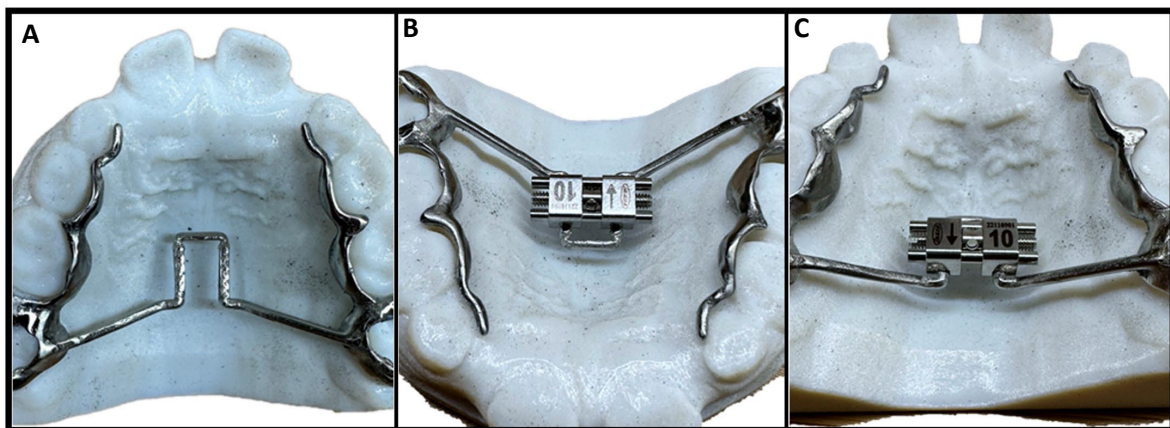


Figure 1. 3D Printed Metallic Appliances. A) 3D metal printed expander structure (bands and arms) with the analog. B) and C) hyrax attached to the analog by laser welding.

Labs have been somewhat slow to adopt SLS printing in orthodontics, mostly because of the cost of the printers. However, all of the large labs and many smaller labs are currently using SLS technology to produce appliances, with some removing traditional analog workflows. This means that all the structures can be printed, including an analog 3D printing structure, to allow the active part of the appliance to be soldered (e.g., an expander screw) (Figure 1). For the labs, SLS technology workflow presents challenges and advantages. The design of the appliance is digital, which requires hardware and software considerations. More importantly, the team members necessary for design are different from those necessary for analog appliance fabrication. Most labs that have adopted SLS technology now have a digital design team working parallel to the fabrication team. This adjustment has resulted in larger lab teams, more equipment, and larger lab spaces, all of which have caused an increase in price of the SLS appliances [11, 13].

The SLS printing process also requires site accommodations not previously needed. The powdered metal is so fine that respirators must be worn, and ventilation is necessary to ensure that no metal is inhaled. The printers are large and sometimes require a special power supply or water cooling to keep the lasers from overheating. While there are less expensive options that utilize standard power sources, the build platforms are rather small, which may cause issues for all but low volume operations.

DIRECT PRINTED FIXED APPLIANCES & AUXILIARIES

3D printing, once limited to the fabrication of models used for various thermoformed appliances, has expanded in use. We are now able to directly print our appliances. One of the first companies to bring a direct printed appliance to the market was Lightforce (LightForce Orthodontics, Burlington, MA) [14]. Lightforce utilizes advanced software to design fixed appliances and 3D printing to fabricate fully customized ceramic brackets [15]. Utilizing fully customized appliances helps to decrease treatment times and the number of overall visits by limiting round tripping and decreasing wire bends and bracket repositions. While this idea is still being researched, there is evidence that these claims have validity [15].



Figure 2. 3D Printed Customized Appliances. Customized indirect bonding system Monolithic – Braces on Demand (Braces on Demand Inc., Hicksville, NY). Brackets and indirect bonding trays are printed at the same time.

Another option for direct printed fixed appliances is Braces on Demand (Braces on Demand Inc., Hicksville, NY), a company which allows orthodontists to print braces and custom appliances in their office [16]. Unlike Lightforce, which uses high powered commercial 3D printers to fabricate their braces, Braces on Demand works seamlessly with several in-office 3D printing systems [13]. Braces on Demand utilizes FDA cleared materials in order to ensure patient safety. The most advanced option for Braces on Demand, Monolith, is an innovative, fully customized, indirect bonding system that allows doctors to print the brackets and indirect bonding trays at the same time (Figure 2). Braces on Demand also has a catalog of auxiliaries that can be printed as needed, including buttons, hooks, and eyelets [16]. Utilizing 3D printing, clinicians are able to fabricate geometries that are impossible to make with traditional manufacturing. Braces on Demand's twisted pivot and bracket system is a system of self-ligation brackets with no moving parts. Instead, it relies on two bracket slots set on an angle to each other (Figure 3) [13, 16].



Figure 3. 3D Printed Customized Appliances. Twisted Pivots – Braces on Demand (Braces on Demand Inc., Hicksville, NY). Self-ligation brackets system with no moving parts. Two bracket slots on an angle to each other.

DIRECT PRINTED RESTORATIONS

Dental restorations may be needed during and/or after the orthodontic treatment of some patients. Orthodontists are all dentists and thus have all of the pre-requisites necessary to deliver non-invasive restorations for patients. A great and emerging use of 3D printing is the direct fabrication of resin bonded bridges, commonly referred to as Maryland bridges [17-20]. As orthodontists, we are ideally equipped to deliver this type of restoration as a temporary solution during treatment or as a long-term temporary solution after treatment until a patient can receive a definitive bridge or implant restoration. The procedures, both digital and clinical, are quite simple. Digital design is best accomplished by a design service. The design lab is able to confirm clearance and design the ideal restoration. A stereolithography (STL) file is returned to the doctor for approval and download. The 3D printing of a restoration is most often accomplished with printers that use digital light processing (DLP) or SLA technologies [10, 21]. The restorations require supports for printing and FDA approved material for intraoral use. There are a variety of materials and colors available for this application, including ceramic reinforced resins. Post processing of the restoration follows similar guidelines to all other prints, including washing in isopropyl alcohol and time in a curing unit for specific periods. It is important to reinforce the concept that materials intended for intraoral use should not be washed in the same alcohol as materials used for models or non-intraoral uses.

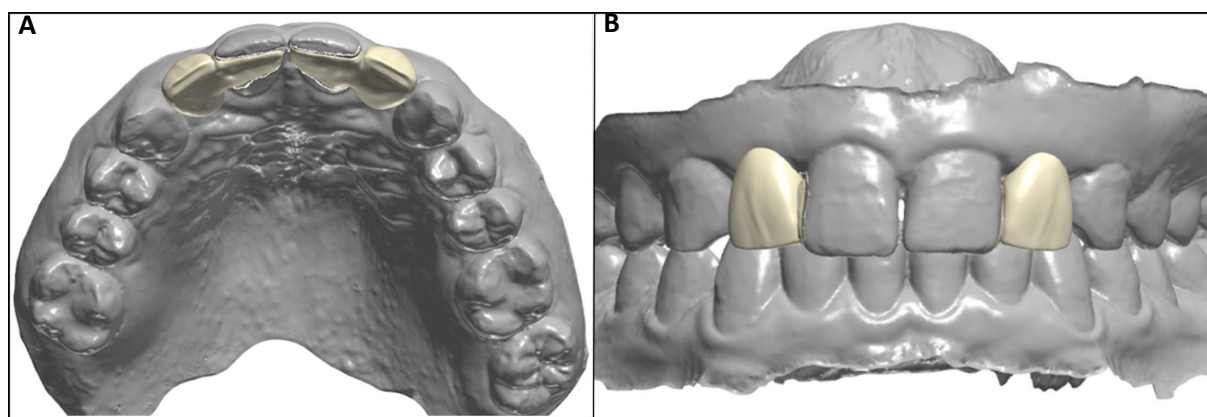


Figure 4. Direct Printed Restorations. Digital design of Maryland bridge in a case with upper lateral incisors agenesis. A) frontal view, B) occlusal view.

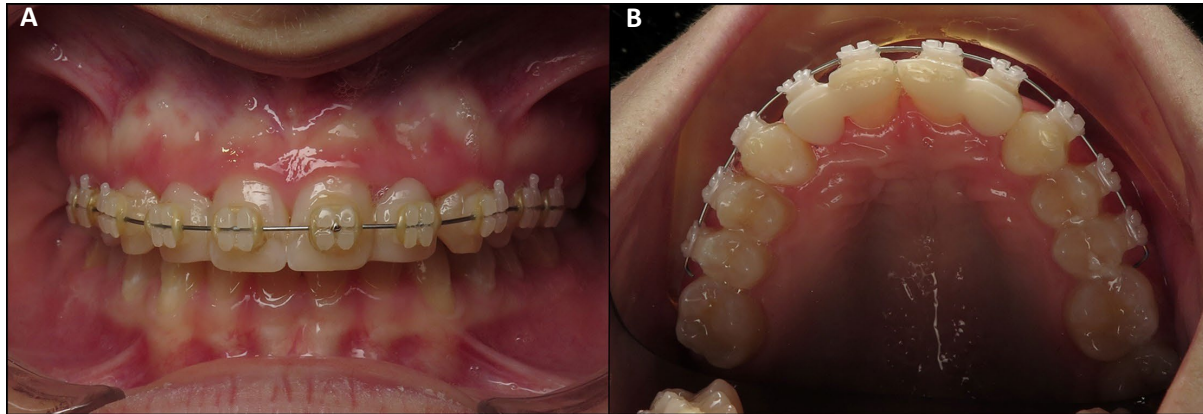


Figure 5. Direct Printed Restorations. Maryland bridge bonded to the upper central incisors in a case with upper lateral incisors agenesis. A) lateral view, B) frontal view.

The clinical procedure is straightforward and takes very little time. Since 3D printed resins are bondable, any orthodontic resin can be used. Thus, a simple flowable resin might be used to bond a temporary restoration. The clinical steps include etching with 37% phosphoric acid, application of bonding agent, application of flowable resin to the wings of restoration, and delivery of the restoration. Since these restorations are directly designed using a digital model (Figures 4 and 5), the fit is such that there is a positive seating and only one way they will fit. A quick cleanup of excess cement and light cure is all that remains of the clinical procedure. In the case presented, the patient was missing both upper lateral incisors and required more space at the apex for successful implant placement. Cantilevered Maryland bridges from the upper central incisors were designed and delivered (Figures 4 and 5). Brackets were then bonded to the Maryland bridges for esthetic purposes only. The major benefit of this type of restoration is that it can be designed, printed, and delivered rather quickly. Since this is not a definitive restoration, the color and contours do not need to match perfectly. There is no risk to damaging the opposing dentition because they are resin instead of ceramic. The cost to print these restorations is quite low compared to having a traditional Maryland bridge fabricated. Some data suggest that 3D printed restorations may have higher fracture resistance when compared to their ceramic counterparts [19, 20, 22]. Occlusion must be amenable to such a restoration – deep bites often make a Maryland bridge impossible due to lack of occlusal clearance.

DIRECT PRINTED BITE SPLINTS

Occlusal splints can be used for diagnosis and/or treatment. In the last case, this can be done after establishing an interdisciplinary plan. Orthodontists have generally not been involved in the fabrication of occlusal guards or bite splints. This is mostly due to the fact that splints are generally hard appliances to deliver because of the significant amount of chair time required for adjustments. The traditional procedure to fabricate an occlusal splint requires stone models mounted on an articulator. The bite is opened to the desired amount and the salt and pepper technique is used to build acrylic until both of the dentitions are occluding on the acrylic. The splint is then cured, adjusted manually on the models, and polished. This is a time intensive lab procedure which does not eliminate clinical adjustments chairside.

The 3D printed workflow is significantly more efficient. Scans are captured, with the bite open and/or closed. A digital design is generated, whether from a lab technician or an artificial intelligence (AI) design program. The splint is 3D printed on a vat polymerization style printer (all typical steps followed: printing, washing, curing). In order to eliminate as much support polishing as possible, the splints can be printed at a 45° angle on a “raft”, which limits supports to a small area in the anterior. These supports are easily polished out with an acrylic bur and a polishing brush before pumice with

heavy pressure is used on a lathe on high speed. It is possible to take the guard through high shine polishing but that is generally unnecessary if the pumice step is accomplished correctly.

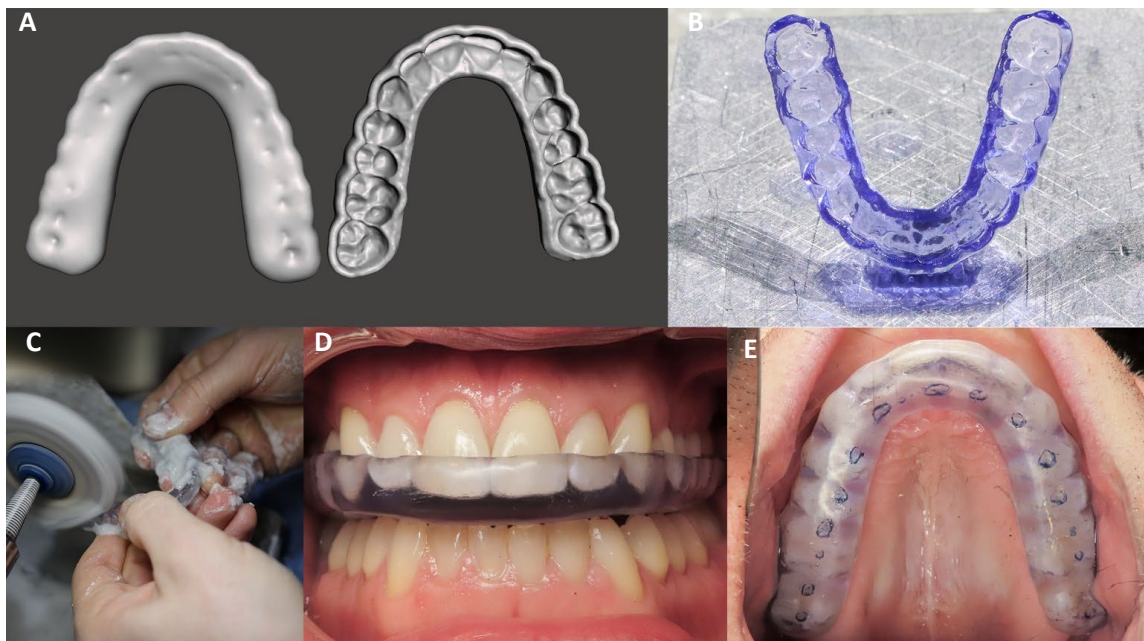


Figure 6. Direct Printed Occlusal Splint. A) digital design of occlusal splint, B) upper right: 3D printed occlusal splint, C) polishing procedure, D) lower middle: frontal view, E) lower right: occlusal view showing the balanced occlusal contacts within all the teeth.

The major advantage of the 3D printed occlusal splint is that the bite can be adjusted digitally, which often results in no adjustments on delivery of the splint. Figure 6 shows the delivery of an occlusal splint without any adjustments where ideal occlusal articulations can be seen. Another benefit of 3D printing occlusal splints is the material. There are many materials available and most of them have some form of thermoelastic properties, meaning they become a little more flexible as they warm up. This creates an environment where they are more comfortable for the patient to wear. 3D printed splints are not perfect, especially those with AI design. While it is constantly improving, there are some occlusal splints that must be manually designed. Additionally, the cost of the resin is quite high and failed prints, though rare, can add up over time. A recent systematic review showed no significant difference in wear between 3D printed occlusal device materials and heat-cure [23]. It also highlighted the need of standardization in wear measurements and parameters across studies.

DIRECT PRINTED RETAINERS AND ALIGNERS

The most cutting-edge application for 3D printing in orthodontics is the direct printing of retainers and aligners, eliminating the model and thermoforming steps. The direct printing of aligners has been promised for years but we are just now at the point where the printing technology and materials are allowing us to make it a reality. There are three main aspects that must be solved in order for the direct printing of these appliances to be feasible: design, printing, and post-processing.

The design of the STL files should theoretically be a straightforward process. However, this is not generally the case. Unlike producing a series of aligners, producing the appliances themselves presents a different set of hurdles. First, undercuts must be dealt with prior to the design of the files, which is not a simple software solution. Next, the trimlines must be generated. It is known that trimlines affect the retention of the tray [24]; however, we do not know the ideal trimline for any particular tooth or movement. Trimlines also can be the preference of the doctor, which creates additional hurdles for

software developers. Some recent studies showed that the thickness of the aligner and the gingival-margin design (shape and height) can affect the orthodontic force expression and influence in tooth movement [25]. These studies suggest that thickness and gingival margin design should be individualized depending on the type of movement for each tooth or group of teeth. This can help to prevent undesirable tooth movements, thereby increasing predictability [25, 26]. Nonetheless, more studies are still needed. Once STL files are produced, the printing process must be accurate and precise.

There are currently 3D printers available on the market that can produce retainers and aligners. Generally, the material must be validated for any particular printer to ensure that there is dimensional accuracy and the material properties have been tested. There are two main concerns that must be answered about the materials: safety and effectiveness [27].

Since aligners are worn full-time and treatment can last more than two years, it is very important that these materials are thoroughly tested for any potential complications. Testing has shown that the release of agents common in plastics, such as bisphenol A, are lower in 3D printed aligners compared to traditionally fabricated aligners [28]. However, more testing is necessary to confirm that these materials are safe over the long term [27].

While the materials may prove to be a safe alternative to the traditional aligner workflow, making sure that they effectively move teeth is something else that must be proven [29]. These materials must be able to deliver consistent, ideal forces to the teeth for effective tooth movement to occur. Early studies have shown a range of answers to this question [30-32]. Some studies have shown a wide variation in material properties, while others have shown material properties are more ideal than the current thermoforming methods. One thing is certain, there is currently no consensus as to whether we have materials with the ability to effectively move teeth at this point in time.

Once aligners are printed, they must be post-processed in order to eliminate any uncured resin and so that the stated material properties can be reached. Currently, some of the materials require a centrifuge and special curing unit. The centrifuge is used to eliminate the uncured resin from the aligners while the curing unit produces nitrogen so that the aligners are cured in the absence of oxygen [31, 33]. Both of these create expenses for offices and labs that will need to purchase additional equipment in order to use these materials. It is true that some materials are able to be washed in alcohol and cured with the same curing units as the rest of their printing materials; however, more research is needed to validate the effectiveness of these materials.

For directly printed retainers and aligners to replace the thermoformed ones, four things must be true when compared to thermoforming: 1) The design and fabrication must be cost effective, 2) The aligners must be as easy to fabricate, 3) The materials must be proven to be effective for moving teeth, 4) The materials must be proven to be safe. Direct printing has significant upsides when compared to thermoforming. Direct printing should allow users to adjust thickness of the material on certain regions to create different force levels for individualized tooth movements and to customize the trimline. The amount of waste produced will decrease significantly because there will be no model printed and no wasted plastic left over after the thermoforming process. Cross-linking of materials may allow us to fabricate aligners that react to pressure, temperature, or other stimuli. The possibilities are only limited by our imaginations and the technology on hand. As with all new technologies, unbiased research on mechanical properties, design, printing, post-processing, safety, and effectiveness of direct 3D printing is still necessary [27]. Finally, suggestions on best practices for in-house 3D printing workflow involving lab infrastructure, safety management, and processing of varied materials should be established to help clinicians and dental staff [34].

CONCLUSIONS

Over the last five years, 3D printing has become common within the orthodontic office. Most of the 3D printing technology is used to produce models, which are then used for the thermoforming of retainers and aligners. However, new technologies and software developments have allowed for an expanded use of 3D printing by the orthodontic office. While more research is necessary to validate new materials and new technologies, the possibilities of what we will be able to accomplish with in-office 3D printing in the future is very exciting.

REFERENCES

1. Chuck Hull. Wikipedia, The Free Encyclopedia. https://en.wikipedia.org/wiki/Chuck_Hull Accessed December 14, 2023.
2. Kesling HD. The philosophy of the tooth positioning appliance. *American Journal of Orthodontics and Oral Surgery* 1945;31(6):297-304.
3. Ponitz RJ. Invisible retainers. *Am J Orthod* 1971;59(3):266-72.
4. McNamara JA, Kramer KL, Juenker JP. Invisible retainers. *J Clin Orthod* 1985;19(8):570-8.
5. Wong BH. Invisalign A to Z. *Am J Orthod Dentofacial Orthop* 2002;121(5):540-1.
6. Kuo E, Miller RJ. Automated custom-manufacturing technology in orthodontics. *Am J Orthod Dentofacial Orthop* 2003;123(5):578-81.
7. Selective Laser Sintering. Wikipedia. https://en.wikipedia.org/wiki/Selective_laser_sintering Accessed December 14, 2023
8. Graf S, Cornelis MA, Hauber Gameiro G, Cattaneo PM. Computer-aided design and manufacture of hyrax devices: can we really go digital? *Am J Orthod Dentofacial Orthop* 2017;152(6):870-874.
9. Graf S, Vasudavan S, Wilmes B. CAD-CAM design and 3-dimensional printing of mini-implant retained orthodontic appliances. *Am J Orthod Dentofacial Orthop* 2018;154(6):877-882.
10. Tsolakis IA, Gizani S, Tsolakis AI, Panayi N. Three-dimensional-printed customized orthodontic and pedodontic appliances: a critical review of a new era for treatment. *Children (Basel)* 2022;9(8):1107.
11. Graf S, Tarraf NE, Kravitz ND. Three-dimensional metal printed orthodontic laboratory appliances. *Semin Orthod* 2021;27(3):189-193.
12. Sakima MT, Dalstra M, Loiola AV, Gameiro GH. Quantification of the force systems delivered by transpalatal arches activated in the six Burstone geometries. *Angle Orthod* 2017;87(4):542-548.
13. Shannon T, Groth C. Be your own manufacturer: 3D printing intraoral appliances. *Semin Orthod* 2021;27(3):184-188.
14. Lightforce. <https://lf.co/> Accessed December 14, 2023.
15. Waldman A, Garvan CS, Yang J, Wheeler TT. Clinical efficiency of LightForce 3D-printed custom brackets. *J Clin Orthod* 2023;57(5):274-282.
16. Braces on Demand. <https://bracesondemand.com/> Accessed December 14, 2023
17. Tahayeri A, Morgan M, Fugolin AP, Bompolaki D, Athirasala A, Pfeifer CS et al. 3D printed versus conventionally cured provisional crown and bridge dental materials. *Dent Mater* 2018;34(2):192-200.
18. Schweiger J, Edelhoff D, Guth JF. 3D printing in digital prosthetic dentistry: an overview of recent developments in additive manufacturing. *J Clin Med* 2021;10(9):2010.
19. Jain S, Sayed ME, Shetty M, Alqahtani SM, Al Wadei MHD, Gupta SG et al. Physical and mechanical properties of 3D-printed provisional crowns and fixed dental prosthesis resins compared to CAD/CAM milled and conventional provisional resins: a systematic review and meta-analysis. *Polymers (Basel)* 2022;14(13):2691.

20. Rizzante F, Bueno T, Guimaraes G, Moura G, Teich S, Furuse A et al. Comparative physical and mechanical properties of a 3D printed temporary crown and bridge restorative material. *J Clin Exp Dent* 2023;15(6):e464-e469.
21. Cousley RRJ. In-house three-dimensional printing within the digital orthodontic workflow. *J World Fed Orthod* 2022;11(6):182-189.
22. Zimmermann M, Ender A, Egli G, Ozcan M, Mehl A. Fracture load of CAD/CAM-fabricated and 3D-printed composite crowns as a function of material thickness. *Clin Oral Investig* 2019;23(6):2777-2784.
23. Grymak A, Aarts JM, Ma S, Waddell JN, Choi JJE. Wear behavior of occlusal splint materials manufactured by various methods: a systematic review. *J Prosthodont* 2022;31(6):472-487.
24. Cowley DP, Mah J, O'Toole B. The effect of gingival-margin design on the retention of thermoformed aligners. *J Clin Orthod* 2012;46(11):697-705.
25. Lyu X, Cao X, Yan J, Zeng R, Tan J. Biomechanical effects of clear aligners with different thicknesses and gingival-margin morphology for appliance design optimization. *Am J Orthod Dentofacial Orthop* 2023;164(2):239-252.
26. Grant J, Foley P, Bankhead B, Miranda G, Adel SM, Kim KB. Forces and moments generated by 3D direct printed clear aligners of varying labial and lingual thicknesses during lingual movement of maxillary central incisor: an in vitro study. *Prog Orthod* 2023;24(1):23.
27. Eliades T, Zinelis S. Three-dimensional printing and in-house appliance fabrication: Between innovation and stepping into the unknown. *Am J Orthod Dentofacial Orthop* 2021;159(1):1-3.
28. Pratsinis H, Papageorgiou SN, Panayi N, Iliadi A, Eliades T, Kletsas D. Cytotoxicity and estrogenicity of a novel 3-dimensional printed orthodontic aligner. *Am J Orthod Dentofacial Orthop* 2022;162(3):e116-e122.
29. Koenig N, Choi JY, McCray J, Hayes A, Schneider P, Kim KB. Comparison of dimensional accuracy between direct-printed and thermoformed aligners. *Korean J Orthod* 2022;52(4):249-257.
30. Hertan E, McCray J, Bankhead B, Kim KB. Force profile assessment of direct-printed aligners versus thermoformed aligners and the effects of non-engaged surface patterns. *Prog Orthod* 2022;23(1):49.
31. Lee SY, Kim H, Kim HJ, Chung CJ, Choi YJ, Kim SJ et al. Thermo-mechanical properties of 3D printed photocurable shape memory resin for clear aligners. *Sci Rep* 2022;12(1):6246.
32. Shirey N, Mendonca G, Groth C, Kim-Berman H. Comparison of mechanical properties of 3-dimensional printed and thermoformed orthodontic aligners. *Am J Orthod Dentofacial Orthop* 2023;163(5):720-728.
33. O'Brien AK, Bowman CN. Impact of oxygen on photopolymerization kinetics and polymer structure. *Macromolecules* 2006;39(7):2501-2506.
34. Panayi N, Eliades T. In-office 3-dimensional-printing: does the hype obscure the hazards for the operator? *Am J Orthod Dentofacial Orthop* 2022;161(6):757-759.

THE AMERICLEFT PROJECT: A ROADMAP FOR AUDITS, QUALITY ASSURANCE, AND IMPROVEMENT IN CLEFT CARE THROUGH COMPARATIVE EFFECTIVENESS RESEARCH USING PRACTICE-BASED EVIDENCE

Ronald R. Hathaway, Ross E. Long, Jr., Kathleen Russell, Ana Mercado, John Daskalogiannakis, Jean-Charles Doucet, Stephen Beals, Patricia Beals

ABSTRACT

A practice-based evidence (PBE) approach has proven to be successful in our Americleft studies for quality improvement of outcomes through inter-center comparison methods. In this chapter, we discuss the Americleft Project; its beginnings, founding principles, and the value of the external audit process to implement changes in team protocols leading to better outcomes for a cleft center.

KEY WORDS: Americleft, Practice-based evidence, Cleft palate, Outcomes, Audits.

INTRODUCTION

Somewhere between a gold standard road of randomized controlled trials (RCTs) and the unpaved roads of clinical storytelling such as case studies and intra-center audits, there lies another road, an effective route well suited for “real world” clinician travelers to arrive at their “best practice” destinations. Comparative effectiveness research (CER) using practice-based evidence (PBE) will be discussed and illustrated with various studies from what has come to be known as the Americleft Project.

A PARADIGM SHIFT IN EVIDENCE BASED STUDIES

In 1992, a group of six European orthodontists published the first studies designed to directly compare outcomes resulting from differing protocols used in the initial care of infants with unilateral cleft lip and palate (UCLP) [1]. This study became known as Eurocleft [1]. Unbeknownst to them at the time, they were using a novel research approach: CER using PBE [2].

In the quest to design approaches to clinical care that are evidence-based, these publications afforded us, for the first time, an opportunity to directly compare expected outcomes from different team treatment approaches for infants affected by clefting. Previous reliance on RCTs, still considered the standard for evidence in research, unfortunately has turned out to be too cumbersome to answer all of our clinical research questions related to treatment outcomes. As stated by Sackett [3], one of the principal proponents of evidence-based practice and RCTs: “...some questions about therapy do not require [or are not feasible for] randomized trials...if no randomized trial has been carried out for our patient’s predicament, we must follow the trail to the next best external evidence.” Fortunately, PBE-CER,

while not capable of matching RCTs' level of unbiased evidence, is nonetheless capable of identifying favorable outcomes from our treatment choices.

One of the first descriptions of PBE from CER was provided by Horn and Gassaway in 2007 [2]. Since that time, PBE-CER has been used successfully in several major research projects in the cleft field, most notably the original Eurocleft Study [1], and more recently, the Americleft Project [4-8]. The latter used the principles and successful methodology of the Eurocleft Study and PBE-CER to identify favorable outcomes from a wide range of infant management protocols. This approach has now expanded to include alveolar bone graft outcomes as well as speech, surgical, and psychosocial outcomes. All of these assessments are of additional importance to a cleft team. Also, the outcome data generated by this research can be used by teams for important internal audits of team outcomes for quality assurance (QA) and quality improvement (QI). All of the internal audits for QA and QI require CER with peer-benchmarking to maximize their value and improve the care provided for patients.

AMERICLEFT BEGINNINGS

The Americleft Project began organically around 2004 with a handful of interested orthodontists who were committed to sharing data from their respective cleft team centers for the purpose of studying cleft treatment outcomes. The group formally met for the first time in 2006 at the Lancaster Cleft Palate Clinic. The proposed aims centered on developing strategies to execute inter-center collaborative outcome studies for the purpose of documenting and assessing outcomes and best practices of team care.

Participating centers' team members had to be experienced and focally interested in cleft care and have an interest in seeking knowledge about the relative merits of various treatment protocols. This desire had to dominantly precede over any unquestioning loyalty to particular procedures. While we, as care providers, believe that the procedures we are doing are the best possible for our patients, involvement in collaborative outcome studies implies a degree of uncertainty about the true effectiveness of our individual protocols. The ability to question our own beliefs and to accept the possibility that there may be other equally good or better outcomes with protocols different from those used by our own teams is one of the basic principles on which PBE research and assessments are founded.

The Americleft studies emphasized controlling biases, utilization of the audit process of similar outcome studies [9] (Figure 1), and inter-center comparisons of the various multifaceted protocols practiced by each center. While using the PBE-CER method, the limitation that causal inference of specific factors is not possible was recognized. Accepting this limitation, PBE-CER is a practical approach that is well suited to the complexities of the assessment of cleft treatment outcomes. The PBE-CER approach reduces challenges related to the time required for outcome studies, small sample sizes at each center, expense and required grant funding, and ethical concerns inherent in conducting RCTs. In contrast to RCTs that stress the efficaciousness of treatments, utilization of the PBE-CER method for clinical audits can determine the comparative effectiveness of a center's treatment protocol and also elucidate certain treatment features with outcomes at the extremes within a center's protocol, further generating hypotheses for specific RCTs.

Finally, professionals entrusted with the provision of health care have an obligation to review the success of our practices and, where shortcomings are revealed, to take remedial action. Audit of the treatment of cleft treatment is a considerable challenge due to the lengthy follow-up required, complexity and multifaceted nature of cleft care, subtlety, and number of relevant outcomes and, above all, the

relatively small number of cases per center. Inter-center collaboration offers significant advantages, by providing insight into the processes and outcomes of treatment of comparable services by other teams, the exchange of clearly successful practices, and the establishment of future goals.

The Audit Cycle

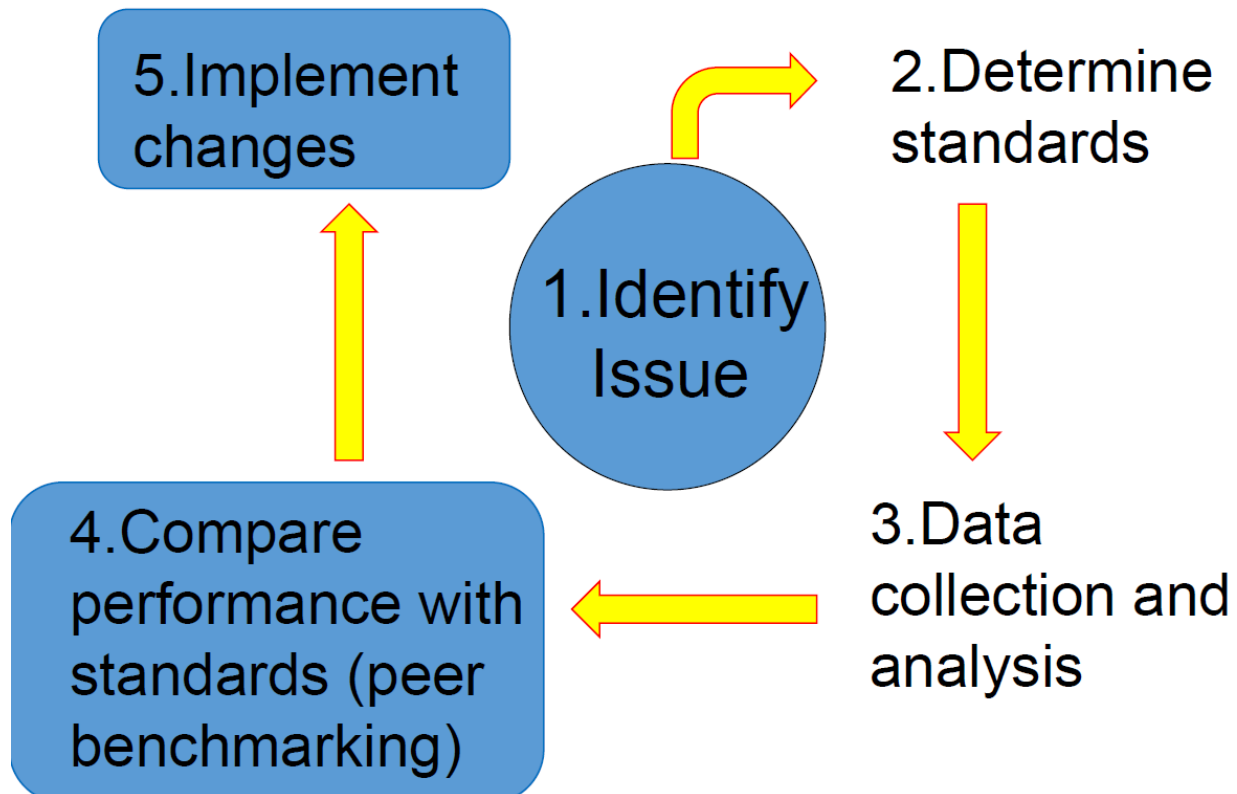
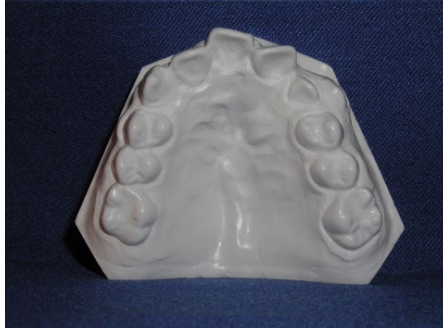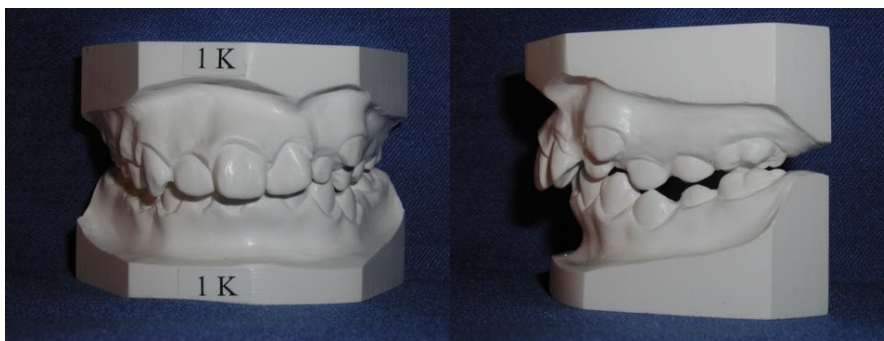


Figure 1. The audit cycle. The cycle demonstrates the steps taken towards quality improvement. Step 1, the issue is that outcomes for centers vary widely. Step 2, standards such as data timepoints and assessment instruments are chosen with agreement among participating centers. Step 3, data must be blinded, and measurements validated. Step 4, it is critical that there is peer benchmarking using external standards. Step 5, only through peer benchmarking and external standards will a center be able to determine what changes, if any, are to be implemented based on quality outcomes.

EARLY AMERICLEFT STUDIES

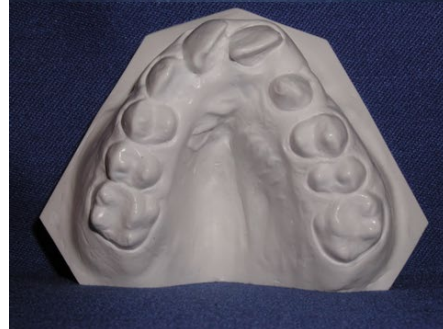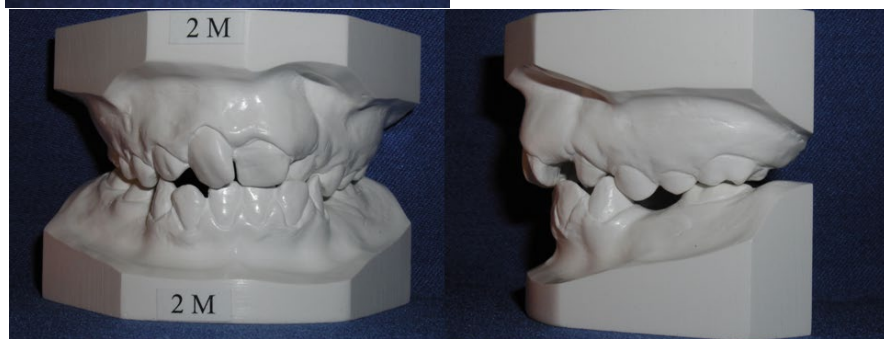
Since their inception, Americleft studies have incorporated the principles of good record keeping, eliminating bias in sample selection, and intellectual honesty of the individuals representing each center. Examples of record and data standards and the methods used in Americleft outcome studies can be found in the guidebook, *The Americleft Project* [10]. Standards included the preparation of dental casts in a manner by which the rater is blinded to center origin by requiring identical cast dimensions from all centers. Also, all facial photographs were cropped using specified landmarks in the nasolabial area with standardized pixel dimensions, again to ensure de-identification of the photograph's particular center.

Criteria for inclusion in the original Americleft studies were as follows: 1) non-syndromic complete UCLP and palate, with no associated malformations, 2) consecutively enrolled patients that could be documented by the center's records and patient birth dates, 3) all primary treatment (surgeries and any orthopedics) received at the same center, 4) no additional active orthodontic treatment including arch expansion prior to the mixed dentition study, 5) availability of pre-surgical records to confirm complete skeletal clefts, and 6) availability of dental casts trimmed in occlusion, date matching lateral cephalometric radiographs, and facial photos.



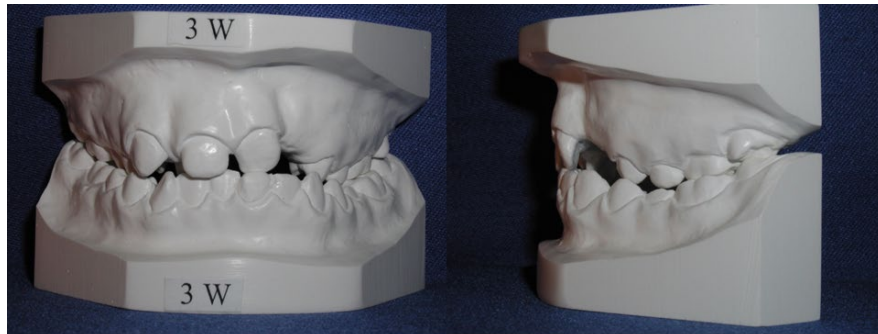
Goslon Yardstick

1



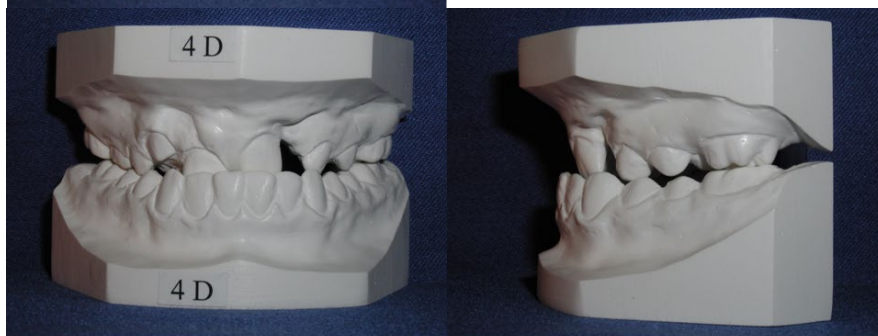
Goslon Yardstick

2



Goslon Yardstick

3



Goslon Yardstick

4



Figure 2A-E. Goslon scoring in UCLP. A score of 1 is best and a score of 5 is worst. Scores of 4 and 5 indicate eventual need for orthognathic surgery to establish an acceptable outcome.

Initially, five centers were identified to participate in the original UCLP study that was closely modeled after the Eurocleft Study for 9-year-old patients (range 7-11 years). The Americleft studies focused on the comparison of dental arch relationship outcomes utilizing the UCLP Goslon Yardstick (Figure 2a-e), craniofacial form outcomes utilizing standard cephalometric measurements (Figure 3), and nasolabial appearance outcomes based on frontal and lateral images similar to the Asher McDade assessment (Figure 4).

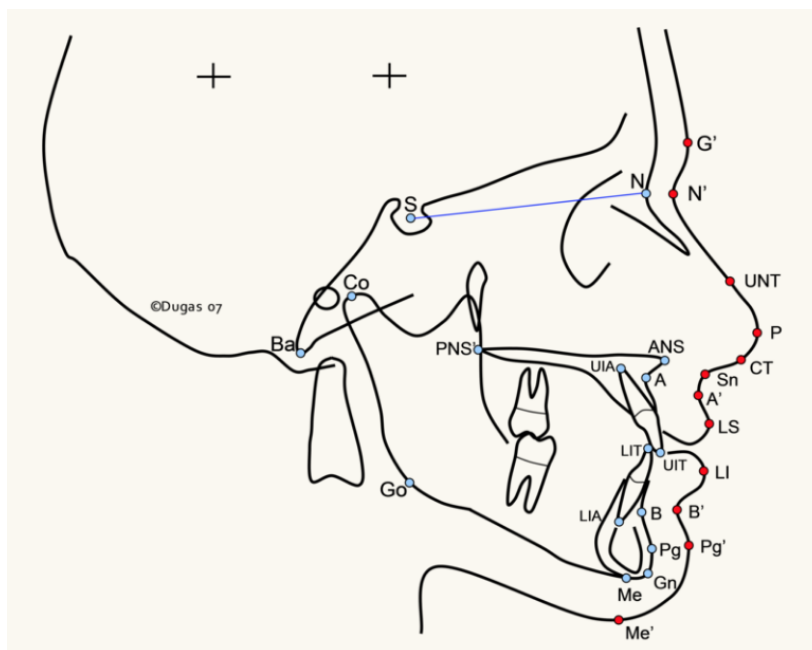
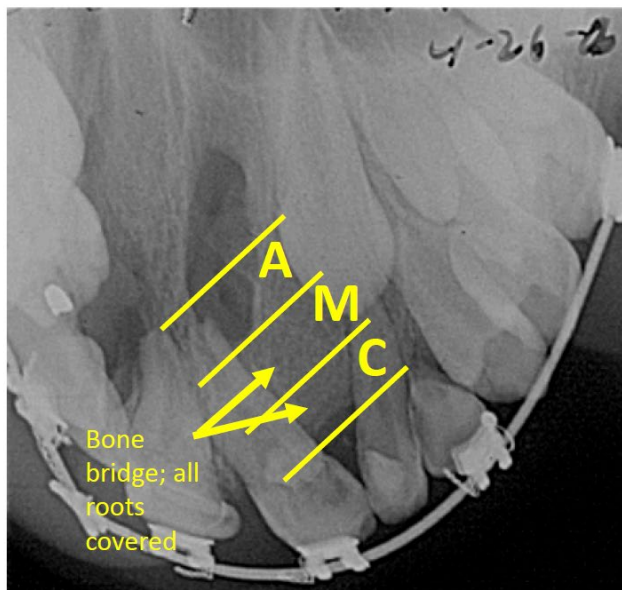


Figure 3. Reference landmarks on the lateral cephalometric tracing. Cephalometric measurements included the following: SNA ($^{\circ}$), SNB ($^{\circ}$), ANB ($^{\circ}$), Ba-N-ANS ($^{\circ}$), Ba-N-Pg ($^{\circ}$), ANS-N-Pg ($^{\circ}$), WITS appraisal ($A \perp OP : B \perp OP$) (mm), Ba-N (mm), PNS'-ANS (mm), Md length (Co-Gn) (mm), SN-MP (SN-GoGn) ($^{\circ}$), ANS-Me (mm), N-Me (mm), ANS-Me/N-Me (%), U1-PP ($^{\circ}$), and L1-MP (L1-GoGn) ($^{\circ}$).

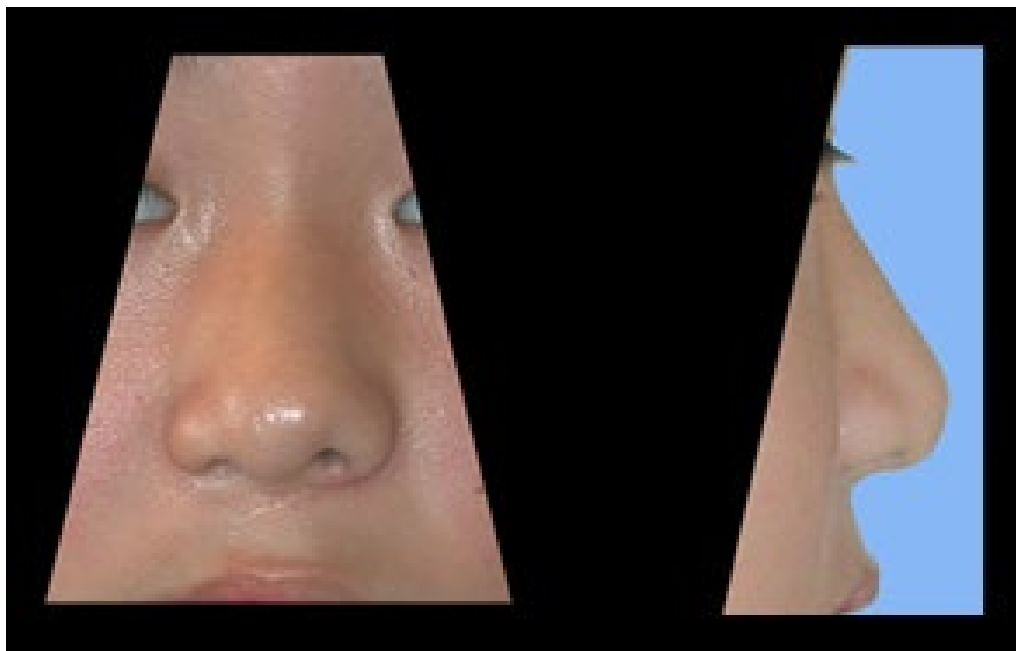

Figure 4. Example of standardized cropped photographs for nasolabial esthetic ratings for outcome assessment of nasal form, nasal symmetry, vermilion border, and nasolabial profile. Features are rated on a 1 to 5 scale: 1 – Very good (for a patient with a cleft), 2 – Good, 3 – Fair, 4 – Poor, 5 – Very poor.

Americleft: Validation for assessing ABG's (2012)



*The Americleft **SWAG** method of bone graft outcome assessment*

A	0
M	2
C	2
Total	4

Figure 5. Example of Standardized Way to Assess Grafts (SWAG) validated by Americleft. Two points are possible for any one third of the roots’ apical, middle, and coronal regions. Two points are given for a complete bony bridge, or one point for no bony bridge, but with bone covering all of the root surfaces in that third, and zero points when there is no bony bridge and an absence of bone covering and root area in the designated third. In this example, the total score assigned is four out of a total possible six points due to no bony bridge in the apical third and no bone covering of the central incisor in the same third.

Following these studies, a new method to investigate secondary alveolar bone grafting (ABG) outcomes was developed and validated. While numerous previous methods were used for such assessments, the one used most frequently was the Bergland assessment [11]. The Americleft group sought a less complicated and more intuitive method to assess ABGs. This led to what has become known as the Standardized Way to Assess Grafts (SWAG) [12, 13] (Figure 5).

Key Elements of Primary Protocols

Treatment	Center A	Center B	Center C	Center D	Center E	Center F
Pre-surgical orthopedics	No	Yes	No	Yes	Yes	Yes
Lip repair	6 wks Millard or 6 mos Delaire	2-3 mos Millard	3 mos Tennison	3 mos Variable	7 wks Lip Adhesion; 7 mos Millard	3-4 mos Millard
Primary bone grafting	No	Yes 6-9 mos	No	No	No	No
Hard palate repair	9-12 mos Bardach or Delaire	11-15 mos Hard palate Wardill-Kilner	12 mos Vomer flap	12 mos Vomer flap	14 mos V-Y pushback	? mos Vomer flap/ Von Langenbeck
Soft palate repair	9-12 mos Bardach Or 6 mos Delaire	11-15- mos Furlow (1 surgeon) or IVV	18 mos Median suture with IVP	12 mos Van Langenback with IVP		? Veau pushback
Secondary bone grafting	6 yrs Delaire	8-9 yrs If needed	9 yrs	7-10 yrs	9 yrs	9-11 yrs
Surgeons	2	4	1	4 (80% w/1)	1	4

Figure 6. Key elements of primary protocols. Notable features of interest were the addition of presurgical infant orthopedics by Centers B, D, E, F; primary alveolar bone grafting performed by Center B; and the variability in the number of surgeons among centers (a possible source of proficiency bias).

The key elements of the original six Americleft center protocols are shown in Figure 6. It is noted that Center E was not included in the later published results of these studies due to a significantly lengthy period of infant orthopedics to the age of 14 months at that center.

Completion of Goslon ratings for these centers was the first objective of the Americleft group and the preliminary unpublished results are shown in Figures 7 and 8. Additional training and rating sessions followed over the next few years, resulting in improved intra-reliability and inter-reliability scores. The first results of the well-controlled and well-designed inter-center outcome comparison studies were published in 2011 in a five-part journal article to which the reader is referred for details [4-8, 13]. Summaries of the three original Americleft studies are presented below. In addition, the summary of a 2017 study, “Standardized Way to Assess Grafts (SWAG)” is also presented.

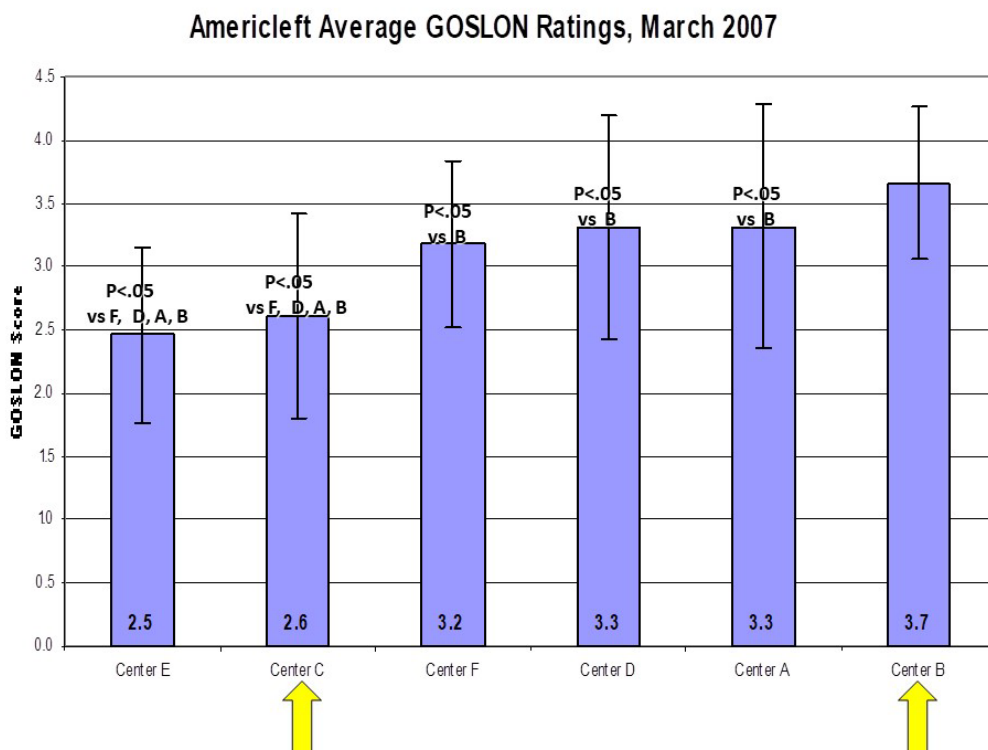


Figure 7. Average Goslon ratings for UCLP outcomes, March 2007. Center B with primary alveolar bone grafting protocol had significantly poorer outcomes when compared to all other centers. Note: Center B is referred to as Center A11 in Figures 9 and 10.

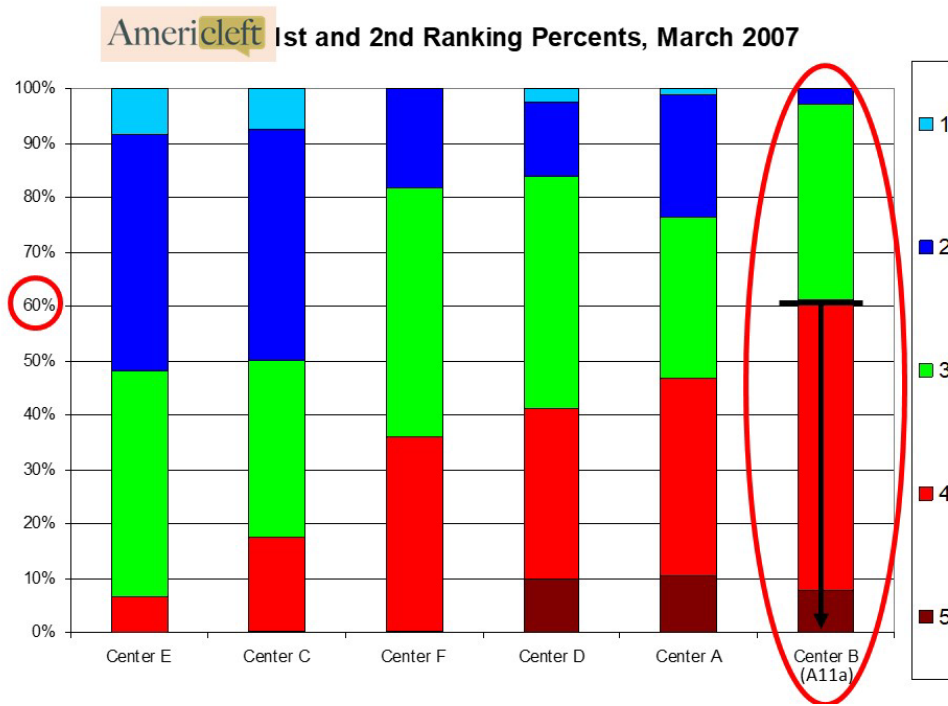


Figure 8. Ratings by Goslon category for UCLP outcomes, March 2007. Center B's Goslon scores of four and five indicate a need for orthognathic procedures in nearly two-thirds of their patients.

Americleft Study 2011: UCLP Dental Arch Relationships Study (Goslon Yardstick) [5]

Objective: To compare maxillomandibular relationships for individuals with non-syndromic complete UCLP using the Goslon Yardstick for dental models.

Design: Retrospective cohort study.

Setting: Five cleft palate centers in North America.

Subjects: A total of 169 subjects with repaired non-syndromic complete UCLP who were consecutively treated at the five centers.

Methods: Ethics approval was obtained. A total of 169 dental models of patients between 6 and 12 years of age with repaired complete UCLP were assessed using the Goslon Yardstick. Weighted kappa statistics were used to assess intra-rater and inter-rater reliabilities and analysis of variance (ANOVA) and Tukey-Kramer analysis were used to compare the Goslon scores. Significance levels were set at $p < 0.05$.

Results: Intra-rater and inter-rater reliabilities were very good for model ratings. One center that incorporated primary ABG showed poor Goslon scores that were significantly poorer than the remaining centers. Surgery protocols used by the other four centers did not include primary ABG but involved a number of different lip and palate surgical techniques. Based on the Goslon Yardstick assumptions, the center with the best scores would be expected to require end-stage maxillary advancement orthognathic surgery in 20% of its patients; whereas the center with the worst scores would be likely to require this surgery in 66% of its patients.

Conclusions: The Goslon Yardstick proved capable of discriminating among the centers' dental arch relationships.

Americleft Study 2011: Analysis of UCLP Craniofacial Form (Cephalometric Study) [6]

Objective: To compare craniofacial morphology for individuals with non-syndromic complete UCLP between the ages of 6 and 12 years.

Design: Retrospective cohort study.

Setting: Four North American cleft palate centers.

Subjects: A total of 148 subjects with repaired complete UCLP who were consecutively treated at the four centers.

Methods: A total of 148 pre-orthodontic lateral cephalometric radiographs were scanned, scaled, digitized, and coded to blind the examiners to the origin of the radiograph. For each radiograph, 18 cephalometric measurements (angular and ratio) were performed. Measurement means, by center, were compared using ANOVA and Tukey-Kramer analysis.

Results: Significant differences were found for sagittal maxillary prominence among the four centers. The most significant difference was seen between Center B (lowest SNA) and Center C (highest SNA). Similar differences were seen at the soft tissue level, with Center C showing a significantly larger ANB angle

compared with Centers B and D. Center C was also shown to have statistically greater mean soft tissue convexity than Centers B, D, and E. The mean nasolabial angle in Center B was significantly more acute than in Centers C, D, and E. No statistically significant differences were seen for mandibular prominence, vertical dimensions, or dental inclinations.

Conclusion: Significant differences were seen among the centers for hard and soft tissue maxillary prominence, but not for mandibular prominence, vertical dimensions, or dental inclinations. A statistically significant ($p < .001$) negative correlation was found between Goslon scores and ANB angle ($r = -0.607$).

Americleft Study 2011: UCLP Nasolabial Esthetics Study (Photographic Images) [7]

Objective: To compare the nasolabial esthetics of individuals with repaired non-syndromic complete UCLP between the ages of 5 and 12 years.

Design: Retrospective cross-sectional study.

Setting: Four cleft centers in North America.

Subjects: A total of 124 subjects with repaired complete UCLP who were treated at the four centers.

Methods: After ethics approval was obtained, 124 pre-orthodontic frontal and profile patient images were scanned, cropped to show the nose and upper lip, and coded. Using the coded images, four nasolabial features that reflect esthetics (i.e., nasal symmetry, nasal form, vermilion border, and nasolabial profile) were rated by five trained investigators using the system reported by Asher-McDade et al. (1991). Intra-rater and inter-rater reliabilities were determined using weighted kappa statistics. Mean ratings, by center, were compared using ANOVA.

Results: Intra-rater reliability scores were good to very good and inter-rater reliability scores were moderate to good. Total nasolabial scores were as follows: Center B = 2.98, Center C = 3.02, Center D = 2.80, and Center E = 2.87. No statistically significant differences among centers were detected for both total aesthetic scores and all of the individual aesthetic components.

Conclusion: There were no significant differences in nasolabial esthetics among the centers. Overall fair to good nasolabial aesthetic results were achieved using the different treatment protocols in the four North American centers.

Americleft Study 2017: UCLP - Standardized Way to Assess Grafts (SWAG) (Occlusal Radiographs) [13]

Objective: The objective of this study was to evaluate a new method, a SWAG, to rate ABG outcomes for patients with cleft lip and palate.

Design: Retrospective comparison using the SWAG scale.

Setting: This study assessed ABG outcomes among four cleft centers with different treatment protocols.

Methods: A total of 160 maxillary occlusal radiographs taken 3 to 18 months post-ABG for sequentially treated patients with repaired and grafted cleft lip and palate were assessed using the SWAG scale.

Radiographs were scanned, standardized, blinded, and rated by six calibrated orthodontists. Raters assessed bone fill by vertical thirds, bony root coverage, and total bony fill (13). All radiographs were rated twice, 24 hours apart, by the same raters.

Main Outcomes: Intra-rater and inter-rater reliabilities were assessed.

Results: Intra-rater reliability was good to very good (0.760; 0.652–0.834), inter-rater reliability was moderate to good (0.606; 0.569–0.681), and the reliabilities were comparable to previously published methods.

Conclusions: Rater reliabilities were shown to be comparable to or better than existing methods. The SWAG method was validated for ABG assessments in both the mixed and permanent dentitions based on reliabilities from an inter-center outcome comparison.

Average Dental Arch Relationship (Goslon) Ratings

Center	Goslon	PSOT	Latham	NAM	GPP	1° ABG	Delayed HP	# Surgeons
A2	2.36	√						1
E1	2.47							1
A1	2.50							1
E2	2.59							6
E3	2.64	√					√	6
E4	3.03	√				√		7
E5	3.04							10
A3	3.13							4
A4	3.13			√				2
A5	3.18	√						4
A6	3.32			√				4
A7	3.32							1
A8	3.38							2
E6	3.46	√						12
A9	3.60			√				3
A10	3.63			√	√			1
A11	3.66	√				√		4
A12	3.75			√				3
A13	3.77	√				√		4
A14	3.91			√	√			3
A15	3.92		√		√			2
A16	3.94		√					3

Figure 9. Rank ordered results for UCLP Goslon outcomes. Americleft Centers (A1-A16), Eurocleft Centers (E1- E5), Americleft Center A1 was the link for Goslon score comparison with the Eurocleft center scores. Centers outlined in the blue rectangle had relatively fewer total procedures and demonstrated better outcomes, while centers outlined in the red rectangle had more procedures (more infant orthopedics, more primary surgeries) and demonstrated poorer outcomes. (Note that Center A11 with primary alveolar bone grafting was Center B in Figures 7 and 8.)

THE VALUE OF AMERICLEFT STUDIES: NEW CENTERS AND CONTINUED QUALITY IMPROVEMENT

Expanding Americleft: Additional Inter-center UCLP Dental Arch Relationship (Goslon) Comparisons [14, 15]

Using the same methods reported in our initial UCLP Goslon study for inter-center comparison, the number of Americleft centers has expanded to a total of 16 centers. These Americleft centers were compared with each other and with the five original Eurocleft centers. One Americleft center served as the common link, having been compared with the Eurocleft Centers. Figure 9 shows centers with protocols that included additional procedures such as infant orthopedics and supplementary primary surgeries beyond lip and palate repair, and that they demonstrated less favorable outcomes. It is important to note that although causal inferences cannot be made, studies showed that centers can achieve good results with fewer procedures and there appear to be no measurable over-riding benefits from utilizing presurgical infant orthopedic modalities and nasoalveolar molding (NAM) modalities for dental arch relationship outcomes.

Average Dental Arch Relationship (Goslon) Ratings

Center	Goslon	PSOT	Latham	NAM	GPP	1° ABG	Delayed HP	# Surgeons
A1	2.36	✓						1
E1	2.47							1
A2	2.5							1
E2	2.59							6
E3	2.64	✓					✓	6
E4	3.03	✓				✓		7
E5	3.04							10
A11b	3.07							4
A3	3.13							4
A4	3.13			✓				2
A5	3.18	✓						4
A6	3.32			✓				4
A7	3.32							1
A8	3.38							2
E6	3.46	✓						12
A9	3.53			✓				4
A10	3.63			✓	✓			1
A11a	3.66	✓				✓		4
A12	3.75			✓				3
A13	3.77	✓				✓		4
A14	3.91			✓	✓			3
A15	3.92		✓		✓			2
A16	3.94		✓					3

Figure 10. Improvement of dental arch outcomes for a center after eliminating primary alveolar bone grafting. Center A11a was the original Center B in the 2007 audit. Center A11b is the same center in 2017 with no primary alveolar bone grafting.

Elimination of Primary Alveolar Bone Grafting: A UCLP Dental Arch Relationship (Goslon) Follow-Up Study for One Center [16]

Improvement in quality outcomes was noted after Center B eliminated primary ABG from its protocol following the 2007 audit (Figure 10). In a follow-up audit after discontinuation of primary bone grafting 10 years later, there were statistically significantly better dental arch relationships when compared with the center's original sample. In addition, the new dental arch relationships were not statistically different from those of the best of the Americleft centers when ranked ordered by the average Goslon score for each center. In fact, the outcomes after elimination of primary ABG resulted in an average Goslon score more favorable than 14 of the 16 centers previously examined.

Americleft Nasolabial Esthetics:

A Longitudinal Investigation of Nasolabial Esthetic Changes With and Without Revision Surgery In Patients with Non-syndromic, Unilateral Cleft Lip and Palate. Dabbagh et al., 2018

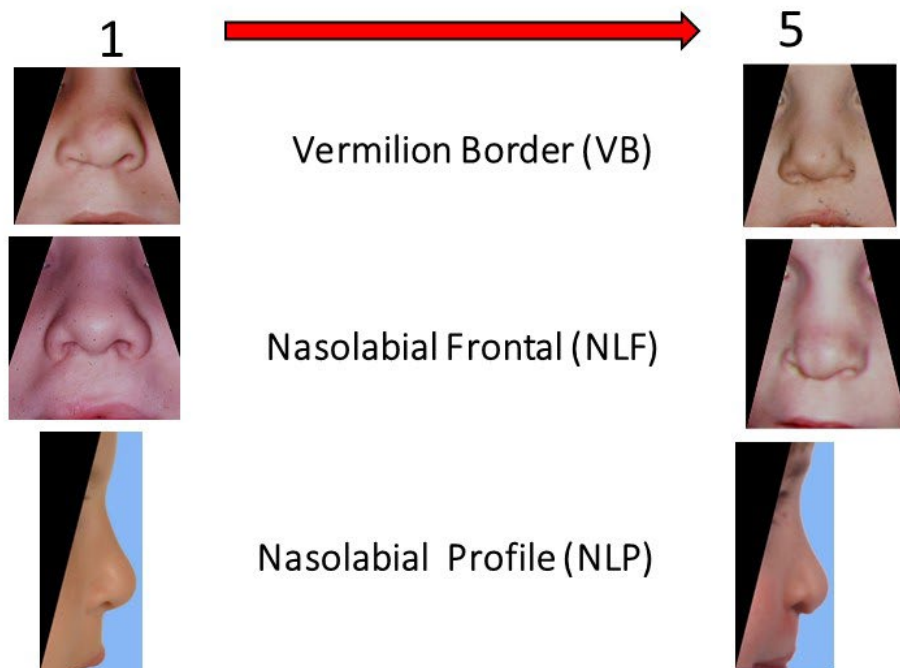


Figure 11. Examples used for rating of best and worst outcomes for parameters of nasolabial esthetics.

Assessment of Nasoalveolar Molding (NAM): A UCLP Nasolabial Esthetics Outcomes Studies and Protocol Changes [17]

Using the same methods reported in our initial UCLP nasolabial study for inter-center comparison (Figure 11), a four center study was conducted to assess cumulative outcome rankings for the parameters of vermilion border, nasolabial frontal, and nasolabial profile esthetics. Two of the centers had extra procedures, one included NAM and the other included NAM with or without gingivoperioplasty. The cumulative scores (Figure 12) noted little variation in the nasolabial esthetic outcomes. There was, however, wide variation for vermilion border outcomes perhaps related to the surgeons' proficiencies.

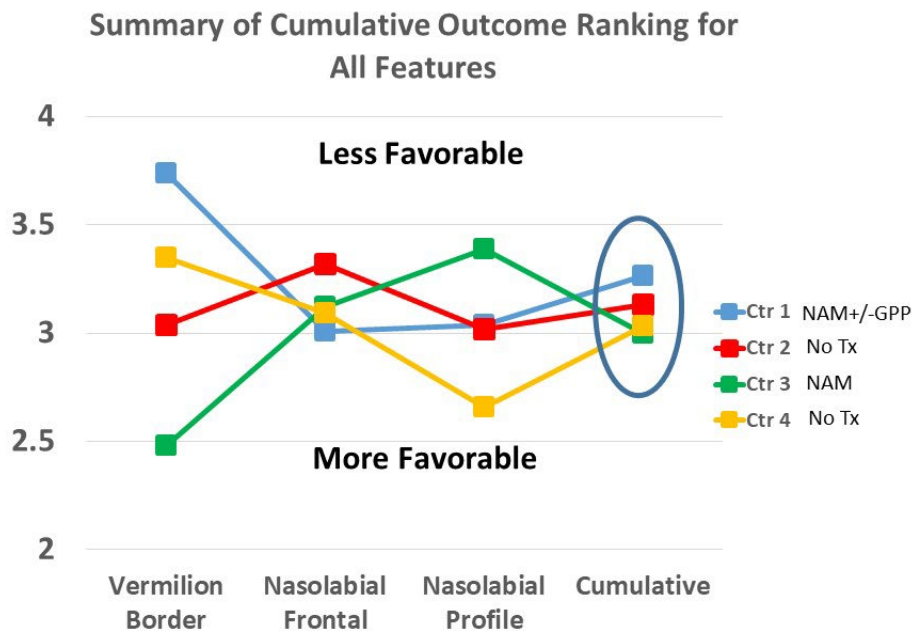


Figure 12. Summary of cumulative outcome ranking of three nasolabial esthetic features in a four center UCLP comparison study. The blue area encircled on the right indicates little variation in the cumulative outcomes between centers.

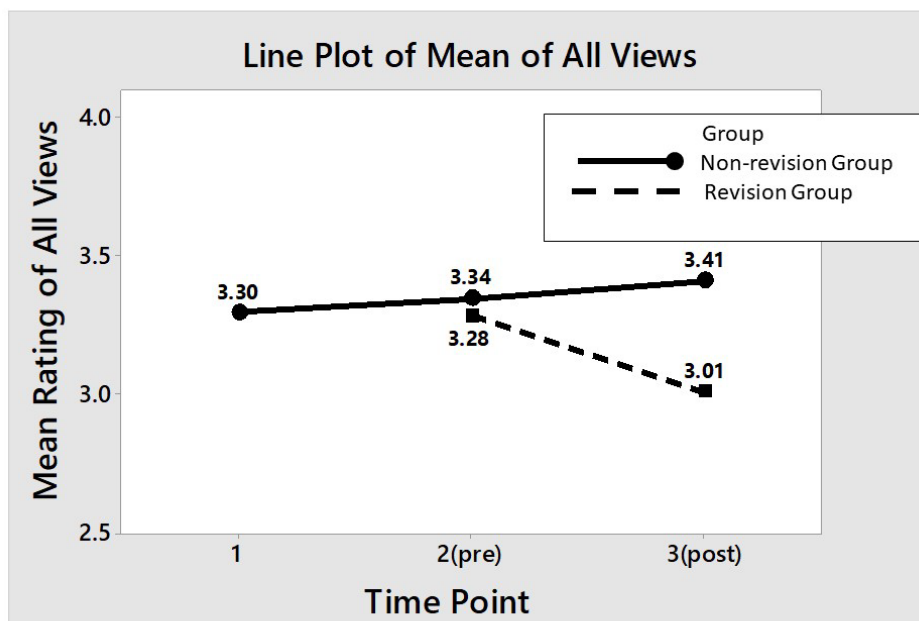


Figure 13. Improvement in nasolabial outcomes scores in a center that introduced the option of lip and nose revisions. Time point 2 represents the center making surgical revisions available to patients and time point 3 represents the outcomes for subgroups that either accepted or rejected the additional surgery. (Note that the lower the score, the better the outcome.)

Figure 13 shows improvement of the nasolabial composite score for one center that did not perform pre-surgical infant orthopedics (PSIO) or NAM but included follow-up at a later date after additional lip and nose revision surgeries. The subgroup that received revision surgeries improved their nasolabial scores when compared with the subgroup from the same center that did not choose revisionary surgery. Through this nasolabial study and other Americleft nasolabial studies [18, 19], it has been concluded that nasolabial esthetics improved with both NAM and secondary revision surgery at the ages studied. It should be noted that for patients with isolated cleft lip only, which were excluded from our studies, it has been reported [20] that more surgeries were correlated to lower verbal IQ and higher frontal lobe volume. The ultimate test of long-term benefits from NAM may be in the future demonstration of improved long-term outcomes and a benefit vs. burden analysis of NAM vs secondary revision surgery vs. neither NAM nor revision surgery at the completion of treatment.

Treatment	Center 1	Center 2	Center 3	Center 4
Pre-surgical orthopedics	No	No	Taping	No
Lip repair	6 wks Millard or 6 mos Delaire w/ nasal floor repair	3 mos Tennison no nasal floor repair	3-4 mos Millard no nasal floor repair	3 mos Millard lip w/ hard palate vomerplasty w/ nasal floor repair
Primary bone grafting	No	No	No	No
Hard palate repair	9-12 mos Bardach or Delaire	12 mos Vomer flap	12 mos Vomer flap	NA
Soft palate repair	9-12 mos Bardach or 6 mos Delaire	18 mos Median suture w/ IVP	12 mos von Langenbeck with IVP	18 mos modified von Langenbeck
Secondary bone grafting	5-6 yrs	7-10 yrs	7-10 yrs	9-10 yrs
Pre-grafting Orthodontics	No	83% exp and alignment	32% exp and 7% exp & alignment	18% exp and 75% alignment
Surgeons	2 lip / palate 1 ABG	4 lip / palate 5 ABG	4 lip / palate 1 ABG	6 lip /palate 3 ABG
Sample Size	44	36	28	44

Figure 14. Protocols of a four center UCLP SWAG study.

Assessment of UCLP with the SWAG and Changing Protocols [21]

Protocols of a four center UCLP SWAG study are shown in Figure 14. Subsequent to an initial inter-center comparison audit, Center 2 adopted the early secondary bone grafting protocol of Center 1. Center 2 changed the time for the bone grafting from traditional secondary grafting at an average age 8 to 9 years to early secondary grafting at approximately six years old (prior to central incisor eruption). The center also discontinued pre-ABG maxillary expansion procedures and surgically closed the nasal floor at the time of grafting. Center 2 demonstrated significant improvement for bone fill in the coronal one-third, from the SWAG scale, as a result of the change in protocol (Figure 15).

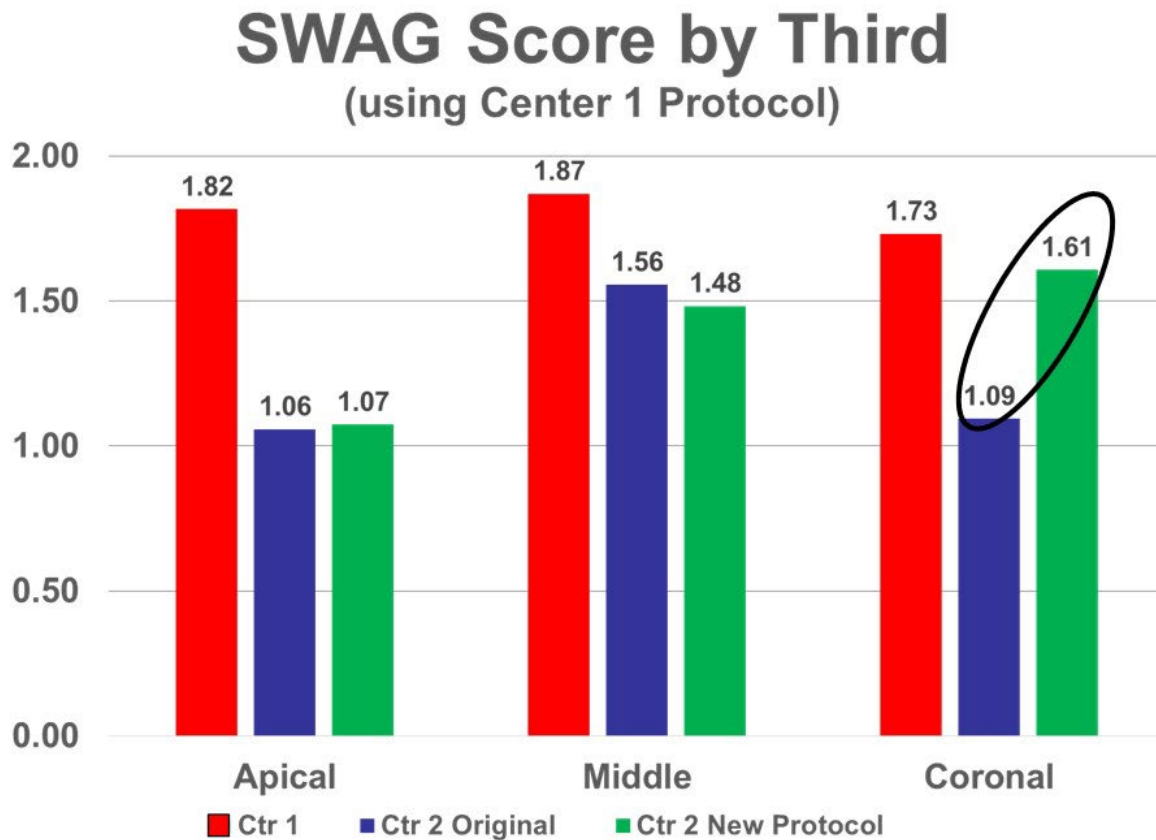


Figure 15. Center 2 Outcomes. Center 2 had significant improvement for the coronal one-third bone fill after adopting the early secondary alveolar bone grafting protocol of Center 1.

CONCLUSIONS

Americleft started with a group of orthodontists from five cleft centers. It has expanded to include additional established and grant-funded study groups for speech, surgery, psychosocial, and medical and dental outcomes. Numerous contributions to the literature [4-8, 10, 12-19, 21-44] have resulted from the efforts of these additional Americleft groups and their outcome studies.

Several Americleft centers have further collaborated with other centers in a new project, Craniofacial Outcomes Research Network (CORNET), a data registry supported by the National Institutes of Health that studies the relationships of speech outcomes to primary surgical interventions as practiced by numerous centers [45].

The goal to provide the most optimal treatment with the lowest burden of care for patients and their families rests with each individual clinician. The heart and soul of Americleft initially was and remains to be of service to all clinicians and cleft centers that want to conduct QI in their cleft treatment protocols through utilization of the audit process and inter-center comparison of outcomes in a PBE process.

REFERENCES

1. Shaw WC, et al. A six-center international study of treatment outcome in patients with clefts of the lip and palate. *Cleft Palate Craniofac J*. 1992;29(1-5):393-418.
2. Horn SD, Gassaway J. Practice-based evidence study design for comparative effectiveness research. *Med Care* 2007;45(10 Supl 2):S50-57.
3. Sackett DL, Straus SE, Richardson WS, et al. *Evidence-Based Medicine. How to Practice and Teach EBM*. Churchill Livingstone, Edinburgh, 2000.
4. Long RE Jr, Hathaway R, Daskalogiannakis J, Mercado A, Russell K, Cohen M, Semb G, Shaw W. The Americleft Study: an inter-center study of treatment outcomes for patients with unilateral cleft lip and palate part 1. Principles and Study Design. *Cleft Palate Craniofac J* 2011;48(3):239-243.
5. Hathaway R, Daskalogiannakis J, Mercado A, Russell K, Long RE Jr, Cohen M, Semb G, Shaw W. The Americleft Study: an inter-center study of treatment outcomes for patients with unilateral cleft lip and palate part 2. Dental arch relationships. *Cleft Palate Craniofac J* 2011;48(3):244-251.
6. Daskalogiannakis J, Mercado A, Russell K, Hathaway R, Dugas G, Long RE Jr, Cohen M, Semb G, Shaw W: The Americleft Study: an inter-center study of treatment outcomes for patients with unilateral cleft lip and palate part 3. Analysis of craniofacial form. *Cleft Palate Craniofac J* 2011;48(3):252-258.
7. Mercado A, Russell K, Hathaway R, Daskalogiannakis J, Sadek H, Long RE Jr, Cohen M, Semb G, Shaw W. The Americleft Study: an inter-center study of treatment outcomes for patients with unilateral cleft lip and palate part 4. Nasolabial esthetics. *Cleft Palate Craniofac J* 2011;48(3):259-264.
8. Russell K, Long RE Jr, Hathaway R, Daskalogiannakis J, Mercado A, Cohen M, Semb G, Shaw W. The Americleft Study: an inter-center study of treatment outcomes for patients with unilateral cleft lip and palate part 5. General discussion and conclusions. *Cleft Palate Craniofac J* 2011; 48(3):265-270.
9. Kim JB, Strike P, Cadier MC. A simple assessment method for auditing multi-centre unilateral cleft lip repairs. *J Plast Reconstr Aesthet Surg* 2011;64(2):195-200.
10. Long Jr, RL. The Americleft Project: Experiences and Recommendations for Establishing Successful Inter-center Collaborative Outcome Study. (2010)
<https://static1.squarespace.com/static/5a8741a6c027d8435ad214c2/t/5a9dafa624a6949eb20e9e9a/1520283580634/americleft-Workbook.pdf>
11. Bergland O, Semb G, Abyholm F, Borchgrevink H, Eskeland G. Secondary bone grafting and orthodontic treatment in patients with bilateral complete clefts of the lip and palate. *Ann Plast Surg* 1986;17(6):460-474.
12. Russell K, Long RE Jr, Daskalogiannakis J, Mercado A, Hathaway R, Semb G, Shaw W. A multicenter study using the SWAG Scale to compare secondary alveolar bone graft outcomes for patients with cleft lip and palate. *Cleft Palate Craniofac J*. 2016;53(2):180-186.
13. Russell K, Long RE Jr, Daskalogiannakis J, Mercado A, Hathaway R, Semb G, Shaw W. Reliability of the SWAG – the standardized way to assess grafts method for alveolar bone grafting in patients with cleft lip and palate. *Cleft Palate Craniofac J* 2017;54(6):680-686.
14. Long Jr, Ross E, Shaw WC, Semb G: Eurocleft and Americleft Studies: Experiments in Intercenter and International Collaboration. In: Berkowitz S, ed. *Cleft Lip and Palate: Diagnosis and Management* (3rd Edition). Springer Berlin Heidelberg; 2012:Ch 47 (pp929-943).
15. Hathaway RR, Long Jr RE, Mercado AM, Daskalogiannakis J, Russell KA, Semb G, Shaw WC, Gregory J. The Americleft Project: use of a standardized outcome measure of dental arch relationships (Goslon) to allow international interstudy comparisons. Transactions of the 12th International Congress on Cleft Lip/Palate and Related Craniofacial Anomalies, Orlando, FL, May 5-10, 2013, Abstract 1560.
16. Long Jr RE, Hall T, Stauffer L, Daskalogiannakis J, Hathaway RR, Russell KA, Doucet JC, Mercado AM, Beals P, Beals S. An intercenter comparison of changes in UCLP dental arch relationship before

- and 10-Years after a change in a center's treatment protocol. Transactions of the 14th International Congress on Cleft Lip/Palate and Related Craniofacial Anomalies, Edinburgh, Scotland, July 11-15, 2022, Abstract 947.
17. Dabbagh W, Long R, Horst M, Daskalogiannakis J, Hathaway R, Russell K, Mercado A, Beals P, Weaver L, Doucet JC, Hall T, Beals S. Long-term changes in CUCLP nasolabial appearance ratings at 5, 8, and 11 years of age without secondary revision surgery. American Cleft Palate Craniofacial Association 75th Annual Meeting Abstracts, Abstract 205. *The Cleft Palate-Craniofacial Journal* 2018; 55(1S):1-123.
 18. Peanchitlertkajorn S, Mercado A, Daskalogiannakis J, Hathaway R, Russell K, Semb G, Shaw W, Lamichane M, Fessler, J, Long RE Jr. An intercenter comparison of dental arch relationships and craniofacial form including a center using nasoalveolar molding. *Cleft Palate Craniofac J* 2018;55(6):821-829.
 19. Peanchitlertkajorn S, Mercado A, Daskalogiannakis J, Hathaway R, Russell K, Semb G, Shaw W, Lamichane M, Cohen M, Long RE Jr. An intercenter comparison of nasolabial appearance including a center using nasoalveolar molding. *Cleft Palate Craniofac J* 2018;55(5):655-663.
 20. Conrad AL, Goodwin JW, Choi J, Block RI, Nopoulos P. The Relationship of exposure to anesthesia on outcomes in children with isolated oral clefts. *J Child Neurol* 2017;32(3):308-315.
 21. Lowry CH, Long RE, Russell K, Giltner JQ, Weaver L, Mercado AM, Beals S, Beals P, Daskalogiannakis J, Hathaway RR, Doucet JC, Semb G, Shaw WC. The effect of earlier bone grafting, prior to orthodontic treatment, on SWAG ratings of graft outcomes. *Cleft Palate Craniofac J* 2021;58(2):208-214.
 22. Long Jr RE: The Americleft Project: Comparing treatment outcomes for cleft lip and palate to identify evidence-based practices of importance to the orthodontist. *Practical Reviews in Orthodontics*, April, 2011. (Continuing education subscription service).
 23. Daskalogiannakis J Long Jr RE, Hathaway RR, Russell KA, Mercado AM, Semb G, Shaw WC. The Americleft Project: lessons learned from intercenter outcome assessments. Transactions of the 12th International Congress on Cleft Lip/Palate and Related Craniofacial Anomalies, Orlando, FL, May 5-10, 2013, Abstract 1301.
 24. Russell KA, Long Jr RE, Daskalogiannakis J, Mercado AM, Hathaway RR, Semb G, Shaw WC. The Americleft Project: alveolar bone graft outcome assessment: History, challenges, and a method developed to overcome these challenges. Transactions of the 12th International Congress on Cleft Lip/Palate and Related Craniofacial Anomalies, Orlando, FL, May 5-10, 2013, Abstract 1760.
 25. Daskalogiannakis J, Russell KA, Mercado AM, Hathaway RR, Singer E., Stoutland A, Long Jr RE, Semb G, Shaw WC. The Americleft Project: burden of care of various infant orthopedic protocols for improvement of nasolabial aesthetics in patients with CUCLP. Transactions of the 12th International Congress on Cleft Lip/Palate and Related Craniofacial Anomalies, Orlando, FL, May 5-10, 2013, Abstract 670.
 26. Long Jr RE, Mercado AM, Daskalogiannakis J, Hathaway RR Russell KA, Stoutland A, Singer E, Semb G, Shaw WC, Gregory J. The Americleft Project: a modification of Asher-McDade method for rating nasolabial esthetics in patients with CUCLP. Transactions of the 12th International Congress on Cleft Lip/Palate and Related Craniofacial Anomalies, Orlando, FL, May 5-10, 2013, Abstract 1195.
 27. Mercado AM, Russell KA, Daskalogiannakis J, Hathaway RR, Long Jr RE, Semb G, Shaw WC, Ozawa T, Smith A, Lin AY, Gregory J. The Americleft Project: a proposed expanded nasolabial appearance yardstick of 5-year old patients with CUCLP. Transactions of the 12th International Congress on Cleft Lip/Palate and Related Craniofacial Anomalies, Orlando, FL, May 5-10, 2013, Abstract 1774.
 28. Hathaway RR, Long RE Jr. Early cleft management: in search of evidence. *Am J Orthod Dentofacial Orthop* 2014;145(2):135-141.

29. Sitzman TJ, Mara CA, Long RE Jr, Daskalogiannakis J, Russell KA, Mercado AM, Hathaway RR, Carle AC, Semb G, Shaw WC. The Americleft Project: burden of care from secondary surgery. *Plast Reconstr Surg Global Open* 2015;3(7):e442.
30. Baylis, A., Chapman, K., Whitehill, TL; The Americleft Speech Group. Validity and reliability of visual analog scaling for assessment of hypernasality and audible nasal emission in children with repaired cleft palate. *Cleft Palate Craniofac J* 2015;52(6):660–670.
31. Ruppel JK, Long RE Jr, Oliver DR, Semb G, Russell KA, Mercado AM, Daskalogiannakis J, Hathaway RR. The Americleft Project: A comparison of short and long-term secondary alveolar bone graft outcomes in two centers using the standardized way to assess grafts scale. *Cleft Palate Craniofac J* 2016;53(5):508-515.
32. Chapman KL, Baylis A, Trost-Cardamone J, Cordero K., Dixon AJ, Dobbelsteyn C, Thurmes A, Wilson K, Harding-Bell A, Sweeney T, Stoddard G, Sell D. The Americleft Speech Project: a training and reliability study. *Cleft Palate-Craniofac J* 2016;53(1):93–108.
33. Mercado AM, Russell KA, Daskalogiannakis J, Hathaway RR, Semb G, Ozawa T, Smith A, Lin A. The Americleft Project: a proposed expanded nasolabial appearance yardstick for 5- to 7-year old patients with CUCLP. *Cleft Palate Craniofac J* 2016;53(1):30-37.
34. Stoutland A, Long RE Jr, Mercado A, Daskalogiannakis J, Hathaway RR, Russell KA, Singer E, Semb G, Shaw WC. The Americleft Project: a modification of Asher-McDade method for rating nasolabial esthetics in patients with unilateral cleft lip and palate using Q-sorT. *J of Craniofac Surg* 2017;28(8):1911-1917.
35. Long RE Jr, Daskalogiannakis J, Mercado AM, Hathaway RR, Fessler J, Russell KA. The Americleft Project: plaster dental casts versus digital images for GOSLON Yardstick ratings when used in intercenter comparisons. *J of Craniofac Surg* 2017;28(5):1269-1273.
36. Jones CM, Roth B, Mercado AM, Russell, KA, Daskalogiannakis D, Samson TD, Hathaway RR, Semb G, Smith A, Makay DR, Long RE Jr. The Americleft Project: comparison of ratings using 2D vs. 3D images for evaluation of nasolabial appearance in patients with unilateral cleft lip and palate. *J Craniofac Surg* 2018;29(1):105-108.
37. Kornbluth M, Campbell R, Daskalogiannakis J, Ross E, Glick PH, Russell KA, Doucet JC, Hathaway RR, Long Jr RE, Sitzman TJ. Active Presurgical Infant Orthopedics for Unilateral Cleft Lip and Palate: Intercenter Outcome Comparison of Latham, Modified Mc Neil, and Nasoalveolar Molding. *Cleft Palate Craniofac J* 2018;55:639-648.
38. Sitzman TJ, Allori AC, Matic DB, Beals SP, Fisher DM, Samson TD, Marcus JR, Tse RW; The Americleft Task Force Surgeon Subgroup. Reliability of oronasal fistula classification. *Cleft Palate Craniofac J* 2018;55(6):871-875.
39. Singer E, Daskalogiannakis J, Russell KA, Mercado AM, Hathaway RR, Stoutland A, Long RE Jr, Fessler J, Semb G, Shaw WC. Burden of care of various infant orthopedic protocols for improvement of nasolabial esthetics in patients with CUCLP. *Cleft Palate Craniofac J* 2018; 55(9):1236-1243.
40. Doucet JC, Russell KA, Daskalogiannakis J, Mercado AM, Emanuele N, James L, Hathaway RR, Long RE Jr. Facial growth of patients with complete unilateral cleft lip and palate treated with alveolar bone grafting at 6 years. *Cleft Palate Craniofac J* 2019;56(5):619-627.
41. Doucet JC, Russell KA, Daskalogiannakis J, Mercado AM, Hathaway RR, Semb G, Shaw WC, Long RE Jr. Early secondary alveolar bone grafting and facial growth of patients with complete unilateral cleft lip and palate. *Cleft Palate Craniofac J* 2023;60(6):734-741.
42. Briss DS, Long Jr R, Peterman JB, Doucet JC, Daskalogiannakis J, Hathaway RR, Mercado AM, Russell K, Stauffer L. Evaluating SWAG and its validity when compared to 3D imagery of secondary sites. *Cleft Palate Craniofac J* 2023:(Online ahead of print). PMID: 37844606 DOI: 10.1177/10556656231207570.

43. Long Jr RE. Standardized Diagnostic Records in Cleft and Craniofacial Orthodontics. In: Sheyte P and Gibson T, eds. Cleft and Craniofacial Orthodontics. Hoboken, NJ: Wiley; 2023: Ch 43 (pp583-592).
44. Long RE Jr, Hathaway RR. Practice-based evidence from comparative effectiveness research to inform evidence-based practice. Cleft Palate Craniofac J. 2023. PMID: 37649309 DOI: 10.1177/10556656231198661. Online ahead of print.
45. Chapman, K, Kean JT. A comparative effectiveness study of speech and surgical treatments using a Cleft Palate Registry/Research Outcomes Network. <https://grantome.com/grant/NIH/R01-DE027493-01>

INNOVATIONS IN CRANIOFACIAL CARE: A FUTURE WITH INTRA-ORAL ULTRASOUND?

*Marilia Yatabe, Fabiana Soki, Hsun-Liang Chan, Jade Cook,
Jennifer Xu, Oliver Kripfgans*

ABSTRACT

Intra-oral ultrasound is a novel diagnostic imaging tool developed to overcome the challenges of using a traditional-sized transducer, which does not allow direct application of ultrasound in the intra-oral cavity. It enables the user to assess oral structures including soft tissue, blood vessels, and the mineralized surfaces of teeth and bone, while maintaining the main advantage of the ultrasound, the use of non-ionizing radiation with direct imaging of structures of interest. This chapter reviews the literature regarding the use of ultrasonography and intra-oral ultrasonography, within the different specialties in dentistry, and proposes the future use of high-resolution intra-oral ultrasonography in orthodontics and craniofacial care.

KEY WORDS: Ultrasound, Dental, Imaging.

INTRODUCTION

Imaging in modern dentistry is mostly conducted using intra-oral radiography, as this technique has been clinically accepted, and often provides sufficient diagnostic yield. Specific treatment modalities in orthodontics and oral surgery may require additional extra-oral radiographs, such as panoramic x-rays and/or lateral cephalograms to aid in the clinical decision. These two-dimensional (2D) radiographs provide a larger overview of the maxillofacial complex and can provide adequate diagnostic information. However, the fact that a 2D imaging modality is representing a three-dimensional (3D) structure leads to some distortions and/or superimpositions. To overcome this difficulty, a cone beam computed tomography (CBCT) exam provides 3D images and is extremely valuable, especially if the interest is in hard tissues, such as teeth and bone. The disadvantage of x-rays and CBCTs is the radiation dose, which holds potential risks for the patient, especially with repeated uses on the same patients. In addition, the presence of metal structures, such as implants or orthodontic appliances, creates artifacts that can severely reduce the diagnostic value. Lastly, soft tissue contrast is inferior on CBCT, making soft tissue diagnosis very difficult, if not impossible.

Magnetic resonance imaging (MRI) and ultrasonography (US) are types of imaging modalities that do not use radiation. MRI can provide important information about hard tissue (e.g., bone) involvement in pathology that is mainly occupying soft tissue, while US is an economical imaging modality that can be used in a chairside setting in a dental office to investigate soft tissues in the head and neck region.

DIAGNOSTIC ULTRASONOGRAPHY

US is an imaging technique based on the propagation and reflection of ultrasound waves with frequencies equal to or above 20 kHz generated from electromechanical transducers using piezoelectric (and other) materials, which are coupled and transmitted into the human body. The depth of penetration depends on the frequency of the transducer used [1-3]. For a 30 MHz device, the penetration depth is approximately 10 mm, which is sufficient for most intra-oral indications.

The transducer includes an electrically stimulated piezoelectric crystal that converts high-frequency electrical impulses to high-frequency sound waves, which are transmitted into the tissues being examined (Figure 1). As this sound passes through tissues with different acoustic impedances (e.g., blood and muscle), part of it is reflected or scattered from within the medium while another part of it continues to penetrate and travel through the tissues. Some portion of the sound is lost to attenuation/absorption. Echo is the part of the sound wave that is reflected and scattered back toward the transducer. These echoes are collected by the transducer and reconverted into electrical pulses, amplified, processed, and displayed as grayscale images on a screen [2].

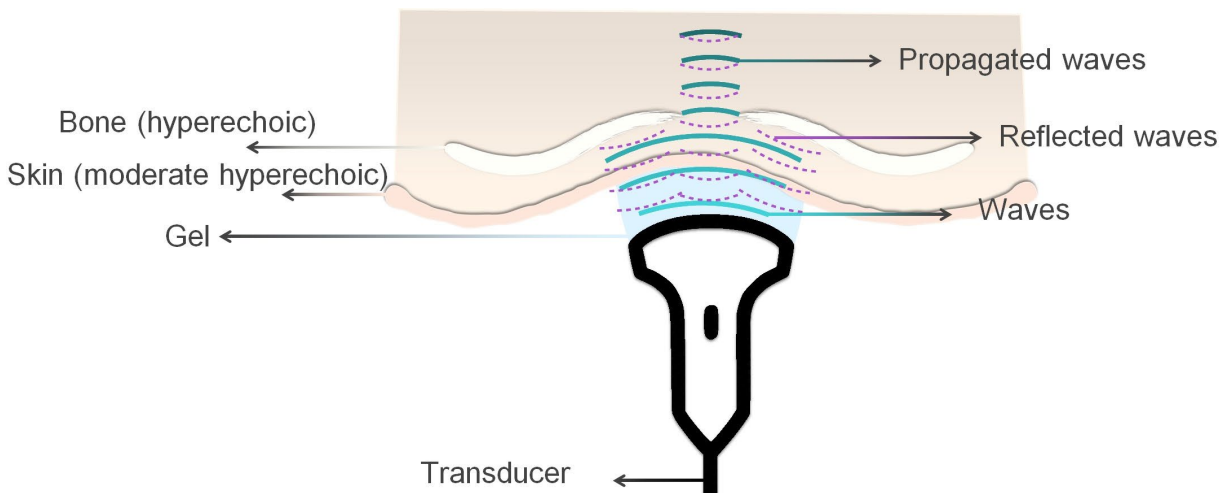


Figure 1. Schematic example of the transducer on the hard palate, the ultrasound waves (in green) and the reflection of the waves (in purple).

The propagation speed of the ultrasound wave in a liquid relies on the particle density and the bulk modulus of compression. As a first approximation, soft tissues can be considered as a viscous fluid. Because densities and compression modulus of most soft tissues are similar to that of water at 37°C, a mean propagation speed of 1540 m/s is assumed for the most common case of brightness modulated (B-mode) pulse-echo imaging [3]. Potential variations in speed of sound either due to the heterogeneous soft tissue distribution or even local temperature differences can cause distance measurement errors and refraction-based image distortion. More complex cases arise if hard tissues, like tooth and bone, are in the focus of interest [3]. There are ultrasound probes in different shapes and formats, which influence how the image will be generated and what penetration and receiver sensitivity are achievable.

The resulting image is a composite of different shades of gray. The brightness depends on the intensity of the received echoes, which in turn depends on the ability of a tissue or structure to reflect or scatter sound; this is known as echogenicity [2]. At the boundary between two distinct tissues of different acoustic impedances, sound is reflected. From those, the probe only captures the waves that are reflected

toward the aperture, then they are converted into radio frequency (RF) electric signals. This method is well known as pulse echo ultrasound [1, 3].

With diagnostic US, tissues are classified based on their echogenicity into four categories (Figure 2) [2]: hyperechoic or echogenic – highly reflective tissues (very bright), such as surface of the mucosa, osseous structures, or cartilage; moderately echogenic – (fairly bright), such as walls of glands and arteries; hypoechoic – (fairly dark), such as the walls of venous blood vessels and muscles; and anechoic – (very dark), such as fluids (ultrasound gel, urine, and blood). It must be noted that high frequency ultrasound can visualize blood in B-mode in veins, which is related to the Rouleaux effect of venous blood.

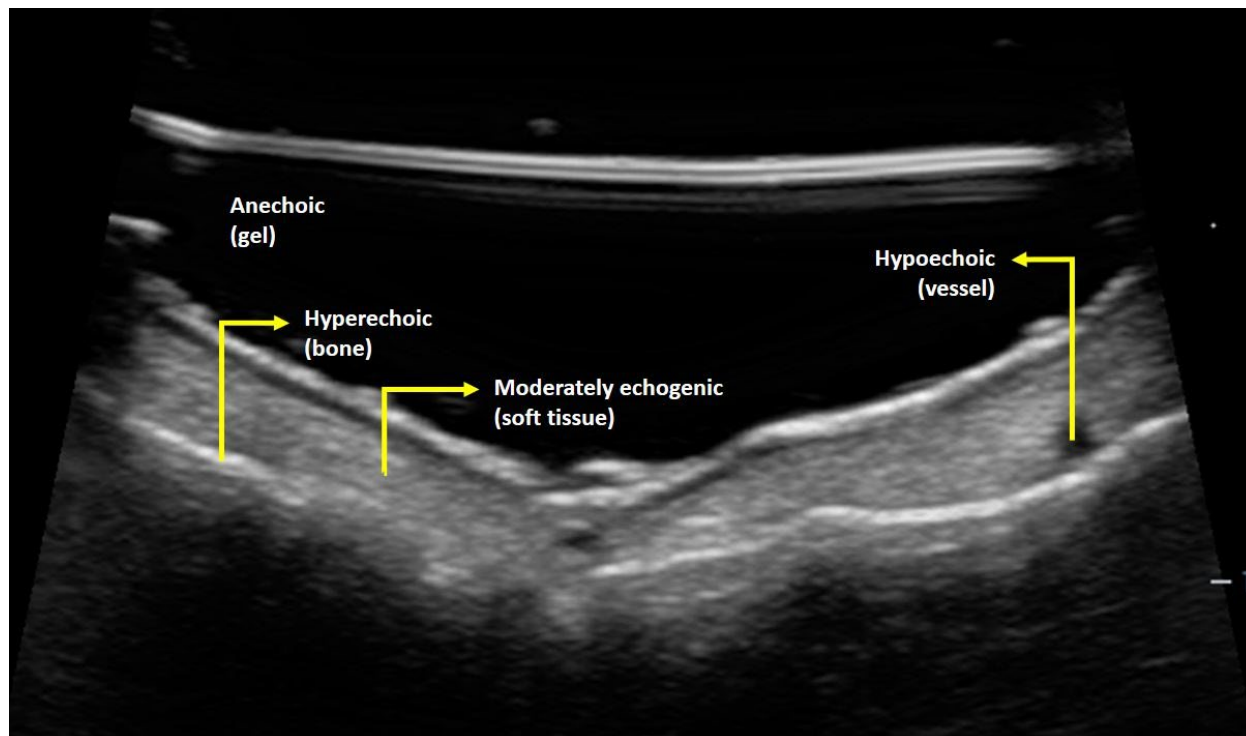


Figure 2. Examples of the different echogenicity found in the ultrasound image.

There are different image modalities that can be generated from the ultrasound. The literature suggests that the common modes used in dentistry are the A-mode, B-Mode, Color/Power modes, and pulse wave [2, 3].

The A-mode (amplitude) uses a single crystal to generate a one-dimensional (1D) image with the echo amplitude, which is displayed vertically, and the echo time, which is displayed horizontally. This mode is listed mostly for historic reasons.

The B-mode (brightness) generates 2D grayscale images, in which the degree of pixel brightness represents the backscattered (received) ultrasound echo in this location. B-mode images allow for visualization and quantification of spatial relations, including soft–hard tissue boundaries, various dental structures, and characterization of soft tissues because of backscatter changes (Figure 3). The lateral image dimension is defined by the probe width, and the vertical extension is defined by the selected image depth of field. Regarding the image orientation, most of the time the top of the image is located where

the source from which the ultrasound wave originates, i.e., a vertically mirrored image of the structure being scanned [1].

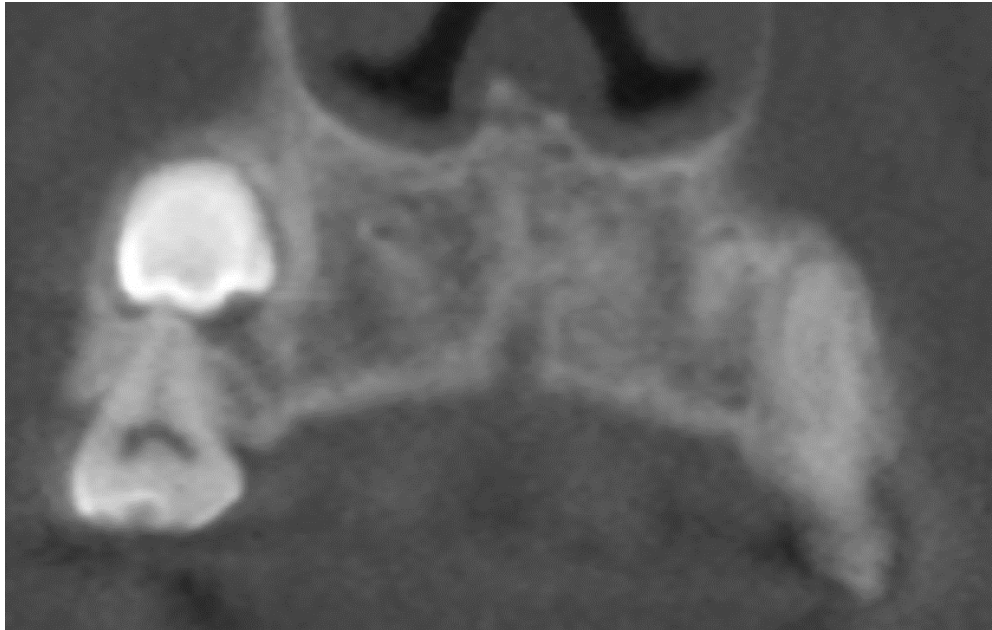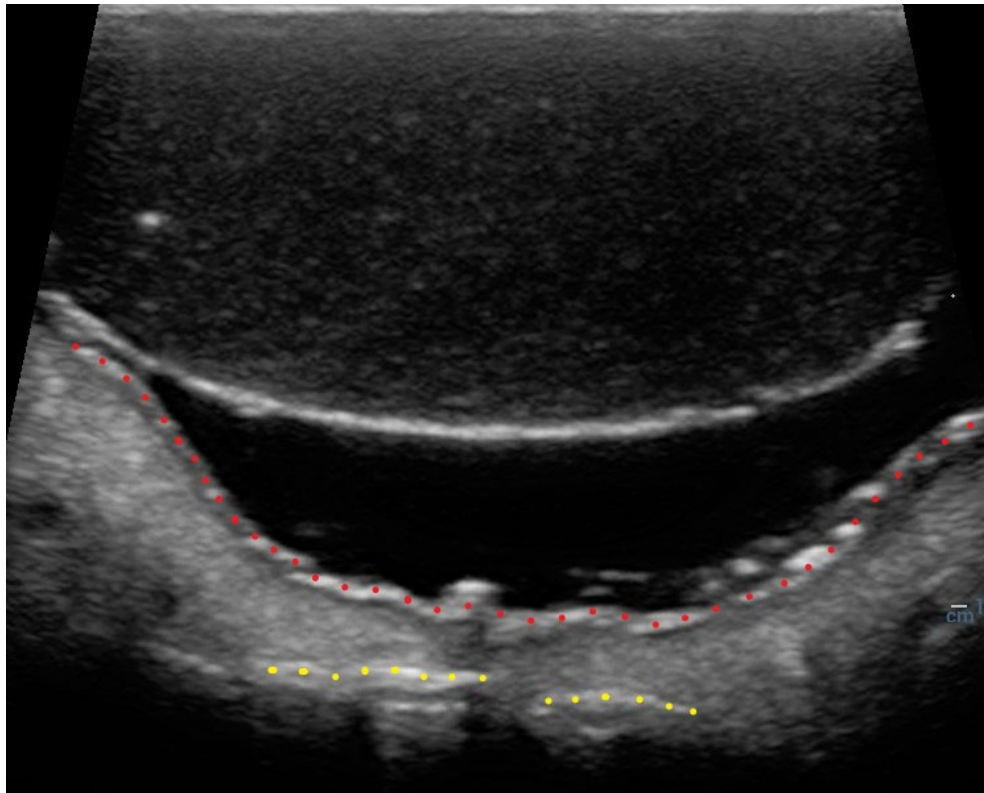
A**B**

Figure 3. Example of how the image of the ultrasound is rendered in the system. A) illustrates a coronal section of the palate originated from the CBCT, while B) illustrates a representation of the same structure mirrored vertically, originated from the intra-oral ultrasound. The yellow dots indicate the limits of the bone, while the red dots indicate the limits of the soft tissue.

Color Flow (Figure 4) enables display of the content and vascularization of lesions. It shows the mean velocity of moving tissues at a given time on a color scale, with red describing the flow toward the transducer and blue describing the flow away from the transducer.

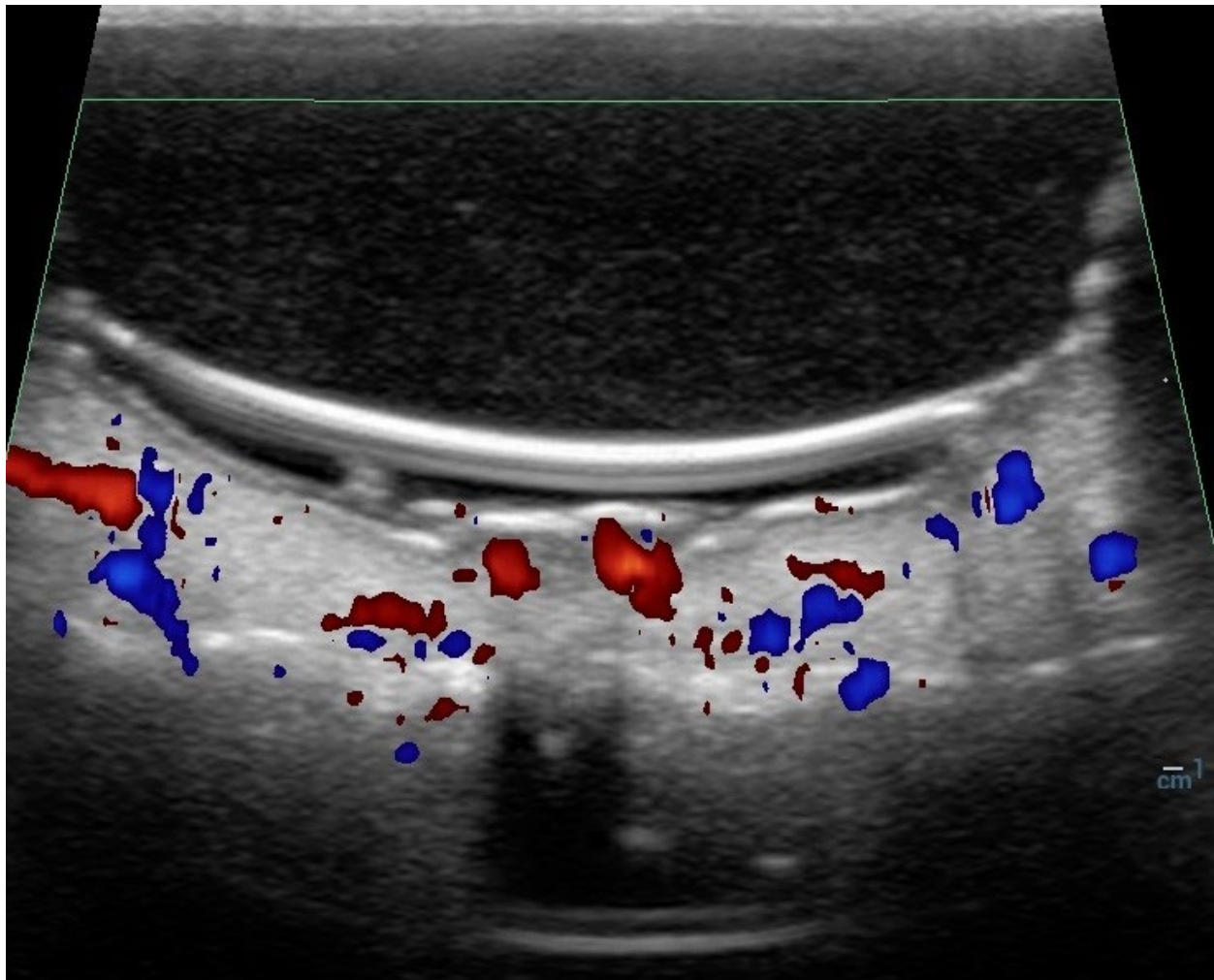


Figure 4. Illustration of the color mode during an ultrasound scan. The red color indicates the flow toward the transducer, while blue indicates the flow away from the transducer.

Power mode measures a quantity proportional to the number of moving blood cells in the sample volume and is sensitive for measuring the slower blood flow, e.g., flow in small vessels/capillaries [2].

From those generated images, there are two types of files that can be recorded and stored from the real-time imaging modality: single 2D images (print screens) or cine loops (videos), which means a temporal collection of consecutive still images [1]. The cine loops are especially useful when tracing or confirming an anatomical structure, e.g., an impacted tooth [1].

Well-known advantages of the US are that it is noninvasive, fast, cost-effective, painless, and reproducible; it provides real-time and simultaneous imaging of both soft tissue cross-sections and hard tissue surfaces; and it is easily tolerated by patients which makes it very interesting and capable of being used in all specialties [3-5]. One of the most striking features is the fact that it is non-ionizing, and therefore is ideally suited for longitudinal monitoring. US offers cross-sectional anatomical information,

which is desirable in dentistry which is currently not achievable with 2D radiographs. This dimension is becoming more important in the oral surgery field due to the need to know the soft-hard tissue dimensions/thickness and the healing status of the biomaterials placed underneath the mucosa for regenerative purposes. Another distinct advantage is the functional evaluation of tissues. Unlike radiographs, which show the anatomical alveolar bone changes due to various reasons (e.g., inflammatory periodontitis) but are unable to know the current disease activity, ultrasound can detect subclinical tissue qualitative changes and blood flow in soft tissues in approximation to the bone that is related to the current status and may predict future changes. The main disadvantage is its inability to penetrate (cortical) bone and other hard tissues [6].

ULTRASONOGRAPHY IN DENTISTRY

The term ultrasonography was first introduced to dentistry in 1954, when Drs. Oman and Applebaum suggested that it was a painless method for cavity preparation [7]. Later, in 1963, Baum and colleagues suggested a diagnostic use of the ultrasound: they used a 15 MHz transducer to display the interior structures (pulp chamber) of the anterior teeth. However, the quality and clarity of the resulting RF signal was not satisfactory. Since then, it has been utilized in diagnostic and therapeutic applications with mechanical vibration of dental tools, particularly in ultrasonic scalers, or piezoelectric surgery apparatuses [8].

Even though it has been suggested that linear array US probes are not designed for an intra-oral application [8], there is a wide variety of ultrasound usage in dentistry [2-6, 8-10], including diagnostic imaging and therapeutic US (listed below). Within the diagnostic capacity, US may not be able to replace the conventional radiographs for most purposes, but B-mode and color flow functionalities are straightforward and reproducible techniques that have the potential to supplement conventional radiography [10].

The literature has described different applications within the following specialties [2, 3, 6-10]:

- General dentistry: dental fractures, restorations faults, interproximal carious lesions, and treating cavities.
- Endodontics: pre- and post-endodontic treatments, assessment of pulpal blood flow.
- Oral medicine: location, assessment, and measurements of hard, soft, and vascular tissue lesions, guide fine-needle aspiration.
- Oral surgery: monitor healing and remodeling of bone wounds, measurement of osteotomy gaps, assessment of callus maturation, maxillofacial fractures, muscle thickness measurement, guide biopsies, injections, drains and shunts, assess bone microarchitecture, piezoelectric osteotomies, induce endochondral and intra-membranous ossification, assist in osteoclast proliferation and differentiation, increase vascular growth factors, accelerate soft and hard tissue healing, reduce swelling, anesthesia.
- Prosthodontics: measure enamel thickness.
- Periodontics: gingival thickness, measurement of periodontal defects and implant site assessment.
- Orthodontics: soft tissue thickness to select temporary anchorage device (TAD) height, midpalatal suture assessments, cephalometric measurement of soft tissue.
- Temporomandibular disorder (TMD): measure muscle thickness, visualize the temporomandibular joint (TMJ) and the abnormal position of the joint disk, guide arthrocentesis.

INTRA-ORAL ULTRASONOGRAPHY

In order to overcome the challenges of the extra-oral ultrasound and broaden the applicability of the ultrasound to dentistry, different intra-oral prototype probes have been suggested. The goal is that the probe would be small enough to allow a full assessment of the oral mucosa and periodontium.

The first description of an intra-oral ultrasound, in 2012, suggested a small intra-oral probe the size of a dental high speed, which showed excellent feasibility and accuracy. However, this probe was unable to provide color flow information for the blood flow and a coupling device such as an ultrasonic gel pad was added to increase the contact between probe and tissue [11].

More recently, a high-resolution (8 to 30 MHz), toothbrush sized (~30 x 18 x 12 mm) probe (Figure 5) co-developed between the University of Michigan and Mindray of North America, demonstrated a high correlation between the ultrasound, clinical, and radiological measurements [12, 13]. It has been suggested to be a valid tool for periodontal, palatal soft tissue thickness, and implant assessment. This probe has been thoroughly studied in the periodontal field and has shown good accuracy and reproducibility compared to histology or CBCT [14, 15]. In addition, it provides color flow and color power, which allows for assessment of blood flow. The intra-oral ultrasound function allows for the highest resolution images (highest frequency, depth of field to 15 mm), so that even submillimeter structures can be visualized [1].



Figure 5. A) Illustration of the intra-oral ultrasound probe in a lateral view, and B) in a superior view. The arrows indicate where the sound waves are emitted from.

Considering that volumetric blood-flow imaging is an official biomarker of the Quantitative Imaging Biomarkers Alliance [1], it is valuable to be able to visualize and quantify blood flow using ultrasound. Color is an imaging mode in which blood flow is superimposed onto B-mode anatomy. Color flow usually indicates direction (toward and from the ultrasound transducer) and the velocity magnitude of blood flow. Direction is indicated by using two distinct colors, such as red and blue. Velocity magnitude is indicated by the shade of the color. Color power displays the strength/intensity of how much blood is contributing to each voxel. For example, bright yellow, on a scale from black to red, to orange, to yellow, means that the entire voxel is filled with moving blood [15]. The signal is quantifiable, and its increase indicates higher blood flow, which may suggest inflammation [1]. It must be noted that only blood flow with a directional component to or from the ultrasound transducer is registered. Velocity components that are perpendicular to this direction are not seen. Also, it must be noted that 2D visualization and quantification of blood flow as described here and referred to in the listed literature is relying on surrogate quantities. True blood flow in volume per time, e.g., milliliters per minute, is not measured. It can be measured but it requires 3D ultrasound [16].

Some of the clinical relevance of being able to visualize the blood flow is the fact that it could possibly detect subclinical inflammation before bone loss occurs [1]. The advantages for the intra-oral ultrasound are as follows: real-time cross-sectional imaging modality, capable of changing direction and angulation, portability, cost-efficiency, and the direct interaction of the examiner with the patient [13, 17]. On the other side, some of the known limitations of the ultrasound are the need of using a coupling medium, inability to penetrate bone, a narrow field of view, image quality is operator dependent, and the considerable learning curve of this methodology [1, 12]. In regard to the learning curve, a recent study suggested that with training and practice over a few weeks, a good level of agreement can be achieved among ultrasound-unaccustomed providers [14].

INTRA-ORAL ULTRASONOGRAPHY IN DENTISTRY

The literature has suggested that intra-oral US was primarily designed for soft tissue evaluation, e.g., measuring the soft tissue in the oral cavity, evaluating soft tissue lesions, and gingival thickness after grafting procedures [18]. More recently, it has been suggested that a high-resolution (8-30 MHz) intra-oral US can complement conventional radiographs because it is able to assess the hard tissue, for example the buccal alveolar bone crest height (including after surgical procedures) as opposed to flap elevation, with the main disadvantage being that the ultrasound is not able to transmit through the bone [12, 19, 20].

The validity of measuring the soft tissue thickness also extends to orthodontics, when determining the proper miniscrew height. Attempts to evaluate it were proposed using a specific “ultrasonic gingival thickness meter” suggested in 1971 [21, 22]. This device works by measuring the time between when an ultrasonic wave is emitted, when it has passed through the oral mucosa, and is reflected from the bone surface. The meter’s monitor displays the soft-tissue thickness [23].

Using a linear array transducer US with B-mode, previous studies have suggested measuring the soft tissue thickness of cephalometric points (N, A, and B), as well as the ANB angle when compared to regular lateral cephalograms [9], or assessing the midpalatal suture prior to and during the palatal expansion by scanning the buccal alveolar bone of the upper central incisors [5]. It was suggested that ultrasound can provide accurate information of bone fill in the distraction area during the surgical assisted rapid palatal expansion (SARPE) expansion in adult patients.

Other potential applications of high-resolution intra-oral ultrasound (HR-IOUS) suggested by our team include locating the impacted teeth and assessing bone prior to orthodontic movement in extracted teeth cases or edentulous sites with questionable bone quantity. Preliminary assessment suggests that the HR-IOUS can locate impacted teeth independently from clinical visualization, when they are in close proximity to the buccal or lingual cortices, which are thinned and slightly expanded. In relation to patients with cleft lip, cleft palate, and/or craniofacial anomalies, based on the literature and its potential, it can be suggested that the HR-IOUS may provide valuable information. For instance, HR-IOUS has the ability to quantify visible blood vessel density. Its increase indicates higher blood volume, which may suggest inflammation [1]. It can also reveal the progressive formation of new vessels in bone during the initial healing period, which might relate to the course of healing and its outcome [15], even before visible bone formation. In addition, it may be more effective in assessing bone micro-architecture, the onset of bone formation, and the surface topography of the new bone [5, 8, 10]. HR-IOUS may be used to assess the blood flow/inflammation during bone formation after alveolar bone graft surgery.

Another possible advantage is how color power scan displays the blood flow strength, which is particularly useful for small vessels and those with low-velocity flow. During the treatment planning phase, knowledge of soft/hard tissue dimensions, tissue phenotype, relationship to vital structures, and bone density measurement is a pre-requisite for successful surgeries [1, 10]. Therefore, a potential application of HR-IOUS as a tool to assess blood flow in the premaxilla region and its surroundings to aid in pre-surgical planning of osteotomy to avoid possible necrosis of the premaxilla.

Other clinical uses can include follow-up of distraction osteogenesis to evaluate precise measurement of the gap between the bone edges and early detection of ossification within the new bone, therefore achieving accurate and noninvasive evaluation of the rate and quality of callus formation [5, 24]. HR-IOUS also can be applied to assess callus maturity during mandibular distraction.

CONCLUSIONS

In this chapter, we focused on the applicability of the diagnostic use of intra-oral ultrasound. It can be concluded that even though we are still at the initial phase of determining the applicability of HR-IOUS to our clinical practice, HR-IOUS has shown promising results in assessing the bone surfaces and blood supply in the oral cavity, thus complementing the current imaging modalities available for diagnostic and treatment plan purposes. Further research should be conducted to determine its accuracy and in the different aspects, not only to orthodontics, but also to other specialties.

REFERENCES

1. Chan HL, Kripfgans OD. Ultrasonography for diagnosis of peri-implant diseases and conditions: a detailed scanning protocol and case demonstration. *Dentomaxillofac Radiol* 2020; 49(7):20190445.
2. Demirturk Kocasarac H, Angelopoulos C. Ultrasound in dentistry: toward a future of radiation-free imaging. *Dent Clin North Am* 2018; 62(3):481-489.
3. Marotti J, Heger S, Tinschert J, Tortamano P, Chuembou F, Radermacher K, Wolfart S. Recent advances of ultrasound imaging in dentistry--a review of the literature. *Oral Surg Oral Med Oral Pathol Oral Radiol* 2013; 115(6):819-832.
4. Gumussoy I, Miloglu O, Bayrakdar IS, Dagistan S, Caglayan F. Ultrasonography in the evaluation of the mid-palatal suture in rapid palatal expansion. *Dentomaxillofac Radiol* 2014; 43(8):20140167.

5. Sumer AP, Ozer M, Sumer M, Danaci M, Tokalak F, Telcioglu NT. Ultrasonography in the evaluation of midpalatal suture in surgically assisted rapid maxillary expansion. *J Craniofac Surg* 2012; 23(5):1375-1377.
6. Isfeld D, Lagravere M, Leon-Salazar V, Flores-Mir C. Novel methodologies and technologies to assess mid-palatal suture maturation: a systematic review. *Head Face Med* 2017; 13(1):13.
7. Lefkowitz W: Ultrasonics in dentistry. *J Am Dent Assoc* 1956; 52(4):406-409.
8. Elbarbary M, Sgro A, Khazaei S, Goldberg M, Tenenbaum HC, Azarpazhooh A. The applications of ultrasound, and ultrasonography in dentistry: a scoping review of the literature. *Clin Oral Investig* 2022; 26(3):2299-2316.
9. Di Blasio A, Di Blasio C, Pedrazzi G, Cassi D, Magnifico M, Manfredi E, Gandolfini M. Combined photographic and ultrasonographic measurement of the ANB angle: a pilot study. *Oral Radiol* 2017; 33(3):212-218.
10. Tikku AP, Kumar S, Loomba K, Chandra A, Verma P, Aggarwal R. Use of ultrasound, color Doppler imaging and radiography to monitor periapical healing after endodontic surgery. *J Oral Sci* 2010; 52(3):411-416.
11. Salmon B, Le Denmat D. Intraoral ultrasonography: development of a specific high-frequency probe and clinical pilot study. *Clin Oral Investig* 2012; 16(2):643-649.
12. Chan HL, Sinjab K, Li J, Chen Z, Wang HL, Kripfgans OD. Ultrasonography for noninvasive and real-time evaluation of peri-implant tissue dimensions. *J Clin Periodontol* 2018; 45(8):986-995.
13. Thöne-Mühling M, Kripfgans OD, Mengel R. Ultrasonography for noninvasive and real-time evaluation of peri-implant soft and hard tissue: a case series. *Int J Implant Dent* 2021; 7(1):95.
14. Majzoub J, Tavelli L, Barootchi S, Salami A, Inglehart MR, Kripfgans OD, Chan HL. Agreement in measurements of ultrasonography-derived periodontal diagnostic parameters among multiple raters: a diagnostic accuracy study. *Oral Surg Oral Med Oral Pathol Oral Radiol* 2022; 134(3):375-385.
15. Tavelli L, Barootchi S, Majzoub J, Chan HL, Giannobile WV, Wang HL, Kripfgans OD. Ultrasonographic tissue perfusion analysis at implant and palatal donor sites following soft tissue augmentation: a clinical pilot study. *J Clin Periodontol* 2021; 48(4):602-614.
16. Kripfgans OD, Rubin JM, Hall AL, Gordon MB, Fowlkes JB. Measurement of volumetric flow. *J Ultrasound Med* 2006; 25(10):1305-1311.
17. Siqueira R, Sinjab K, Pan YC, Soki F, Chan HL, Kripfgans O. Comprehensive peri-implant tissue evaluation with ultrasonography and cone-beam computed tomography: a pilot study. *Clin Oral Implants Res* 2021; 32(7):777-785.
18. Rodriguez Betancourt A, Samal A, Chan HL, Kripfgans OD. Overview of ultrasound in dentistry for advancing research methodology and patient care quality with emphasis on periodontal/peri-implant applications. *Z Med Phys* 2023;33(3):336-386.
19. Chan HL, Sinjab K, Chung MP, Chiang YC, Wang HL, Giannobile WV, Kripfgans OD. Non-invasive evaluation of facial crestal bone with ultrasonography. *PLoS One* 2017; 12(2):e0171237.
20. Sinjab K, Kripfgans OD, Ou A, Chan HL. Ultrasonographic evaluation of edentulous crestal bone topography: a proof-of-principle retrospective study. *Oral Surg Oral Med Oral Pathol Oral Radiol* 2022;133(1):110-117.
21. Eger T, Muller HP, Heinecke A. Ultrasonic determination of gingival thickness. Subject variation and influence of tooth type and clinical features. *J Clin Periodontol* 1996; 23(9):839-845.
22. Müller HP, Barrieshi-Nusair KM, Kononen E. Repeatability of ultrasonic determination of gingival thickness. *Clin Oral Investig* 2007; 11(4):439-442.
23. Cha BK, Lee YH, Lee NK, Choi DS, Baek SH. Soft tissue thickness for placement of an orthodontic miniscrew using an ultrasonic device. *Angle Orthod* 2008; 78(3):403-408.

24. Bruno C, Minniti S, Buttura-da-Prato E, Albanese M, Nocini PF, Pozzi-Mucelli R. Gray-scale ultrasonography in the evaluation of bone callus in distraction osteogenesis of the mandible: initial findings. *Eur Radiol* 2008; 18(5):1012-1017.

THE IMPACT OF 3D IMAGING ON ORTHODONTICS

Lucia Cevidaneş, Felicia Miranda, Selene Barone, Aron Aliaga, Marilia Yatabe, Antonio Ruellas, Marcela Gurgel, Najla Al Turkestani, Luc Anchling, Yanjie Huang, Nathan Hutin, Maxime Gillot, Baptiste Baquero, Hina Shah, Juan Prieto, Jonas Bianchi

ABSTRACT

Objective: This manuscript elucidates recent advancements in the realm of imaging analysis tools within orthodontics, where artificial intelligence (AI) has been seamlessly integrated. Additionally, it offers a step-by-step guide for conducting imaging analysis in orthodontics using AI-based tools available through open-source platforms. **Three-dimensional (3D) Imaging Methods and Results:** The process of orthodontic diagnosis and treatment planning involves the aggregation of diverse records. Notably, the latest progress highlights the assimilation of AI tools for the comprehensive analysis of lateral cephalograms, panoramic radiographs, facial and intra-oral photographs, cone beam computed tomography (CBCT), and digital dental models (DDMs). These AI-driven tools substantially refine the imaging analysis workflow, automating tasks like precise orientation, skeletal structure segmentation, tooth segmentation, as well as identification and registration of landmarks. Across various orthodontic tools, AI models are undergoing training and assessment, consistently demonstrating remarkable accuracy, and significantly reducing the time traditionally required for manual evaluations. The rapid proliferation of AI technology within orthodontic clinical practices accentuates the importance for clinicians and researchers to proactively familiarize themselves with these innovative methodologies. **Conclusions:** Diagnostic image analysis for clinical practice and research applications in orthodontics was significantly changed with the implementation of AI models. Satisfactory outcomes are being observed with the novel tools, however continuous training and validation are necessary for improving the performance and generalizability of these methods.

KEY WORDS: Orthodontics, Imaging, Three-dimensional, Artificial Intelligence

INTRODUCTION

Digital evolution in orthodontics and the role of AI

In recent years, the field of dentistry has undergone a notable digital transformation, resulting in a surge of technological advancements. With the collection of data from diverse sources such as clinical records, remote monitoring, photographs, lateral cephalograms, panoramic radiographs, and three-dimensional (3D) imaging, including cone beam computed tomography (CBCT) and digital dental models (DDMs), the integration of digital technologies in orthodontics has become increasingly essential [1]. Furthermore, the emergence of artificial intelligence (AI) tools and machine learning methods has opened up new avenues for handling data, facilitating integration, processing information, and enabling visualization within the realm of orthodontics [2-4]. These technological innovations have led to improvements in various aspects of orthodontics, including diagnosis, treatment planning, and assessment of treatment progress and outcomes. AI tools are now demonstrating significant potential in enhancing the accuracy and efficiency of orthodontic procedures. However, it is important to note that these advancements, while promising, still require

careful clinician oversight to ensure accurate and precise healthcare decision-making. As such, it is imperative for clinicians and researchers alike to familiarize themselves with these AI-driven approaches to orthodontic imaging tools. Image analysis and digital diagnosis in orthodontics draw from diverse data sources, including clinical examinations, 2D (two-dimensional) or 3D photographs, remote monitoring, lateral cephalograms, panoramic X-rays, CBCT, computed tomography (CT), magnetic resonance imaging (MRI), and DDMs.

Impact of AI on conventional orthodontic records

Among conventional orthodontic records, lateral cephalograms hold a pivotal role as a fundamental diagnostic tool, facilitating the assessment of maxillomandibular relationships and dentoskeletal characteristics such as the position of the lower incisors in the symphysis [5]. Within the orthodontic literature, a number of cephalometric analyses have been used, aimed at pinpointing specific anatomical landmarks and quantifying distances, angles, and ratios to delineate dentoskeletal attributes. Recent advancements have demonstrated the integration of AI tools in the process of landmark identification during cephalometric tracing [5-7]. Leveraging AI during this tracing process offers the advantage of saving time and mitigating both systematic and random subjective errors. Regarding the placement of landmarks, the application of AI in a dataset of 400 to 500 lateral cephalograms showcased satisfactory accuracy in positioning landmarks, with precision ranging from 88.43% to 92% [8, 9]. While AI-driven tools exhibit high precision in calculating cephalometric outcomes, it remains essential for orthodontic specialists to verify the positioning of each landmark subsequent to automatic identification [5, 10].

The initial radiographic exam for orthodontic care is determined by clinical findings that indicate a deviation from normal dental and craniofacial growth and development, as well as the patient's medical history. Panoramic radiography is regarded as a valuable imaging technique in orthodontics due to its potential to enhance dental screening and contribute to clinical decision-making [7, 11]. Given its 2D nature, panoramic images can present complexities in analysis due to the wealth of information contained and the overlapping of various anatomical structures that can impact image quality. Consequently, the integration of AI is being embraced for the interpretation of panoramic radiographs, providing support to dental practitioners [12]. A range of distinct AI models are under development to facilitate the analysis of panoramic radiographs. These models encompass tasks such as identifying specific anatomical structures including teeth and condyles, detecting pathological conditions such as caries, periapical lesions, bone loss, and osteoporosis, as well as segmenting and classifying anatomical structures or pathological anomalies [7, 11, 13]. Moreover, AI holds potential for forensic applications in this context. Encouragingly, promising outcomes have been reported for the application of automated models in panoramic radiograph analysis, boasting accuracy rates of 97% for teeth identification and 87% for teeth classification [14, 15].

Additional patient records commonly employed in orthodontics for diagnosis and treatment monitoring encompass facial and intra-oral photography. Utilizing AI tools, facial photograph analysis has been explored to assess post-treatment facial attractiveness, classify clinical images, and gauge treatment requirements [16-19]. Within this context, a convolutional neural network (CNN) algorithm was employed to predict the apparent age and facial attractiveness of patients who underwent orthognathic treatment [18]. The algorithm's projections indicated that orthognathic patients appeared 1.75 years older than their biological age in pre-treatment photographs and 0.82 years older in post-treatment photographs [18]. The subjective nature of facial attractiveness prediction by a trained algorithm remains a matter of inquiry, introducing questions regarding its reliability and accuracy.

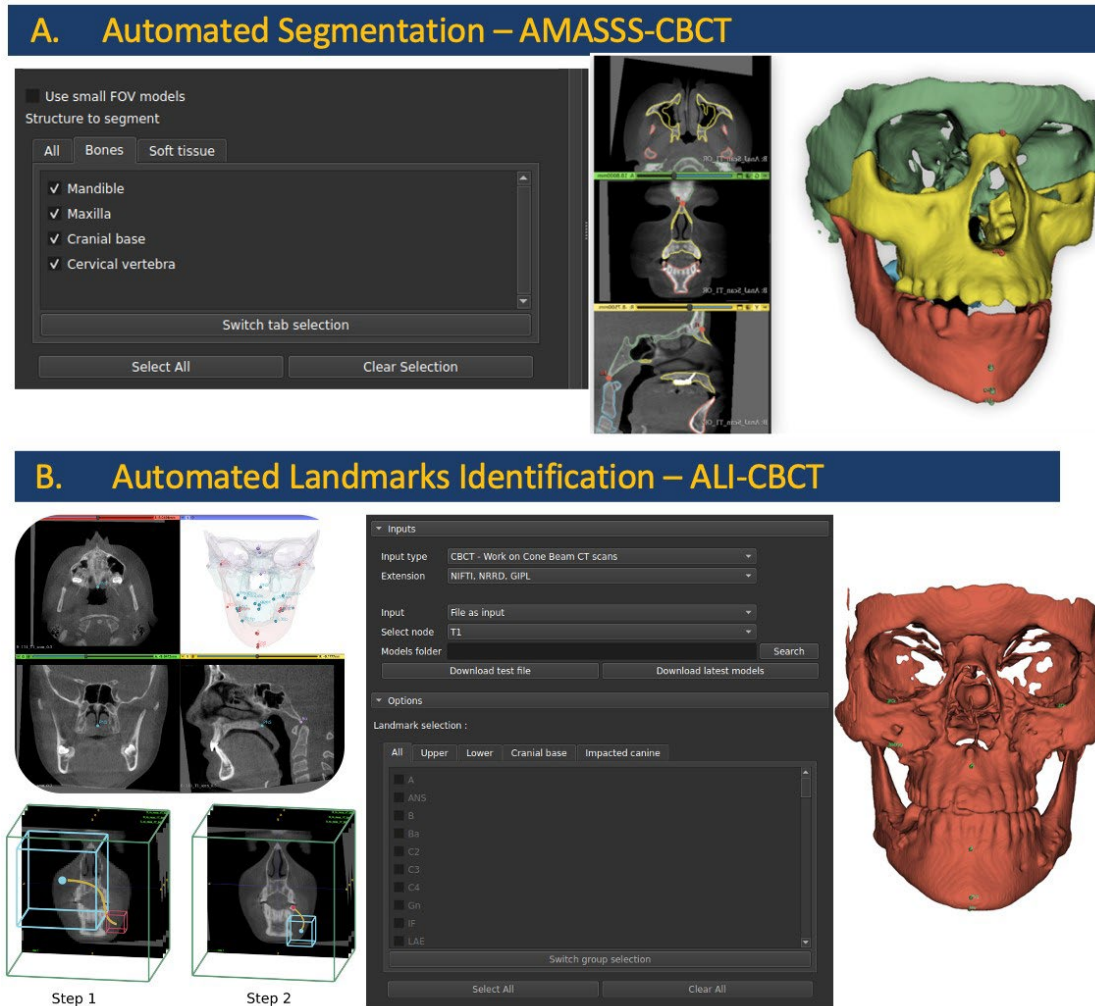


Figure 1. A) 3D surface models generated from 3D volumetric label maps using the AMASSS module of the 3D Slicer software. B) Automatic landmark identification performed with the ALICBCT module of the 3D Slicer software.

Impact of AI on 3D orthodontic records

A significant surge of interest in developing AI tools for conducting 3D assessments of CBCT scans has been observed in the realm of orthodontics. This heightened focus stems from the recognition that CBCT imaging analysis presents even greater intricacies and time demands compared to conventional 2D X-rays. The 3D models reconstructed from CBCT scans offer a platform for both visual and quantitative evaluations of comprehensive anatomical surfaces (Figure 1A). Nonetheless, the manual segmentation of craniofacial structures poses a formidable and time-intensive challenge within the CBCT imaging analysis workflow. Recent endeavors have given rise to studies introducing automated methodologies for segmenting maxillo-mandibular structures within CBCT scans, leveraging the power of AI tools [20-24]. These AI-based approaches have demonstrated notable consistency with manually segmented models, while concurrently reducing the time investment required, ranging from 13.7 seconds to 20 minutes for different cases. Furthermore, a recent study devised a novel open-source technique for automatic segmentation, using a dataset of 618 CBCT images to both assess and train the AI model. Impressively, this approach achieved a rapid execution time of approximately 24 seconds per scan, coupled with an impressive Dice coefficient of 0.96, signaling remarkable progress facilitated by AI integration [25]. The Dice coefficient is a metric used to measure the similarity between two sets. The Dice coefficient ranges from 0 to 1, where 0 indicates no overlap (completely dissimilar sets), and 1 indicates complete overlap (identical sets). It is a

measure of the similarity or agreement between two sets, and it is particularly useful when dealing with imbalanced datasets. In applications like image segmentation, the Dice coefficient is often used to assess the accuracy of the segmentation algorithm by comparing the predicted segmentation mask with the ground truth mask.

The infusion of AI tools has markedly advanced the realm of automatic segmentation for craniofacial structures, leading to heightened levels of accuracy and improved temporal efficiency. Equally pivotal within the domain of 3D CBCT imaging analysis is the identification of manual landmarks. Errors in the manual identification of landmarks in CBCT can fluctuate between 0.1 to 4 mm, contingent on the specific anatomical structure in question [26]. In response, AI and machine learning methodologies have been harnessed to automatically determine landmark positions within CBCT scans [27, 28]. A previous study evaluated an automated landmark identification (ALI) method in CBCT, involving a dataset of 100 CBCT scans encompassing 53 landmarks within distinct craniofacial structures [27]. The findings indicated an average error distance of 3.19 mm (SD 2.6) between the automated approach and manual identification. Subsequently, a recent study introduced an open-source AI model coined "ALICBCT" for the automatic identification of landmarks in CBCT scans, employing CNNs (Figure 1B). In this instance, a panel of 34 landmarks was manually situated by two clinicians within a sample of 56 CBCT scans, serving as the foundation for the training and validation of the ALICBCT algorithm. The outcome revealed an average error margin of less than 2 mm. These innovative AI tools have indeed elevated the accuracy of landmark identification for imaging analysis. Nevertheless, it is incumbent upon clinicians to fine-tune landmark positions before embarking on rigorous assessments, along with pursuing novel training and testing endeavors to fortify the model's robustness. Enhancing the performance of these tools necessitates a continuous process of training the AI models with more diverse samples, spanning varied skeletal conditions and distinct image acquisition protocols. This ongoing refinement serves as a crucial imperative to drive the efficacy of AI-driven techniques in the domain of 3D CBCT imaging analysis.

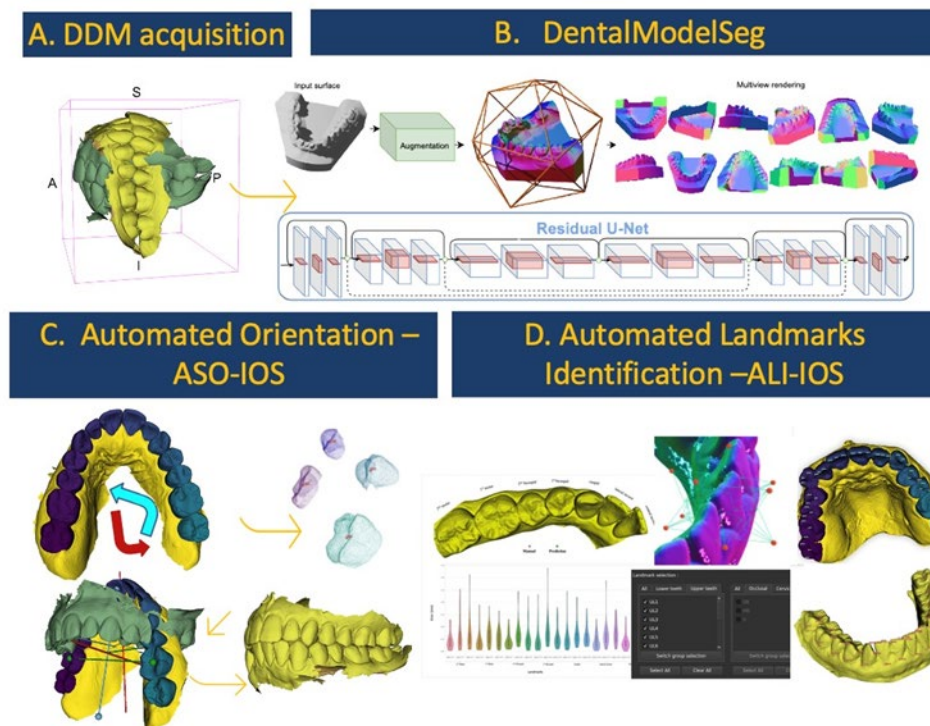


Figure 2. A) The acquisition of digital dental models (DDMs) often occurs in variable orientation as shown in yellow. B) Tooth segmentation performed with the DentalModelSeg module of the 3D Slicer software. C) Automatic Standardized Orientation. D) Automatic landmark identification performed with the ALIIOS module of the 3D Slicer software.

DDMs have taken a pioneering role in driving digital treatment simulation and advancing additive manufacturing through the utilization of 3D printing for orthodontic appliances. This technology has gained substantial traction, particularly due to its extensive adoption within orthodontic practices. It is noteworthy that these DDMs have also emerged as a focal point for innovative AI tools, designed to facilitate segmentation, landmark identification, and registration in conjunction with CBCT scans. This convergence has led to the development of novel methodologies, including automated tooth segmentation within DDMs (Figure 2), opening avenues for virtual setups, 3D visualization of tooth movement, and the streamlined production of orthodontic devices. Notably, the application of AI-driven algorithms has yielded commendable success rates and temporal efficiency in achieving these outcomes [29-34]. In the realm of DDM analysis, the identification of landmarks assumes paramount significance. To this end, a groundbreaking technique known as automatic landmark identification in intra-oral scans (ALIIOS) has been introduced, employing the innovative FlyByCNN algorithm [35]. This approach incorporates dental model segmentation prior to ALI of the teeth centroids, thereby isolating the tooth crown for precise analysis and orientation (Figure 2). While the ALIIOS model has exhibited a satisfactory level of performance, it is essential to underscore that further refinement, encompassing enhanced training and rigorous testing, is imperative to harness the full clinical potential of this nascent tool. Notably, as the DDMs primarily encapsulate dental crown information, it is vital to consider the potential limitation of relying solely on these models for treatment planning, particularly concerning dental root movement beyond the confines of the alveolar bone. Therefore, a comprehensive approach that amalgamates DDMs with supplementary diagnostic modalities is paramount to ensuring robust and accurate treatment planning in cases involving complex root movement scenarios. This underscores the imperative need to harmonize digital tools with traditional methodologies, thereby enriching the precision and efficacy of orthodontic interventions.

The compilation of orthodontic electronic records, particularly the inclusion of DDMs, has spurred heightened interest in the adoption of a comprehensive digital workflow [1]. The utilization of digital planning and 3D virtual configurations has gained increased prominence, notably in tandem with the growing prevalence of clear aligners in orthodontic practices. Digital planning holds a dual role within orthodontics: firstly, as a diagnostic tool offering the capacity to validate, adapt, or discard treatment plans; secondly, as a therapeutic instrument for implementing orthodontic interventions and fabricating diverse appliances [36, 37]. Leveraging advancements in computational technologies, orthodontists are empowered to execute virtual simulations, envisioning dental movements, surgical procedures, and precise bone anchorage placements. Moreover, digital planning has fostered the innovation and creation of diverse orthodontic appliance designs, encompassing clear aligners, miniscrew-anchored maxillary expanders, virtual bracket positioning, and surgical guides. Beyond enhancing treatment prognoses, the integration of digital planning and workflows offers the potential to bolster patient communication throughout the diagnostic and treatment planning stages, thereby enriching the overall treatment experience [1, 36, 37].

Incorporating AI, teledentistry has emerged as an avenue with potential to diminish costs and minimize chairside durations by substituting certain in-office visits with regular virtual monitoring [38-40]. This novel approach holds promise in refining patient care processes. Teledentistry encompasses the utilization of AI-driven remote monitoring systems, including pioneering platforms such as Dental Monitoring (DM) software and the Grin Remote Monitoring Platform (<https://get-grin.com/>), which facilitate remote patient supervision and management [41-43]. DM, a pivotal component of teledentistry, has been seamlessly integrated into orthodontic treatment protocols. It serves multifaceted roles, encompassing the evaluation of oral hygiene levels, tracking the progression of clear aligner therapies, monitoring advancements in orthodontic mechanics, ensuring the appropriate usage of removable appliances, and addressing other treatment imperatives [44-47]. This digital innovation not only holds the promise of streamlining orthodontic treatment processes but also contributes to fostering a heightened level of patient engagement and adherence, bolstering the

overall treatment experience. As technology continues to evolve, teledentistry underpinned by AI-driven remote monitoring stands as a progressive paradigm in the contemporary landscape of orthodontic care, exemplifying the potential of innovative solutions to transform traditional practices.

This chapter describes the advances in the diagnostic tools for image analysis in orthodontics promoted by the use of AI and a step-by-step method for image analysis in orthodontics using open-source AI-based tools.

THREE-DIMENSIONAL IMAGE ANALYSES METHODOLOGIES

Data management

In the midst of a proliferation of AI tools, the effective collection and management of data pose an ongoing challenge. This challenge stems from the imperative need for consistent data standards to be universally applied to scientific data and its associated metadata. This ensures the seamless interoperability of datasets and resources, thereby facilitating accessibility and utilization. Embracing the tenets of Findability, Accessibility, Interpretability, and Reproducibility (FAIR) principles, the National Institutes of Health (NIH) has introduced a mandate that necessitates all studies to delineate a comprehensive data management and sharing strategy [48]. However, it is noteworthy that the journey toward standardized data within orthodontics encounters a key hurdle: the evolution of secure cloud-based data management systems. Progress in this realm remains imperative to enable the realization of standardized data practices. As these developments continue to evolve, the prospect of standardized data in orthodontics draws nearer, potentially revolutionizing the landscape of research and practice in the field.

Image analysis procedures using open-source AI tools

A detailed outline of the process for 3D image analysis using the automated open-source craniomaxillofacial modules within the 3D Slicer software (Figure 3) is delineated below.

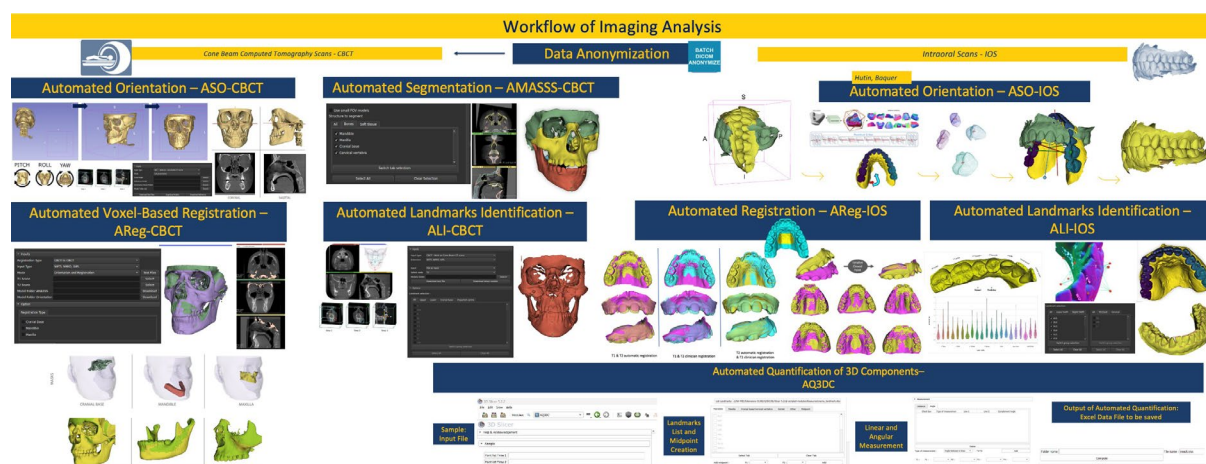


Figure 3. Workflow for the Slicer Automated Dental Tools.

Data anonymization of 3D diagnostic records

The process of anonymization assumes paramount importance in safeguarding the privacy of human subjects, rendering the data amenable for analysis, sharing, and potential public dissemination. Recent initiatives, such as Facebase [49] and the Imaging Data Commons [50], have

been conceived with the objective of establishing a comprehensive public database spanning multiple centers, protocols, and modalities. However, a pragmatic challenge arises due to the prohibition of sharing data containing protected or personal health information that might compromise subject privacy or confidentiality, particularly from clinical centers or medical institutions [51]. To surmount this challenge, an innovative solution has been devised: a fully automated anonymization tool tailored for medical image data, coupled with a defacing algorithm designed specifically for CBCT scans. This tool has been seamlessly integrated as an extension within the 3DSlicer software [52]. Functioning under the moniker of the Slicer Batch Anonymize tool, it facilitates automated meta-data stripping and defacement of images, thereby ensuring anonymity and the eradication of identifiable facial features prior to data sharing [53]. This pioneering development stands as a robust response to the imperative of preserving subject privacy while advancing the possibilities of data sharing and collaborative research.

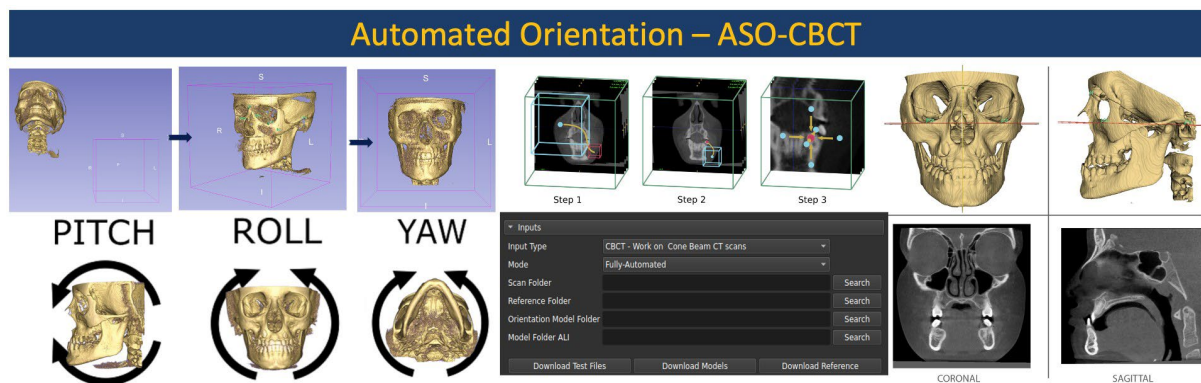


Figure 4. Standardized head orientation in CBCT based on landmarks.

Automated standardized orientation

Standardizing the alignment of CBCT scans and 3D surface models within a shared coordinate framework is of paramount importance. This standardization serves as a foundational pillar for consistent baseline diagnosis, longitudinal evaluations, facilitating group comparisons, and ensuring uniform measurements across subjects [54]. Our ongoing endeavors delve into the integration of ALICBCT [28] or ALIiOS [35] Slicer Software AI tools to orchestrate the alignment of all subject scans within a consistent coordinate system, catering to various clinical applications. For large field-of-view scans, the ALICBCT tool identifies key reference planes, including the Frankfurt plane, through bilateral landmarks like Orbitale and Porion, as well as the midsagittal plane defined by Sella, Nasion, and Basion landmarks (Figure 4). For intra-oral scans (IOSs), the standardized orientation is established with the occlusal plane aligned parallel to the Slicer horizontal plane standardized coordinate system. Subsequent to landmark identification, the Automated Standardized Orientation (ASO) tool harnesses an Iterative Closest Point (ICP) algorithm, enabling the precise alignment of all models relative to previously standardized gold standard scans. The ASO tool effectively engenders a consistent orientation across all models within a given sample, facilitating the harmonization of scans acquired from the same patient at disparate time points.

Automated construction of 3D volumetric label maps and surface model segmentations

The Automatic Multi-Structures Skull Segmentation (AMASSS) tool, an AI module embedded within the user-friendly 3D Slicer interface, proficiently undertakes full-face segmentation with exceptional precision and commendable temporal efficiency (Figure 1) [25]. Developed leveraging the UNet Transformers (UNETR) from the Medical Open Network for Artificial Intelligence (MONAI) framework, the development of AMASSS drew upon a dataset comprising 618 de-identified CBCT scans acquired under varying parameters, serving as a foundation for training and testing. This

concerted effort yielded remarkable accuracy and robustness, as evidenced by a Dice score reaching up to 0.962 ± 0.02 [25]. Impressively, the arduous task of manually segmenting CBCT structures, a process demanding approximately seven hours of meticulous work from seasoned clinicians, is juxtaposed with the mere five minutes required by the efficient AMASSS module.

For DDMs, the Slicer DentalModelSeg tool has been devised for the purpose of automated dental model segmentation [55]. Employing a deep learning methodology, this tool extracts a 3D object from multiple perspectives, capturing snapshots that subsequently facilitate the extraction of 2D image features. Its functionalities encompass the segmentation of dental crowns and the classification of upper and lower arches. Additionally, the tool enables the labeling of dental crowns based on the 'Universal Numbering System' (Figure 2). This technological innovation further bolsters the realm of dental image analysis and underscores the potential of AI-driven solutions in enhancing the efficiency and precision of dental workflows.

Image registration

Registration (superimposition) of CBCT scans acquired at different time points allows the assessment of growth and/or treatment response. The 3D registrations/superimpositions evaluation depends on the reference structure for registration. Three-dimensional registration on different regions of reference (RORs) leads to different interpretations of the results.

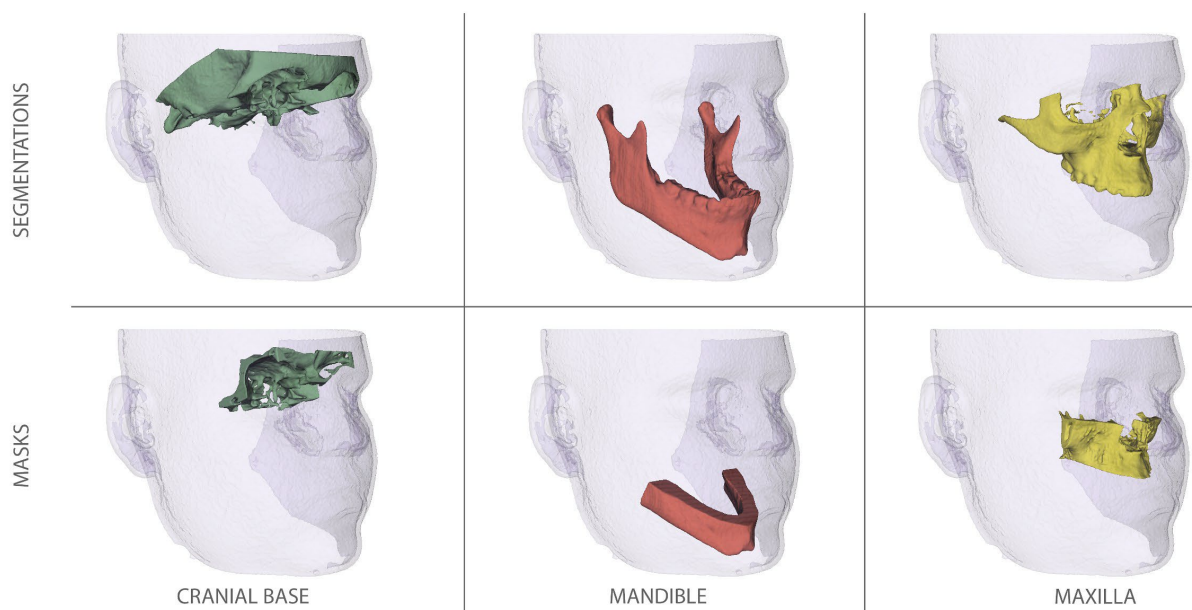

Figure 5. A) Cranial base, B) maxillary, and C) and mandibular masks created for Voxel-Based Registration.

Voxel-Based Registration: Our automatic alignment is based on a regional voxel-based registration (VBR) approach which automatically aligns mask segmentations that contain only stable RORs or masks within the cranial base, the mandible, or the maxilla. The VBR methods compare voxel by voxel the gray-level values in two CBCT scans to calculate the rotation and translation parameters between them. Automatic Multi-Anatomical Skull Structure Segmentation (AMASSS-CBCT) [25] utilizes MONAI UNETR trained models to perform segmentation of stable RORs within specific craniofacial structures. These RORs are defined based on established references for each region, within the cranial base [56, 57], mandible [58], and maxilla [59] as illustrated in Figure 5. For this purpose, different mask segmentations were trained with 135 anonymized CBCTs for each of the three RORs. Our Flexible VBR (F-VBR) algorithm utilized the Python library optimized for medical image registration for the desired voxel-based method: SimpleElastix [16]. To perform the F-VBR, we applied

the automatically-obtained segmentation as a mask to the fixed image, to only keep the important information from the scan within the delimited area. To have an accurate transformation between the moving image and the fixed image, we initially ran a registration between the full images and then with the masked image as a fine-tuning step. The optimized parameters used for the two rigid registration steps in this application for craniomaxillofacial CBCT imaging included 256 iterations for scans approximation and then 10,000 iterations for registration fine-tuning. The tool then generated registered label maps and surface meshes using the AMASSS functions.

Surface and Landmark-Based Registration: The palatal rugae are often used as stable reference regions for the maxillary DDMs registration and the mucogingival margin for the mandibular DDMs registration. The techniques for the automatic registration of DDMs include neural network predictions and the ICP algorithm. The implementation of the method incorporates the pipeline of Pytorch-lightning, Pytorch, and MONAI. The registration process first involves crown segmentation using the DentalModelSeg extension. This allows the identification of teeth crowns and the determination of their centroids. After orientation using the centroids, the scans are rendered to generate images for the neural network to predict the region of interest (ROI) in the palatal rugae region. Subsequently, the ICP algorithm is applied to register the upper jaw scans using the predicted ROI as the registration target. The performance of the proposed method was evaluated using a testing dataset of 24 growing patients. The results demonstrate the effectiveness of the automated registration approach, with average and standard deviation of the errors at less than 1.67° and less than 0.84 mm for angular and linear measurements, respectively, between the automated registration and the expert clinician's registration. Scans from growing patients or those taken at significantly different time intervals were the most challenging to register. The integration of the method into 3D Slicer through the SlicerAutomatedDentalTools extension enhances its accessibility and usability. The code is available here: <https://github.com/DCBIA-OrthoLab/SlicerAutomatedDentalTools>.

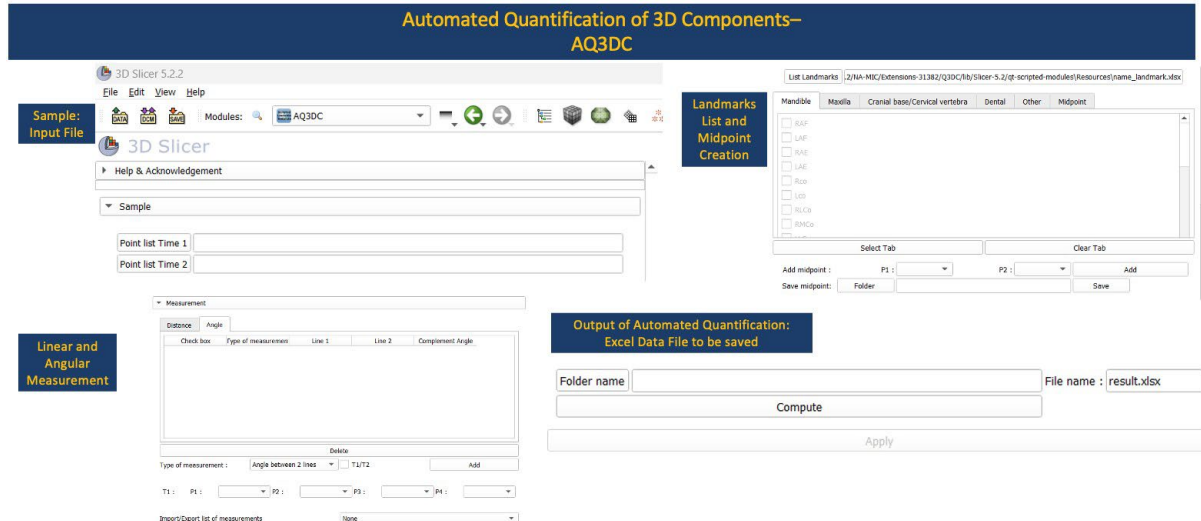


Figure 6. Automated Quantification of directional changes for whole samples and folders.

Landmark identification and quantitative measurements

Automatic landmark identification can be performed using the ALICBCT and ALIIOS tools of the Slicer Automated Dental Tools module of 3D Slicer, which is available as open source software. After landmark location, users can check and refine the landmark's location using the Markups module. Different types of quantitative measurements can be performed, such as volume, 3D Linear Surface Distances based on observer defined landmarks and based on thousands of points in triangular meshes automatically defined in the surface models, and 3D angular measurements (Figure 6). The Automated Quantification of 3D components (AQ3DC) is a module of 3D Slicer software that allows

automatic computations for a whole folder of lists of landmarks in one or more time points, quantifying the transversal (x-axis), antero-posterior (y-axis), and vertical (z-axis) direction in different types of measurements.

Distances between 3D landmarks identified with ALICBCT or ALIIOS can be quantified using two types of quantitative assessment: at one time point, when the 3D linear distances correspond to the Euclidean distances between the landmarks (e.g., to the characterization of dimensions prior to treatment), and between two time points, when the 3D linear distances in each plane of the space for displacements of the maxilla and/or mandible can be measured. The AQ3DC module in the 3D Slicer software also allows 3D angular measurements. The angular measurements can be used for the characterization of facial morphology or evaluation of rotational changes between time points.

Three-dimensional surface distances computed at the vertices of the triangular meshes can be computed as *closest points* between non-correspondent surfaces meshes. The calculation of the surface distances can be stored as color-coded 3D linear distance models, using the Slicer Model to Model Distance module [60]. Closest point 3D linear distances measure the closest distances between the vertices of the triangular meshes in two surfaces. The Spherical Harmonics – Point Distribution Models (SPHARM-PDM) module in the Slicer software computes point-based surface models, where all models have the same number of triangular meshes and vertices in corresponding locations. Corresponding surface distances and vectors can be calculated and graphically displayed in Slicer using this tool.

CONCLUSIONS

The incorporation of AI has ushered in a new era of possibilities for 3D imaging in orthodontics, revolutionizing the procedures involved in imaging analysis for patients necessitating orthodontic, orthopedic, and/or surgical interventions. This groundbreaking advancement has found its manifestation through the integration of AI tools within open-source software, orchestrating a symphony of image anonymization, segmentation, landmark identification, standardized orientation, registration, and quantification. As these AI-driven methodologies continue to evolve and refine, a dynamic process of perpetual testing and training is essential. This iterative method is pivotal in refining the clinical precision of these automated techniques and enhancing their capability to effectively address the ever-changing and varied demands of the wider orthodontic community.

REFERENCES

1. Jacox LA, Mihas P, Cho C, Lin FC, Ko CC. Understanding technology adoption by orthodontists: a qualitative study. *Am J Orthod Dentofacial Orthop* 2019;155(3):432-442. PubMed PMID: 30826046.
2. Alyass A, Turcotte M, Meyre D. From big data analysis to personalized medicine for all: challenges and opportunities. *BMC Med Genomics* 2015;8:33. PubMed PMID: 26112054.
3. Cai L, Zhu Y. The challenges of data quality and data quality assessment in the big data era. *Data Science Journal* 2015;14:2-2.
4. Li P, Kong D, Tang T, Su D, Yang P, Wang H, et al. Orthodontic treatment planning based on artificial neural networks. *Sci Rep* 2019;9(1):2037. PubMed PMID: 30765756.
5. Subramanian AK, Chen Y, Almalki A, Sivamurthy G, Kafle D. Cephalometric analysis in orthodontics using artificial intelligence-a comprehensive review. *Biomed Res Int* 2022; 2022:1880113. PubMed PMID: 35757486.

6. Monill-Gonzalez A, Rovira-Calatayud L, d'Oliveira NG, Ustrell-Torrent JM. Artificial intelligence in orthodontics: where are we now? A scoping review. *Orthod Craniofac Res* 2021;24 Suppl 2:6-15. PubMed PMID: 34270881.
7. Schwendicke F, Golla T, Dreher M, Krois J. Convolutional neural networks for dental image diagnostics: a scoping review. *J Dent* 2019;91:103226. PubMed PMID: 31704386.
8. Lee JH, Yu HJ, Kim MJ, Kim JW, Choi J. Automated cephalometric landmark detection with confidence regions using Bayesian convolutional neural networks. *BMC Oral Health* 2020;20(1):270. PubMed PMID: 33028287.
9. Kim H, Shim E, Park J, Kim YJ, Lee U, Kim Y. Web-based fully automated cephalometric analysis by deep learning. *Comput Methods Programs Biomed* 2020;194:105513. PubMed PMID: 32403052.
10. Arik SO, Ibragimov B, Xing L. Fully automated quantitative cephalometry using convolutional neural networks. *J Med Imaging (Bellingham)* 2017;4(1):014501. PubMed PMID: 28097213.
11. Hwang JJ, Lee JH, Han SS, Kim YH, Jeong HG, Choi YJ, et al. Strut analysis for osteoporosis detection model using dental panoramic radiography. *Dentomaxillofac Radiol* 2017;46(7):20170006. PubMed PMID: 28707523.
12. Chandrashekar G, AlQarni S, Bumann EE, Lee Y. Collaborative deep learning model for tooth segmentation and identification using panoramic radiographs. *Comput Biol Med* 2022;148:105829. PubMed PMID: 35868047.
13. Lee JH, Han SS, Kim YH, Lee C, Kim I. Application of a fully deep convolutional neural network to the automation of tooth segmentation on panoramic radiographs. *Oral Surg Oral Med Oral Pathol Oral Radiol* 2020;129(6):635-642. PubMed PMID: 31992524.
14. Hou S, Zhou T, Liu Y, Dang P, Lu H, Shi H. Teeth U-Net: A segmentation model of dental panoramic X-ray images for context semantics and contrast enhancement. *Comput Biol Med* 2023;152:106296.
15. Krois J, Garcia Cantu A, Chaurasia A, Patil R, Chaudhari PK, Gaudin R, et al. Generalizability of deep learning models for dental image analysis. *Sci Rep* 2021;11(1):6102. PubMed PMID: 33731732.
16. Jeong SH, Yun JP, Yeom HG, Lim HJ, Lee J, Kim BC. Deep learning based discrimination of soft tissue profiles requiring orthognathic surgery by facial photographs. *Sci Rep* 2020; 10(1):16235. PubMed PMID: 33004872.
17. Obwegeser D, Timofte R, Mayer C, Eliades T, Bornstein MM, Schatzle MA, et al. Using artificial intelligence to determine the influence of dental aesthetics on facial attractiveness in comparison to other facial modifications. *Eur J Orthod* 2022;44(4):445-451. PubMed PMID: 35532375.
18. Patcas R, Bernini DAJ, Volokitin A, Agustsson E, Rothe R, Timofte R. Applying artificial intelligence to assess the impact of orthognathic treatment on facial attractiveness and estimated age. *Int J Oral Maxillofac Surg* 2019;48(1):77-83. PubMed PMID: 30087062.
19. Ryu J, Lee YS, Mo SP, Lim K, Jung SK, Kim TW. Application of deep learning artificial intelligence technique to the classification of clinical orthodontic photos. *BMC Oral Health* 2022;22(1):454. PubMed PMID: 36284294.
20. Wang L, Gao Y, Shi F, Li G, Chen KC, Tang Z, et al. Automated segmentation of dental CBCT image with prior-guided sequential random forests. *Med Phys* 2016;43(1):336. PubMed PMID: 26745927.
21. Kim YH, Shin JY, Lee A, Park S, Han SS, Hwang HJ. Automated cortical thickness measurement of the mandibular condyle head on CBCT images using a deep learning method. *Sci Rep* 2021;11(1):14852. PubMed PMID: 34290333.
22. Preda F, Morgan N, Van Gerven A, Nogueira-Reis F, Smolders A, Wang X, et al. Deep convolutional neural network-based automated segmentation of the maxillofacial complex from cone-beam computed tomography: a validation study. *J Dent* 2022;124:104238. PubMed PMID: 35872223.

23. Wang H, Minnema J, Batenburg KJ, Forouzanfar T, Hu FJ, Wu G. Multiclass CBCT image segmentation for orthodontics with deep learning. *J Dent Res* 2021;100(9):943-949. PubMed PMID: 33783247.
24. Shaheen E, Leite A, Alqahtani KA, Smolders A, Van Gerven A, Willems H, et al. A novel deep learning system for multi-class tooth segmentation and classification on cone beam computed tomography. A validation study. *J Dent* 2021;115:103865. PubMed PMID: 34710545.
25. Gillot M, Baquero B, Le C, Deleat-Besson R, Bianchi J, Ruellas A, et al. Automatic multi-anatomical skull structure segmentation of cone-beam computed tomography scans using 3D UNETR. *PLoS One* 2022;17(10):e0275033. PubMed PMID: 36223330.
26. Lagravere MO, Low C, Flores-Mir C, Chung R, Carey JP, Heo G, et al. Intraexaminer and interexaminer reliabilities of landmark identification on digitized lateral cephalograms and formatted 3-dimensional cone-beam computerized tomography images. *Am J Orthod Dentofacial Orthop* 2010;137(5):598-604. PubMed PMID: 20451778.
27. Ghowsi A, Hatcher D, Suh H, Wile D, Castro W, Krueger J, et al. Automated landmark identification on cone-beam computed tomography: Accuracy and reliability. *Angle Orthod* 2022;92(5):642-654. PubMed PMID: 35653226.
28. Gillot M, Miranda F, Baquero B, Ruellas A, Gurgel M, Al Turkestani N, Anchling L, Hutin N, Biggs E, Yatabe M, Paniagua B, Fillion-Robin JC, Allemang D, Bianchi J, Cevidanes L, Prieto JC. Automatic landmark identification in cone-beam computed tomography. *Orthod Craniofac Res* 2023;26(4):560-567. PubMed PMID: 36811276.
29. Im J, Kim JY, Yu HS, Lee KJ, Choi SH, Kim JH, et al. Accuracy and efficiency of automatic tooth segmentation in digital dental models using deep learning. *Sci Rep* 2022;12(1):9429. PubMed PMID: 35676524.
30. Wu TH, Lian C, Lee S, Pastewait M, Piers C, Liu J, et al. Two-stage mesh deep learning for automated tooth segmentation and landmark localization on 3D intraoral scans. *IEEE Trans Med Imaging* 2022;41(11):3158-3166. PubMed PMID: 35666796.
31. Woodsend B, Koufoudaki E, Lin P, McIntyre G, El-Angbawi A, Aziz A, et al. Development of intra-oral automated landmark recognition (ALR) for dental and occlusal outcome measurements. *Eur J Orthod* 2022;44(1):43-50. PubMed PMID: 33950251.
32. Tian S, Dai N, Zhang B, Yuan F, Yu Q, Cheng X. Automatic classification and segmentation of teeth on 3D dental model using hierarchical deep learning networks. *IEEE Access* 2019; 7:84817-28.
33. Lian C, Wang L, Wu TH, Wang F, Yap PT, Ko CC, et al. Deep multi-scale mesh feature learning for automated labeling of raw dental surfaces from 3D intraoral scanners. *IEEE Trans Med Imaging* 2020;39(7):2440-2450.
34. Chen Q, Huang J, Salehi HS, Zhu H, Lian L, Lai X, et al. Hierarchical CNN-based occlusal surface morphology analysis for classifying posterior tooth type using augmented images from 3D dental surface models. *Comput Methods Programs Biomed* 2021;208:106295. PubMed PMID: 34329895.
35. Baquero B, Gillot M, Cevidanes L, Al Turkestani N, Gurgel M, Leclercq M, Bianchi J, Yatabe M, Ruellas A, Massaro C, Aliaga A, Castrillon MA, Rey D, Aristizabal JF, Prieto JC. Automatic landmark identification on IntraOralScans. *Clinical Image-Based Procedures: 11th Workshop, CLIP 2022, Held in Conjunction with MICCAI 2022, Singapore, September 18, 2022, Proceedings Sep 2022, pages 32-42*; https://doi.org/10.1007/978-3-031-23179-7_4.
36. Baan F, de Waard O, Bruggink R, Xi T, Ongkosuwito EM, Maal TJJ. Virtual setup in orthodontics: planning and evaluation. *Clin Oral Investig* 2020;24(7):2385-93. PubMed PMID: 31720852.
37. Cunha TMAD, Barbosa IDS, Palma KK. Orthodontic digital workflow: devices and clinical applications. *Dental Press J Orthod* 2021;26(6):e21spe6. PubMed PMID: 34932716.
38. Hansa I, Semaan SJ, Vaid NR. Clinical outcomes and patient perspectives of Dental Monitoring(R) GoLive(R) with Invisalign(R)-a retrospective cohort study. *Prog Orthod* 2020; 21(1):16. PubMed PMID: 32537723.

39. Hansa I, Katyal V, Ferguson DJ, Vaid N. Outcomes of clear aligner treatment with and without Dental Monitoring: a retrospective cohort study. *Am J Orthod Dentofacial Orthop* 2021; 159(4):453-459. PubMed PMID: 33573897.
40. Giudice A, Barone S, Muraca D, Averta F, Diodati F, Antonelli A, et al. Can teledentistry improve the monitoring of patients during the Covid-19 dissemination? A Descriptive Pilot Study. *Int J Environ Res Public Health* 2020;17(10):3399. PubMed PMID: 32414126.
41. Vaid NR. Artificial intelligence (AI) driven orthodontic care: a quest toward utopia? *Seminars in Orthodontics* 2021;27(2):57-61.
42. Morris RS, Hoye LN, Elnagar MH, Atsawasuwan P, Galang-Boquiren MT, Caplin J, et al. Accuracy of Dental Monitoring 3D digital dental models using photograph and video mode. *Am J Orthod Dentofacial Orthop* 2019;156(3):420-428. PubMed PMID: 31474272.
43. Hansa I, Katyal V, Semaan SJ, Coyne R, Vaid NR. Artificial intelligence driven remote monitoring of orthodontic patients: Clinical applicability and rationale. *Seminars in Orthodontics* 2021;27(2):138-156.
44. Sangalli L, Savoldi F, Dalessandri D, Visconti L, Massetti F, Bonetti S. Remote digital monitoring during the retention phase of orthodontic treatment: a prospective feasibility study. *Korean J Orthod* 2022;52(2):123-130. PubMed PMID: 35321951.
45. Sangalli L, Savoldi F, Dalessandri D, Bonetti S, Gu M, Signoroni A, et al. Effects of remote digital monitoring on oral hygiene of orthodontic patients: a prospective study. *BMC Oral Health* 2021;21(1):435. PubMed PMID: 34493255.
46. Minervini G, Russo D, Herford AS, Gorassini F, Meto A, D'Amico C, et al. Teledentistry in the management of patients with dental and temporomandibular disorders. *BioMed Res Int* 2022;2022:7091153.
47. Hannequin R, Ouadi E, Racy E, Moreau N. Clinical follow-up of corticotomy-accelerated Invisalign orthodontic treatment with Dental Monitoring. *Am J Orthod Dentofacial Orthop* 2020;158(6):878-888. PubMed PMID: 33129633.
48. Fair principles. Available at <https://www.go-fair.org/fair-principles/> and accessed on November 20, 2022.
49. FaceBase. Available at <https://www.facebase.org/> and accessed on November 22, 2022.
50. Imaging Data Commons. Available at <https://datacommons.cancer.gov/repository/imaging-data-commons> and accessed on November 22, 2022.
51. Mildenerberger P, Eichelberg M, Martin E. Introduction to the DICOM standard. *Eur Radiol* 2002;12(4):920-927. PubMed PMID: 11960249.
52. 3D Slicer. Available at <https://www.slicer.org/> and accessed on November 22, 2022.
53. Diaz O, Kushibar K, Osuala R, Linardos A, Garrucho L, Igual L, et al. Data preparation for artificial intelligence in medical imaging: A comprehensive guide to open-access platforms and tools. *Phys Med* 2021;83:25-37. PubMed PMID: 33684723.
54. Ruellas AC, Tonello C, Gomes LR, Yatabe MS, Macron L, Lopinto J, et al. Common 3-dimensional coordinate system for assessment of directional changes. *Am J Orthod Dentofacial Orthop* 2016;149(5):645-656. PubMed PMID: 27131246.
55. Deleat-Besson R, Le C, Zhang W, Turkestani NA, Cevidanes L, Bianchi J, Ruellas A, Gurgel M, Massaro C, Del Castillo AA, Ioshida M. Merging and annotating teeth and roots from automated segmentation of multimodal images. In *Multimodal Learning for Clinical Decision Support: 11th International Workshop, ML-CDS 2021, Held in Conjunction with MICCAI 2021, Strasbourg, France, October 1, 2021, Proceedings 11 2021* (pp. 81-92). Springer International Publishing.
56. Cevidanes LH, Heymann G, Cornelis MA, DeClerck HJ, Tulloch JF. Superimposition of 3-dimensional cone-beam computed tomography models of growing patients. *Am J Orthod Dentofacial Orthop* 2009;136(1):94-99. PubMed PMID: 19577154.
57. Cevidanes LH, Styner MA, Proffit WR. Image analysis and superimposition of 3-dimensional cone-beam computed tomography models. *Am J Orthod Dentofacial Orthop* 2006; 129(5):611-618. PubMed PMID: 16679201.

58. Ruellas AC, Huanca Ghislanzoni LT, Gomes MR, Danesi C, Lione R, Nguyen T, et al. Comparison and reproducibility of 2 regions of reference for maxillary regional registration with cone-beam computed tomography. *Am J Orthod Dentofacial Orthop* 2016;149(4):533-542. PubMed PMID: 27021458.
59. Ruellas AC, Yatabe MS, Souki BQ, Benavides E, Nguyen T, Luiz RR, et al. 3D mandibular superimposition: comparison of regions of reference for voxel-based registration. *PLoS One* 2016;11(6):e0157625. PubMed PMID: 27336366.
60. Model to model distance and ShapePopulationViewer video tutorials, available at https://www.youtube.com/watch?v=Qen8ou5QsAw&list=PLI4LKTeqllaeBYEHGp1E-0xc510B_bC2Z&index=15, accessed on Nov 23,2022.

WHEN ARTIFICIAL INTELLIGENCE MEETS DIGITAL ORTHODONTICS

Tai-Hsien Wu, Leah Stetzel, Sumeet Minhas, Lily Etemad, and Ching-Chang Ko

ABSTRACT

This chapter navigates the confluence of artificial intelligence (AI) and digital orthodontics, signifying a transformative shift in patient care. It introduces the digital workflow of orthodontics, encompassing essential technology setup and introduction, before diving into a discussion of AI and its applications, such as classification, regression, image segmentation, and landmark identification. Deep Learning (DL) is introduced and distinguished from traditional Machine Learning (ML), emphasizing its potential for handling complex orthodontic data. Subsequently, we examine various data formats, including tabular, image, and text data, and identify the neural networks best suited for each, supplementing the discourse with practical examples from the dental field. The chapter concludes with strategies to enhance AI model performance, underscoring the importance of dataset size and quality, advanced network architectures, and innovative training strategies. The synergistic effect of these factors can significantly boost model effectiveness, refining precision in digital orthodontic diagnostics and treatments. This chapter aims to provide a concise, yet comprehensive guide to the potential of AI in reshaping digital orthodontics, encouraging continued research and application to revolutionize patient care.

KEY WORDS: Machine Learning, Deep Learning, Artificial Intelligence, Digital Orthodontics

INTRODUCTION

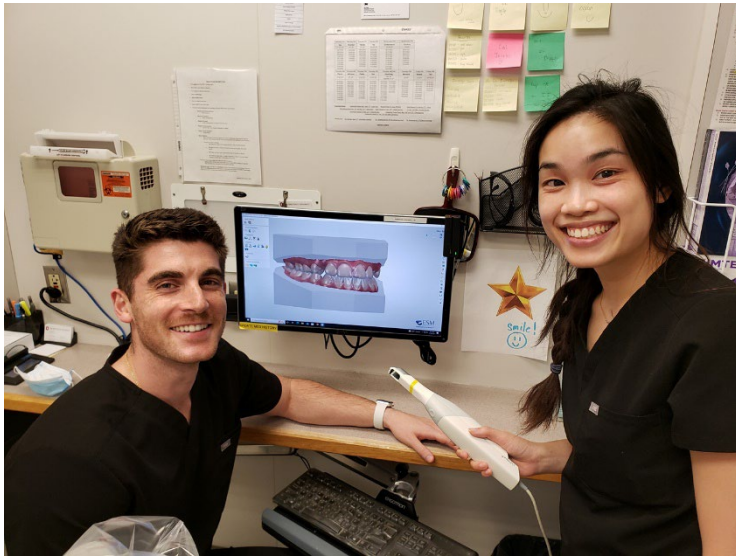
Over the past decade, the use of artificial intelligence (AI) has become increasingly prevalent in dental specialties, such as orthodontics, prosthodontics, restorative dentistry, and periodontology. These AI applications have the potential to revolutionize the field, enabling faster, more accurate diagnosis and planning treatment, and improving patient care [1]. Many of these are attributed to the advent of digital orthodontics, which involves the use of advanced images and three-dimensional (3D) printing technologies. The technology has allowed AI to be integrated into orthodontic practice including the creation of customized orthodontic appliances. The chapter provides an overview of digital orthodontics and AI, from which the content delves into deep learning (DL) that has broader impacts on different applications.

DIGITAL ORTHODONTICS

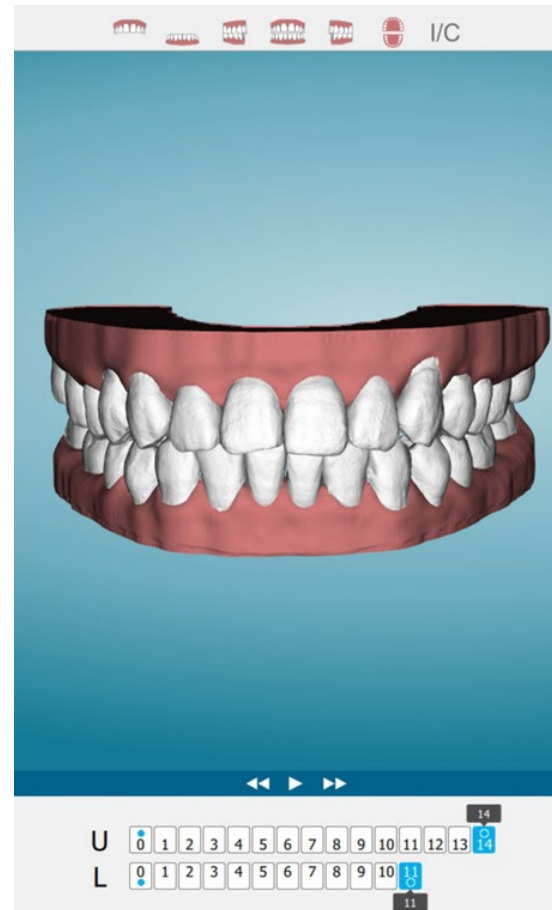Contemporary orthodontic practice involves the use of digital radiographs, intra-oral scanners, imaging software, computer-aided design (CAD) software, and 3D printers. The new image technologies allow for faster image acquisition, reduced radiation exposure, and the ability to store and transmit images electronically. Analyses of the digital images provide quantitative assessments for diagnosis and treatment planning. In addition to the 2D cephalometric and panoramic radiography, cone beam

computed tomography (CBCT) can create 3D anatomic information that helps plan treatment of impacted teeth, supernumerary teeth, craniofacial anomalies, and placement of temporary skeletal anchorage. Nevertheless, learning the operation of machines and computer software is critical for practice.

A



B



C



Figure 1. The digital workflow, including A) optical scanner, B) digital treatment planning, and C) fabrication.

Digital workflow

The use of advanced technologies and software has formed a sequela of digital workflow, which differentiates itself from traditional practice. The modern office would prefer to stay free of photography chemicals, x-ray films, alginate, plasters, etc. One of the major barriers for practitioners adapting to new technologies is the sophisticated procedures. Digital workflow will help streamline these complicated procedures. The following contents describe a typical digital workflow in orthodontics (also shown in Figure 1):

Technology setup: Hardware such as digital cephalometric and panoramic radiography, CBCT, and intra-oral 3D scanners have helped in gathering images. Electronic sensors and the replacement of traditional film allow for the immediate construction of digital images on a computer screen. Following the trend of digitization in orthodontics, the integration of 3D printing, especially vat photopolymerization technology, has enhanced precision and efficiency in the field. This advancement allows the direct fabrication of individualized appliances such as aligners and retainers from digital scans. The setup includes choosing an appropriate printer, calibrating it for accuracy, loading with dental-approved resin, and interfacing with specialized software to transform intra-oral 3D scans into physical models, thereby revolutionizing orthodontic treatment plans. Other software methods have been useful in representing these data such as digital electronic records, graphic tracings, 3D imaging rendition, and 3D printing.

Optical Scanner: Replication of oral tissues is a critical procedure for orofacial diagnosis and treatment planning. During the past 100 years, dental trays, impression materials, and plaster of Paris have evolved and been used to produce dental models. Optical scanners were developed in the last two decades and have become the mainstream of orthodontic impression. Optical scanning creates a mesh data, containing numerous individual points that represent surface topology of oral tissues in 3D space. The first step in the digital workflow is to be able to operate the intra-oral wand to create a digital model of the patient's teeth and surrounding structures.

Diagnosis/Treatment Plan: The second step of the digital workflow is to be familiar with software programs (e.g., 3D slicer, Meshmixer, Geomagic Design) that were designed to render the surface image of the mesh data. The computer model allows clinicians to virtually examine the occlusion and tooth position, analog to the plaster model. The clinician can use the model to prioritize the problems and determine treatment options. Beyond the visualization of the model, recent advances in image segmentation and qualifications allow CAD treatments. For example, specialized software (e.g., ClinCheck from Invisalign [www.invisalign.com] and uDesign from uLab Systems [www.ulabsystems.com]) allows the orthodontist to manipulate the digital model and simulate the desired outcome, from which treatment steps can be created using reverse engineering.

Fabrication: After the orthodontic treatment plan has been finalized, the next step is to use specialized software to design and create digital files. These files can be for either orthodontic appliances or dental models. If the digital files are orthodontic appliances, they can be 3D printed directly, such as in the case of indirect bonding trays. Instead, if the files are dental models, they need to be 3D printed first, and then additional fabrication processes are required. For example, a common "sucking down" process is used to fabricate clear aligners.

Treatment monitoring: Throughout the course of the orthodontic treatment, the patient's progress can be monitored using digital scans and other imaging techniques. This allows the orthodontist to track the movement of the teeth remotely and make a proper appointment for adjustments, which can reduce

unnecessary visits and manage urgency as needed. When the case is finished, the retainer can be fabricated from the digital model.

Overall, the digital workflow in orthodontics can offer numerous benefits, including increased accuracy and precision, improved treatment outcomes, and a more streamlined and efficient treatment process. However, some digital workflows are tedious and repetitive, which can consume a lot of doctors' time. Recent AI technologies can be employed to help streamline these tasks.

ARTIFICIAL INTELLIGENCE (AI)

There are two types of AI commonly defined as weak and strong AI. Weak AI, also known as narrow AI, refers to AI designed to perform a specific task or set of tasks [2]. This type of AI is programmed to excel at a single or limited range of tasks, such as playing chess or identifying objects in images. However, it does not possess the broad, adaptable intelligence associated with human cognition.

In contrast, strong AI, also known as general AI or artificial general intelligence, refers to AI that exhibits human-like cognitive abilities and can learn and reason in a manner that is indistinguishable from human intelligence [3, 4]. Strong AI would be capable of performing any intellectual task that a human can, including understanding natural language, solving complex problems, and learning from experience.

These two types of AI represent different levels of sophistication and capability. While weak AI has already been widely applied in various industries, strong AI remains largely theoretical and is still in the research and development phase. In this chapter, we mainly focus on the introduction and application of weak AI.

In the context of AI, data hold paramount importance as the foundational elements. Data serve as the lifeblood of AI, akin to how books are vital sources of knowledge for humans. Without sufficient and high-quality data, AI algorithms cannot learn and make accurate predictions or decisions. The exciting thing about the intersection of AI and digital orthodontics is that digital orthodontics naturally fulfills two key requirements for AI: *sufficient* and *high-quality data*. In the digital workflow of orthodontics, almost all patient information is converted into digital data, creating a vast pool of data for AI algorithms to learn from. Over the past decade, numerous companies have collected large amounts of data to develop their AI technologies. Moreover, since these data are utilized for treatment planning, the quality of the data directly impacts the effectiveness of the treatment. Under these circumstances, all members (i.e., clinicians, assistants, and technicians) of the digital orthodontics workflow work collaboratively to ensure that the data is of high quality. Therefore, the integration of AI and digital orthodontics has the potential to revolutionize the field, improving clinical efficiency and treatment efficacy. In the following section, we provide a brief overview of some fundamental AI concepts, as well as several commonly used applications that have been developed and are currently being used in clinics.

AI applications

AI has shown great promise in the fields of medicine and dentistry, with applications ranging from automated diagnosis and treatment planning to predictive modeling and personalized medicine. Four common AI applications in dentistry are classification, regression, image segmentation, and landmark identification, as discussed below.

Classification is a fundamental type of supervised learning that is widely used in dentistry. In the context of dentistry, classification typically involves identifying the presence or absence of a particular disease or condition, such as oral cancer, periodontitis, or caries, based on input data such as dental images or tabular measurements. Welikala et al. presented a classification model to automatically detect and classify oral lesions [5], achieving F1 scores of 87.07% and 78.30% for identification of images containing lesions and requiring referral, respectively. By training AI algorithms on large datasets of dental images and other clinical data, the AI can automatically classify images based on their visual characteristics. It was reported that a DL AI could improve the accuracy, speed, and efficiency of classification, as well as archiving and monitoring of orthodontic images.

Regression is another important type of supervised learning commonly used in dentistry. Unlike classification, regression involves predicting a continuous value based on input data. For instance, a regression model can be used to estimate bone age in young children [6], providing valuable information for orthodontic treatment planning. By analyzing large amounts of data such as medical images and clinical variables, regression models can also provide valuable insights into the progress of treatments or disease progression. This can help dentists develop more personalized treatment plans and improve patient outcomes.

Image segmentation is a crucial technique in medical imaging that involves dividing an image into different regions based on pixel or voxel characteristics, which is essentially a pixel/voxel-wise classification task. In dentistry, image segmentation is commonly used to identify specific structures, such as teeth or alveolar bone, within an image. By segmenting an image into different regions, dentists can extract more precise information about the location and extent of various structures. Image segmentation is a popular topic in medical imaging as it is a foundational step in many treatment plans. Several researchers have achieved clinical-grade segmentation results using AI algorithms. For instance, Cui et al. developed a fully automatic AI system for tooth and alveolar bone segmentation based on 4938 CBCT images, which obtained the average Dice similarity coefficient of 0.915 for tooth and 0.93 for alveolar bone, across the challenging cases with variable dental abnormalities [7]. Gillot et al. also presented an automatic multi-anatomical skull structure segmentation on CBCT using transformer-based network, 3D UNETR, and achieved DSC of approximately 0.96 on their dataset [8].

Landmark identification is a type of AI application in dental imaging that involves the automatic identification of anatomical landmarks in images, such as the tip of the tooth or the center of the joint. This is achieved through the use of ML algorithms that are trained on large datasets of annotated medical images. Landmark identification is a type of regression task, where the goal is to predict the coordinates of the landmark in the image based on input data. Once landmarks are identified, they can be used for a variety of purposes, such as aligning images for comparison or measuring anatomical changes over time. Several studies have demonstrated the effectiveness of AI-based landmark identification in medical imaging, including a study by Wu et al. that used DL to identify landmarks in intraoral scans with an average mean absolute error of approximately 0.6 mm between the prediction and ground truth for 66 landmarks [9].

DEEP LEARNING

Machine learning (ML) vs. deep learning (DL)

ML and DL are two approaches to AI that are often used interchangeably, but they differ in how they learn from data. ML is a form of AI that involves using algorithms to find patterns in data and make predictions or decisions. However, ML algorithms usually require feature engineering, which is the process of selecting and extracting relevant features from the input data that will be used to train the model. Feature engineering is often a time-consuming and complex task that requires domain expertise.

DL, alternatively, is a subset of ML that relies on neural networks to automatically learn and extract features from raw data. The neural network consists of multiple layers of interconnected nodes, and each layer learns to extract increasingly abstract and complex features from the input data. It is important to highlight that neural networks can be categorized into two main types: shallow networks and deep networks. The classification of a network as "deep" is not determined by a specific threshold but is based on the number of layers it comprises. A network is typically regarded as "deep" when it possesses a significant number of layers, indicating a greater depth compared to shallow networks. The feature extraction process is done automatically within the deep network, which means that there is no need for explicit feature engineering. As a result, DL models are often more accurate and can manage a wider range of tasks than traditional ML models if the training data volume is sufficient.

The automatic feature extraction capabilities of neural networks are key reasons why DL models often outperform traditional ML models when dealing with big data. These models can learn more complex and abstract features directly from data, without requiring extensive feature engineering, making them highly adaptable to a wide range of tasks. As a result, they are particularly well-suited for processing large amounts of unstructured data, such as image or speech recognition. However, it is important to note that DL models can suffer from overfitting if the quantity or quality of the data is inadequate, which can negatively impact their performance compared to traditional ML approaches.

DATA FORMAT AND NETWORK TYPES

Neural networks can be applied to a wide range of data types and tasks, making them powerful tools for AI and ML. Those data types include tabular data, images, and text. Although neural networks are flexible for many data types, it is important to use the suitable neural network in order to effectively and efficiently learn the underlying patterns from the corresponding data. In this section, we discuss those three data types and the neural networks that are commonly used for each of them.

Tabular data

Tabular data typically include structured data stored in a spreadsheet or database, such as demographic or cephalometric summaries. To extract insights from tabular data, ML models are commonly employed. Several effective models are particularly well-suited for analyzing tabular data, including random forest (RF), support vector machine (SVM), and multi-layer perceptron (MLP).

RF is an ensemble learning method that combines multiple decision trees to make predictions. It excels in handling tabular data with a large number of features, as it can capture complex interactions and non-linear relationships between variables. SVM is a powerful classification algorithm that works well for

tabular data with clear separation between classes. SVM seeks to find an optimal hyperplane that maximally separates different classes in the feature space. MLP is a type of neural network that consists of multiple layers of interconnected nodes. With its ability to manage complex patterns in tabular data, MLP can be trained to perform various tasks, such as classification or regression. When working with tabular data, MLP models typically do not require excessive complexity. Due to the straightforward nature of tabular data, MLP models can achieve good performance with just a few hidden layers. Excessive complexity, such as too many hidden layers, can lead to overfitting. To strike a balance between model complexity and performance, several researchers have successfully applied 3-layer MLP architectures when working with a few tens of clinical and cephalometric tabular data to predict a binary tooth extraction decision [10–12]. Furthermore, it is also worth noting that a recent study even pointed out that tree-based algorithms outperform the current DL-based method on tabular data [13]. As a result, researchers also explored the efficacy of RF models on the same binary tooth extraction prediction, achieving similar accuracy levels [14, 15].

Images

Images are a type of unstructured data and contain pixels of different colors that represent the visual information of an object or scene. In dentistry and orthodontics, images play a crucial role in capturing and analyzing visual information related to dental structures. When it comes to image data, it can be broadly categorized into two-dimensional (2D) and three-dimensional (3D) images. Images, such as intraoral photographs or dental radiographs, provide a 2D representation of the dental anatomy and are commonly used for diagnostic purposes.

Alternatively, 3D images offer a more comprehensive and detailed view of dental structures. Within the realm of 3D images, there are two main sub-categories: 3D volumetric images and 3D mesh data. Volumetric images, typically obtained from imaging modalities such as CBCT, provide a 3D representation of the internal structures of the oral cavity. These images consist of a series of stacked slices that together form a volumetric dataset, allowing for precise analysis of the dental and skeletal structures.

Convolutional Neural Networks (CNNs) have emerged as the go-to approach for analyzing 2D and 3D volumetric images. CNNs, consisting of convolutional layers, excel at automatically extracting features and patterns from image data, making them effective for tasks such as classification, segmentation, and detection. For 2D images, such as intraoral photos and radiographs, CNNs leverage 2D convolutions to learn dental structures. In the case of 3D volumetric images from modalities such as CBCT, CNNs employ 3D convolutions to capture spatial dependencies across slices, enabling precise segmentation, landmark identification, and pathology detection. CNNs have revolutionized medical imaging by enhancing automated image analysis, treatment planning, and outcome prediction. With continued advancements in imaging technology and data availability, CNNs are poised to further improve patient care and treatment outcomes.

Our research group has a notable example of applying CNNs to 2D dental imaging. Specifically, we utilize ResNet [16], one of the most widely recognized and widely used CNN architectures. Our objective is to predict the Index of Orthodontic Treatment Need for Aesthetic Components (IOTN-AC) based on intraoral photographs, as depicted in Figure 2. The IOTN-AC system is a well-established framework that assesses the aesthetic component of orthodontic treatment needs across 10 different levels. To simplify the classification, we grouped the 10 levels into two categories: "no need" (AC 1-5) and "need for treatment" (AC 6-10).

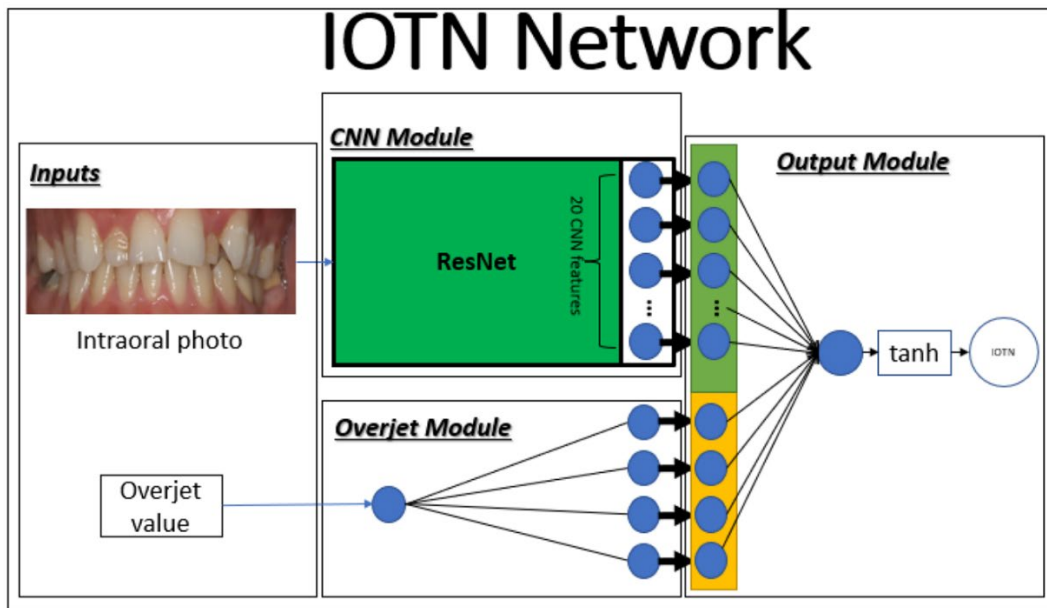


Figure 2. The IOTN Network, composed of two modules: the CNN module and the Overjet module, respectively. The CNN module is used for image processing, while the Overjet module is dedicated to assessing overjet value. Image reprinted with permission from [17].

Given that IOTN-AC classification requires both the intraoral photograph and the overjet value as inputs, we have developed a specialized network called IOTN Network [17]. This network comprises two components: a ResNet to process the intraoral photos and an MLP to handle the overjet values. By integrating these components, we trained the IOTN Network on a dataset of 500 samples. The achieved results demonstrate promising performance, with an accuracy of 0.76, a positive predictive value of 0.72, and a negative predictive value of 0.88.

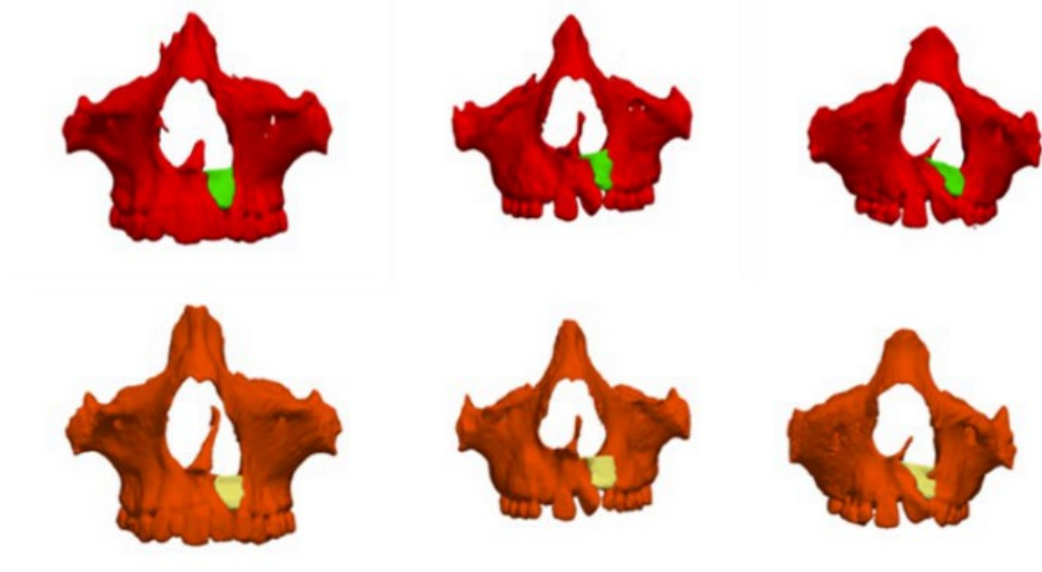


Figure 3. Comparison of automated 3D U-Net segmentation results (first row) versus manual segmentation (second row). Maxillae are denoted by the red and orange segments, while cleft defects are represented in green and yellow. Reprinted with permission from [18].

Segmenting defects on the CBCT scans of patients with cleft lip and palate serves as an example of 3D CNN application. Wang et al. employed the widely recognized 3D U-Net architecture, a popular CNN structure for image segmentation, to accurately segment the maxillary region and the defect (Figure 3). The segmentation achieved an average Dice similarity coefficient of 0.92 ± 0.01 for the maxilla and 0.77 ± 0.06 for the defect [18].

Additionally, 3D mesh data are commonly used in orthodontics to represent the surface geometry of dental structures. Meshes are created by connecting individual vertices, edges, and faces, resulting in a detailed representation of the dental surface. These data are often derived from intraoral scanners or surface reconstructions from CBCT and enable orthodontists to analyze tooth morphology, occlusal relationships, and other anatomical features.

Unlike pixel-based images or volumetric data, 3D mesh data does not have a fixed grid structure, making it challenging to directly apply CNNs designed for regular grids. CNNs rely on the fixed neighborhood connections defined by the grid, which are absent in mesh data. This lack of a fixed structure in mesh data makes it difficult for CNNs to effectively capture the spatial relationships and connectivity information between vertices. As a result, CNNs are not suitable for processing 3D mesh data. However, Graph Neural Networks (GNNs) have emerged as a powerful alternative. GNNs leverage the inherent graph structure of the mesh data, allowing for flexible and adaptive message passing between vertices. By considering the connectivity information, GNNs can capture the complex spatial dependencies and extract meaningful features from the mesh. Therefore, GNNs are well-suited for processing 3D mesh data in dentistry, enabling tasks such as mesh segmentation [9, 19–22] and landmark identification [9, 23–26]. While GNNs are the most suitable network for processing 3D mesh data, some studies have used a different approach. Specifically, they convert 3D mesh data into 2D feature maps, which can be effectively analyzed using 2D CNN [27].

A notable example of GNN application in dental imaging is MeshSegNet, a GNN-based model specifically developed for precise tooth segmentation on intraoral scans [21]. By leveraging the inherent graph structure of dental mesh data, MeshSegNet effectively analyzes the connectivity and relationships between vertices, resulting in accurate tooth segmentation (Figure 4).

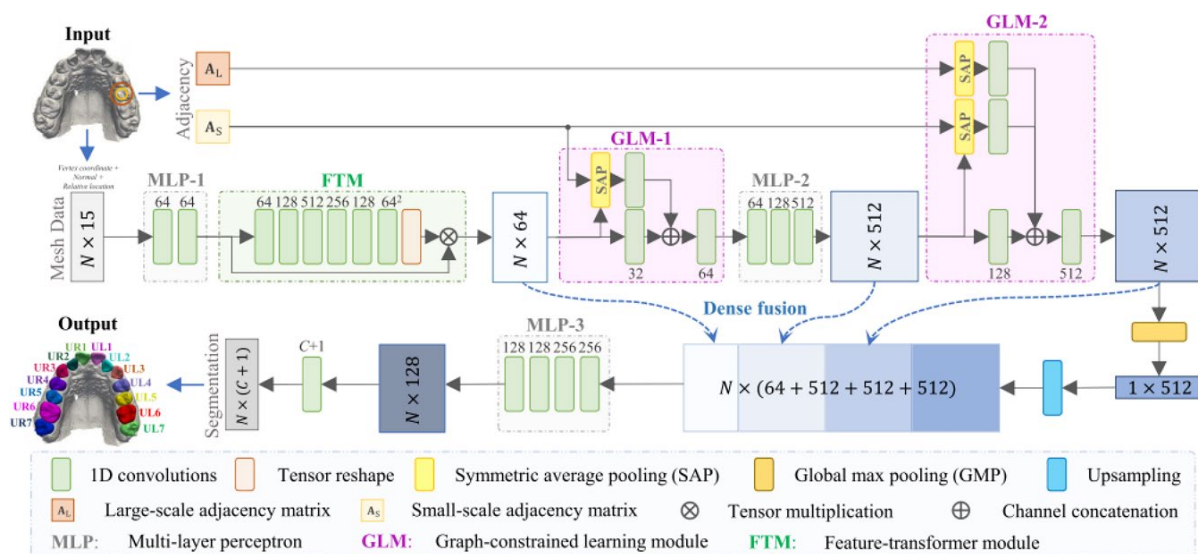


Figure 4. Schematic illustration of MeshSegNet for automated tooth labeling process on raw 3D dental surfaces mesh. Reprinted with permission from [21].

Building on the success of MeshSegNet, our research group introduced the Two-Stage Mesh Deep Learning (TS-MDL) framework, which employs a two-network approach for comprehensive tooth segmentation and landmark identification on 3D mesh data (Figure 5) [9]. The first network in the TS-MDL framework is *iMeshSegNet*, an enhanced version of MeshSegNet tailored to improve both efficiency and accuracy in tooth segmentation tasks. Leveraging advancements in GNNs and incorporating architectural improvements, *iMeshSegNet* delivers more precise and efficient tooth segmentation.

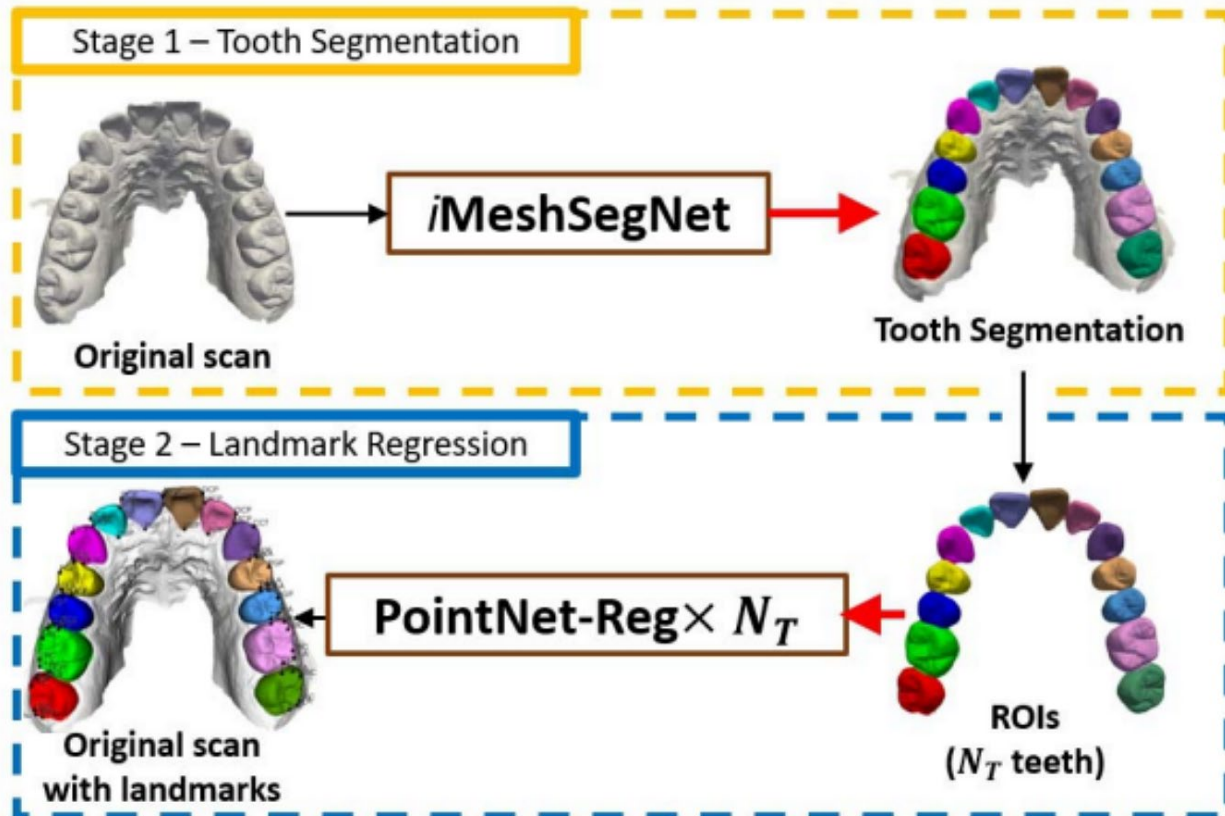


Figure 5. Depiction of the TS-MDL workflow, demonstrating the process of automated tooth segmentation and precise dental landmark localization. ROI denotes the region of interest. Reprinted with permission from [9].

In the second stage of the TS-MDL framework, PointNet-Reg, a point-based DL model, is employed for landmark identification. PointNet-Reg capitalizes on the 3D coordinates of points within the dental mesh data, enabling accurate identification and localization of key landmarks. The combination of *iMeshSegNet* and PointNet-Reg within the TS-MDL framework facilitates comprehensive analysis of dental mesh data, empowering both tooth segmentation and landmark identification tasks.

By utilizing both 2D and 3D image data with DL, dentists and orthodontists can efficiently gain valuable insights into the complex structures of the oral cavity, aiding in diagnosis, treatment planning, and monitoring of orthodontic interventions. Advances in imaging technologies and ML techniques have opened up new opportunities for automated analysis and interpretation of these images, empowering clinicians with more efficient and accurate tools for orthodontic treatment.

Text

Text data is another type of unstructured data that consists of natural language text, such as patient-doctor dialog, symptom descriptions, or clinical observations. Unlike tabular data and images, text data are represented as sequences of discrete symbols, typically characters or words. To process text data with neural networks, a crucial step involves converting the text into numerical representations that can be used as input. This process is known as text encoding or embedding, where words or characters are mapped to dense vectors in a continuous space. These numerical representations capture the semantic and contextual information of the text, enabling neural networks to analyze and make predictions [28–30].

For processing text data, various network architectures have been employed. While recurrent neural networks (RNNs) [31] such as long short-term memory [32] and gated recurrent unit [33] have been popular for handling sequential data, the transformer model has emerged as a powerful alternative. The transformer network has revolutionized natural language processing (NLP) by utilizing self-attention mechanisms [34]. Unlike RNNs, transformers do not rely on sequential processing, making them highly parallelizable and efficient for capturing long-range dependencies in text data. Transformers have demonstrated superior performance in tasks such as machine translation, document classification, and sentiment analysis. Many state-of-the-art large language models (LLMs), including BERT [35], GPT-3 [36], and LLaMA [37], are built based on the transformer architecture, further showcasing its effectiveness in processing text data.

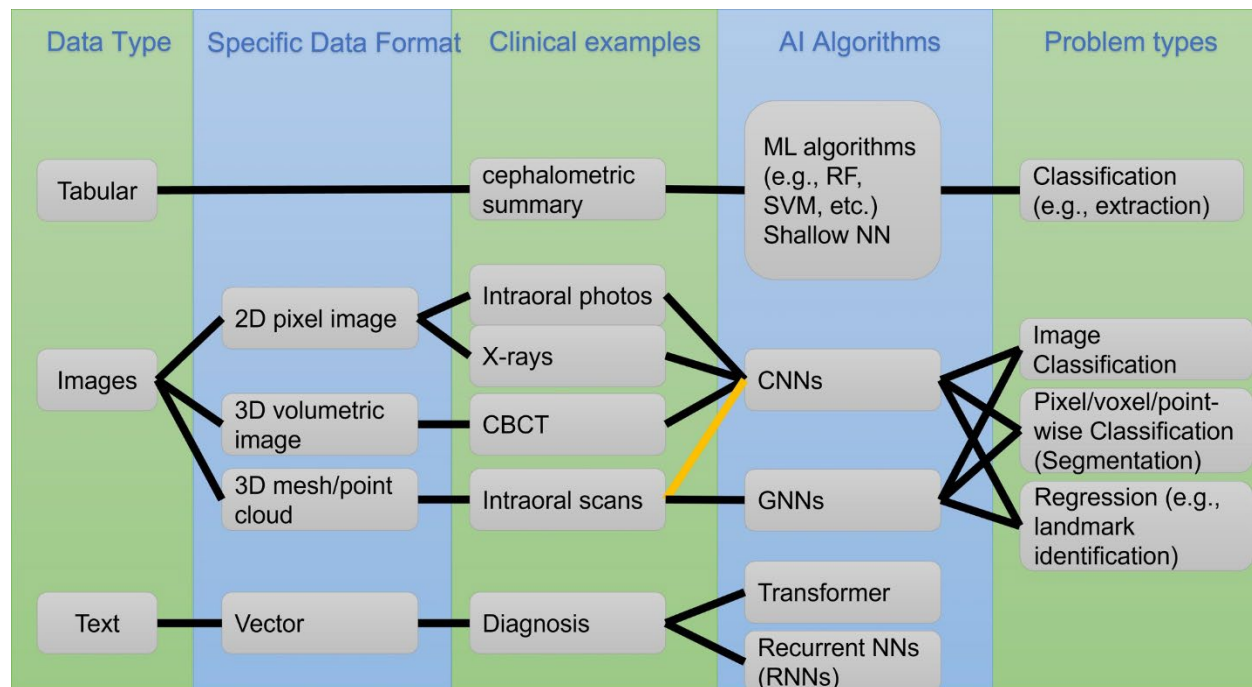


Figure 6. Figure illustrates the interconnections between data types, AI algorithms, and corresponding clinical problems. The yellow line symbolizes the transformation of data format from 3D mesh to 2D pixel images.

In the field of dentistry, DL techniques coupled with NLP have shown promising results in various applications. For instance, researchers have utilized DL models to analyze and classify dental treatment plans, automate clinical documentation, or extract relevant information from patient records. Notable studies include two by Chihiro et al. that used DL-based NLP to create a prioritized problem list and

treatment plan [38, 39]. These studies demonstrated the potential of DL in extracting meaningful insights from text data in the dental domain.

Neural networks offer a versatile framework for handling various data types in the AI and ML. Tabular data, such as demographic or cephalometric summaries, can be effectively processed using ML models including RF, SVM, or MLP. For pixel-based image data, CNNs have shown remarkable performance in tasks such as image classification and segmentation, with advancements such as 2D and 3D convolutions tailored to the specific image dimensions. For mesh data, such as 3D representations of dental structures, GNNs provide a powerful tool to capture the complex relationships and dependencies inherent in the mesh structure. Text data, including treatment plans and clinical notes, can be encoded using techniques such as RNN or transformer-based models including BERT, enabling effective analysis of sequential information. All these relationships are included in Figure 6. By understanding the characteristics of different data formats and leveraging the power of suitable neural networks, researchers and practitioners in orthodontics can unlock the potential of AI for improving diagnosis, treatment planning, and patient care.

HOW TO IMPROVE THE PERFORMANCE OF AI MODELS

Once a clinician obtains an AI model for an orthodontic problem, the performance is usually not perfect. The question is how to improve the performance of the AI model. Enhancing the performance of AI models relies on several key strategies that can enhance their capabilities. Firstly, obtaining big and high-quality data is crucial, as it allows the model to learn from a wide range of examples, improving generalization and robustness. For example, gathering a vast collection of annotated X-ray images from different patients with various dental conditions can enhance the accuracy of an AI model for tooth segmentation. It is worth emphasizing again that the data quality also needs to be addressed. A large number of poor-quality samples in the dataset could negatively impact the model performance.

Secondly, developing advanced network architectures plays a vital role in improving performance. These architectures are designed to more effectively and efficiently extract features and capture underlying patterns in the data. For instance, CNNs are widely used in dental image analysis due to their ability to automatically learn relevant visual features. Utilizing deeper and more complex networks, such as ResNet [16] or DenseNet [40], can further enhance the model's ability to recognize intricate patterns in dental images, leading to improved diagnostic accuracy. However, it is important to keep in mind that network design is crucial and that deeper networks are not always better. The complexity of a network should be meaningful and focused on efficiently extracting informative features based on the data types.

Lastly, employing advanced training strategies can significantly boost model performance. Contrastive learning is an example of such a strategy. By learning a general representation from a large set of unlabeled data, the model can capture the intrinsic structure and similarities between different samples. This pre-training step can be followed by fine-tuning the network on specific dental image tasks, such as tooth classification or disease detection. This two-step process enables the model to leverage both general knowledge learned from a large dataset and specific knowledge fine-tuned for a particular dental analysis task.

CONCLUSIONS

This chapter underscores the transformative potential of AI in revolutionizing digital orthodontics. Through a comprehensive exploration of digital orthodontics' workflow and an in-depth discussion of AI

applications, we have shown how AI - particularly DL - can manage complex orthodontic data in a way that far exceeds traditional ML methods. Our examination of various data formats and corresponding neural networks, supplemented by practical examples from the dental field, demonstrates the vast applicability of AI in the orthodontic arena. From classification and regression to image segmentation and landmark identification, AI holds the promise of significantly enhancing diagnostic accuracy and treatment planning. The chapter also offers insights into optimizing AI model performance, elucidating the importance of dataset size and quality, advanced network architectures, and innovative training strategies. Given the tremendous potential of AI, we advocate for continued research and the integration of AI applications in digital orthodontics to revolutionize patient care. By navigating this confluence of technology and dentistry, we can create a future where personalized, high-quality care becomes an accessible standard for all patients.

REFERENCES

1. Kim S-H, Kim KB, Choo H. New frontier in advanced dentistry: CBCT, intraoral scanner, sensors, and artificial intelligence in dentistry. *Sensors* 2022;22(8):2942.
2. Goodfellow I, Bengio Y, Courville A. *Deep learning*. MIT press; 2016.
3. Christiano PF, Leike J, Brown T, Martic M, Legg S, Amodei D. Deep reinforcement learning from human preferences. *Adv Neural Inf Process Syst* 2017;30.
4. Marcus G. Deep learning: a critical appraisal. *arXiv Prepr arXiv180100631*. 2018.
5. Welikala RA, Remagnino P, Lim JH, Chan CS, Rajendran S, Kallarakkal TG, et al. Automated detection and classification of oral lesions using deep learning for early detection of oral cancer. *IEEE Access* 2020;8:132677–132693.
6. Hao P, Chokuwa S, Xie X, Wu F, Wu J, Bai C. Skeletal bone age assessments for young children based on regression convolutional neural networks. *Math Biosci Eng* 2019;16(6):6454–6466.
7. Cui Z, Fang Y, Mei L, Zhang B, Yu B, Liu J, et al. A fully automatic AI system for tooth and alveolar bone segmentation from cone-beam CT images. *Nat Commun* 2022;13(1):2096.
8. Gillot M, Baquero B, Le C, Deleat-Besson R, Bianchi J, Ruellas A, et al. Automatic multi-anatomical skull structure segmentation of cone-beam computed tomography scans using 3D UNETR. *PLoS One* 2022;17(10):e0275033.
9. Wu T-H, Lian C, Lee S, Pastewait M, Piers C, Liu J, et al. Two-stage mesh deep learning for automated tooth segmentation and landmark localization on 3D intraoral scans. *IEEE Trans Med Imaging* 2022;41(11):3158–3166.
10. Xie X, Wang L, Wang A. Artificial neural network modeling for deciding if extractions are necessary prior to orthodontic treatment. *Angle Orthod* 2010;80(2):262–266.
11. Jung S-K, Kim T-W. New approach for the diagnosis of extractions with neural network machine learning. *Am J Orthod Dentofacial Orthop* 2016;149(1):127–133.
12. Li P, Kong D, Tang T, Su D, Yang P, Wang H, et al. Orthodontic treatment planning based on artificial neural networks. *Sci Rep* 2019;9(1):2037.
13. Grinsztajn L, Oyallon E, Varoquaux G. Why do tree-based models still outperform deep learning on tabular data? *arXiv Prepr arXiv2207.08815*. 2022.
14. Etemad L, Wu T-H, Heiner P, Liu J, Lee S, Chao W-L, et al. Machine learning from clinical data sets of a contemporary decision for orthodontic tooth extraction. *Orthod Craniofac Res* 2021;24 Suppl 2:193–200.
15. Suhail Y, Upadhyay M, Chhibber A, Kshitiz. Machine learning for the diagnosis of orthodontic extractions: a computational analysis using ensemble learning. *Bioengineering* 2020;7(2):55.
16. He K, Zhang X, Ren S, Sun J. Deep residual learning for image recognition. In: *Proceedings of the IEEE*

- conference on computer vision and pattern recognition. 2016. p. 770–778.
17. Stetzel L. Artificial intelligence (AI) for predicting the aesthetic component (AC) of the Index of Orthodontic Treatment Need (IOTN). The Ohio State University; 2023.
 18. Wang X, Pastewait M, Wu TH, Lian C, Tejera B, Lee Y-T, et al. 3D morphometric quantification of maxillae and defects for patients with unilateral cleft palate via deep learning-based CBCT image auto-segmentation. *Orthod Craniofac Res* 2021;24 Suppl 2108–2116.
 19. Zhao Y, Zhang L, Liu Y, Meng D, Cui Z, Gao C, et al. Two-stream graph convolutional network for intra-oral scanner image segmentation. *IEEE Trans Med Imaging* 2022;41(4):826–835.
 20. Cui Z, Li C, Chen N, Wei G, Chen R, Zhou Y, et al. TSegNet: An efficient and accurate tooth segmentation network on 3D dental model. *Med Image Anal* 2021;69:101949.
 21. Lian C, Wang L, Wu TH, Wang F, Yap P, Ko C, et al. Deep multi-scale mesh feature learning for automated labeling of raw dental surfaces from 3D intraoral scanners. *IEEE Trans Med Imaging* 2020;39(7):2440-2450.
 22. Ben-Hamadou A, Smaoui O, Rekik A, Pujades S, Boyer E, Lim H, et al. 3DTeethSeg'22: 3D teeth scan segmentation and labeling challenge. *arXiv Prepr arXiv2305.18277*. 2023.
 23. Lang Y, Chen X, Deng HH, Kuang T, Barber JC, Gateno J, et al. DentalPointNet: landmark localization on high-resolution 3D digital dental models. In Wang L, Dou Q, Fletcher PT, Speidel S, Li S, eds. *Medical Image Computing and Computer Assisted Intervention – MICCAI 2022 - 25th International Conference, Proceedings*. Springer Science and Business Media Deutschland GmbH. 2022. p. 444-452. (Lecture Notes in Computer Science (including subseries Lecture Notes in Artificial Intelligence and Lecture Notes in Bioinformatics)).
 24. Sun D, Pei Y, Li P, Song G, Guo Y, Zha H, et al. Automatic tooth segmentation and dense correspondence of 3D dental model. In: Martel AL, et al., eds. *Medical Image Computing and Computer Assisted Intervention – MICCAI 2020. Lecture Notes in Computer Science, vol 12264*. Cham: Springer International Publishing; 2020. p. 703–712.
 25. Baquero B, Gillot M, Cevidanes L, Turkestani N AI, Gurgel M, Leclercq M, et al. Automatic landmark identification on IntraOralScans. In: Chen Y, Linguraru MG, Shekhar R, Wesarg S, Erdt M, Drechsler K, et al., editors. *Clinical Image-Based Procedures. Lecture Notes in Computer Science, vol 13746*. Cham: Springer Nature Switzerland; 2023. p. 32–42.
 26. Lang Y, Deng HH, Xiao D, Lian C, Kuang T, Gateno J, et al. DLLNet: an attention-based deep learning method for dental landmark localization on high-resolution 3D digital dental models. *Med Image Comput Comput Assist Interv* 2021;12904:478–487.
 27. Zhang J, Li C, Song Q, Gao L, Lai Y-K. Automatic 3D tooth segmentation using convolutional neural networks in harmonic parameter space. *Graph Models* 2020;109(1):101071.
 28. Wang S, Zhou W, Jiang C. A survey of word embeddings based on deep learning. *Computing* 2020;102:717–740.
 29. Mikolov T, Sutskever I, Chen K, Corrado GS, Dean J. Distributed representations of words and phrases and their compositionality. *Adv Neural Inf Process Syst* 2013;26:3111-3119.
 30. Mikolov T, Chen K, Corrado G, Dean J. Efficient estimation of word representations in vector space. *arXiv Prepr arXiv1301.3781*. 2013.
 31. Elman JL. Finding structure in time. *Cogn Sci* 1990;14(2):179–211.
 32. Hochreiter S, Schmidhuber J. Long short-term memory. *Neural Comput* 1997;9(8):1735–1780.
 33. Cho K, Van Merriënboer B, Gulcehre C, Bahdanau D, Bougares F, Schwenk H, et al. Learning phrase representations using RNN encoder-decoder for statistical machine translation. *arXiv Prepr arXiv1406.1078*. 2014.
 34. Vaswani A, Shazeer N, Parmar N, Uszkoreit J, Jones L, Gomez AN, et al. Attention is all you need. *Adv Neural Inf Process Syst* 2017;30.
 35. Devlin J, Chang M-W, Lee K, Toutanova K. Bert: Pre-training of deep bidirectional transformers for

- language understanding. arXiv Prepr arXiv1810.04805. 2018.
36. Brown T, Mann B, Ryder N, Subbiah M, Kaplan JD, Dhariwal P, et al. Language models are few-shot learners. *Adv Neural Inf Process Syst* 2020;33:1877–1901.
 37. Touvron H, Lavril T, Izacard G, Martinet X, Lachaux M-A, Lacroix T, et al. LLaMA: open and efficient foundation language models. arXiv Prepr arXiv2302.13971. 2023.
 38. Shimizu Y, Tanikawa C, Kajiwara T, Nagahara H, Yamashiro T. The validation of orthodontic artificial intelligence systems that perform orthodontic diagnoses and treatment planning. *Eur J Orthod* 2022;44(4):436–444.
 39. Kajiwara T, Tanikawa C, Shimizu Y, Chu C, Yamashiro T, Nagahara H. Using natural language processing to develop an automated orthodontic diagnostic system. arXiv Prepr arXiv1905.13601. 2019.
 40. Huang G, Liu Z, Van Der Maaten L, Weinberger KQ. Densely connected convolutional networks. 2017 IEEE Conference on Computer Vision and Pattern Recognition (CVPR). 2016. p. 2261-2269.

EXTENDED REALITY TECHNOLOGY IN ORTHODONTICS AND DENTISTRY

Esther Suh and Hera Kim-Berman

ABSTRACT

In the 56th volume of the Craniofacial Growth Series monograph, we introduced the concepts of virtual and augmented reality in dentistry. (<https://deepblue.lib.umich.edu/handle/2027.42/153991>) Since then, recent advances in extended reality (XR) technologies, particularly augmented reality have made a significant impact in medical and dental fields. Unlike virtual reality, augmented reality integrates virtual elements into the real world, resulting in a more authentic interactive experience. Research is being conducted to evaluate the benefits of using these technologies and their potential to teach and train students the necessary clinical skills to succeed. This chapter reviews and updates the latest uses of XR technologies for medical and dental education and clinical practice.

Key Words: Extended Reality, Virtual Reality, Augmented Reality, Simulations for Medical and Dental Applications

INTRODUCTION

With advancing technology, extended reality (XR) applications have made a recognizable presence in dental and medical education, and clinical practice [1, 2]. While terms are sometimes misused due to similarity in definitions, XR is commonly accepted as an umbrella term that includes virtual reality (VR), augmented reality (AR), and mixed reality (MR) technologies [2]. VR is a technology that completely immerses the user in a virtual environment with the use of a head-mounted display (HMD). The user can engage with the virtual environment and interact with and manipulate objects in the entirely computer-generated simulation in real-time. Although by definition VR is an immersive experience, non-immersive VR using stereoscopic glasses or screen monitors is also used for dental and medical applications. In contrast to VR, AR has the capability to overlay or superimpose digital information on real objects of an existing reality. Software developers have incorporated AR technology in applications used on mobile devices and HMDs to bring together the digital and real world [1, 2]. MR is considered to be somewhere between VR and AR, blending the real and virtual worlds and allowing users to interact with physical and virtual objects and environments [2]. The term MR was first coined in 1994 by Milgram and Kishino [3]. Some define MR as a similar, more specific, newer development, and extension of AR [4, 5]. Other definitions consider MR as a blend of AR and VR. AR and MR are often used interchangeably in literature, depending on the type of device and software used, though AR is considered a more general term [2, 5]. AR and VR applications are utilized and recognized in several fields, which include entertainment, healthcare, architecture, civil engineering, manufacturing, defense, tourism, automation, marketing, and education. In the epidemiological context of the coronavirus pandemic of 2019 (COVID-19), these technologies have seen a significant advancement in demand, research and development, and implementation across various fields. During and after the time of global shutdown and social distancing, XR technologies have become prevalent in telemedicine, online education and training, marketing, and

healthcare monitoring in the healthcare field [2]. Since VR and AR have fundamental differences, their current applications in the medical and dental literature are presented separately.

VR

VR applications in medical training and education are prevalent in current literature. VR can be immersive where the user is totally dissociated from their environment and non-immersive where the user still has some connection to the real world. Two major uses of VR in medical education include surgical VR simulators and use of three-dimensional (3D) anatomical models and virtual worlds [6] (Figure 1). Examples of VR modalities often used to practice surgical psychomotor skills include, but are not limited to, training in laparoscopic surgery, suturing, and robotics surgery [7-12]. In a meta-analysis of randomized controlled studies evaluating the effectiveness of virtual reality-based technology in teaching medical anatomy, the authors reported a moderate enhancement in test scores from learners using VR compared to students with conventional or other 2D digital methods [13]. When looking at student satisfaction, most students were more interested in using VR to learn anatomy, commenting on better 3D visualization of anatomical structures and benefit of using VR as a complement to traditional teaching methods [13-16]. Advantages of VR applications have been identified in multiple medical disciplines, including dentistry.



Figure 1. Image of student with head mounted device using virtual reality application to learn 3D imaging concepts and anatomy.

VR modalities have been applied in dental education and across various dental specialties including restorative dentistry, endodontics, oral and maxillo-facial surgery (OMFS), orthodontics, and pediatric dentistry [1]. VR educational tools were shown to improve student knowledge in cone beam computed tomography (CBCT) 3D imaging concepts, head and neck anatomy education, and student engagement in learning [17]. In Liebermann and Erdelt, VR simulations enhanced student learning of dental morphologies beyond the traditional textbook, showing a high level of acceptance among students [18]. A similar study showed that students adapted well to a VR simulation and improved comprehension in root canal anatomy, expressing VR simulations were better than CBCT scanning and radiography at visualizing root canals [19]. When investigating the impact of VR simulation in preclinical endodontics training, 85% of participating

students supported the use of VR training to supplement conventional training on dental mannequins, while also recommending needed improvements of it [20]. A majority of VR research is educational in the realm of training motor skill acquisition in preclinical restorative dentistry [1].

Various studies utilized a non-immersive VR simulator, the Simodont® (Nissin Dental Products Inc., Nieuw-Vennep, Netherlands), a haptic 3D VR dental training simulator that allows preclinical training in dental caries removal, cavity preparation, crown preparation, endodontic procedures, and more. These studies reported that the Simodont® may be a valuable adjunct to training dental students in preclinical motor skills [21-23]. Some benefits of the VR technology that were noted included practice repeatability to minimize material consumer costs, enhancement of student self-confidence and performance, and facilitation of patient safety during clinical dental care [24]. The simulation used as an adjunct to the predoctoral direct restorations course would also benefit a student needing remediation [22]. Hattori et al. evaluated whether faculty feedback significantly impacted student learning and skill acquisition when using a VR simulation system for crown preparation, and found there were no significant differences between groups with those who received feedback completing the initial stages of crown preparation slightly quicker than those who did not [25]. Their study also reported that the students who used the VR simulator acquired higher crown preparation scores, suggesting that the use of a VR simulation system improved student training in crown preparation. In contrast, Vincent et al. and Dwisaptarini et al., studying VR simulation in cavity preparation and caries removal, respectively, reported similar improvement or performance between VR simulation and conventional plastic analogue-trained groups [24, 26]. Vincent et al. commented on the benefits of VR, however, such as allowing a more objective criteria assessment lacking in evaluations conducted on plastic analogue teeth, increasing efficiency by reducing supervision and teaching time, and considering the material gain offered by VR [24]. A unique characteristic of VR, as reported by Hattori et al., is the presence of haptics, being able to simulate cutting sensations that impact operator performance. Hattori et al. recommend taking VR characteristics into account when developing and utilizing the haptics simulator [25]. To test construct validity of a 3D immersive haptic simulator, Eve et al. compared the caries removal performance of predoctoral students to graduate prosthodontics residents, and found that the performance measured significantly differed between the two groups. Their study confirmed sufficient sensitivity of the VR simulator to discern between novice and experienced users, supporting the construct validity of the technology [27].

In a study looking at the impact of VR simulation, conventional animal model training, and a combination of both in teaching oral implantology, the groups with combined training using VR and animal models performed significantly higher on a theoretical examination [28]. In 2018, Pulijala et al. found that VR simulation of Le Fort I osteotomy surgeries improved the knowledge and self-confidence of surgical residents [29]. Similarly, a VR application in surgical simulation in orthodontic residents was demonstrated as an appropriate alternative to 2D conventional orthognathic surgery simulation methods when combined with traditional orthodontic records. Though the study noted training is required to familiarize users to the VR technology, residents expressed readiness to adopt the VR simulation [30]. Only a handful of available literature is described, but the aforementioned studies reflect the broad application of VR simulation in dental education.

With increasing prevalence of immersive VR technologies and utilization of stereoscopic displays and systems that track a user's viewpoint to coordinate a virtual scene, cybersickness, blurred vision, and disorientation are common adverse effects reported by users [2, 31-33]. Cybersickness is a visually-induced motion sickness that occurs due to the user's visual perception of motion without actual physical motion. The degree of intensity was cited to depend on the exposure duration and nature of the virtual

content and display technology [2]. The nature of VR as providing full virtual immersion can contribute to these adverse effects.

AR

AR/MR-based optical see-through HMDs (OST-HMD) and their applications in medicine and dentistry enable users to see through the display like a pair of glasses to visualize real and virtual contents simultaneously [34] (Figure 2). Cybersickness has been reported in AR HMD users as well [33]. However, AR devices integrate information from the real and virtual environments, which should reduce the occurrence of adverse health effects VR users experience, namely cybersickness, blurred vision, and disorientation [33]. Although AR and VR both feature immersive experiences, AR incorporates additional information into the physical environment, which is an advantage to AR systems when used in real operations since users are allowed to ‘see through’ reality [32]. Thus, AR seems to have greater benefit in terms of minimizing adverse health effects and maintaining a sense of physical reality or realism.

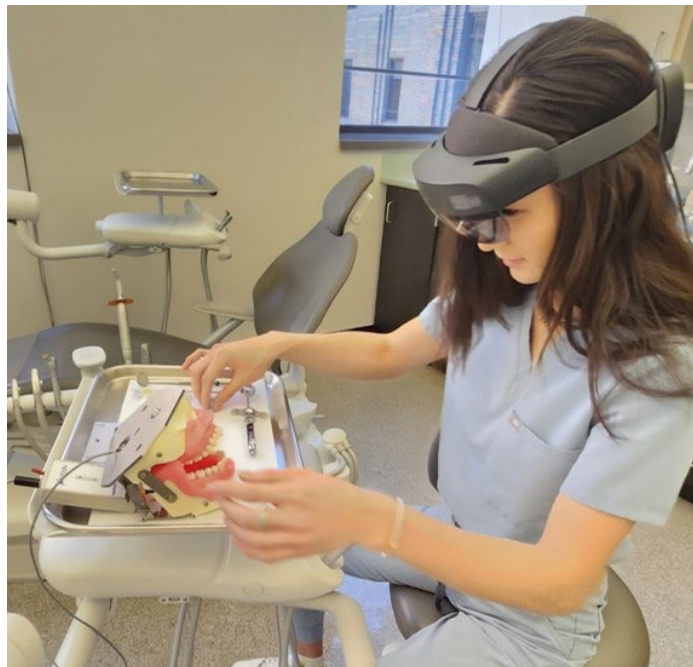


Figure 2. Image of a student wearing the HoloLens2, an augmented reality headset.

A list of commercially available OST-HMDs includes, but is not limited to, Microsoft HoloLens 2 (Microsoft Corporation, Redmond, WA, USA) released in 2019, Magic Leap 2 (Magic Leap, Inc., Plantation, FL, USA) released in 2022, and Apple Vision Pro (Apple Inc., Cupertino, CA, USA) released in 2024 [34-36]. There have been rapid advancements and developmental demands of these AR/MR technologies in recent years. In 2016, Microsoft Corporation released the first generation of HoloLens, Microsoft HoloLens 1 (Microsoft Corporation, Redmond, WA, USA), described as the first fully self-contained holographic computer to run Microsoft’s operating system, Windows 10 (Microsoft Corporation, Redmond, WA, USA). The HoloLens 1 was offered as MR smart glasses able to display an environment where real and virtual elements are perceived to coexist. Three years later, in 2019, Microsoft released an improved version, HoloLens 2, that features an enhanced field of view, reduced overall weight, and longer battery life [37].

Based on available literature, studies across medical and dental disciplines have shown the various applications and advantages of HoloLens programs. In Palumbo's systematic review of the Microsoft HoloLens 2 in medicine and healthcare, the two sub-field applications with the highest quantity of included studies were surgical navigation (29 studies) and medical education and training/virtual teaching/telementoring/teleconsulting (9 studies) [2]. In medical education, the implementation of AR/MR technology using the HoloLens hardware is prevalent in areas such as anatomy and pathology, surgery, procedural and operative care, etc. The use of cadaveric specimens to teach human anatomy has been a part of academic debate for its high cost, ethical considerations, and limited accessibility [38]. Studies have investigated alternative teaching methods such as AR programs in attempts to replace or supplement the conventional cadaveric teaching model [33, 38-40]. A few studies evaluating the effectiveness of learning anatomy using the HoloLens showed no significant differences in test scores between students who used the HoloLens and those who did not. However, these studies concluded that the AR-based HoloLens interventions were rated positively by users, improving learner engagement and motivation [39-42]. In a human anatomy course, second-year medical students were given multiple-choice exams after learning anatomy from a 3D printed skull model with either a textbook or an AR application that could be used on a tablet or HoloLens 2. The results reported no significant difference in test results between the two learning methods. However, the students expressed interest, enthusiasm, and motivation to learn using the AR application, suggesting potential long-term memory retention [40]. In 2021, Moro et al. compared the use of HoloLens with mobile-based AR anatomy learning in healthcare students, and found no significant difference in knowledge acquisition based on test scores. Slight dizziness was reported more frequently by the students who used the HoloLens, which the authors claim this adverse health effect did not appear to impact learning or student perception of the technology based on the test scores and positive questionnaire responses [41]. Geerlings-Batt et al. found that AR models of bony foot and ankle anatomy visualized using the HoloLens 2 were accurately demonstrated in relation to the associated musculature. Their study stated that the process of segmenting the musculature, however, was time-consuming and lacked effective object recognition tools that may limit the reproducibility of the learning tool on a larger scale [38]. Many studies show AR-based HoloLens applications have the potential to replicate realistic anatomy and be utilized as a valid anatomy teaching tool [39-42].

Despite the drawbacks noted by some studies, a benefit to utilizing the HoloLens in medical education was the ability for remote instruction, supervision, consultation, telehealth, and mentoring [43, 44]. In 2018, pathology residents in Hanna et al.'s study performed an autopsy wearing the HoloLens as the AR software provided remote instructions with real-time diagrams, annotations, and voice instruction. The AR tool supported real-time telepathology, enabling users to remotely access a pathologist who was able to guide, supervise, and virtually annotate objects in the MR environment. Their study listed other advantages such as comfort, ease of use, sufficient computing power, and high-resolution imaging associated with the HoloLens device and software [43]. Another study demonstrated the feasibility of using MR-enabled synchronous mentoring of various surgeries in the context of combat casualty care, suggesting that the technology's accessibility to remote mentoring is valuable in the military due to decreased availability of certain surgical specialties [44].

The HoloLens has also been used as an instructional tool in teaching practical medical procedures [45, 46]. In 2020, Schoeb et al. evaluated a step-by-step MR guidance system using the HoloLens to instruct medical students on bladder catheter placement, and found the students who used the MR system performed objectively better on a performance test than those who did not, but the MR students subjectively rated the MR system with less usability [45]. In addition to teaching practical medical procedures, the AR-based HoloLens may improve adherence to procedural guidelines such as the Newborn Life Support (NLS) guideline in neonatal resuscitation, which may, in turn, decrease deviations

and errors in neonatal resuscitation and improve neonatal mortality rates [46]. Considering the quantity of practical or sophisticated medical procedures performed, literature has shown AR has a vast potential for medicine and medical education. This applies to the field of dentistry as well.

Literature includes various applications of AR in dental medicine and education. Some studies have evaluated the validity, effectiveness, or usability of AR-based mobile smartphone systems to assess knowledge in dental anatomy and preclinical skills such as tooth carving and tooth preparation, and remotely training procedural skills such as intraoral examination and dental charting [47-50]. While students in some of the studies regarded the mobile-based AR tool as useful and user-friendly, students in Kim-Berman et al.'s study found difficulty viewing and manipulating objects in the AR application and did not favor the AR application, which was reported to have been due to limitations in application familiarity and application-related technical difficulties experienced [47-50]. Nevertheless, most of the students in these studies expressed that the AR applications they utilized were useful or have the potential to be effective study tools.

AR applications using HMDs such as the HoloLens have received positive feedback from students learning dental anatomy as well [51, 52]. Dolega-Dolegowski et al.'s study determined the feasibility of visualizing the internal dental root anatomy using an AR holographic system on the HoloLens 2 [51]. Their application enabled users to project and interact with semi-translucent 3D holograms of dental roots in the user's natural dental operatory setting. Based on participant survey responses, the students expressed good usability, visualization, and effectiveness of the AR-based HoloLens application. In 2021, Mahrous et al. assessed student perception of four distinct learning modalities (use of natural extracted teeth, 3D-printed teeth, 3D virtual models, and AR-based models) for a dental anatomy course, and found that, in general, students rated the natural extracted teeth of highest educational value, 3D-printed teeth the most accessible, and the AR model viewed using a HMD as the most interesting [52]. Grad et al.'s study compared the suitability of 3D-printed models to AR models visualized in HoloLens 1, and concluded that AR models could be helpful in learning dental anatomy, but was not a suitable replacement for physical models. Grad et al. suggested that these AR methodologies have the potential to supplement dental anatomy education but need further improvement before integration into the dental curriculum [53]. Head and neck anatomy is a course in the dental school curriculum traditionally taught with cadavers, but with concerns surrounding cadaveric teaching, researchers have searched for alternative teaching methods such as AR anatomy training applications on the HoloLens. According to Zafar and Zachar, however, 36.5% of students agreed that the AR anatomy training increased confidence in anatomy skills, 34.1% agreed it added adjunctive value to the traditional method of learning, and 75.3% agreed the AR teaching application should not replace traditional cadaver training. Their study showed that the students demonstrated increased engagement and enjoyment using the AR application, suggesting that the AR tool still has a potential as an adjunct to cadaveric dental head and neck anatomy teaching [54].

Apart from dental education, AR technologies using the HoloLens device have been utilized in preclinical and clinical practice [55-59]. In a study to assess the validity and reliability of 3D holographic palatal superimpositions of pre- and post-treatment digital models of patients that underwent rapid maxillary expansion, Talaat et al. found that 3D digital dental models can be reliably superimposed in AR using the HoloLens to allow virtual assessment of orthodontic treatment outcomes [55]. Similarly, Liu et al. compared implant placement in an in vitro model of users of a MR-based HoloLens dental implant navigation system that provided real-time tracking and guidance to the conventional free-hand approach. While a small sample size (MR group, n=25 and control group, n=25) was mentioned as a limitation, their study found more precision in implant placement in the MR-based dental implant navigation system group,

suggesting it may be used in clinical practice to increase surgical convenience, real-time consultation or guidance, safety, and positional accuracy [57].

AR/MR applications have been used in clinical cases for procedures in dental extractions and surgery [56, 59]. Koyama et al. presented three clinical cases in which maxillary mesiodens extractions were performed using MR technology. Preoperatively, patient computed tomography (CT) Digital Imaging and Communications in Medicine (DICOM) data was acquired and read by an MR application using the HoloLens. The MR system was able to project a 3D holographic volume rendering of the CT image in the indirect field of surgical view while the surgeons performed the extractions. According to Koyama et al., the MR system allowed the oral surgeons to refer to the 3D virtual model without moving their field of view, suggesting it reduces treatment duration and increases the safety and accuracy of the surgery. Their paper listed limitations to the technology including challenges to manually superimposing the virtual image onto the patient, inability to perform virtual operations on holograms intraoperatively, and heavy weight of the HoloLens that may contribute to operator fatigue. However, the investigators utilized HoloLens 1, which is described as heavier and less balanced than the HoloLens 2. Another study that evaluated AR in HoloLens in the context of oral surgery involved the surgical intervention in treatment of an odontogenic cyst of the upper jaw. Lysenko et al. reports the first known use of a rigid endoscope, guided by AR technology, for surgical removal of an odontogenic cyst. An AR marker used to anchor the projected hologram to the real environment was fixed above the patient's nasal bone, which allowed the AR system to overlay a 3D image of the patient's CT model onto the patient's anatomical structures. The AR navigation system enabled the surgeon to virtually visualize the position of the endoscope tip as it entered soft tissue, allowing the removal of the cyst from the area of the left upper second molar without damage to surrounding structures. According to their case study, their positive outcome suggests the AR HoloLens system will improve quality of life and surgical accuracy, reduce operational risks, and shorten operation and recovery time [59].

A potential use case for the use of AR is the Augmented Reality Inferior Alveolar Nerve (ARIAN) injection simulation that has been recently developed by our research group. In dentistry, the most common procedure that is taught and used in practice to anesthetize mandibular teeth is the direct inferior alveolar nerve block (IANB) injections [60]. However, it is considered to have the highest clinical failure rate. Reasons associated to IANB failure include anatomical variations, pathology, pharmacological differences, psychological status, and poor technique, which is the most common reason for failure of the conventional IANB [60, 61]. Although alternative injection techniques have been described in literature, the direct IANB is still the most commonly taught and widely used mandibular block anesthetic technique [60]. Local anesthesia in dental school is mainly taught in the form of didactic instruction based on textbooks and lectures in combination with student-to-student injections and/or simulations using anatomic models. Some dental schools have shifted away from student-to-student injections due to legal, ethical, and physical safety considerations associated with novices performing the procedure on one another [62]. Cadaveric instruction is commonly used to teach anatomy, so cadaver models have been used as a teaching aid for local anesthesia training. However, many dental schools do not utilize cadaver models, potentially due to accessibility, ethical and financial objections. Studies that assess the efficacy of non-cadaveric anatomic models used for local anesthesia training report conflicting recommendations on its use with the most reported limitation being the inaccuracy of anatomical replication and realism of the models. These studies suggest anatomic models may be beneficial to student learning, but need further development and investigation [63-67]. Most students feel their IANB training during dental school was insufficient in preparing them for real patient administration of the IANB, frequently mentioning the lack of knowledge of anatomy and complications of anesthetics [68]. Therefore, there is a need to validate

alternative methods to train the IANB using more realistic models, so dental students are more prepared for real patient administrations and improve their IANB success rate.

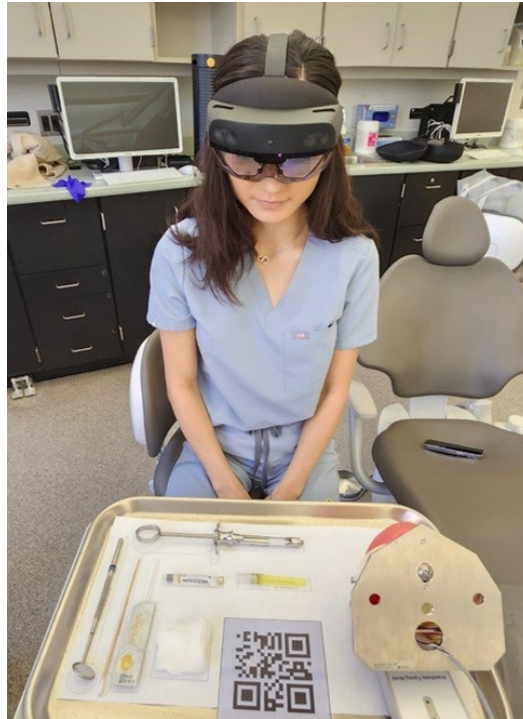

Figure 3. Student using the augmented reality inferior alveolar nerve (ARIAN) injection simulation to learn about the armamentarium necessary to deliver an injection.

Although VR has been applied in simulation training, the fully immersive nature of VR minimizes a user's sense of reality or realism, which was reported as an important consideration when designing an anatomic model. The reported benefits to the HoloLens include its portability, remote connectivity, real-time instruction and consultation, ability to interact with holographic information, audio quality, and visual resolution [43, 44]. In dentistry, AR HoloLens systems have been studied in dental anatomy, head and neck anatomy, treatment outcome evaluations, procedural training, and intraoperative surgical navigations [5, 51, 53-57, 59]. However, there is currently no literature presenting the validity, effectiveness, and usability of an AR HoloLens, or any OST-HMD, IANB training system.

Given the potential of anatomic models and guided AR HoloLens simulations to enhance the training of dental students in the IANB technique and procedure, the ARIAN injection simulation was developed by our research group (Figure 3). Using the HoloLens 2 OST-HMD several educational training modules were developed to teach students on the armamentarium, syringe preparation and breakdown, landmark identification, correct positioning of the syringe, and delivery of the injection. Future research directions include evaluation of the AR-based training tool. These modules will be used to train novice and advanced learners in the delivery of IANB injections and their effectiveness and validity will be evaluated.

CONCLUSIONS

Advances in XR technology have made significant improvements in the medical and dental education and clinical practice. Exploration and implementation of the technology for various disciplines may change dental education and patient care for future clinicians.

REFERENCES

1. Joda T, Gallucci GO, Wismeijer D, Zitzmann NU. Augmented and virtual reality in dental medicine: a systematic review. *Comput Biol Med* 2019;108:93-100. Epub 20190315. doi: 10.1016/j.compbimed.2019.03.012. PubMed PMID: 31003184.
2. Palumbo A. Microsoft HoloLens 2 in medical and healthcare context: state of the art and future prospects. *Sensors (Basel)* 2022;22(20):7709. doi: 10.3390/s22207709. PubMed PMID: 36298059; PubMed Central PMCID: PMC9611914.
3. Milgram P, Kishino F. A taxonomy of mixed reality visual displays. *IEICE Trans Information Systems* 1994;E77-D(12):1321-1329.
4. Rauschnabel PA, Felix R, Hinsch C, Shahab H, Alt F. What is XR? Towards a framework for augmented and virtual reality. *Computers in Human Behavior* 2022;133:107289. doi: 10.1016/j.chb.2022.107289.
5. Blanchard J, Koshal S, Morley S, McGurk M. The use of mixed reality in dentistry. *Br Dent J* 2022;233(4):261-265. doi: 10.1038/s41415-022-4451-z.
6. Jiang H, Vimalasvaran S, Wang JK, Lim KB, Mogali SR, Car LT. Virtual reality in medical students' education: scoping review. *JMIR Med Educ* 2022;8(1):e34860. doi: 10.2196/34860. PubMed PMID: 35107421; PubMed Central PMCID: PMC8851326.
7. Vargas MV, Moawad G, Denny K, Happ L, Misa NY, Margulies S, et al. Transferability of virtual reality, simulation-based, robotic suturing skills to a live porcine model in novice surgeons: a single-blind randomized controlled trial. *J Minim Invasive Gynecol* 2017;24(3):420-425. doi: 10.1016/j.jmig.2016.12.016. PubMed PMID: 28027975.
8. Matzke J, Ziegler C, Martin K, Crawford S, Sutton E. Usefulness of virtual reality in assessment of medical student laparoscopic skill. *J Surg Res* 2017;211:191-5. Epub 20161211. doi: 10.1016/j.jss.2016.11.054. PubMed PMID: 28501116.
9. Paschold M, Huber T, Zeißig SR, Lang H, Kneist W. Tailored instructor feedback leads to more effective virtual-reality laparoscopic training. *Surg Endosc* 2014;28(3):967-973. doi: 10.1007/s00464-013-3258-z. PubMed PMID: 24185749.
10. Kiely DJ, Gotlieb WH, Lau S, Zeng X, Samouelian V, Ramanakumar AV, et al. Virtual reality robotic surgery simulation curriculum to teach robotic suturing: a randomized controlled trial. *J Robot Surg* 2015;9(3):179-186. doi: 10.1007/s11701-015-0513-4. PubMed PMID: 26531197.
11. Yoganathan S, Finch DA, Parkin E, Pollard J. 360° virtual reality video for the acquisition of knot tying skills: A randomised controlled trial. *Int J Surg* 2018;54(Pt A):24-27. doi: 10.1016/j.ijsu.2018.04.002. PubMed PMID: 29649669.
12. Valdis M, Chu MW, Schlachta C, Kiaii B. Evaluation of robotic cardiac surgery simulation training: a randomized controlled trial. *J Thorac Cardiovasc Surg* 2016;151(6):1498-1505 e2. doi: 10.1016/j.jtcvs.2016.02.016. PubMed PMID: 26964911.
13. Zhao J, Xu X, Jiang H, Ding Y. The effectiveness of virtual reality-based technology on anatomy teaching: a meta-analysis of randomized controlled studies. *BMC Med Educ* 2020;20(1):127. doi: 10.1186/s12909-020-1994-z. PubMed PMID: 32334594; PubMed Central PMCID: PMC7183109.
14. da Cruz Torquato M, Menezes JM, Belchior G, Mazzotti FP, Bittar JS, Dos Santos GGR, et al. Virtual reality as a complementary learning tool in anatomy education for medical students. *Med Sci Educ* 2023;33(2):507-516. Epub 20230323. doi: 10.1007/s40670-023-01774-3. PubMed PMID: 37261021; PubMed Central PMCID: PMC10226942.
15. Gloy K, Weyhe P, Nerenz E, Kaluschke M, Uslar V, Zachmann G, Weyhe D. Immersive Anatomy Atlas: learning factual medical knowledge in a virtual reality environment. *Anat Sci Educ* 2022;15(2):360-368. doi: 10.1002/ase.2095. PubMed PMID: 33896115.

16. Alharbi Y, Al-Mansour M, Al-Saffar R, Garman A, Alraddadi A. Three-dimensional virtual reality as an innovative teaching and learning tool for human anatomy courses in medical education: a mixed methods study. *Cureus* 2020;12(2):e7085. doi: 10.7759/cureus.7085. PubMed PMID: 32226686; PubMed Central PMCID: PMC7096077.
17. Kim-Berman H, Bui D, Lee K, Mitchell V, Bonine B, Benavides E, et al. Student learning of head and neck anatomy using cone beam computed tomography and immersive virtual reality. *J Dent Educ* 2023;87(8):1180-1187. doi: 10.1002/jdd.13224. PubMed PMID: 37087542.
18. Liebermann A, Erdelt K. Virtual education: dental morphologies in a virtual teaching environment. *J Dent Educ* 2020;84(10):1143-1150. doi: 10.1002/jdd.12235. PubMed PMID: 32511757.
19. Reymus M, Liebermann A, Diegritz C. Virtual reality: an effective tool for teaching root canal anatomy to undergraduate dental students - a preliminary study. *Int Endod J* 2020;53(11):1581-1587. doi: 10.1111/iej.13380. PubMed PMID: 32750729.
20. Ba-Hattab R, Helvacioğlu-Yigit D, Anweigi L, Alhadeethi T, Raja M, Atique S, et al. Impact of virtual reality simulation in endodontics on the learning experiences of undergraduate dental students. *Applied Sciences* 2023;13(2). doi: 10.3390/app13020981.
21. Hsu MH, Yang HW, Liu CM, Chen CJ, Chang YC. Clinical relevant haptic simulation learning and training in tooth preparation. *J Dent Sci* 2022;17(3):1454-1457. doi: 10.1016/j.jds.2022.01.018. PubMed PMID: 35784153; PubMed Central PMCID: PMC9236931.
22. Murbay S, Neelakantan P, Chang JWW, Yeung S. Evaluation of the introduction of a dental virtual simulator on the performance of undergraduate dental students in the pre-clinical operative dentistry course. *Eur J Dent Educ* 2020;24(1):5-16. doi: 10.1111/eje.12453. PubMed PMID: 31278815.
23. Zafar S, Lai Y, Sexton C, Siddiqi A. Virtual reality as a novel educational tool in pre-clinical paediatric dentistry training: students' perceptions. *Int J Paediatr Dent* 2020;30(6):791-797. doi: 10.1111/ipd.12648. PubMed PMID: 32274838.
24. Vincent M, Joseph D, Amory C, Paoli N, Ambrosini P, Mortier É, Tran N. Contribution of haptic simulation to analogic training environment in restorative dentistry. *J Dent Educ* 2020;84(3):367-376. doi: 10.21815/JDE.019.187. PubMed PMID: 32176342.
25. Hattori A, Tonami KI, Tsuruta J, Hideshima M, Kimura Y, Nitta H, Araki K. Effect of the haptic 3D virtual reality dental training simulator on assessment of tooth preparation. *J Dent Sci* 2022;17(1):514-520. doi: 10.1016/j.jds.2021.06.022. PubMed PMID: 35028078; PubMed Central PMCID: PMC8740096.
26. Dwisaptarini AP, Suebnukarn S, Rhiemora P, Haddawy P, Koontongkaew S. Effectiveness of the multilayered caries model and visuo-tactile virtual reality simulator for minimally invasive caries removal: a randomized controlled trial. *Oper Dent* 2018;43(3):E110-E118. doi: 10.2341/17-083-C. PubMed PMID: 29513643.
27. Eve EJ, Koo S, Alshihri AA, Cormier J, Kozhenikov M, Donoff RB, Karimbux NY. Performance of dental students versus prosthodontics residents on a 3D immersive haptic simulator. *J Dent Educ* 2014;78(4):630-637. PubMed PMID: 24706694.
28. Zhang B, Li S, Gao S, Hou M, Chen H, He L, et al. Virtual versus jaw simulation in oral implant education: a randomized controlled trial. *BMC Med Educ* 2020;20(1):272. doi: 10.1186/s12909-020-02152-y. PubMed PMID: 32811485; PubMed Central PMCID: PMC7433198.
29. Pulijala Y, Ma M, Pears M, Peebles D, Ayoub A. Effectiveness of immersive virtual reality in surgical training-a randomized control trial. *J Oral Maxillofac Surg* 2018;76(5):1065-1072. doi: 10.1016/j.joms.2017.10.002. PubMed PMID: 29104028.
30. Sytek L, Inglehart MR, Ramaswamy V, Aronovich S, Edwards S, Kim-Berman H. Comparisons of orthodontic residents' performance and attitudes using 2D, 3D, and virtual reality surgical

- simulation methods. *J Dent Educ* 2021;85(8):1415-1426. doi: 10.1002/jdd.12598. PubMed PMID: 33792038.
31. Rebenitsch L, Owen C. Review on cybersickness in applications and visual displays. *Virtual Reality* 2016;20(2):101-125. doi: 10.1007/s10055-016-0285-9.
 32. Sutherland J, Belec J, Sheikh A, Chepelev L, Althobaity W, Chow BJW, et al. Applying modern virtual and augmented reality technologies to medical images and models. *J Digit Imaging* 2019;32(1). doi: 10.1007/s10278-018-0122-7.
 33. Moro C, Stromberga Z, Raikos A, Stirling A. The effectiveness of virtual and augmented reality in health sciences and medical anatomy. *Anat Sci Educ* 2017;10(6):549-559. doi: 10.1002/ase.1696. PubMed PMID: 28419750.
 34. Liu Y, Dong H, Zhang L, Saddik AE. Technical evaluation of HoloLens for multimedia: a first look. *IEEE MultiMedia* 2018;25(4):8-18. doi: 10.1109/MMUL.2018.2873473.
 35. Magic Leap 2 Now Available to Customers as the Most Immersive Augmented Reality Headset for Enterprise [Internet]. 2022; September 30. Available from: <https://www.magicleap.com/news/magic-leap-2-now-available-to-customers-as-the-most-immersive-augmented-reality-headset-for-enterprise>
 36. Introducing Apple Vision Pro: Apple's first spatial computer [Internet]. 2023; June 5. Available from: <https://www.apple.com/newsroom/2023/06/introducing-apple-vision-pro/>
 37. Microsoft HoloLens vs Microsoft HoloLens 2 [cited 2023 August 8]. Available from: https://versus.com/en/microsoft-hololens-vs-microsoft-hololens-2#group_features.
 38. Geerlings-Batt J, Tillett C, Gupta A, Sun Z. Enhanced visualisation of normal anatomy with potential use of augmented reality superimposed on three-dimensional printed models. *Micromachines (Basel)* 2022;13(10):1701. doi: 10.3390/mi13101701. PubMed PMID: 36296054; PubMed Central PMCID: PMC9608320.
 39. Gnanasegaram JJ, Leung R, Beyea JA. Evaluating the effectiveness of learning ear anatomy using holographic models. *J Otolaryngol Head Neck Surg* 2020;49(1):63. doi: 10.1186/s40463-020-00458-x. PubMed PMID: 32814593; PubMed Central PMCID: PMC7439621.
 40. Cerenelli L, De Stefano A, Billi AM, Ruggeri A, Marcelli E, Marchetti C, et al. AEducaAR, Anatomical Education in Augmented Reality: a pilot experience of an innovative educational tool combining AR technology and 3D printing. *Int J Environ Res Public Health* 2022;19(3):1024. doi: 10.3390/ijerph19031024. PubMed PMID: 35162049; PubMed Central PMCID: PMC8834017.
 41. Moro C, Phelps C, Redmond P, Stromberga Z. HoloLens and mobile augmented reality in medical and health science education: a randomised controlled trial. *Br J Educ Technol* 2020;52(2):680-694. doi: 10.1111/bjet.13049.
 42. Kumar N, Pandey S, Rahman E. A Novel Three-dimensional interactive virtual face to facilitate facial anatomy teaching using Microsoft HoloLens. *Aesthetic Plast Surg* 2021;45(3):1005-1011. doi: 10.1007/s00266-020-02110-5.
 43. Hanna MG, Ahmed I, Nine J, Prajapati S, Pantanowitz L. Augmented reality technology using Microsoft HoloLens in anatomic pathology. *Arch Pathol Lab Med* 2018;142(5):638-644. doi: 10.5858/arpa.2017-0189-OA. PubMed PMID: 29384690.
 44. Tadlock MD, Olson EJ, Gasques D, Champagne R, Krzyzaniak MJ, Belverud SA, et al. Mixed reality surgical mentoring of combat casualty care related procedures in a perfused cadaver model: Initial results of a randomized feasibility study. *Surgery* 2022;172(5):1337-1345. doi: 10.1016/j.surg.2022.06.034. PubMed PMID: 36038376.
 45. Schoeb DS, Schwarz J, Hein S, Schlager D, Pohlmann PF, Frankenschmidt A, et al. Mixed reality for teaching catheter placement to medical students: a randomized single-blinded, prospective trial. *BMC Med Educ* 2020;20(1):510. doi: 10.1186/s12909-020-02450-5. PubMed PMID: 33327963; PubMed Central PMCID: PMC7745503.

46. Tsang KD, Ottow MK, van Heijst AFJ, Antonius TAJ. Electronic decision support in the delivery room using augmented reality to improve Newborn Life Support Guideline adherence: a randomized controlled pilot study. *Simul Healthc* 2022;17(5):293-298. doi: 10.1097/SIH.0000000000000631. PubMed PMID: 35102128; PubMed Central PMCID: PMC9553249.
47. Kim-Berman H, Karl E, Sherbel J, Sytek L, Ramaswamy V. Validity and user experience in an augmented reality virtual tooth identification test. *J Dent Educ* 2019;83(11):1345-1352. doi: 10.21815/JDE.019.139. PubMed PMID: 31406007.
48. Lim EJ, Kim YS, Im JE, Lee JG. Mobile educational tool based on augmented reality technology for tooth carving: results of a prospective cohort study. *BMC Med Educ* 2023;23(1):462. doi: 10.1186/s12909-023-04443-6. PubMed PMID: 37344879; PubMed Central PMCID: PMC10286372.
49. Llena C, Folguera S, Forner L, Rodriguez-Lozano FJ. Implementation of augmented reality in operative dentistry learning. *Eur J Dent Educ* 2018;22(1):e122-e130. doi: 10.1111/eje.12269. PubMed PMID: 28370970.
50. Mladenovic R, Matvijenko V, Subaric L, Mladenovic K. Augmented reality as e-learning tool for intraoral examination and dental charting during COVID-19 era. *J Dent Educ* 2022;86(Suppl 1):862-864. doi: 10.1002/jdd.12780. PubMed PMID: 34420217; PubMed Central PMCID: PMC8657534.
51. Dolega-Dolegowski D, Proniewska K, Dolega-Dolegowska M, Pregowska A, Hajto-Bryk J, Trojak M, et al. Application of holography and augmented reality based technology to visualize the internal structure of the dental root - a proof of concept. *Head Face Med* 2022;18(1):12. Epub 20220405. doi: 10.1186/s13005-022-00307-4. PubMed PMID: 35382839; PubMed Central PMCID: PMC8981712.
52. Mahrous A, Elgreatly A, Qian F, Schneider GB. A comparison of pre-clinical instructional technologies: natural teeth, 3D models, 3D printing, and augmented reality. *J Dent Educ* 2021;85(11):1795-1801. doi: 10.1002/jdd.12736. PubMed PMID: 34216032.
53. Grad P, Przeklasa-Bierowiec AM, Malinowski KP, Witowski J, Proniewska K, Tatoń G. Application of HoloLens-based augmented reality and three-dimensional printed anatomical tooth reference models in dental education. *Anat Sci Educ* 2023;16(4):743-755. doi: 10.1002/ase.2241. PubMed PMID: 36524288.
54. Zafar S, Zachar JJ. Evaluation of HoloHuman augmented reality application as a novel educational tool in dentistry. *Eur J Dent Educ* 2020;24(2). doi: 10.1111/eje.12492. PubMed PMID: 31899840.
55. Talaat S, Ghoneima A, Kaboudan A, Talaat W, Ragy N, Bourauel C. Three-dimensional evaluation of the holographic projection in digital dental model superimposition using HoloLens device. *Orthod Craniofac Res* 2019;22(Suppl. 1):62-8. doi: <https://doi.org/10.1111/ocr.12286>.
56. Koyama Y, Sugahara K, Koyachi M, Tachizawa K, Iwasaki A, Wakita I, et al. Mixed reality for extraction of maxillary mesiodens. *Maxillofac Plast Reconstr Surg* 2023;45(1):1. doi: 10.1186/s40902-022-00370-6. PubMed PMID: 36602618; PubMed Central PMCID: PMC9816364.
57. Liu L, Wang X, Guan M, Fan Y, Yang Z, Li D, et al. A mixed reality-based navigation method for dental implant navigation method: a pilot study. *Comp Biol Med* 2023;154:106568. doi: <https://doi.org/10.1016/j.combiomed.2023.106568>. PubMed PMID: 36739818.
58. Ito T, Kawashima Y, Yamazaki A, Tsutsumi T. Application of a virtual and mixed reality-navigation system using commercially available devices to the lateral temporal bone resection. *Ann Med Surg (Lond)* 2021;72:103063. doi: 10.1016/j.amsu.2021.103063. PubMed PMID: 34824840; PubMed Central PMCID: PMC8604738.

59. Lysenko A, Razumova A, Yaremenko A, Ivanov V, Strelkov S, Krivtsov A. The use of augmented reality navigation technology in combination with endoscopic surgery for the treatment of an odontogenic cyst of the upper jaw: a technical report. *Imaging Sci Dent* 2022;52(2):225-230. doi: 10.5624/isd.20210256. PubMed PMID: 35799962; PubMed Central PMCID: PMC9226234.
60. Johnson TM, Badovinac R, Shaefer J. Teaching alternatives to the standard inferior alveolar nerve block in dental education: outcomes in clinical practice. *J Dent Educ* 2007;71(9):1145-1152. doi: <https://doi.org/10.1002/j.0022-0337.2007.71.9.tb04378.x>. PubMed PMID: 17761620.
61. Madan GA, Madan SG, Madan AD. Failure of inferior alveolar nerve block: exploring the alternatives. *J Am Dent Assoc* 2002;133(7):843-846. doi: 10.14219/jada.archive.2002.0298. PubMed PMID: 12148677.
62. Rosenberg M, Orr II DL, Starley ED, Jensen DR. Student-to-student local anesthesia injections in dental education: moral, ethical, and legal issues. *J Dent Educ* 2009;73(1):127-132. doi: <https://doi.org/10.1002/j.0022-0337.2009.73.1.tb04645.x>. PubMed PMID: 19126773.
63. Hossaini M. Teaching local anesthesia in dental schools: opinions about the student-to-student administration model. *J Dent Educ* 2011;75(9):1263-1269. PubMed PMID: 21890857.
64. Knipfer C, Rohde M, Oetter N, Muench T, Kesting MR, Stelzle F. Local anaesthesia training for undergraduate students - how big is the step from model to man? *BMC Med Educ* 2018;18(1):308. doi: 10.1186/s12909-018-1389-6. PubMed PMID: 30547783; PubMed Central PMCID: PMC6295027.
65. Kary AL, Gomez J, Raffaelli SD, Levine MH. Preclinical local anesthesia education in dental schools: a systematic review. *J Dent Educ* 2018;82(10):1059-1064. doi: 10.21815/JDE.018.106. PubMed PMID: 30275140.
66. Lee JS, Graham R, Bassiur JP, Lichtenthal RM. Evaluation of a local anesthesia simulation model with dental students as novice clinicians. *J Dent Educ* 2015;79(12):1411-1417. PubMed PMID: 26632295.
67. Brand HS, Baart JA, Maas NE, Bachet I. Effect of a training model in local anesthesia teaching. *J Dent Educ* 2010;74(8):876-879. PubMed PMID: 20679457.
68. Brand HS, Tan LL, van der Spek SJ, Baart JA. European dental students' opinions on their local anaesthesia education. *Eur J Dent Educ* 2011;15(1):47-52. doi: 10.1111/j.1600-0579.2010.00633.x. PubMed PMID: 21226806.

THREE-DIMENSIONAL IMAGING OF MANDIBLE GROWTH DURING CLASS II ORTHOPEDICS

Hugo De Clerck, Hilde Timmerman, Sergio Siciliano

ABSTRACT

Forward projection of the chin during growth is the result of true mandibular lengthening, condylar displacement following glenoid fossa modeling, and true mandibular rotation. Horizontal and vertical lengthening of the mandible have mainly been attributed to condylar growth. However, modeling changes in the ramus and at the gonial angle seem to play a more important role in the changes of shape and size of the mandible than cartilage growth. Fossa modeling and the resulting displacement of the condyles only have a small effect on chin projection. Thanks to three-dimensional (3D) imaging, the growth of the mandible can be split into pure rotation and pure translation. The effect of true rotation of the mandible on forward growth of the chin has been underestimated in the past. Anterior rotation leads to more advancement of the chin, whereas posterior rotation reduces chin projection with increased facial height.

KEY WORDS: Mandible, Class II malocclusion, Orthopedic treatment, Bone-anchored Herbst appliance, Cone beam computed tomography

INTRODUCTION

Especially in Western Europe there is a high incidence of about 30% of Class II malocclusion [1], characterized by a retro positioned chin and a convex soft tissue profile. This convexity may be further increased by an excessive vertical growth. So called orthopedic or functional appliances not only aim to correct Class II malocclusion but also to stimulate mandibular growth. Application of forward directed forces to the lower dentition may lead to a different loading of the condyle, and a change of amount and direction of cartilage growth.

Two types of appliances are expected to have an orthopedic outcome. The first type applies anteriorly directed forces to the lower dentition that do not result in a propulsion of the mandible. Examples are Forsus springs fixed between upper and lower fixed appliances, Jasper Jumpers, and Carriere appliances. Although they may generate forces higher than conventional Class II elastics, they usually do not pull the condyles out of their glenoid fossa. This mainly results in dento-alveolar compensation, i.e., proclination of the lower and retroclination of the upper incisors. Therefore, they should not be considered as orthopedic appliances. The second type of appliances prevents the condyles sliding back into the glenoid fossa during mouth closure. This relocation of the condyle could result in a different loading and a change in amount and/or direction of growth. Typical appliances are bionators, Fränkel appliances, activators, twin blocks, and Herbst appliances. The forward shift of the condyle is partially induced by the design of the appliance but also requires an activation of muscles responsible for propulsion and closure of the mouth: the lateral and medial pterygoid muscles, and masseter. During mouth closure, the suprahyoid muscles and the horizontal fibers of the temporal muscle are passively stretched and act as a big rubber band, pulling the mandible backward. Stretching of muscular spindles may even trigger small contractions. Forces generated by stretching the muscles tend to move the condyles back towards the fossa. However, the design of the orthopedic appliance

prevents the mandible returning to its original position because of a rigid connection between upper and lower dentition. This connection generates posteriorly directed forces to the upper and forward directed forces to the lower dentition, resulting in retroclination of the upper, and proclination of the lower incisors. Each millimeter of horizontal movement of the upper and/or lower dentition results in an equal amount of posterior displacement of the mandible. These dento-alveolar compensations start from day one of insertion of the orthopedic appliance, and immediately initiate a backward displacement of the condyles. After a couple of millimeters of posterior shift, the condyles start to slide along the posterior cant of the anterior eminence of the glenoid fossa, pulled upwards by the masseter, the anterior fibers of the temporal muscle, and the medial pterygoid muscle. It is our hypothesis that due to dento-alveolar compensation, within the first months of the orthopedic treatment the condyles are seated back into their fossa. Therefore, the amount of forward growth of the mandible in a skeletal Class II individual during a one year treatment with orthopedic appliances is hardly larger than what can be expected from an untreated control group [2].

Without any dento-alveolar compensations, the condyles stay out of the fossa in front of the anterior eminence of the temporomandibular joint for a much longer time. Dento-alveolar compensations can be minimized by increasing the number of teeth included in the anchor unit or by using occlusal splints, connecting groups of teeth. A miniscrew can also be inserted in the lower canine region and rigidly connected by a wire bonded to the labial surface of the canine crown. Limited rigidity of the connection and poor stability of the miniscrew into alveolar bone generally result in anchorage loss and mesial drift of the lower dentition. However, miniscrew skeletal anchorage may, within certain limits, reduce anchorage loss [3]. Instead of indirect skeletal anchorage, direct skeletal anchorage can also be used. Miniplate anchorage offers better resistance against the very aggressive forces generated by the orthopedic appliance [4]. Anchorage is increased since the miniplate is fixed by two or three osteosynthesis screws instead of one single miniscrew. Furthermore, the osteosynthesis screws are inserted into very solid monocortical bone close to the lower border of the mandible, which is much more resistant to force application than alveolar bone. To reduce the risks of local infection, the skeletal anchorage should perforate soft tissues into attached gingiva. Therefore, miniscrews have to be inserted in alveolar bone close to the alveolar crest. Miniplates have the advantage that they can be fixed by screws inserted close to the lower border of the mandible facing mobile mucosa, since an extension of the plate moves the perforation of the soft tissues up to attached gingiva. Ideally, direct skeletal anchorage should be used in both jaws. However, the cortical bone in front of the sinus is very thin, reducing the resistance against force application. Moreover, for insertion of two miniplates in each jaw, general anesthesia or intravenous (IV) sedation may be recommended, especially in young and anxious children. If miniplates are only inserted in the lower canine region, access for the surgeon is easier and requires shorter surgery time, which can be performed under local anesthesia. If an occlusal splint or printed frame is used in the upper jaw instead of skeletal anchorage, upper molars and premolars may be distalized during the orthopedic treatment. This may be helpful to align crowded anterior teeth and create space for impacted upper canines during the orthodontic treatment with fixed appliances or aligners following the orthopedic phase. However, similar to proclination of the lower incisors, distalization of the upper dentition results in a posterior shift of the mandible. Each millimeter of distalization of the upper molars should be compensated by an adaptation of the orthopedic appliance, increasing the propulsion of the mandible by the same amount. This is only possible if the angulation of the upper incisors is well controlled.

CASE PRESENTATION

A 14.5 year old girl with a cervical vertebral maturation stage 4 was treated with a bone anchored Herbst appliance (DC appliance, Tita-Link, Brussels, Belgium). She presented a skeletal Class II with an ANB angle of 8° and a Wits appraisal of 7.5 mm. The vertical growth pattern was normodivergent with GoGnSN of 32°. Because of proclination of the lower incisors, the overjet was only 6 mm (Figure 1A).

The upper incisors were proclined first until an overjet of 10 mm was reached (Figure 1B). A bone anchored Herbst appliance was inserted and maintained for 10 months.

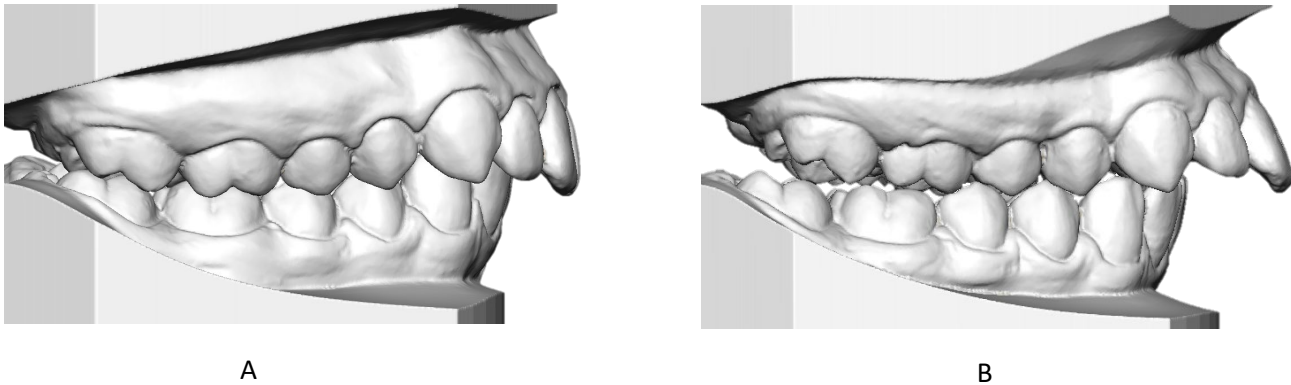


Figure 1. Class II malocclusion A) At the start of treatment, B) After proclination of the upper incisors.

METHODS

Before treatment, a cone beam computed tomography (CBCT) (CBCT1) and intra-oral scan (IOS) were made following a standardized protocol. CBCT1 was acquired using a Newtom VGi evo device (Cefla, Imola, Italy) with settings of 110 kV and 8.9 mAS, and tube current modulation was utilized to allow for patient-specific dose reduction. In addition, an IOS was made using a Trios intra-oral scanner (3Shape, Copenhagen, Denmark). Voxel-based registration was then performed using D2P software (3D Systems., Leuven, Belgium), to get a three-dimensional (3D) model of CBCT1 and IOS images. This 3D model was then used to design a customized appliance. The patient specific bone anchors for the mandible were 3D laser printed in Ti-6Al-4V ELI titanium alloy. The correct position of the bone anchors during surgery was secured by a surgical guide fixed to the occlusal surface of the lower teeth. Under local anesthesia, a small mucoperiosteal flap was made and the miniplates were fixed on both sides between the lower first premolar and canine. Three osteosynthesis screws were inserted close to the lower border of the mandible at a safe distance from the roots of the adjacent teeth. An extension of the miniplate was perforating the soft tissues at the mucogingival border. In the upper arch, a custom made 3D printed titanium frame was bonded to the premolars and first molars, connected in the middle by an expansion screw. The screw was activated twice a week for four months. Between the hook from the bone anchor and a hook on the frame in front of the upper first molars, a connector was adjusted that consisted of a rod sliding into a modified Forsus spring (3M, Saint Paul, Minnesota, US). The length of the connectors was adjusted until an edge to edge relation of the upper and lower incisors was reached at mouth closure. The modified Herbst appliance was worn for 10 months.

Two months after debonding, a second CBCT (CBCT2) and IOS were made. Both CBCT images were saved in Digital Imaging and Communications in Medicine (DICOM) format. CBCT1 was oriented parallel to the Frankfurt horizontal plane and registered twice, on the anterior cranial base, and on the symphysis of the mandible of CBCT2, using ITK-SNAP software (version 4.0) [5]. The DICOM images were then imported to D2P software (3D Systems, Leuven, Belgium), where virtual surface models were created and saved in Standard Tessellation Language (STL) format (Figure 2). The models were imported to Freeform Plus software (3D Systems, Leuven, Belgium) to quantify mandibular changes.

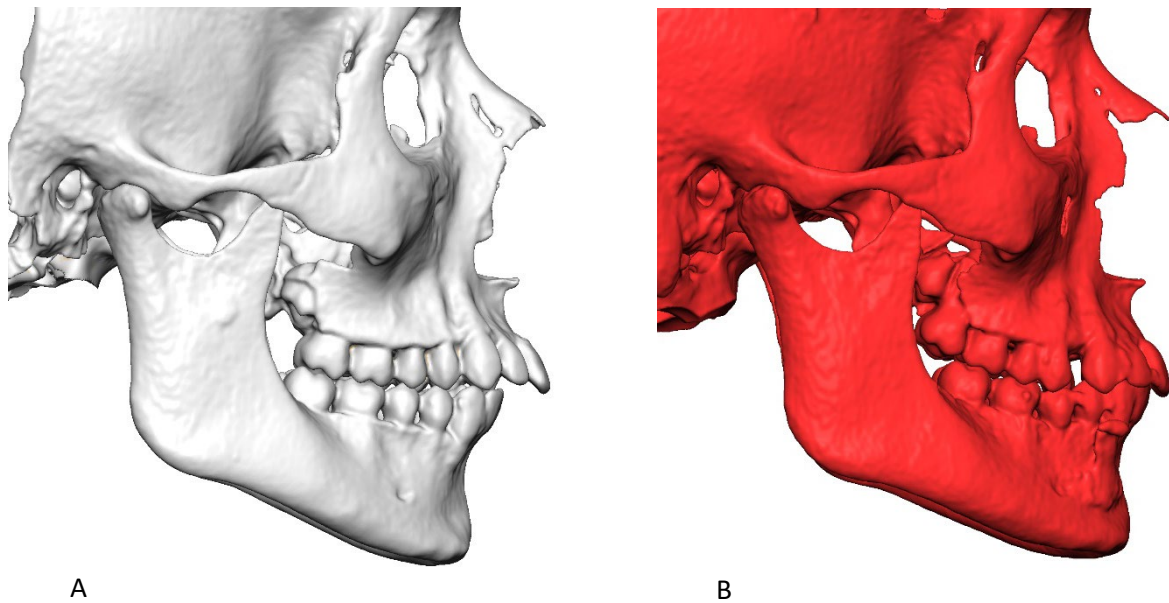
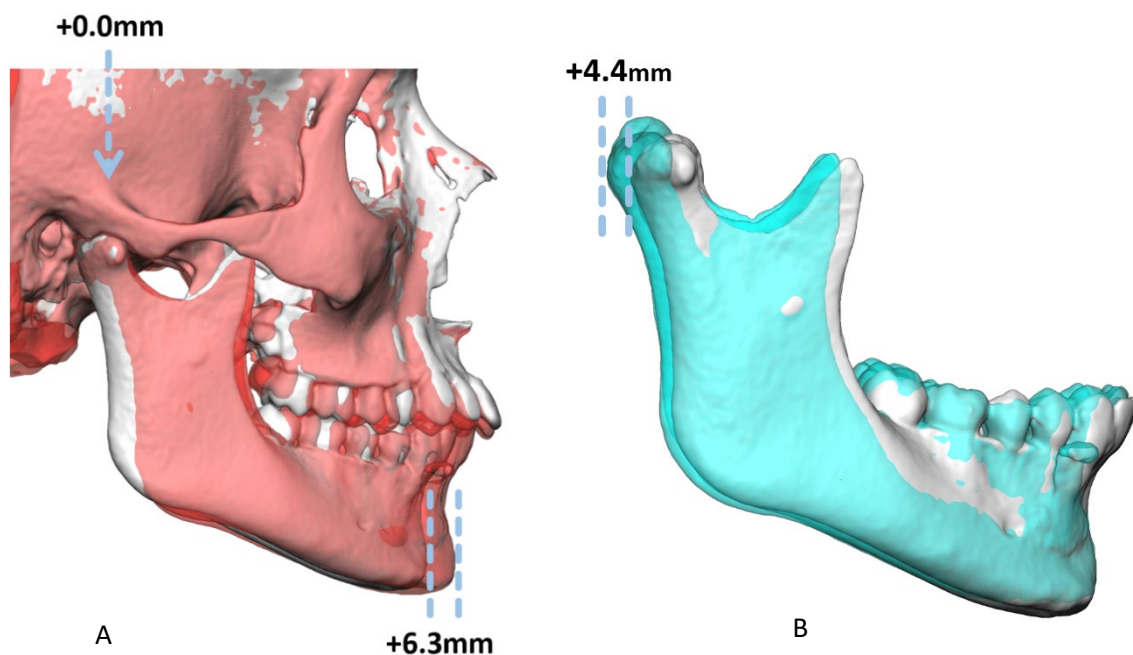


Figure 2. Surface models generated from CBCT A) Before treatment, B) Two months after removal of the orthopedic appliance.

First, a good seating of the condyles in the glenoid fossa was checked on both surface models. Then three measurements were done on the models registered on the anterior cranial base: the amount of forward growth of the chin, and the horizontal and vertical displacements of the condyles following glenoid fossa modeling (Figure 3A). After isolation of the surface models of the mandibles registered on the chin, the true horizontal and vertical mandibular lengthening were measured. Also, the displacement of the lower incisors could be visualized (Figure 3B). Recently, a new protocol was introduced to measure the true rotation of a growing mandible [6], starting from the surface models of CBCT1 and CBCT2 registered on the anterior cranial base. Then, only the segmented mandible of CBCT2 is registered on the chin of the surface model of CBCT1. This segmented mandible is moved horizontally and vertically over a distance equal to the amount of true mandibular lengthening plus the amount of condylar displacement following glenoid fossa modeling. Finally, the amount of pure rotation needed to get a perfect fit of both mandibles is measured: positive values for anterior rotation and negative values for posterior rotation (Figure 3C).



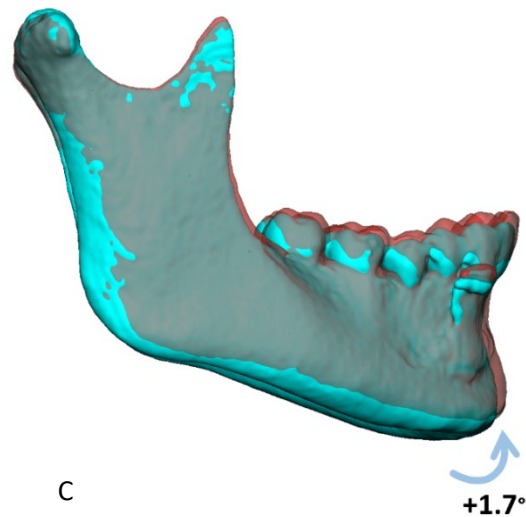


Figure 3. Surface models generated after registration of CBCT1 and 2 A) Surface model of post-treatment CBCT2 (red color) registered with CBCT1 model (white color) on anterior cranial base, no relocation of the condyle but 6.3 mm forward projection of the chin, B) Surface model of CBCT2 mandible (blue color) registered with surface model of CBCT1 mandible on symphyseal region, 4.4 mm true mandibular lengthening, C) 1.7 mm true anterior mandibular rotation of CBCT2-derived mandible (blue color) until best fit with the CBCT2-derived mandible (red color) registered on the symphysis of CBCT1.

RESULTS

Over a period of 14 months, mandibular growth resulted in a forward projection of the chin by 6.3 mm as measured on both surface models generated from CBCT1 and CBCT2, registered on the anterior cranial base. Also, on a midsagittal slice of CBCT1 registered on the anterior cranial base of CBCT2 surface model the advancement of the chin was measured (Figure 4A). This was mainly the result of a true mandibular lengthening of 4.4 mm. No displacement of the condyle due to glenoid fossa modeling was measured. However, an anterior rotation of the mandible by 1.7° resulted in a forward displacement of the chin by another 1.9 mm. The sagittal overbite was reduced by 7 mm, the Class II malocclusion of the molars was overcorrected into a slight Class III malocclusion (Figure 5), with a retroclination of the lower incisors (Figure 4B). Thanks to the expansion of the upper arch by activation of the midpalatal screw twice a week for four months, no crossbite was created in the lateral segments. Thanks to the advancement of the chin, convexity of the soft tissue profile was reduced (Figure 6).

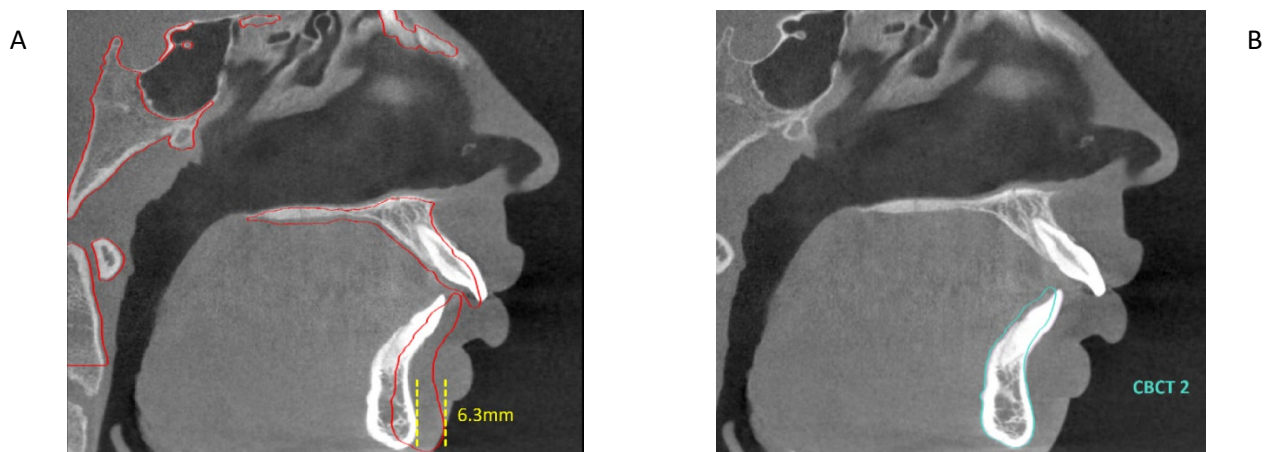


Figure 4. A) Midsagittal slice of CBCT1 registered on the anterior cranial base of CBCT2 surface model (red color), B) Midsagittal slice of CBCT1 registered on the symphysis of CBCT2 surface model (blue color).

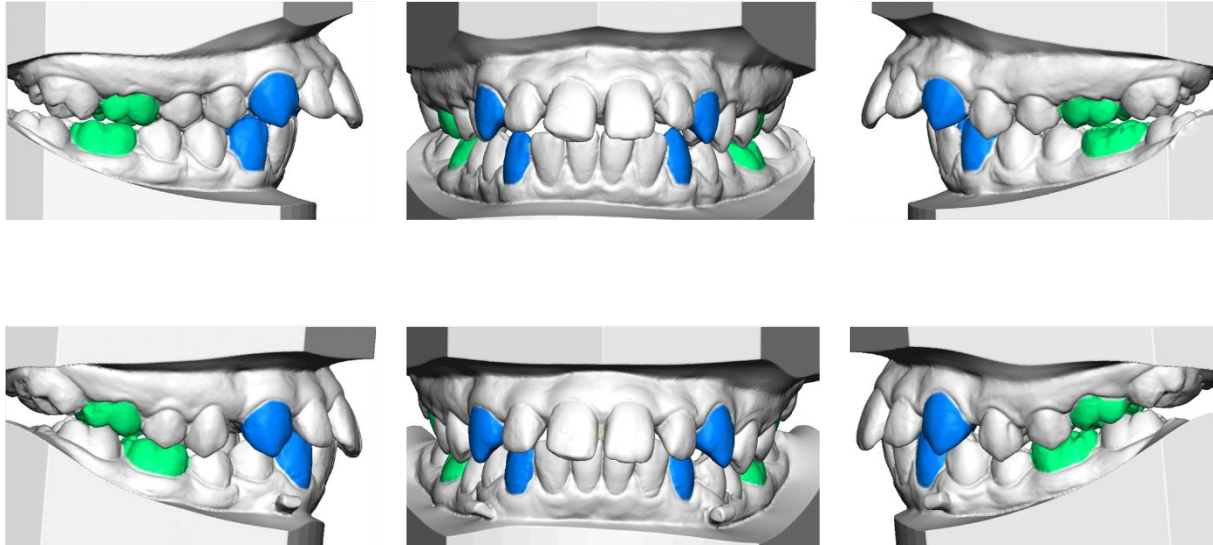


Figure 5. Class II malocclusion at the start of orthopedic treatment (top), and Class I occlusion two months after removal of the orthopedic appliance (bottom).

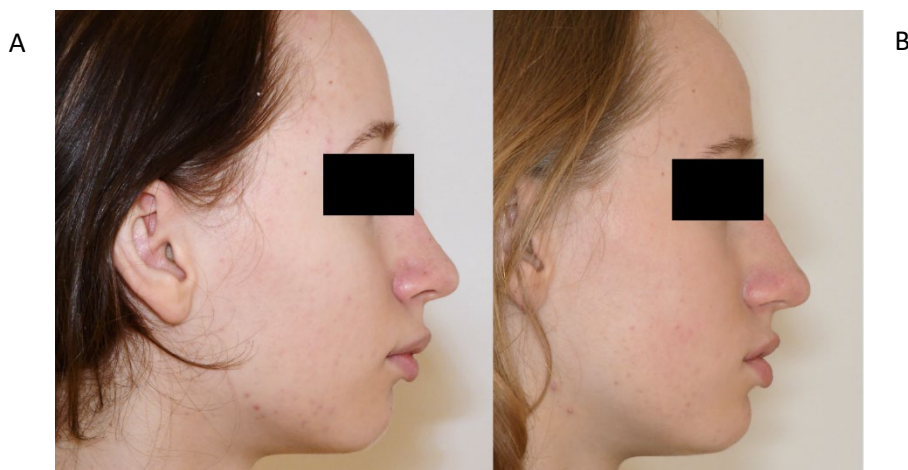

Figure 6. Soft tissue profile A) Pre-treatment, B) Two months post-treatment.

DISCUSSION

Class II orthopedics aim to increase mandibular growth, resulting in a forward projection of the chin, and a reduction of facial convexity. However, there is poor evidence available that supports the idea that orthodontists are growing mandibles [7]. With functional appliances, the amount of forward growth of the chin is hardly more than 2.5 mm a year, which is clinically not relevant, compared with untreated Class II individuals [8]. Since the condyle is the main growth center of the mandible, it is logical that for many years it was the focus of clinical research on the effects of Class II orthopedics. Initially, the direction and amount of condylar growth was related to age, sex, and vertical growth pattern based on the studies of Björk and Skieller [9], using metal bone markers for superimposition of mandibles in two-dimensional (2D) cephalometrics. Later, the direction of condylar growth was also linked with horizontal growth: condyles grow more vertical and slightly forward in Class II growth [10], whereas they grow in a more posterior direction in Class III growth [11]. Orthodontists try to restrain the lengthening of the mandible in a Class III growing individual by the application of heavy forces to

the chin with face masks or chincups. With miniplate anchored Class III traction, twice as much forward growth of the maxilla occurred, and a significant closure of the gonial angle was found, resulting in less forward projection of the chin [12]. Class II orthopedic appliances are supposed to stimulate condylar growth, resulting in longer mandibles. However, adaptability of condylar growth is smaller than the adaptability of sutures and subperiosteal modeling [13].

Bone apposition and resorption in the ramus and gonial angle are an underestimated mechanism of mandibular growth. Bone modeling at the surface of the mandible is affected by overall loading as a result of muscular contractions during mastication, swallowing, and respiration, and the elasticity of the soft tissue envelope. It continues until an equilibrium of forces is reached. If additional forces are applied to the mandible by an orthopedic appliance, the equilibrium is disturbed, creating zones of tension and compression in the mandible, resulting in apposition and resorption, respectively. This changes the size and shape of the mandible until a new balance of forces is reached. The unique L-shape of the mandible amplifies a small change in the gonial angle towards a larger displacement of the condyle. Orthopedic loading should be maintained for a sufficiently long time to get the amount of modeling needed for a clinically relevant lengthening of the mandible. Besides the duration of the mandibular propulsion, the amount of forward displacement of the condyles by the orthopedic appliance has an effect on the mandibular lengthening. The larger the propulsion, the more lengthening of the mandible may be expected. Therefore, as for orthognathic surgery, it is important to increase the overjet by proclination of the upper incisors before the start of the orthopedic treatment, and to stabilize it during the whole active treatment. Proclination can be achieved with removable or fixed appliances.

Finally, the age at the start of treatment also has an effect on the outcome. While the adaptability of condylar growth reduces with age, it is well known that subperiosteal modeling is still possible after adolescent growth spurt [13]. Even changes in the gonial angle due to bone modeling have been observed in adults after extraction of posterior teeth, because of a perturbation of the equilibrium of forces [14].

Forward growth of the chin is the result of three growth mechanisms. The most important of these is *true mandibular lengthening*. This can be accurately measured by the posterior displacement of the line perpendicular to the Frankfurt horizontal plane and tangent to the posterior limit of the condyles after symphyseal registration of both mandibles before and after treatment. In the case presented above, a lengthening of 4.4 mm over a period of 14 months was measured. If only growth activity of the condyles was responsible for this lengthening, modifications at the coronoid process and anterior border of the ramus would be difficult to explain. It rather looks like a posterior translation of the whole ramus occurred, together with the condyles, as a result of modeling all along the surface of the ramus and the gonial angle. This may be explained by a posterior traction from the horizontal fibers of the temporal muscle on the coronoid process, and the forward pressure from the orthopedic appliance on the chin, resulting in a couple of forces that create zones of stretching and compression in the ramus.

A second mechanism of forward projection of the chin is a *relocation of the glenoid fossa* following bone modeling. The orthopedic appliance prevents the condyles from being seated in the glenoid fossa at mouth closure. This reduces the pressure on the articular fossa that may lead to bone apposition and a downward displacement of the condyles at the end of treatment. Also, forward pressure by the condyles when they return into the fossa in a later stage of treatment may result in bone apposition at the posterior wall and bone resorption at the anterior eminence of the fossa. This was previously observed with 3D imaging after treatment with a conventional Herbst appliance [15]. With Class III bone anchored midface protraction, opposite modeling changes have been found, i.e., apposition at the anterior eminence and resorption at the posterior wall of the fossa [16]. Thanks to

3D imaging, this modeling can be visualized on the surface models before and after treatment, and registered on the anterior cranial base. A poor outline of the fossa on the surface models, and changes in the complex shape of the fossa during treatment make accurate quantification very difficult. However, the resulting displacement of the condyles, which can be accurately measured, and not the relocation of the fossa, results in an equal displacement of the chin. Commonly, these relocations only have a small effect on the projection of the chin. In the presented case, no displacement of the condyles was measured in relation to the anterior cranial base.

True mandibular rotation is the third mechanism of chin projection. Anterior or posterior rotation may occur during growth, resulting in forward or backward displacement of the chin, respectively. Posterior rotation is commonly linked to an excessive vertical growth of the lower face, with an increase of the mandibular plan angle, whereas an anterior rotation is found in short faces, resulting in more chin prominence. Quantification of mandibular rotation by changes in the mandibular plane angle is difficult due to bone modeling all along the mandibular border and especially at the gonial angle. Moreover, parallax magnification, mandibular asymmetry, and poor head positioning during image capture can cause the lower borders of both mandibular sides to not coincide on a lateral cephalogram [17]. However, with our new measuring protocol we can split the forward growth into pure translation and pure rotation. In the presented case, an anterior rotation of the mandible of 1.7° occurred during the orthopedic treatment. Based on previous research, this rotation has to be multiplied by 1.1 to get the resulting forward projection of the chin of 1.9 mm [18]. The sum of the mandibular lengthening of 4.4 mm combined with the forward projection of the chin by 1.9 mm as a result of anterior rotation, explains the overall advancement of the chin by 6.3 mm. This net change has been measured on the registration of the surface models on the anterior cranial base. In this case, 30% of the horizontal growth of the mandible is the result of pure rotation. However, in cases with a posterior rotation of the mandible, the resulting backward movement of the chin reduces the amount of forward projection that could be expected from the mandibular lengthening [19]. Therefore, facial convexity will be reduced less. Furthermore, it is remarkable that instead of a proclination of the lower incisors, which is usually observed in Class II orthopedics, in this case the incisors retroclined during treatment. This can likely be explained by the pure skeletal anchorage in the mandible, a reduction of the lingual pressure by the tongue, and an increase in the pressure from the lower lip on the lower incisors because of the forward movement of the chin.

CONCLUSIONS

True mandibular lengthening is the primary source of forward chin projection. The lengthening depends largely on good control of dento-alveolar compensations during orthopedic treatment. Furthermore, the amount of propulsion by the orthopedic appliance, the duration of active treatment, and the age of the patient all impact the final outcome. Relocation of the glenoid fossa only has a minor effect on the antero-posterior growth of the lower jaw. However, it is well known that mandibular rotation has an important effect on forward projection of the chin during normal growth, orthopedic treatment, and in orthognathic surgery. Quantification has always been difficult with 2D cephalometrics, because of important modeling along the lower border of the mandible, and at the gonial angle. Thanks to 3D imaging, the forward growth of the chin can be split into pure translation and pure rotation. This will make it possible in future research to learn more about the impact of skeletal features, vertical growth pattern, and the direction of forces generated by the orthopedic appliances on the final rotation of the mandible. Better control of mandibular rotation may result in a greater improvement of chin projection, and more pleasing facial features.

REFERENCES

1. Alhammadi M, Halboub E, Fayed M, Labib A, El-Saaidi C. Global distribution of malocclusion traits: a systematic review. *Dental Press J Orthod* 2018;23(6): 40.e1-40.e10.
2. Flores-Mir C, Ayeh A, Goswami A, Charkhandeh S. Skeletal and dental changes in Class II division 1 malocclusions treated with splint-type Herbst appliances. A systematic review. *Angle Orthod* 2007;77(2):376-381.
3. Manni A, Pasini M, Mauro C. Comparison between Herbst appliances with or without miniscrew anchorage. *Dent Res J* 2012;9(Suppl 2):S216-S221.
4. Celikoglu M, Buyuk S, Ekizer A, Unal T. Treatment effects of skeletally anchored Forsus FRD EZ and Herbst appliances: a retrospective clinical study. *Angle Orthod* 2016;86(2):306-314.
5. Nguyen T, Cevidanes L, Franchi L, Ruellas A, Jackson T. Three-dimensional mandibular regional superimposition in growing patients. *Am J Orthod Dentofac Orthop*. 2018;153(5): 747-754.
6. De Clerck H, Timmerman H, Vloebergh K, Nguyen T, Jacobs R, Shujaat S, Siciliano S. Quantifying three-dimensional mandibular changes following treatment with bone-anchored Herbst appliance: A proof-of-concept. 2023; submitted.
7. De Clerck HJ, Proffit WR. Growth modification of the face: A current perspective with emphasis on Class III treatment. *Am J Orthod Dentofacial Orthop* 2015;148(1):37-46.
8. Yang X, Zhu Y, Long H, Zhou Y, Jian F, Ye N, Gao M, Lai W. The effectiveness of the Herbst appliance for patients with Class II malocclusion: a meta-analysis. *Eur J Orthod* 2016;38(3):324-333.
9. Björk A, Skieller V. Facial development and tooth eruption. An implant study at the age of puberty. *Am J Orthod* 1972;62(4):339-383.
10. Jacob HB, Buschang PH. Mandibular growth comparisons of Class I and Class II division 1 skeletofacial patterns. *Angle Orthod* 2014;84(5):755-761.
11. Wolfe SM, Araujo E, Behrents RG, Buschang PH. Craniofacial growth of Class III subjects six to sixteen years of age. *Angle Orthod* 2011;81(2):211-216.
12. Cevidanes L, Baccetti T, Franchi L, De Clerck H. Comparison of two protocols for maxillary protraction: Bone anchors versus face mask with rapid maxillary expansion. *Angle Orthod* 2010; 80(5):799-806.
13. Van Der Linden FP. *Facial Growth and Facial Orthopedics*. Quintessence Pub Co 1986.
14. Hutchinson EF, Farella M, Kramer B. Importance of teeth in maintaining the morphology of the adult mandible in humans. *Eur J Oral Sci* 2015;123(5):341-349.
15. LeCornu M, Cevidanes L, Zhu H, Wu C, Larson B, Nguyen T. Three-dimensional treatment outcomes in Class II patients treated with the Herbst appliance: a pilot study. *Am J Orthod Dentofacial Orthop* 2013;144(6):818-830.
16. De Clerck H, Nguyen T, de Paula L, Cevidanes L. Three-dimensional assessment of mandibular and glenoid fossa changes after bone-anchored Class III intermaxillary traction. *Am J Orthod Dentofacial Orthop* 2012;142(1):25-31.
17. Sicurezza E, Greco M, Giordano D, Maiorana F, Leonardi R. Accuracy of landmark identification on postero-anterior cephalograms. *Prog Orthod* 2012;13(2):132-140.
18. Buschang PH, Jacob HB. Mandibular rotation revisited: what makes it so important? *Semin Orthod* 2014;20(4):299-315.
19. Rogers K, Campbell PM, Tadlock L, Schneiderman E, Buschang PH. Treatment changes of hypo- and hyperdivergent Class II Herbst patients. *Angle Orthod* 2018;88(1):3-9.

EARLY TREATMENT OF CLASS III MALOCCLUSION: A 30-YEAR PERSPECTIVE

Lorenzo Franchi, Valentina Rutili, Veronica Giuntini, James A. McNamara Jr.

ABSTRACT

The aim of this chapter is to discuss four fundamental aspects of Class III malocclusion. The first aspect is growth in untreated Class III subjects. A recent long-term study reported that untreated Class III malocclusion progressively worsened over time and did not show spontaneous improvement. Class III malocclusion was characterized by a protruded and larger mandible, while generally the maxilla was not retruded at the end of growth. The second aspect to be considered is the long-term effects produced by rapid maxillary expansion and facemask (RME/FM) with respect to untreated Class III subjects. RME/FM therapy produced favorable long-term dentoskeletal changes that were characterized by improvements in Class III sagittal skeletal relationships, primarily due to favorable control of mandibular position rather than to maxillary protraction. Overjet, overbite, and molar relationship also improved significantly. The prevalence rate of long-term failure was substantially lower in the treated group (25%) than in the control group (65%). Third, the best time to treat a Class III patient was during the prepubertal phase. However, there were no significant long-term differences when treating Class III patients with RME/FM either during an early prepubertal phase (≤ 7 years of age) or during a late prepubertal phase (≥ 9 years of age). Finally, the long-term lack of success of early treatment of Class III malocclusion with RME/FM can be predicted with an accuracy of 95% if the inclination of the condylar axis to the mandibular plane is greater than 148° at the start of treatment.

Key Words: Class III malocclusion, Growth modification, Treatment timing, Cephalometrics

INTRODUCTION

Class III malocclusion in growing patients represents one of the most challenging and perplexing orthodontic presentations, due mostly to the uncertainty of a stable outcome at the end of active growth. In this chapter, we will discuss four fundamental aspects that every clinician should consider before treating a growing Class III patient.

The first issue has to do with growth in untreated Class III subjects. The clinician should understand how unfavorable craniofacial growth (particularly at the level of the mandible) can occur if a Class III patient is left untreated. The clinician should realize how prudent it is to start orthopedic treatment during the early developmental phases.

The second aspect that we will examine concerns the effects that the most commonly-used approach for early Class III treatment, rapid maxillary expansion and facemask (RME/FM), can produce in the long term with respect to untreated Class III subjects. Finally, two patient-related factors that potentially can improve the long-term efficacy of Class III treatment will be discussed. These are treatment timing and individual patient responsiveness, and they have to do with the possibility of predicting the long-term lack of success for early Class III treatment.

GROWTH IN UNTREATED CLASS III SUBJECTS

The many etiological factors underlying Class III malocclusion are still not understood completely. Both genetic and environmental factors can play a role in the etiopathogenesis of this disharmony. Familial aggregation studies demonstrated that hereditary factors are crucial [1]. The type of inheritance of this disharmony has been debated, and the most reliable theories to date agree on a polygenic inheritance model or an autosomal-dominant inheritance with incomplete penetrance and variable expressivity [2, 3].

Although Class III malocclusion is the least prevalent malocclusion worldwide, there are ethnic differences regarding its diffusion. Southeast Asian populations (in particular, China and Malaysia) have the highest prevalence (12.6% - 26.7%) while European populations have a much lower prevalence (4.9%) [4]. Ethnicity also plays a role in the facial and dentoskeletal aspects of this malocclusion. In fact, Asian populations tend to have a smaller anterior cranial base associated with a more deficient maxilla, while Americans presented a greater amount of mandibular prognathism and a larger anterior cranial base [5].

Moreover, the prevalence of Class III malocclusion seems slightly higher in males than in females (by 0.2%) during both childhood and adolescence. A large survey performed in US in 1998 on prevalence of malocclusions [6] found that moderate (-1 to -2 mm), severe (-3 to -4 mm), and extremely severe (≥ 4 mm) reverse overjet was very rare (0-0.7%) in the US population, in all ethnic groups combined. While the percentage of mild reverse overjet (0 mm) increased considerably from 8 to 11 years of age (2.2%) to 12 to 17 years of age (4.6%), little occurred from 17 to 50 years of age (4.8%).

Gender differences also have been demonstrated in Class III subjects, with males presenting significantly larger linear dimensions of the maxilla, mandible, and anterior facial heights compared with females during the circumpubertal and post-pubertal periods. Moreover, males tend to have a more vertical growth pattern than females [7, 8].

The growth pattern in skeletal Class III malocclusion is a complex topic in orthodontics. Angle in 1907 [9], first reported that Class III malocclusion worsens over time even up to 16 to 18 years of age or thereafter. Angle wrote that Class III malocclusion, once established, "usually progresses rapidly, only a few years being necessary to develop by far the worst type of deformities the orthodontist is called on to treat." In Caucasian Class III subjects, few cross-sectional studies have been performed [10, 11] and semi-longitudinal or longitudinal studies on Class III growth are scarce as well [11-14]. This paucity of data could be related both to the relatively low prevalence rate of Class III malocclusion in the population and/or to the difficulty of leaving a Class III subject untreated from the early developmental phases due to the evidence suggesting that early intervention is important, creating ethical concerns regarding non-intervention.

The most recent Class III Caucasian investigation was performed by Rutili and colleagues [14] who examined the largest semi-longitudinal untreated Class III sample (144 individuals) that ranged from 2 years and 9 months through 21 years and 7 months of age. A curvilinear multilevel model was used to describe growth curves for 10 cephalometric variables for each individual subject and for the sample as a whole. Males and females were analyzed separately. The multilevel model used 'Age' as an explanatory variable to detect variations in the growth curve for each cephalometric variable. This study was the first using a multilevel model to detect curvilinear growth variations in untreated Class III subjects, with earlier longitudinal studies using linear growth models [13]. Results of this study demonstrated that Class III malocclusion has typical features that already are present at an early age. Two growth spikes were observed, one at 3 to 5 years, and another at 11 to 15 years, for three

cephalometric variable (Co-Gn, Co-A and ANS-Me). Total mandibular length showed a curvilinear growth curve, and this growth continued for some time after puberty, up to 17 years of age in females. In males, a modest continuation of growth occurred until the end of observation time (21.7 years). Total mandibular length increased over time and showed excesses that added up over time (Figure 1A). Previous longitudinal studies [11, 12, 13] with a final observation at 16 to 18 years supports the data found in this more recent study. The persistence of active mandibular growth after the circumpubertal stage was reported by previous postpubertal cross-sectional studies with a final observation time at 16 years of age [10, 11]. Small increments of growth in total mandibular length were also observed in males in a large semi-longitudinal sample in the age intervals between 16 to 17 and 17 to 18 years [12]. Taken together, there is much evidence indicating that total mandibular length in class III individuals continues after puberty.

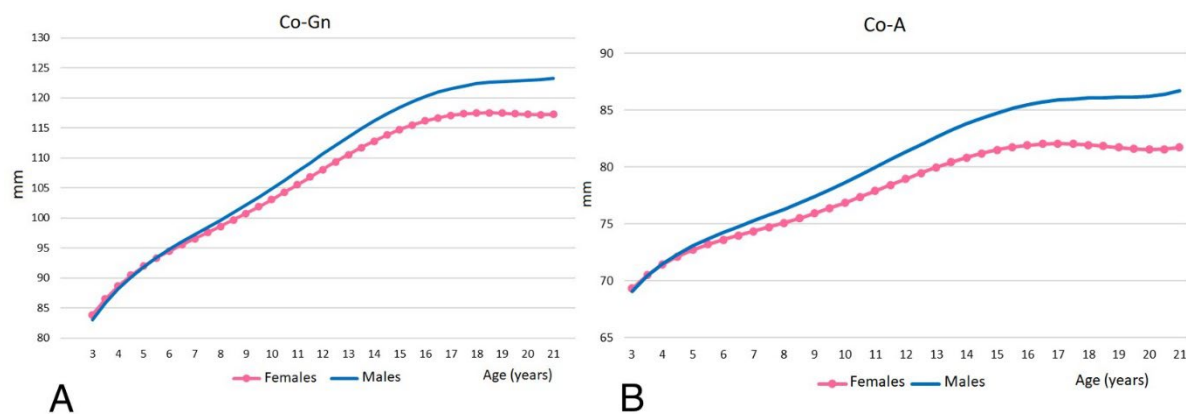


Figure 1. Multilevel growth curves for A) total mandibular length (Co-Gn), and B) midfacial length (Co-A) (from Rutili et al. [14]).

In the Rutili et al. study [14], midfacial length (Co-A) demonstrated an amount of growth at the end of the observation time that only was about a third (3.4 mm) of that shown by the increase in total mandibular length (8.4 mm). The midfacial length growth curve was curvilinear, and growth of this variable ended at about 17 years of age in both males and females (Figure 1B). Lower anterior facial height also increased over time, slowing substantially at about 17 years in both males and females. Some previous studies indicated a gender difference regarding the vertical growth of Class III subjects, with females showing a more horizontal growth pattern, and males presenting with a greater increase in anterior facial height [12, 13]. However, in the study by Rutili et al. [14], no gender differences in anterior facial height were found, both as growth trend and as growth amount. Gender differences were observed for total mandibular length, midfacial length, and facial divergence. For total mandibular length and midfacial length, these differences increased over time. Additionally, in males the growth spurt at 11 to 15 years was delayed by about one year compared with females, was greater by about 5 mm, and lasted one year longer than in females [14].

Maxillary position did not show significant changes during growth, and the maxilla was not retruded at the end of the observation period compared with normal individuals [15]. Mandibular forward position increased progressively both in males and in females, with a linear growth curve noted. At the end of the observation time, the mandible was protruded and larger than normal subjects [15]. The ANB angle decreased over time without differences between males and in females. At about 20 years of age, the ANB angle stabilized at a value of -2.5° .

The gonial angle decreased over time in both males and in females. Two accentuated decreases in the gonial angle were found at about 3 to 5 years of age and 12 to 16 years of age. This growth trend was also seen in previous longitudinal studies describing growth increments per year [12]. Facial

divergence decreased with differences between males and females. Females showed a less steep growth curve and smaller values than males until 14 years of age. Similarly, intermaxillary divergence decreased with time, showing a linear growth curve. Previous longitudinal studies demonstrated a similar decrease of divergence over time [11, 12]. A larger mandibular plane angle than normal was observed in Class III at 11 years of age, and it slightly decreased over time [13].

In general, Class III subjects show a variability of craniofacial aspects that make the overall analysis more complex. The most important clinical implication that can be derived from the analysis of growth in untreated Class III subjects is that due to this unfavorable growth pattern, particularly at the mandibular level, the outcomes of early orthodontic intervention should be monitored until at least age 17 in females and age 20 in males.

LONG TERM EFFICACY OF CLASS III TREATMENT WITH RAPID MAXILLARY EXPANSION AND FACEMASK

Several approaches have been proposed for skeletal Class III treatment. One of the most used and investigated in the literature is the RME/FM protocol [16, 17]. RME is commonly used in Class III patients to correct transverse maxillary deficiency. Transverse maxillary deficiency is a typical feature of Class III patients (-3.8 mm with respect to Class I subjects) [18]. In absence of transverse interarch discrepancy, RME use for 8 to 10 days has been proposed to disrupt the maxillary sutures and facilitate, presumably, maxillary protraction [19]. However, this approach has been abandoned by many because it has been demonstrated that the RME does not per se improve the protraction [20]. Additionally, a sagittal improvement of Class III malocclusion due to a maxillary advancement during the first weeks or months following RME has been shown to be temporary [19, 21]. In Class III patients, therefore, we recommend that the use of RME always should be associated with the FM.

In the short term, the combination of RME/FM has been shown to be effective in improving Class III dentoskeletal relationships, with an increase of about 1.7° to 2.1° in the SNA angle, a reduction of SNB of about -1.2° to -1.5°, a favorable improvement of ANB of nearly 4°, and an increase in lower anterior facial height of approximately 1.5° to 1.6° [22-24]. As for dentoalveolar effects in the short-term, mesial movement of the upper permanent molars and upper incisors occurs as a side effect of maxillary protraction. Skeletal palatal anchorage with FM has been proposed in cases where these dentoalveolar side effects need to be reduced or eliminated [25]. Patients with a proclination of the upper incisors at the beginning of treatment or with a lack of space for the eruption of the permanent upper lateral incisors or canines can benefit from this approach.

Systematic reviews in the “medium term” (with a final observation after the pubertal growth spurt) showed that the treatment effects produced by RME/FM were stable one to two years after the end of treatment. In subsequent years, however, a relapse of the maxillomandibular relationships was demonstrated, due to the typical growth features of Class III malocclusion characterized by excessive mandibular growth (particularly at puberty) associated with a sagittal position of the maxilla that remained either stable over time or with no differences compared with untreated controls [24, 26]. In Class III patients treated early with RME/FM, therefore, a long-term observation well beyond the pubertal stage is mandatory, as it has been shown that unfavorable mandibular growth continues long after this stage [14].

Unfortunately, studies on the long-term effects produced by RME/FM are scarce [27-31]. In addition, in most of them there exist major study design limitations such as small sample size and/or lack of comparison with a control group of subjects with untreated Class III malocclusion. Masucci et al. [30] compared the treated group to a control group of untreated Class III subjects. Unfortunately, for this study [30] the sample size was limited for both the treated (22 subjects) and control groups

(13 subjects). Le et al [31] analyzed the long-term efficacy of RME/FM by comparing a treatment group of 42 Class III patients with a control group of untreated Class III subjects. However, the two groups showed significantly different chronologic ages at baseline and at the long-term observation. Additionally, the long-term changes from initial to final observations in the treatment and control groups were not analyzed or compared. A new investigation [32] of the effects of RME/FM on class III malocclusion will be discussed in detail below.

Multicenter study of RME+FM

A recent multicenter study by Rutili and colleagues [32] evaluated the short-term and long-term effects produced by early treatment of Class III malocclusion with RME/FM as compared to a control group of untreated Class III subjects. To our knowledge, this investigation is the largest controlled long-term study conducted to date. Forty-four patients (27 females and 17 males) were recruited for participation from three centers (the University of Florence, the University of Rome Tor Vergata in Italy, and the University of PUC Minas in Brazil) with a mean age at the start of treatment of 8.1 ± 1.8 years and 9.8 ± 1.6 years at T1, were followed up until a long-term observation after 17 years of age for females and after 20 years of age in males (mean age 19.5 ± 1.6 years at T2). All patients had three observations available: at T0, before the treatment with RME/FM, at T1, immediately after treatment with RME/FM, and at T2, at a long-term observation. The treated group was compared with an historical untreated control group of 17 subjects (12 females and 5 males) with similar age at T0, T1, and T2. For the intergroup differences during the short-term (T1-T0) and long-term (T2-T0) intervals, an analysis of covariance (ANCOVA) was conducted with the values of the cephalometric variables at baseline as covariates.

Table 1. Descriptive statistics and statistical comparisons between treated and control groups for the T1-T0 changes.

	Treated Group N = 44 Mean (SD)	Control Group N = 17 Mean (SD)	Difference	95% CI	P value (ANCOVA)
Age	1.7 (0.4)	1.9 (0.6)	-0.2	-0.5; 0.0	0.066
NSBa°	0.4 (1.9)	0.0 (1.8)	0.4	-0.7; 1.5	0.448
SNA°	1.7 (1.6)	-0.1 (1.1)	1.8	0.9; 2.7	< 0.001
SNB°	-0.5 (1.3)	0.7 (1.3)	-1.1	-1.9; -0.4	0.002
ANB°	2.2 (2.0)	-0.8 (1.1)	2.9	1.9; 3.9	< 0.001
Wits mm	2.0 (3.3)	-0.7 (2.4)	2.7	1.4; 4.1	< 0.001
SN-Pal. Pl.°	-1.0 (1.5)	-0.1 (1.5)	-0.9	-1.8; -0.1	0.038
SN-Mand. Pl.°	0.5 (1.8)	0.1 (1.6)	0.4	-0.6; 1.4	0.467
Pal. Pl.-Mand. Pl.°	1.4 (2.5)	0.2 (1.8)	1.3	0.0; 2.7	0.048
Co-Gn mm	3.9 (2.6)	6.5 (1.6)	-2.4	-3.8; -1.1	0.041
CoGoMe°	-1.2 (2.0)	0.1 (1.9)	-1.3	-2.4; -0.1	0.031
OVJ mm	3.6 (2.3)	0.1 (1.5)	2.6	1.8; 3.5	< 0.001
OVB mm	0.2 (2.3)	-0.1 (1.4)	0.1	-1.1; 1.2	0.887
Mol. Rel. mm	-2.6 (2.2)	0.4 (2.5)	-3.6	-4.8; 2.4	< 0.001
Upper Inc.-Pal. Pl.°	4.5 (6.8)	4.9 (9.5)	-0.6	-3.9; 2.6	0.694
Lower Inc.-Mand. Pl.°	-0.4 (5.2)	2.3 (8.6)	-2.0	-5.3; 1.3	0.227

Pal.= Palatal; Pl.=Plane; Mand.=Mandibular; Mol.=Molar; Rel.=Relationship; Inc.=Incisor
ANCOVA = Analysis of Covariance; CI = Confidence interval; SD = Standard deviation

During the short-term interval (Table 1), significant improvements in sagittal skeletal relationships were found, with an increase of almost 3° in ANB and of 2.7 mm in the Wits appraisal value. These were ascribed mainly to a significant maxillary protraction (SNA +2.0°) rather than to a significant,

though not clinically relevant, mandibular retrusion (SNB -1.1°). As for vertical skeletal relationships, a significant increase in intermaxillary divergence was found, together with a significant counterclockwise rotation of the palatal plane ($+1.3^\circ$ Pal-Pl.-Mand. Pl.; -0.9° SN-Pal.Pl.). These changes, however, were not clinically relevant, as they were smaller than 1.0° - 1.5° . The significant closure of the mandibular angle (CoGoMe -1.3°) could have contributed to the significantly smaller increases in total mandibular length (-2.4 mm) with respect to the untreated Class III controls. As for the dentoalveolar changes, there were statistically significant improvements in both overjet ($+2.6$ mm) and A-P molar relationship (-3.6 mm) that could be due to a mesial movement of the maxillary molars rather than mandibular distalization. These findings are similar to those reported in systematic reviews on short-term outcomes produced by RME/FM [22-24].

Table 2. Descriptive statistics and statistical comparisons between treated and control groups for the T2-T0 changes.

	Treated Group N = 44 Mean (SD)	Control Group N = 17 Mean (SD)	Difference	95% CI	P value (ANCOVA)
Age	11.4 (1.7)	10.5 (2.9)	0.7	-0.1; 1.6	0.098
Unsuccess	11 (25%)	11 (65%)	0.18 (OR)	0.05; 0.61	0.007
NSBa°	0.3 (2.5)	0.5 (2.2)	-0.2	-1.7; 1.2	0.738
SNA°	1.5 (2.0)	0.6 (1.6)	1.0	-0.1; 2.1	0.075
SNB°	1.7 (2.3)	3.4 (2.8)	-1.7	-3.1; -0.3	0.021
ANB°	-0.2 (1.9)	-2.8 (2.1)	2.6	1.5; 3.7	<0.001
Wits mm	1.0 (3.4)	-1.7 (3.4)	2.7	1.1; 4.4	0.001
SN-Pal. Pl.°	0.1 (2.0)	0.7 (2.1)	-0.6	-1.8; 0.6	0.299
SN- Mand. Pl.°	-2.5 (2.8)	-1.6 (4.3)	-0.8	-2.7; 1.1	0.391
Pal. Pl.-Mand. Pl.°	-2.7 (3.4)	-2.3 (3.5)	-0.2	-2.1; 1.7	0.831
Co-Gn mm	19.1 (6.2)	22.9 (7.4)	-2.7	-6.2; 0.7	0.115
CoGoMe°	-3.9 (3.1)	-0.9 (4.4)	-2.9	-4.9; -0.9	0.006
OVJ mm	2.5 (2.6)	-0.6 (1.2)	2.1	1.3; 2.9	<0.001
OVB mm	1.1 (1.7)	-0.5 (1.5)	1.3	0.7; 2.0	<0.001
Mol. Rel. mm	0.0 (2.7)	1.9 (2.6)	-2.7	-3.9; -1.5	<0.001
Upper Inc.-Pal. Pl°	8.7 (8.0)	9.8 (9.6)	-1.4	-4.8; 2.0	0.418
Lower Inc.-Mand. Pl.°	1.3 (5.8)	-0.1 (8.6)	2.0	-1.7; 5.7	0.285

Pal.= Palatal; Pl.=Plane; Mand.=Mandibular; Mol.=Molar; Rel.=Relationship; Inc.=Incisor

ANCOVA = Analysis of covariance; CI = Confidence interval; OR = Odds ratio; SD = Standard deviation

During the overall long-term observation period of T2-T0 (Table 2), a significant improvement in the sagittal intermaxillary relationship was maintained. ANB and Wits appraisal improvements that were achieved during the short-term period remained stable at T2 ($+2.6^\circ$ and $+2.7$ mm, respectively). These favorable sagittal skeletal modifications must be attributed primarily to a significant control of mandibular sagittal position (SNB -1.7°) rather than to a non-significant maxillary advancement (SNA 1.0°). It should be noted that when looking at the long-term T2-T0 changes that occurred in SNA in the treated group, the value of $+1.5^\circ$ is similar to that shown during the short-term T1-T0 changes ($+1.7^\circ$). The non-significant maxillary advancement (SNA $+1.0^\circ$) during the long-term follow-up period (T2-T0) has to be ascribed mainly to the maxillary advancement that occurred in the control group ($+0.6^\circ$). This finding is consistent with Masucci et al. [30], who reported a long-term decline in maxillary protraction gains in Class III subjects compared with untreated controls. Vertical skeletal relationships did not increase during the overall interval from T1 to T2.

Both treated and control groups demonstrated the same amount of reduced intermaxillary divergence. This outcome also agrees with Masucci et al. [30] who did not report significant long-term differences in vertical skeletal relationships. The mandibular angle (CoGoMe) decreased significantly by almost 3° in the treated group with respect to the untreated Class III controls. This growth modification has been described as a mechanism to control or dissipate excessive mandibular growth along Co-Gn [33]. Using a morphometric analysis (thin-plate spline), Franchi et al. [34] analyzed the long-term mandibular effects produced by RME/FM and found that both the mandibular rami and condyles grew in an upward and forward direction in the treated group. In the above mentioned study [32], the closure of the mandibular angle, therefore, contributed to a reduction of excessive mandibular growth and helped to control mandibular prognathism through a favorable "shrinkage" of the mandible along Co-Gn. The significant decrease in the mandibular angle in the long term did not lead to a corresponding significant decrease in total mandibular length (-2.7 mm in favor of the treated group). Long-term smaller increments along total mandibular length in the treated group versus untreated Class III controls (-3.9 mm), though not statistically significant, were reported also by Masucci et al. [30]. As for the dentoalveolar variables, both the overjet and molar relationships improved significantly in the treated group in the long-term (+2.1 mm and -2.7 mm, respectively). Masucci et al. [30] found no significant long-term changes in overjet between the treated and untreated groups (+1.2 mm), while the improvement in molar relationship remained statistically significant in the treated group (-3.2 mm).

In general, our long-term study [32] showed that Class III early orthopedic treatment was effective in improving the dentoskeletal characteristics of Class III cases, with good stability in the long-term. Additionally, the long-term prevalence rate of unsuccessful outcomes was significantly smaller ($p = 0.007$) in the treated group (25%, 11 out of 44 patients) than in the control group (65%, 11 patients out of 17; Table 2).

LONG-TERM ASSESSMENT OF THE ROLE OF TREATMENT TIMING FOR RME/FM

One important aspect to consider in a Class III malocclusion treatment is the timing of the intervention. In that Class III malocclusion is one of the most challenging disharmonies to treat, numerous theories have been introduced over time to deal with a patient with this type of problem. Is it worthwhile to treat this malocclusion early, or is it better to wait until the end of growth?

One approach has been to defer treatment until adulthood. According to some authors, the unfavorable growth of Class III does not allow an effective improvement of the malocclusion despite orthopedic treatment, and typical Class III characteristics of prognathism cannot be altered by early treatment [35]. However, the resulting facial deformity of class III growth could lead patients and/or parents to request a treatment that limits the unpleasant aesthetic appearance. Furthermore, the stability of the surgical correction may not be achieved if the sagittal skeletal discrepancy is excessive, requiring a large mandibular set-back [36]. On the other hand, treatment with RME/FM during the early developmental phases has been shown to have good efficacy in improving the abnormal dentoskeletal characteristics of Class III patients, both in the short-term and in the long-term [32].

Regarding treatment timing for RME/FM, many studies have dealt with this topic that, however, remains controversial. For example, in 1971 Delaire [37] was the first one who proposed to start treatment with the FM at a very early period, during the deciduous dentition. Several short-term and long-term studies [38-41] reported that early treatment in the deciduous or early mixed dentition produced more favorable effects than at later stages. Chen et al. [42] found that treatment for a Class III growing patient would be best accomplished at the time of late mixed-early permanent dentition. Other studies [43, 44] stated that there was no difference between FM treatment initiated during the

early mixed or late mixed dentition. Similarly, studies in Asian populations [45, 46] indicated no differences in the effects of maxillary protraction treatment regardless of whether the treatment was initiated in the prepubertal or pubertal growth period.

The main limitations of the above mentioned studies were that different age ranges between groups were considered. Further, only Cha et al. [46] and Franchi et al. [41] included an indicator of individual skeletal maturity (hand-wrist method [47] and the cervical vertebral maturation method [48], respectively) to define treatment timing. Moreover, most studies investigated the short-term effect of treatment timing with RME/FM. Franchi et al. [41] evaluated the role of treatment timing on the postpubertal effects produced by RME/FM. They found that RME/FM treatment is most effective when it is started before puberty (early mixed dentition) rather than during the late mixed dentition, when most of the patients were starting or in puberty.

A crucial clinical question is whether treatment effects produced by RME/FM are more effective during the early prepubertal phases versus the late prepubertal period. This is why we recently performed a multicenter study [49] that was designed to answer this question by evaluating the effects induced by RME/FM in the long term (at least 17 years of age in females and at least 20 years in males). This study included a group of 17 early prepubertal patients (Early Prepubertal Group, EPG, 14 females and 3 males) with a mean age before treatment (T0) of 5.8 ± 0.7 years (age range 4.3-6.9 years) and a group of 17 late prepubertal patients (Late Prepubertal Group, LPG, 8 females and 9 males) with a mean age at T0 of 10.1 ± 0.8 (age range 9.0-11.1 years).

Table 3. Descriptive statistics and statistical comparisons between EPG and LPG at baseline (T0).

	EPG N = 17 Mean (SD)	LPG N = 17 Mean (SD)	Difference	95% CI	P – value (t-test)
Age (years)	5.8 (0.7) Range 4.3-6.9	10.1 (0.8) Range 9.0-11.1	4.3	3.7; 4.3	< 0.001
NSBa°	131.3 (6.0)	132.1 (5.5)	0.7	-3.3; 4.8	0.711
SNA°	78.7 (3.6)	78.8 (2.7)	0.2	-2.1; 2.4	0.885
SNB°	77.9 (3.2)	77.8 (2.7)	-0.2	-2.2; 1.9	0.881
ANB°	0.8 (1.9)	1.1 (1.7)	0.3	-1.0; 1.6	0.612
Wits mm	-4.6 (4.0)	-4.8 (2.4)	-0.3	-2.6; 2.0	0.815
SN-Pal. Pl.°	9.0 (3.3)	9.5 (2.4)	0.5	-1.5; 2.5	0.581
SN- Mand. Pl.°	36.1 (4.7)	37.1 (3.5)	1.0	-1.9; 3.9	0.486
Pal. Pl.-Mand. Pl.°	27.1 (5.2)	27.6 (3.2)	0.5	-2.5; 3.5	0.476
Co-Gn mm	91.6 (4.2)	102.8 (4.5)	11.3	8.2; 14.3	<0.001
CoGoMe°	128.3 (5.1)	128.2 (4.0)	-0.1	-3.3; 3.1	0.938
OVJ mm	-2.6 (2.0)	0.2 (1.8)	2.7	1.4; 4.0	<0.001
OVB mm	0.6 (2.1)	0.9 (1.4)	0.4	-0.9; 1.6	0.565
Mol. Rel. mm	2.8 (2.3)	2.2 (1.2)	-0.6	-1.9; 0.7	0.338
Upper Inc.- Pal. Pl.°	96.6 (5.5)	111.3 (7.0)	14.7	-10.3; 19.1	<0.001
Lower Inc. -Mand. Pl.°	83.4 (9.1)	87.3 (5.5)	3.9	-1.4; 9.1	0.145

SD = Standard deviation; CI = Confidence interval; EPG = Early prepubertal group; LPG = Late prepubertal group; Pal.= Palatal; Pl.=Plane; Mand.=Mandibular; Mol.=Molar; Rel.=Relationship; Inc.=Incisor

All patients in both EPG and LPG were treated with an RME/FM protocol before puberty according to the cervical vertebral maturation method [48], except for one female patient in the LPG who was treated at puberty. Fixed appliance therapy in the post-pubertal phase was performed in 80% of the patients. After the second phase of treatment, thermoformed Essix (invisible) retainers in both arches

were given to the patients. Lateral cephalograms were collected at the baseline (T0) and at the long-term observation (T1, mean ages in EPG 19.8 ± 1.0 years and in LPG 21.0 ± 2.1 years). Significant differences were found between the two groups for three cephalometric variables at T0 (Table 3). Total mandibular length was significantly greater in LPG (102.8 mm vs 91.6 mm in EPG) with a difference of 11.3 mm. This result agreed with that which was previously reported [44]. This data supports the concept that excessive mandibular growth is a critical aspect involved in the unfavorable growth of this type of malocclusion, particularly in the long term [14].

In terms of dentoalveolar changes, overjet showed a more favorable value in LPG (0.2 mm vs -2.6 mm in EPG) with a significant difference between the two groups of 2.7 mm. This result could be related to the dentoalveolar compensation that occurred due to significantly greater proclination of the upper incisors relative to the palatal plane in LPG (111.3°) as compared to that seen in the EPG group (96.6°).

Table 4. Descriptive statistics and statistical comparisons between EPG and LPG at the long-term observation (T1).

	EPG N = 17 Mean (SD)	LPG N = 17 Mean (SD)	Difference	95% CI	P – value (t-test)
Age (years)	19.8 (1.0) Range 18.4-21.7	21.0 (2.1) Range 17.1-24.4	1.2	0.1; 2.4	0.037
Unsuccess	3 (18%)	5 (29%)	1.94 (OR)	0.38; 9.88	0.688
NSBa°	131.2 (7.6)	131.5 (6.1)	0.3	-4.5; 5.1	0.902
SNA°	80.5 (3.4)	80.2 (3.0)	-0.3	-2.5; 2.0	0.798
SNB°	79.4 (4.5)	79.4 (3.4)	0.0	-2.8; 2.8	1.000
ANB°	1.1 (3.2)	0.8 (2.9)	-0.3	-2.4; 1.9	0.803
Wits mm	-3.7 (3.7)	-4.2 (2.6)	-0.6	-2.8; 1.7	0.616
SN-Pal. Pl.°	8.8 (3.9)	9.8 (2.6)	1.0	-1.3; 3.3	0.388
SN- Mand. Pl.°	32.8 (7.0)	35.0 (5.3)	2.2	-2.1; 6.5	0.303
Pal. Pl.-Mand. Pl.°	24.0 (6.8)	25.2 (4.8)	1.2	-2.9; 5.4	0.550
Co-Gn mm	115.7 (7.9)	117.5 (6.3)	1.8	-3.2; 6.8	0.464
CoGoMe°	122.7 (5.8)	125.0 (5.8)	2.3	-1.8; 6.3	0.264
OVJ mm	1.8 (1.5)	1.1 (2.6)	-0.7	-2.2; 0.8	0.348
OVB mm	1.5 (1.3)	1.3 (1.7)	-0.2	-1.2; 0.9	0.747
Mol. Rel. mm	2.2 (1.9)	3.2 (2.6)	1.0	-0.6; 2.5	0.220
Upper Inc.- Pal. Pl.°	116.4 (6.2)	116.8 (4.7)	0.4	-3.4; 4.3	0.826
Lower Inc. -Mand. Pl.°	91.0 (9.7)	90.2 (7.6)	-0.8	-6.9; 5.3	0.784

SD = Standard deviation; CI = Confidence interval; OR=Odds ratio; EPG = Early prepubertal group; LPG = Late prepubertal group; Pal.= Palatal; Pl.=Plane; Mand.=Mandibular; Mol.=Molar; Rel.=Relationship; Inc.=Incisor

Overall, the multicenter study comparing intervention in early vs. late puberty [49] showed that no significant differences in the long-term observation were found between the two groups (Table 4). The clinical implications of this finding are that there are no differences in long-term outcomes produced by RME/FM in prepubertal patients treated during either very early phase (4-7 years) or a later phase (9-11 years). This data indicates that if a patient treated during early prepubertal phases shows early signs of relapse, there is still another chance for a second phase of treatment with RME/FM at a late prepubertal stage.

As for long-term unsuccessful outcomes [49], the prevalence rate was greater for LPG (29%) than EPG (18%) though this comparison did not reach the level of statistical significance. This outcome

agrees with a previous study that reported that prevalence rate of unsuccessful of Class III treatment with RME/FM was increased in patients older than 10 years of age [28].

PREDICTION OF LONG-TERM SUCCESS/LACK OF SUCCESS FOR EARLY TREATMENT OF CLASS III MALOCCLUSION WITH RME/FM

Treatment failure of a skeletal Class III malocclusion is always a concern. Most studies have shown that the best treatment timing with RME/FM is during the early developmental phases (during the deciduous or early mixed dentition) [37-41]. However, using an early orthopedic treatment with this protocol does not always guarantee a successful long-term result. Lack of long term success has been observed both in Caucasian patients and in patients of Asian origin [28].

Some degree of relapse can occur following this treatment, sometimes resulting in a less than successful outcome of the intervention. A commonly used criterion for determining an unfavorable outcome is lack of maintenance of a positive overjet. Using this criterion, the prevalence rate of unsuccessful class III treatment outcomes has been estimated to be about 25%, according to long-term controlled studies [30, 32].

Relapse could be due primarily to a tendency to reestablish a preexisting unfavorable Class III growth pattern. For this reason, orthodontists over time have tried to identify variables that can predict future individual response to early orthopedic therapy. Are there any dentoskeletal features before treatment that may predispose to a poor long-term outcome?

In 2004, Baccetti et al. [50] attempted to identify cephalometric variables that are predictive for the long-term (postpubertal) outcome of early orthopedic treatment of Class III patients with RME/FM, followed by a phase of fixed appliances. Failure of treatment at T2 was defined as the concurrent presence of Class III permanent molar relationship, negative overjet, and Class III facial profile. Accordingly, the sample was divided into two groups, successful (30 patients, 71%) or unsuccessful (12 patients, 29%). After application of discriminant analysis, the craniofacial features of a bad responder were: 1) an excessive length of the mandibular ramus (i.e., increased posterior facial height), 2) an acute cranial base angle, and 3) a steep mandibular plane angle.

In 2011, Fudalej et al. [51] performed a systematic review on the prediction of the outcome of different types of orthodontic/orthopedic treatments of Class III malocclusion in growing patients. The gonial angle was identified most frequently (5 out of 14 publications) as a significant predictor of treatment outcomes. Specifically, a large gonial angle was a significant predictor for unsuccessful early Class III treatment.

Masucci et al. [30] reported prevalence rates of successful and unsuccessful cases (73% and 27%, respectively), which were similar to those reported by Baccetti et al. [50]. The unsuccessful cases were characterized by a modest degree of compliance during active treatment with the FM. Moreover, the unsuccessful cases showed a significantly greater gonial angle (3.8°), a significantly greater downward inclination of the mandibular plane to Frankfort horizontal (4.1°), and a significantly greater mesial molar relationship (1.5 mm) when compared with the successful cases [30].

The most recent study on this topic [52] developed and validated a prediction model to forecast long-term stability of early treatment with RME/FM in a sample of 73 Caucasian Class III growing patients (41 females and 32 males). Patients in the test group were treated at a mean age of 7.1 ± 1.6 years (range 4.4 to 11.1 years) and evaluated over the long term at a mean age of 21.8 ± 3.2 years. RME/FM treatment had a mean duration of 12 months, with a wearing of FM for 12 to 14 hour per day (nighttime included), extraoral elastics with a force of 400 to 500 g and about 30° of downward

inclination relative to the occlusal plane. All patients were treated until an overcorrection was achieved with a positive overjet and occlusal relationships towards Class II. After RME/FM treatment, retention with a chin cup was used. After that, a phase with fixed appliances was performed if necessary.

Unsuccessful treatment was defined based on the evaluation of both the occlusion and profile, as derived from the facial and intraoral photos and/or from the lateral cephalograms at the long-term observation. Twenty-four cephalometric variables were measured on the lateral cephalograms taken before treatment with RME/FM.

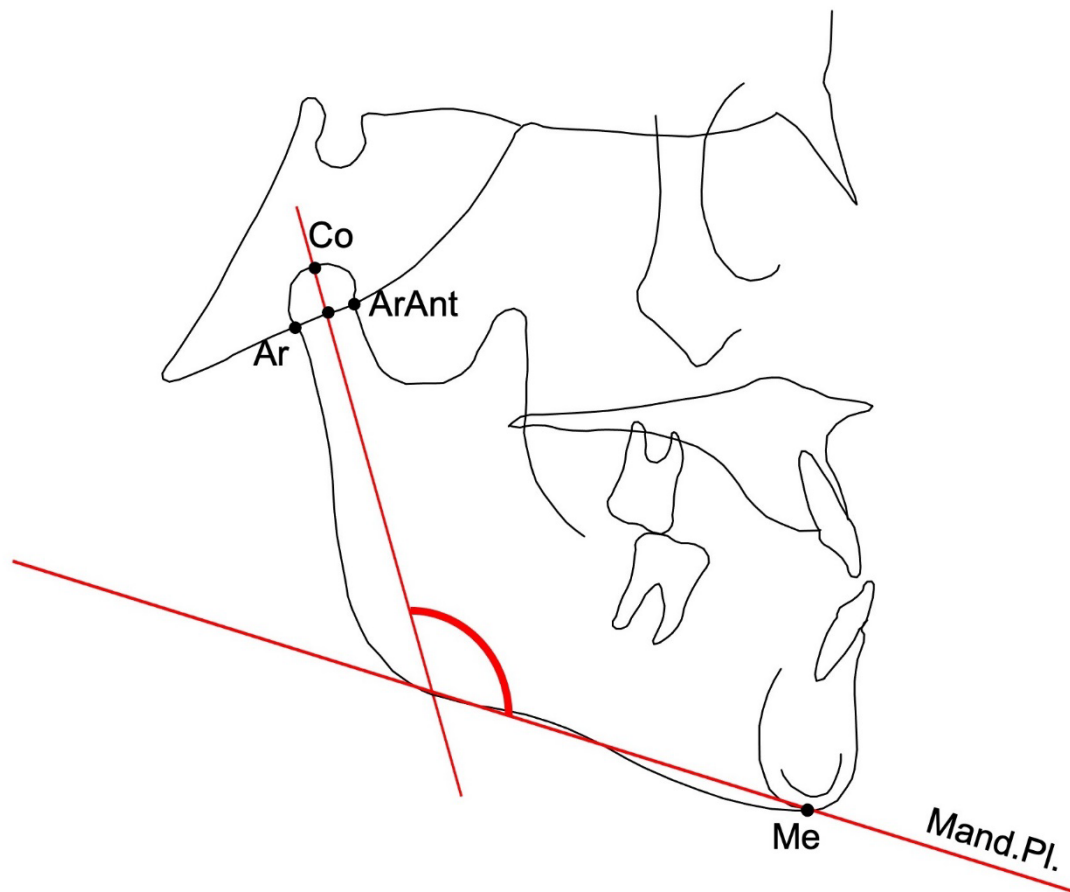


Figure 2. Angle between the condylar axis and the mandibular plane (Mand. PI.).

The prevalence rate of unsuccessful patients in the test group was 30% (22 out of 73 patients), similar to that reported in the studies described above. The prediction model comprised only one cephalometric variable, which was the angle between the condylar axis and the mandibular plane (CondAx–MP) (Figure 2). The condylar axis passed through point condyloidion and the midpoint between point articulare and articulare anterior. The mandibular plane passed through Menton, tangent to the lower mandibular border in the region of the gonial angle. Long-term unsuccessful treatment was predicted for pretreatment values of CondAx–MP greater than a cut-off value of 147.8° that corresponds to a probability of long-term unsuccessful outcome of 50%. Only 3 of 22 unsuccessful patients and 1 of 51 successful patients were predicted incorrectly. Accuracy was 0.95, sensitivity 0.86, and specificity 0.98. Positive and negative predictive values were 0.95 and 0.94. Moreover, it was possible to calculate the probability of success with the following formula:

$$P = 1 / 1 + e^{-(62.029 + 0.41973 \text{ CondaxMP})}$$

The prediction accuracy of 95% found in this long-term study [52] was higher than that found previously by Baccetti et al. [50] at a postpubertal observation (prediction accuracy of 83%).

From a practical standpoint, the probability of unsuccessful long-term outcome (expressed as a percentage) in a Caucasian Class III patient with a chronological age between 4.5 and 11 years that presents with indications for treatment with RME/FM can be calculated by using any spreadsheet software (e.g., Excel, Numbers, Calc) by copying the following formula in cell A1:

$$=1/(1+(1/EXP(-62.029+0.41973*(B1))))*100$$

The following step is to measure the value of the angle CondAx-MP on the pretreatment lateral cephalogram of the individual Class III patient and report their value in cell B1. Automatically in cell A1 will appear the percent probability of long-term unsuccessful outcome.

One of the most important aspects when proposing a new prediction model is to validate it on a different sample with similar characteristics to the population from which the model was derived. In the study under discussion [52], the prediction model derived from the test group was validated on a sample of 28 Caucasian patients (14 females and 14 males, mean age at the start of therapy of 9.0 ± 1.3 years and 18.2 ± 1.4 years at the long-term observation) that were available from the archives of the University of Florence and the University of Rome Tor Vergata. Also in this sample, all patients were treated with RME/FM for a mean period of 12 months. After RME/FM treatment, a retention phase with either a removable mandibular retractor or a Class III Bionator was performed, followed by fixed appliances if necessary. The percentage of unsuccessful patients in the validation group was 18% (5 out of 28 patients). The accuracy, sensitivity, specificity, positive predictive value, and negative predictive values also were high (96%, 100%, 96%, 83%, and 100%, respectively). These calculations provide relevant information, showing that the model works to predict class III RME/FM intervention for other groups of patients.

Though the predictive model proposed by Souki et al. [52] was reliable from a statistical standpoint, it should be applied *with caution* in everyday clinical practice because prediction of long-term outcomes of early treatment with RME/FM can be influenced by multiple factors, such as interindividual variability in compliance and/or ethnic and cultural differences. Patients' parents, therefore, should be informed carefully by the orthodontist that prediction of long-term success of treatment can be affected by a degree of uncertainty and that, in general, the probability of failure of treatment for class III malocclusion by RME/FM in the long term is 25% to 30%.

CONCLUSIONS

Untreated Class III malocclusion progressively worsens over time and does not show spontaneous improvement. Patients with Class III malocclusion generally have a protruded and larger mandible, commonly with the maxilla being not retruded at the end of the active growth period. While maxillary growth was completed in both genders at 17 years of age, mandibular growth ended about 17 years of age for females while in males it continued beyond 18 years.

In the short-term, RME/FM treatment significantly improved sagittal skeletal changes due mainly to maxillary protraction. In the long-term, improvements in Class III skeletal relationship remained stable, primarily due to favorable mandibular alterations rather than to maxillary protraction.

Ideal timing for treatment with RME/FM in growing Class III patients is during the prepubertal phase of development when looking at short term outcomes. In the long term, treatment with RME/FM was equally effective whether performed in the early prepubertal or late prepubertal period.

The long-term prevalence rate of unsuccessful outcomes was greater for Class III RME/FM patients treated during the late prepubertal (29%) than during the early prepubertal phases (18%), though this difference did not reach the level of statistical significance. The probability of long-term

unsuccess of early treatment with RME/FM is 25 to 30%. Unsuccess of treatment can be predicted in a Caucasian Class III patient with a chronologic age between 4.5 and 11 years when their pretreatment value of the angle between the condylar axis and the mandibular plane (CondAx–MP) is greater than 148°.

REFERENCES

1. Cruz RM, Krieger H, Ferreira R, Mah J, Hartsfield J Jr, Oliveira S. Major gene and multifactorial inheritance of mandibular prognathism. *Am J Med Genet A* 2008;146A(1):71-77.
2. Doraczynska-Kowalik A, Nelke KH, Pawlak W, Sasiadek MM, Gerber H. Genetic factors involved in mandibular prognathism. *J Craniofac Surg* 2017;28(5):e422-e431.
3. Dehesa-Santos A, Iber-Diaz P, Iglesias-Linares A. Genetic factors contributing to skeletal class III malocclusion: a systematic review and meta-analysis. *Clin Oral Investig* 2021;25(4):1587-1612.
4. Hardy DK, Cubas YP, Orellana MF. Prevalence of angle class III malocclusion: a systematic review and meta-analysis. *Open Journal of Epidemiology* 2012;2(04):75-82.
5. Ngan P, Hägg U, Yiu C, Merwin D, Wei SH. Cephalometric comparisons of Chinese and Caucasian surgical Class III patients. *Int J Adult Orthodon Orthognath Surg* 1997;12(3):177-188.
6. Proffit WR, Fields HW Jr, Moray LJ. Prevalence of malocclusion and orthodontic treatment need in the United States: estimates from the NHANES III survey. *Int J Adult Orthodon Orthognath Surg* 1998;13(2):97-106.
7. Battagel JM. The aetiological factors in Class III malocclusion. *Eur J Orthod* 1993;15(5):347-370.
8. Baccetti T, Reyes BC, McNamara JA Jr. Gender differences in Class III malocclusion. *Angle Orthod* 2005;75(4):510-520.
9. Angle EH. *Treatment of Malocclusion of the Teeth: Angle's System*. Philadelphia, PA: S. S.-White Dental Manufacturing Company, 1907.
10. Reyes BC, Baccetti T, McNamara JA Jr. An estimate of craniofacial growth in Class III malocclusion. *Angle Orthod* 2006;76(4):577-584.
11. Baccetti T, Franchi L, McNamara Jr JA. Growth in the untreated Class III subject. *Seminars in Orthodontics* 2007;13(3):130-142.
12. Alexander AE, McNamara JA Jr, Franchi L, Baccetti T. Semilongitudinal cephalometric study of craniofacial growth in untreated Class III malocclusion. *Am J Orthod Dentofacial Orthop* 2009;135(6):700.e1-701.
13. Wolfe SM, Araujo E, Behrents RG, Buschang PH. Craniofacial growth of Class III subjects six to sixteen years of age. *Angle Orthod* 2011;81(2):211-216.
14. Rutili V, Nieri M, Giuntini V, McNamara JA Jr, Franchi L. A multilevel analysis of craniofacial growth in subjects with untreated Class III malocclusion. *Orthod Craniofac Res* 2020;23(2):181-191.
15. Bhatia SN, Leighton BC. *A Manual of Facial Growth: A Computer Analysis of Longitudinal Cephalometric Growth Data*. Oxford, UK: Oxford University Press, 1993, pp. 1-401.
16. McNamara JA Jr. An orthopedic approach to the treatment of Class III malocclusion in young patients. *J Clin Orthod* 1987;21(9):598-608.
17. Ngan PW, Hagg U, Yiu C, Wei SH. Treatment response and long-term dentofacial adaptations to maxillary expansion and protraction. *Semin Orthod* 1997;3(4):255-264.
18. Franchi L, Baccetti T. Transverse maxillary deficiency in Class II and Class III malocclusions: a cephalometric and morphometric study on postero-anterior films. *Orthod Craniofac Res* 2005;8(1):21-28.
19. Haas AJ. Rapid expansion of the maxillary dental arch and nasal cavity by opening the midpalatal suture. *Angle Orthod* 1961;31(2):73-90.

20. Foersch M, Jacobs C, Wriedt S, Hechtner M, Wehrbein H. Effectiveness of maxillary protraction using facemask with or without maxillary expansion: a systematic review and meta-analysis. *Clin Oral Investig* 2015;19(6):1181-1192.
21. Farronato G, Giannini L, Galbiati G, Maspero C. Sagittal and vertical effects of rapid maxillary expansion in Class I, II, and III occlusions. *Angle Orthod* 2011;81(2):298-303.
22. Cordasco G, Matarese G, Rustico L, et al. Efficacy of orthopedic treatment with protraction facemask on skeletal Class III malocclusion: a systematic review and meta-analysis. *Orthod Craniofac Res* 2014;17(3):133-143.
23. Woon SC, Thiruvengkatachari B. Early orthodontic treatment for Class III malocclusion: a systematic review and meta-analysis. *Am J Orthod Dentofacial Orthop* 2017;151(1):28-52.
24. Lee WC, Shieh YS, Liao YF, Lee CH, Huang CS. Long-term maxillary anteroposterior changes following maxillary protraction with or without expansion: A meta-analysis and meta-regression. *PLoS One* 2021;16(2):e0247027.
25. Rutili V, Nieri M, Franceschi D, Pierleoni F, Giuntini V, Franchi L. Effects produced by the facemask with and without skeletal anchorage for the orthopaedic treatment of Class III malocclusion in growing patients: a systematic review and meta-analysis of RCTs. *Eur J Orthod*. 2023;45(2):157-168.
26. Kakali L, Christopoulou I, Tsolakis IA, et al. Mid-term follow up effectiveness of facemask treatment in class III malocclusion: a systematic review. *Int Orthod* 2021;19(3):365-376.
27. Hägg U, Tse A, Bendeus M, Rabie AB. Long-term follow-up of early treatment with reverse headgear. *Eur J Orthod* 2003;25(1):95-102.
28. Wells AP, Sarver DM, Proffit WR. Long-term efficacy of reverse pull headgear therapy. *Angle Orthod* 2006;76(6):915-922.
29. Wendl B, Stampfl M, Muchitsch AP, et al. Long-term skeletal and dental effects of facemask versus chin cup treatment in Class III patients : A retrospective study. *J Orofac Orthop* 2017;78(4):293-299.
30. Masucci C, Franchi L, Defraia E, Mucedero M, Cozza P, Baccetti T. Stability of rapid maxillary expansion and facemask therapy: a long-term controlled study. *Am J Orthod Dentofacial Orthop* 2011;140(4):493-500.
31. Le BNH, Goonewardene M, Duigou C, Bharat C. The long-term efficacy of rapid maxillary expansion and facemask therapy in Class III malocclusion. *Austral Orthod J* 2020;36(1):27-37.
32. Rutili V, Souki BQ, Nieri M, Farnese Morais Carlos AL, Pavoni C, Cozza P, McNamara JA Jr, Giuntini V. Long-term effects produced by early treatment of Class III malocclusion with rapid maxillary expansion and facemask followed by fixed appliances: a multicenter retro-prospective controlled study. *Orthod Craniofac Res* 2023. doi: 10.1111/ocr.12748. Online ahead of print.
33. Lavergne J, Gasson N. Operational definitions of mandibular morphogenetic and positional rotations. *Scand J Dent Res* 1977;85(3):185-192.
34. Franchi L, Pavoni C, Cerroni S, Cozza P. Thin-plate spline analysis of mandibular morphological changes induced by early Class III treatment: a long-term evaluation. *Eur J Orthod* 2014;36(4):425-430.
35. Campbell PM. The dilemma of Class III treatment. Early or late? *Angle Orthod* 1983;53(3):175-191.
36. Jakobsone G, Stenvik A, Sandvik L, Espeland L. Three-year follow-up of bimaxillary surgery to correct skeletal Class III malocclusion: stability and risk factors for relapse. *Am J Orthod Dentofacial Orthop* 2011;139(1):80-89.
37. Delaire, J. Maxillary development revisited: relevance to the orthopaedic treatment of Class III malocclusions. *Eur J Orthod* 1997;19(3):289-311.
38. Kapust AJ, Sinclair PM, Turley PK. Cephalometric effects of face mask/expansion therapy in Class III children: a comparison of three age groups. *Am J Orthod Dentofacial Orthop* 1998;113(2):204-212.

39. Saadia M, Torres E. Sagittal changes after maxillary protraction with expansion in class III patients in the primary, mixed, and late mixed dentitions: a longitudinal retrospective study. *Am J Orthod Dentofacial Orthop* 2000;117(6):669-680.
40. Baccetti T, Franchi L, McNamara JA Jr. Treatment and posttreatment craniofacial changes after rapid maxillary expansion and facemask therapy. *Am J Orthod Dentofac Orthop* 2000;118(4):404-413.
41. Franchi L, Baccetti T, McNamara JA Jr. Postpubertal assessment of treatment timing for maxillary expansion and protraction therapy followed by fixed appliances. *Am J Orthod Dentofac Orthop* 2004;126(5):555-568.
42. Chen L, Chen R, Yang Y, Ji G, Shen G. The effects of maxillary protraction and its long-term stability—a clinical trial in Chinese adolescents. *Eur J Orthod* 2012;34(1):88-95.
43. Merwin D, Ngan P, Hagg U, Yiu C, Wei SH. Timing for effective application of anteriorly directed orthopedic force to the maxilla. *Am J Orthod Dentofacial Orthop* 1997;112(3):292-299.
44. Yüksel S, Uçem TT, Keykubat A. Early and late facemask therapy. *Eur J Orthod* 2001;23(5):559-568.
45. Hwang CJ, Kyung SH, Lim JK. Treatment effect of protraction head gear on skeletal Class III malocclusion. *Korean J Orthod* 1994;24(4):851-860.
46. Cha KS. Skeletal changes of maxillary protraction in patients exhibiting skeletal Class III malocclusion: a comparison of three skeletal maturation groups. *Angle Orthod* 2003;73(1):26-35.
47. Fishman LS. Radiographic evaluation of skeletal maturation. A clinically oriented method based on hand-wrist films. *Angle Orthod* 1982;52(2):88-112.
48. McNamara JA Jr, Franchi L. The cervical vertebral maturation method: a user's guide. *Angle Orthod* 2018;88(2):133-143.
49. Rutili V, Souki BQ, Nieri M, Farnese Morais Carlos AL, Pavoni C, Cozza P, McNamara JA Jr, Giuntini V. Long-term assessment of treatment timing for rapid maxillary expansion and facemask followed by fixed appliances: a multicenter retro-prospective study. *J Clin Med* 2023;12(21):6930
50. Baccetti T, Franchi L, McNamara JA Jr. Cephalometric variables predicting the long-term success or failure of combined rapid maxillary expansion and facial mask therapy. *Am J Orthod Dentofacial Orthop* 2004;126(1):16-22.
51. Fudalej P, Dragan M, Wedrychowska-Szulc B. Prediction of the outcome of orthodontic treatment of Class III malocclusions—a systematic review. *Eur J Orthod* 2011;33(2):190-197.
52. Souki BQ, Nieri M, Pavoni C, et al. Development and validation of a prediction model for long-term unsuccess of early treatment of Class III malocclusion. *Eur J Orthod* 2020;42(2):200-205.

ORTHODONTICS, MALOCCLUSION, AND TEMPOROMANDIBULAR JOINT PAIN: WHERE IS THE ASSOCIATION?

Ambra Michelotti, Rosaria Bucci, Roberto Rongo

ABSTRACT

Orthodontists routinely see patients reporting signs and symptoms of temporomandibular joint (TMJ) problems before, during, and after orthodontic treatment. Because of the close anatomical and functional relationship between the dental occlusion and the TMJs, orthodontic treatment has been historically considered either a remedy or a cause of TMJ disorders. Occlusion has been considered for years to be one of the major etiological factors causing temporomandibular disorders (TMDs). Nevertheless, the associations reported recently are few, weak, and inconsistent across studies. Furthermore, the correction of a malocclusion by an orthodontic treatment seems to neither prevent nor increase the risk of developing TMDs. Hence, the role of the occlusion and orthodontic treatment in TMD should not be overstated. In particular, in some cases occlusal changes could be the consequence rather than a cause for TMDs. Some local or systemic pathologies affecting the TMJs, such as arthritis, hypoplasia, and hyperplasia, may result in occlusal changes. The management of these conditions requires a deep understanding of the underlying pathology and often a complex multidisciplinary treatment. It is therefore crucial for orthodontists to understand the relationship between occlusion and TMJ problems and to develop the diagnostic skills that are necessary to assess the TMJs and jaw function. In this chapter we discuss the relationship between TMDs and occlusion and the most common TMDs, such as joint pain and disc displacement, providing suggestions on how to diagnose and manage these conditions.

KEY WORDS: Temporomandibular Disorders, Malocclusions, Occlusion, Arthralgia, Disc Displacement

INTRODUCTION

The correct functioning of the temporomandibular joint (TMJ) is of paramount importance for patients' wellbeing and oral health-related quality of life [1–3]. Orthodontists routinely work on dental occlusion, and occlusal changes may also result from several TMJ pathologies. A deep understanding of the relationship between occlusion and TMJ problems is therefore crucial for orthodontists [4]. Temporomandibular disorder (TMD) is a collective term including a set of heterogeneous conditions that affect the masticatory muscles, the temporomandibular joints (TMJs), and the surrounding tissues and structures. These conditions are characterized by regional acute or persistent pain in the facial and/or preauricular areas, limitation, or interference in jaw functions (e.g., chewing, yawning, and talking), and/or noises from the TMJs during jaw movements. The most common conditions are classified in the diagnostic criteria for temporomandibular disorders (DC/TMDs) [5].

Among children and adolescents recruited from patient populations and general populations, researchers performing standardized clinical examinations reported an average prevalence of TMD ranging from 7.3% to 30.4% [6]. Among adults, TMDs represent the most common non-dental orofacial pain conditions, affecting approximately 5 to 12% of the population, and the second most common musculoskeletal condition after chronic low back pain [5]. In the general population, TMD prevalence peaks in middle age and then gradually diminishes among both men and women [7]. It has been

extensively demonstrated that the risk of developing TMD in women is twice that of men, considering both overall TMD diagnosis and individual diagnosis of muscle and joint diseases. The level of pain associated with TMDs can range from none to extremely severe. Most people with TMD report that symptoms are intermittent and can fluctuate, and self-remission of symptoms is frequently observed [8]. On the other hand, one-third of TMD patients can turn from acute conditions to chronic persistent painful symptoms due to several intrinsic and extrinsic factors [9].

Individuals with a diagnosis of TMD pain, especially those presenting with chronic TMDs, manifest comorbidities with multiple current chronic pain conditions, such as chronic back pain, myofascial syndrome, chronic stomach pain, chronic migraine headache, irritable bowel syndrome, and fibromyalgia [10, 11]. In addition, many non-specific and non-painful comorbid conditions (e.g., tendency to faint, sleep disturbances, depression, tinnitus) are often reported by TMD patients, thus these are listed among the noteworthy predictors of first-onset TMD [12].

Finally, changes in the occlusal relationship may result from changes in TMJ morphology, which are associated with degenerative joint disease, neoplasm, or fractures. It is therefore important that orthodontists have the necessary diagnostic skills to assess TMJ problems [13]. Finally, orthodontists have been blamed for provoking TMDs and it is important to know what the effects of orthodontic treatment on TMJ may be [14, 15].

ETIOLOGY OF TMD

The development of all types of TMDs has been associated with multiple genetic, physical, psychological, and environmental etiological factors. Due to the complexity and heterogeneity of these disorders, a single cause is highly unlikely to be identified in any given patient.

Increased frequency of parafunctional behaviors has been reported as one of the major risk factors for TMD onset, probably due to the micro-trauma determined by overuse of muscle and jaw joints during parafunctional oral activities [10]. Other strong risk factors for developing TMD are increased number of painful and non-painful comorbid conditions (e.g., irritable bowel syndrome, depression, tinnitus), pain elsewhere in the body, and poor sleep quality [12, 16]. Minor contributors include psychological stress, anxiety, obsessive-compulsive feelings, and pain-coping strategies [17]. Interestingly, among 300 genes investigated, six single-nucleotide polymorphisms (SNPs) have been identified as risk factors for chronic TMD, also supporting a fundamental role of genetic markers in the development of these disorders [18]. Macro-trauma of the jaws, due to car accidents, falls, sports injuries, forceful oral intubation, and other causes of prolonged and forced mouth opening, such as dental treatments, has been demonstrated to be the one of the major initiating factors for TMD incidence [19].

Anatomical factors – the role of condylar position

The role of anatomical factors in the development of TMD has been a topic of great debate in the literature [20]. Currently, this relationship is still an area of ongoing discussion [21]. Since the early 1970s, it has been hypothesized that a malocclusion can have a negative impact on the physiological condylar-disc relationship, which in turn can result in the onset of TMDs [22]. Hence, for many years dentists adopted numerous procedures involving repositioning of the mandible as part of dental treatments. The aim of mandibular repositioning was to obtain an optimal and repeatable condyle-to-skull relationship, in order to prevent TMD development or to manage TMD signs and symptoms. Therefore, this assumption supported the existence of “good” and “bad” condyle positionings in the temporal fossa [23]. According to the early definition, the ideal condyle-fossa relationship (“centric relation”) was considered as a jaw position, achieved when the mouth is fully closed, that should be

identified independently from tooth contact. The definition of centric relation underwent several changes and adjustments over time, until being integrated with some concepts related to dental occlusion. In particular, the concept of centric relation evolved from being a simple reference into a “biologically desirable” position of the lower jaw. When the mandible is in its centric relation, a good static intercuspation of upper and lower teeth (in the so-called “centric occlusion”) should occur. According to these premises, whenever centric occlusion corresponds to the maximum intercuspation of the teeth, the patient maintains a status of health; when discrepancies between maximum intercuspation and centric occlusion exist, an orthodontic treatment should be suggested to correct this discrepancy [24].

However, these theories have been widely questioned for several reasons. First, the clinical relevance of centric relation is highly questionable. In particular, when comparing the condylar position (assessed with magnetic resonance imaging [MRI]) related to different dental positions in a symptom-free population, minor and non-statistically significant differences were observed [25]. Second, there is no evidence that the position of the condyle within the fossa might be associated with ongoing TMD, or with increased (or decreased) risk to develop TMD [26]. MRI studies pointed out that condylar position is characterized by great variability, both within and between individuals, and anterior/posterior positions of the mandibular condyle as well as an anterior location of the articular disc should be considered as a variation of normality [27]. Anterior, concentric, and posterior condylar positions can be found in joints of healthy volunteers, and no differences in condylar position were found between symptomatic and asymptomatic individuals [28, 29].

In addition, it has been observed that the condyle-fossa relationship may change depending on several factors, such as fatigue of masticatory muscles, oral behaviors, posture, tongue pressure, hydration of the disc, and wear of the dental surfaces [30]. Current evidence indicates that the position of the TMJ in healthy subjects is variable, ranging from retruded to centered and anterior, hence it can be speculated that an ideal three-dimensional (3D) position of condyle that can be used to prevent or treat TMD does not exist [31-33].

Condyle-fossa relation is strongly influenced by anatomical variation of the fossa, varying from narrow and deep to wide and shallow. Asymptomatic patients may present three possible scenarios of fossa-condyle relation: a concentric position of the condyle in the fossa, a posterior position of the condyle in the fossa, or an anterior position of the condyle in the fossa, but with an average ratio fossa depth/fossa width. On the contrary, patients with disc displacement more commonly present a wider and shallower fossa or a very narrow posterior joint space associated with a narrow or a deep fossa, depending on the typology of disc displacement [34]. Hence, anatomical factors seem to have a more important role than condylar position in the onset of TMDs.

Current concepts of joint functional anatomy underlined that most joint movements occur physiologically along the articular crest. Therefore, the TMJ seems to biologically operate as a “ball on a hill” (rather than a ball in a socket), capable of travelling on both slopes of that hill, thus limiting the importance of its position within the fossa when the mouth is closed [35].

Finally, most patients are capable of growing and adapting continuously throughout their lives. A healthy, well-adapted jaw position does not need to be analyzed or changed. Therefore, there is currently no evidence to support unnecessary bite-changing and jaw-repositioning interventions as therapeutic or preventative procedures for TMDs.

Anatomical factors – the role of occlusal disharmonies

For many years, clinicians and researchers have considered occlusal factors and the static dental occlusion (i.e., the way the teeth fit together during intercuspation) to be associated with developing TMDs. Also, modifications of the occlusion, including orthodontic treatment, have been claimed to have diverse effects on TMDs. It has been hypothesized that orthodontic treatment might contribute to the development of TMD. On the other hand, orthodontic treatment is often offered as a preventive strategy or treatment option for TMD with the intent to re-establish the ideal occlusal relationship.

A systematic review on the association between occlusal disharmonies and presence or absence of TMD underlined that the associations reported in the literature are few, weak, and mainly drawn from research with a single-variable design. Furthermore, the associations are not consistently reported across studies, thus supporting the idea that the observed associations may even be due to chance [36]. A recent review addressed the prevalence of TMD signs and symptoms among patients seeking orthodontic treatment: interestingly, the authors observed a prevalence of TMD ranging from 21.1% to 73.3%, showing significantly higher values compared to those observed among the general population. However, inconsistent findings regarding association between TMD and specific occlusal features were observed [37]. Notwithstanding, the authors concluded that considering the high possibility of orthodontists encountering patients with pre-existing TMD, a routine TMD-related examination prior the commencement of orthodontic therapy appears to be crucial [37].

Population-based studies on large-scale samples failed to support the relationship between TMD signs and symptoms and different static occlusal parameters [38–40]. A recent cohort study, based on a large sample of New Zealanders born between April 1972, and March 1973, aimed at assessing the role of posterior crossbite, overjet, and overbite, which were present during adolescence, in the development of TMJ clicking sounds 30 years later. This long-term assessment pointed out overall no associations between occlusal variables and TMJ outcomes. Interestingly, only the association between increased overbite and lower prevalence (protective factor) of self-reported or clinically assessed disc displacement with reduction was reported [41].

Considering the prevalence of occlusion or malocclusion among individuals with TMD and without history of previous orthodontic treatment, cross-sectional studies have identified similar features of sagittal, vertical, and transversal dental occlusion in populations with TMD compared to those without [42, 43]. However, despite the growing evidence supporting the view that occlusion should not be considered a contributing cause for common TMD, more than half of dentists worldwide suggest occlusal therapies and occlusal adjustments as a treatment for TMD [44–46].

TMD complaints can appear before, during, or following an orthodontic treatment. Most likely, if signs and symptoms of TMD occur during or after treatment, orthodontists may be blamed for causing TMD by unsatisfied patients. Considering the high prevalence of TMD among orthodontic patients, considering patients' beliefs regarding the curative role of orthodontic treatment in TMD, and in view of possible medical-legal implications, it is crucially important to make an appropriate functional diagnostic assessment before starting an orthodontic treatment. In case of positive findings emerging from screening questionnaires and clinical examination, one could decide either to manage the TMD issue or to refer the patient for multidisciplinary care. The management should primarily include patient education and a conservative treatment protocol.

As a general rule, orthodontic treatment should not be initiated if a patient suffers from pain, either coming from the muscle or from the joint area [47]. The same cannot be stated with regard to non-painful joint diseases (i.e., disc displacement with reduction) in absence of functional limitations. As a matter of fact, due to the fluctuation of this symptom and to the absence of harmfulness of the

noise alone, disc displacement with reduction does not represent a contra-indication for the beginning of an orthodontic treatment if pain is not present. Once the pain has disappeared, the patient has integrated habit reversal techniques and counseling in his or her daily life, and the pain-free condition remains stable for a reasonable period, initiation of orthodontic therapy may be considered. It is clear that a patient with a pre-existing TMD should be carefully followed-up during orthodontic treatment, as he or she represents a more “vulnerable” individual and relapses can occur.

In case TMD signs and symptoms arise during the orthodontic treatment, the priority is to reassure the patient (and the parents, if applicable) regarding the benign nature of the disease, the favorable prognosis, the frequent self-limiting course, and the etiologic factors, not including the orthodontic treatment. It should be stressed that TMD can occur in all healthy individuals [48]. Following an appropriate diagnosis, “active” orthodontic treatment should be temporarily limited to avoid additional load on the muscles and joints, thus limiting exacerbating factors. This temporary interruption of the treatment does not imply removal of a multibracket fixed therapy or dismissing a removable functional appliance, but instead limiting the use of active forces (such as intermaxillary elastics) or reducing the wearing hours of a removable device (e.g., only during night-time) in order to reduce the contribution of external factors [47]. At the same time, conservative treatment protocol as suggested above can be used to manage TMD signs and symptoms. As soon as the pain has disappeared, orthodontic treatment can re-start as previously planned. However, in a small number of more severe cases, the need to modify the treatment plan according to the patient’s conditions can arise, and acceptable orthodontic compromises should be discussed with the patient.

Interestingly, although occlusal interferences have been claimed for many years as primary factors responsible for TMD development, it must be considered that continuous occlusal changes occur during orthodontic treatment and no direct correlation with TMD onset has been observed. Most likely, the development of a TMD is due to the individual patient’s ability to adapt (or not adapt) to changes in the occlusion (Figure 1).

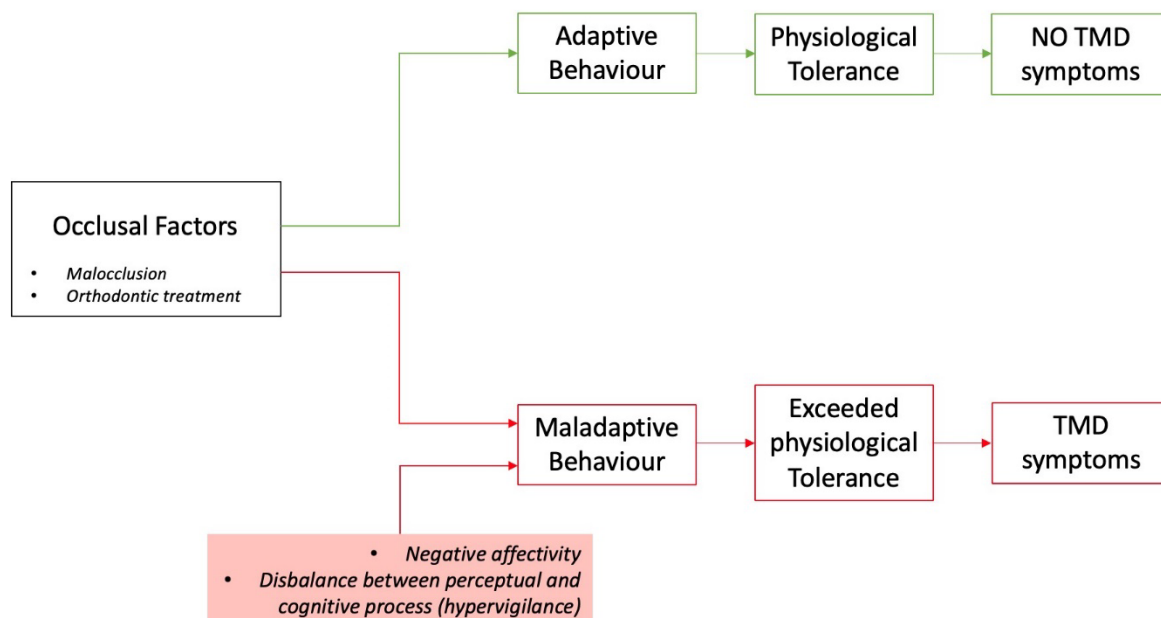


Figure 1. Flow-chart showing different adaptation paths to occlusal changes.

When TMD signs and symptoms appear after orthodontic treatment, no specific indication in terms of treatment and management are needed. Following the appropriate diagnosis, the stepped care approach for TMD management should be adopted. The major role of the orthodontist in this context is to talk with the patient (sometimes also with the general practitioner), to overcome a variety of negative beliefs or opinions about the TMD-orthodontic relationship [49].

Treatment with clear aligners is widely chosen by adult patients these days, in view of their aesthetics and compatibility with their daily lives [50]. Some authors have suggested that clear aligners may be a preferential treatment choice for patients with sleep bruxism due to their full occlusal coverage, which allows protection for the tooth surface against dental wear [51]. However, researchers have observed that the masticatory muscle activity tends to increase in short-term follow-up (within six months of treatment) after the commencement of clear aligner therapy, and some signs and symptoms of muscle soreness are present among orthodontic patients wearing aligners [52–54]. Therefore, according to current findings the therapeutic use of clear aligners in patients with TMD is not recommended, as temporary increase in muscle pain might occur.

The existing controversies regarding the association between occlusion and TMD possibly lies in the definition of “occlusion” [21]. Indeed, despite the absence of causal association, the role of occlusion (but still not malocclusion) in the development of TMD merits attention. As a matter of fact, from an extremely mechanical and static interpretation, the occlusion is considered as “the way the teeth fit together,” and this relation often breaks away from what is considered ideal. However, in a broader and more comprehensive sense, the dental occlusion represents a highly complex specialized system of integration of peripheral inputs arising from periodontal, dental, and soft tissue mechanoreceptors. This complex network of information is processed continuously through stimulus and response mechanism of the central nervous system (CNS) to adjust and refine jaw position and movements [55]. Therefore, the broader concept of occlusion should refer to “the way one can interpret the contact between teeth” and not only to the way teeth fit together, and the different interindividual adaptability should be considered as the actual factor that might predispose a patient to the development of TMD.

TMJ DISORDERS

TMJ problems are routinely encountered by orthodontists in daily practice, and therefore it is important to correctly diagnose and manage these conditions. TMJ signs and symptoms include pain (arthralgia), condylar disc incoordination (disc displacement), and anatomical or degenerative changes (arthrosis, systemic arthritis, and growth disturbances) [56]. In general, the management of signs and symptoms of TMDs, such as pain or dysfunction, should include reversible therapies based on the biopsychosocial model [57, 58]. The biopsychosocial model suggests the patient’s biologic, clinical, and behavioral characteristics as factors involved in the onset, maintenance, and remission of TMDs [58]. Hence, the focus of occlusion as a risk factor for TMD has shifted, and other putative factors have been identified, such as genetic predisposition, CNS pain control mechanisms, psychosocial status, and parafunctions, with all of these playing an important role in the TMD evolution [59]. Based on current evidence, changing the occlusion to treat TMD is not recommended [24]. Conversely, reversible treatments should be preferred, also because of large fluctuations in signs and symptoms of TMDs. Symptoms may spontaneously decrease or even disappear without any treatments; hence conservative management is recommended including cognitive-behavioral therapies, biofeedback, oral occlusal appliances, physical therapies, and pharmacologic agents [60, 61].

There is no convincing evidence supporting the idea that occlusion, malocclusion, or orthodontic treatment cause TMDs; but some TMDs, such as osteoarthritis or arthralgia, may cause occlusal alterations such as open bite, crossbite, or Class II malocclusion. Hence, an appropriate TMJ

examination before starting orthodontic treatment is needed, and could affect the treatment planning that should be tailored based on patient conditions and expectations [13].

Joint pain (arthralgia)

Arthralgia is defined as joint pain that is affected by jaw movement, function, or parafunction, and replication of this pain occurs with provocation testing of the TMJs. When arthralgia is present, the pain is reported to be directly in front of the ear, the lateral pole of the condyle is usually tender to palpation, and the pain is usually constant and increased by jaw movements.

Arthralgia may be a symptom linked to several conditions, such as inflammation of different components of the TMJ (ligaments, retrodiscal tissue, bone, fibrocartilage), and it is often present in arthritis cases. Arthritis is defined as an inflammation or infection associated with edema, erythema, and/or increased temperature over the affected joint, and it includes not only the inflammation of the bone structures but also other TMJ structures such as synovia (synovitis) or capsule (capsulitis), and retrodiscal structures (retrodiscitis). Most inflammatory conditions affecting the joint are secondary to macrotrauma or microtrauma to the tissues within the joint, such as, for example, a bump to the chin (macrotrauma), nail biting (onychophagia), tooth grinding, or tooth clenching (microtrauma) [59, 62]. Furthermore, also internal derangements of the TMJ (disc displacement with or without reduction) may cause arthralgia due to possible inflammation of the retrodiscal tissue [63].

Another possible condition associated with arthralgia is osteoarthritis/osteoarthrosis i.e., the inflammation of the articular surfaces of the joint. It is characterized by the degeneration of the bone tissue of the TMJ, and in severe cases can provoke a malocclusion such as anterior or posterior open bite. Pain is usually unilateral, increases during palpation and during jaw movements, and may be associated with crepitus during auscultation [64].

The management of arthralgia involves elimination of microtrauma, suggestions of a pain-free diet with slow movements during chewing and small bites, prescription of mild analgesics (e.g., non-steroidal anti-inflammatory drugs [NSAIDs], naproxen), physiotherapy, use of minimally invasive therapy (such as arthrocentesis) and use of an occlusal appliance to reduce overload of the joint [61]. Often arthritis may evolve into complete resolution while osteoarthritis may evolve into remodeling of the TMJ [65, 66].

Disc disorders

The TMJ disc disorders include conditions described as intracapsular disorders involving the condyle-disc complex. According to the DC/TMD [5], the four conditions are disc displacement: with reduction, with intermittent locking, without reduction with limited opening, and without reduction without limited opening. The diagnostic validity of all these conditions has been thoroughly tested.

The correct management of disc derangement disorders is based on two factors: making a correct diagnosis and understanding the natural course of the disorder. Disc displacement with reduction and disc displacement with reduction and with intermittent locking are two conditions that may present joint clicking but that should be managed in different ways.

Disc displacement with reduction is a condition that requires treatment only if associated with pain. The prevalence of joint sounds, often accompanying the disc displacement with reduction, is very high in the general population (>25%), but often they are asymptomatic and many do not seek treatment [67, 68]. Moreover, in community samples disc displacement with reduction was found in 26% to 38% of MRIs and was not associated with any sound or symptom [67, 69]. In some cases,

however, disc displacement with reduction may cause pain (arthralgia), mainly due to the load applied to the retrodiscal tissue by the condyle when the disc is dislocated. In this case, treatment is recommended, considering that pain may alter the mandibular function.

In the disc displacement with reduction and with intermittent locking, the disc reduction does not always happen during the opening pattern, but the patient should perform a maneuver, often a lateral jaw movement, to reduce the disc and to open the mouth fully. However, when the dislocation is not reduced the jaw opening is reduced and the treatment should focus on restoring a sufficient jaw opening (>40 mm) and eliminating pain. However, in absence of pain or mandibular opening reduction, the disc displacement with reduction may not require treatment, especially non-reversible treatment.

Reversible therapies include patient education (counseling about disc displacement with reduction), jaw exercises, relaxation techniques [70], stabilization splint, and anterior positioning appliance [71]. The first stage of treatment involves the clinician providing information to the patient about the condition. Self-reports of TMJ clicking are more frequent in care seeking patients that also have greater non-specific physical symptoms, with a propensity to somatization and with heightened awareness of their own body image [72]. Hence, the doctor should explain that this condition is not an evolving condition, that the disc displacement is fluctuating, and that most of the time it disappears without any treatment. Furthermore, the patient should be educated to avoid keeping teeth in touch, excessive joint loading, and self-provoking the click.

Good results in controlling joint pain secondary to joint clicking can also be achieved with a stabilization splint with well-distributed occlusal contacts, which has a lower risk of inducing occlusal changes [73]. Surgical therapy and occlusal therapy, with prosthodontic or orthodontic approaches, are among the non-reversible treatments for disc displacement with reduction. However, the long-term success of the recaptured disc is unpredictable. Indeed, both reversible and non-reversible treatments may result in a high percentage of relapse, around 50%, for joint sound, while arthralgia or locking show a good prognosis with reversible therapies [74].

Disc displacement without reduction with or without limited opening is not associated with joint sounds, but during the clinical examination a reduced mouth opening (< 40 mm), a reduced laterotrusion to the contralateral side, and an uncorrected deviation ipsilateral to the affected side may be present. Patients often report or have a history of click, which suddenly disappears with the reduction of the mouth opening, or a sudden reduction of the opening without history of joint sound.

Depending on the time from the onset of the condition, two different management approaches are possible. In the first week following the dislocation, a reduction of disc position by means of condylar distraction might be attempted, but after this, success with reduction becomes very unlikely and the main treatment goal should be to restore function. Hence, while the patient is in an acute condition the clinician should try to reduce the disc dislocation, but in a chronic condition, when the normal anatomy of the disc is lost, and bone remodeling is present, therapy with exercises, mobilization of the joint, and a stabilization splint to reduce the loading of the retrodiscal tissue allowing a better natural healing of the TMJ should be followed [75]. Restoring jaw function may require time, up to 8 to 12 months or more. Surgical treatments such as arthrocentesis can be considered for the management of pain and dysfunction associated with the condition [76].

OCCLUSAL CHANGES DUE TO TEMPOROMANDIBULAR DISORDERS

TMDs can be also the cause of occlusal changes that might be misdiagnosed and mistreated by clinicians. In some cases, these changes are transient and disappear with TMD treatment, while in other cases the role of the orthodontist is to compensate for the occlusal changes due to the TMJ

alteration with camouflage; in some other cases it is necessary to prepare the patient for orthognathic surgery. It is important for orthodontists to recognize possible causes of transient occlusal changes that should not be treated by irreversible orthodontic treatment, and which occlusal changes should be treated by irreversible therapies.

Joint effusion and unilateral open bite

The most common transitory occlusal change due to TMJ problems is the unilateral open bite due to joint effusion [13]. Joint effusion is defined as collection of fluid in the TMJ space and can be assessed by MRI [77]. Fluid in the joint capsule changes the disc and condyle position within the fossa and the patient feels a different teeth contact that increases on the contralateral canine with deviation of the lower midline and open bite ipsilateral to the affected side. TMJ effusion is not always associated with arthralgia. In this case, it is extremely important to collect an accurate history from the patient, to investigate when this lateral open bite occurred, history of TMD, history of trauma, if the patient perceives a swelling of the area in front of the ear, and if there is pain [78]. The treatment must be focused on the elimination of the effusion using NSAIDS and eventually to liquid aspiration. In a few weeks, the patient should achieve the same intercuspal position as before the acute episode.

TMJ bone alteration and occlusal changes

TMJ inflammation might be the consequence of a generalized systemic inflammatory disease such as rheumatoid arthritis, juvenile idiopathic arthritis (JIA), spondyloarthropathies, or other autoimmune or mixed connective tissue disorders. The role of the dentist or orthodontist is mainly to monitor the possible involvement of the TMJs and their evolution.

The expanded taxonomy of DC/TMD describes criteria for the diagnosis of systemic arthritides, however, sensitivity and specificity for the diagnosis of TMJ involvement for each systemic disease has not been established [79]. Rongo and colleagues assessed the diagnostic performance of the DC/TMD of systemic arthritides for the evaluation of the TMJ involvement in patients with JIA. A low sensitivity (0.15) and high specificity (0.92) were found, which is mainly due to two considerations: 1) crepitus is present only when TMJ damage is severe, 2) joint pain, instead, is seldom reported in JIA [80]. On the other hand, the TMJ is involved in 17 to 87% of children with JIA depending on subtype, diagnostic criteria used, and ethnicity [81–83]. Severe cases of TMJ arthritis can present mandibular asymmetry, when unilateral, or mandibular micrognathia, when bilateral, associated to dental Class II, open bite, and crossbite [84] (Figure 2).

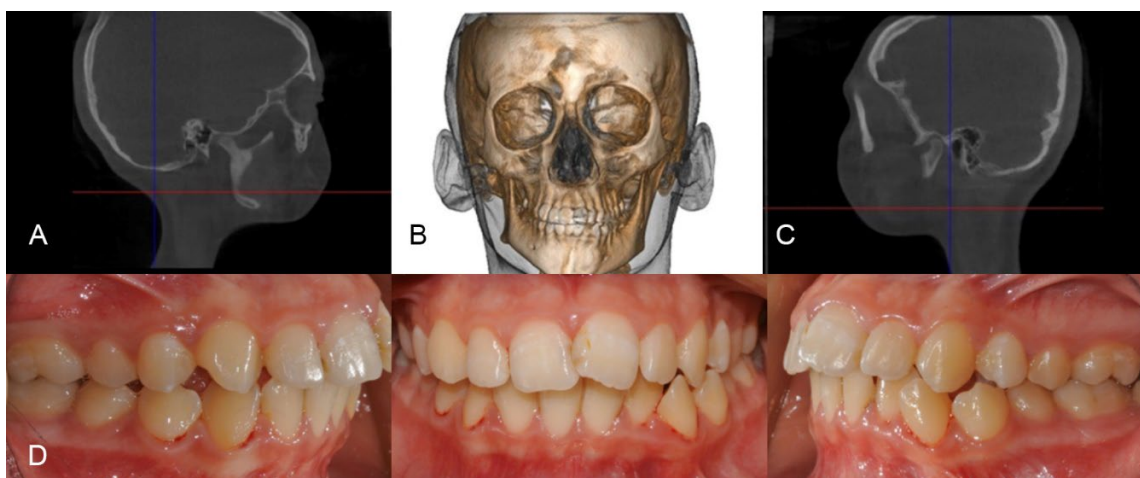


Figure 2. Occlusal changes due to Juvenile Idiopathic Arthritis: A) Right TMJ with osteoarthrosis, B) 3D reconstruction to highlight jaw asymmetry and occlusal canting, C) Left TMJ Healthy, D) Occlusal pictures, class II on the right side, deviation of the lower midline.

Furthermore, signs of mandibular dysfunction can be reported such as deviation on mouth opening, reduced mouth opening, arthralgia, and myalgia [85]. Clinicians should be aware that early identification of TMJ involvement is important. Stoustrup and colleagues developed a three-minute screening protocol useful for both clinical and research settings [86].

Management of TMJ arthritis aims to reduce inflammation, reduce orofacial signs and symptoms, correct or control growth disturbances, and treat possible malocclusion. Orthodontists may play a role in all of these aspects. The main treatment in these patients is the systemic treatment that with time has evolved from the use of methotrexate to the use of biologic drugs. In addition to this systemic treatment, there is evidence supporting the use of a stabilization splint to reduce the orofacial symptoms or the use of functional appliances such as the distraction splint to control or correct growth disturbances [87, 88].

Finally, orthognathic interventions can be performed in these patients to treat growth disturbances, such as orthognathic surgery in skeletally mature patients, distraction osteogenesis in growing patients, and alloplastic TMJ reconstruction in extremely severe cases. Resnick et al. proposed an algorithm based on ongoing active disease, skeletal maturity, and degree of facial deformity. This aims to aid clinicians in the treatment planning pathway and to provide a more standardized approach to surgically managing dentofacial deformity in JIA [89, 90].

It must be considered that TMJ arthritis management is based on a multidisciplinary approach where, together with the rheumatologist, other specialists are involved such as radiologists, physiotherapists, psychologists, and orthodontists. This can contribute to avoiding important sequelae due to JIA involvement of TMJs.

CONCLUSIONS

TMDs should be assessed by the orthodontist before, during, and after the orthodontic treatment. There is no convincing evidence supporting the concept that TMDs are causally related to occlusion, the condylar position, or orthodontic treatment, but their etiology is linked to the biopsychosocial model. TMJ arthralgia and disc disorders presented a high incidence in adolescents and young adults and should be treated with reversible therapies. TMJ effusion may cause transient occlusal changes, which must not be treated before the effusion disappears. Other TMJ alterations due to systemic arthritis may cause major occlusal changes that require multidisciplinary management.

ACKNOWLEDGEMENTS

All authors equally contributed to this chapter.

REFERENCES

1. Chanthavisouk P, John MT, Paulson D, Pattanaik S. Commonalities among dental patient-reported outcomes (dPROs)-A Delphi consensus study. *PLoS One* 2022;17(6):e0268750.
2. John MT. Foundations of oral health-related quality of life. *J Oral Rehabil*. 2020. <https://doi.org/10.1111/JOOR.13040>. Online ahead of print.
3. Häggman-Henrikson B, Lobbezoo F, Durham J, Peck C, List T. The voice of the patient in orofacial pain management. *J Evid Based Dent Pract* 2022; 22(1S):101648.
4. Michelotti A, Iodice G. The role of orthodontics in temporomandibular disorders. *J Oral Rehabil* 2010;37(6):411-429.

5. Schiffman E, Ohrbach R, Truelove E, Look J, Anderson G, Goulet JP, et al. Diagnostic Criteria for Temporomandibular Disorders (DC/TMD) for clinical and research applications: Recommendations of the International RDC/TMD Consortium Network and Orofacial Pain Special Interest Group. *J Oral Facial Pain Headache*. 2014;28(1):6–27.
6. Christidis N, Lindström Ndanshau E, Sandberg A, Tsilingaridis G. Prevalence and treatment strategies regarding temporomandibular disorders in children and adolescents-A systematic review. *J Oral Rehabil* 2019;46(3):291–301.
7. Lovgren A, Haggman-Henrikson B, Visscher CM, Lobbezoo F, Marklund S, Wanman A. Temporomandibular pain and jaw dysfunction at different ages covering the lifespan--a population based study. *Eur J Pain* 2016;20(4):532–40.
8. Manfredini D, Favero L, Gregorini G, Cocilovo F, Guarda-Nardini L. Natural course of temporomandibular disorders with low pain-related impairment: a 2-to-3-year follow-up study. *J Oral Rehabil* 2013;40(6):436–442.
9. Sabsoob O, Elsaraj SM, Gornitsky M, Laszlo E, Friction JR, Schiffman EL, et al. Acute and chronic temporomandibular disorder pain: a critical review of differentiating factors and predictors of acute to chronic pain transition. *J Oral Rehabil* 2022;49(3):362-372.
10. Ohrbach R, Fillingim RB, Mulkey F, Gonzalez Y, Gordon S, Gremillion H, et al. Clinical findings and pain symptoms as potential risk factors for chronic TMD: descriptive data and empirically identified domains from the OPPERA case-control study. *J Pain* 2011;12 (11 Suppl):T27–T45.
11. Kleykamp BA, Ferguson MC, McNicol E, Bixho I, Arnold LM, Edwards RR, et al. The prevalence of comorbid chronic pain conditions among patients with temporomandibular disorders: a systematic review. *J Am Dent Assoc* 2022;153(3):241-250.e10.
12. Sanders AE, Slade GD, Bair E, Fillingim RB, Knott C, Dubner R, et al. General health status and incidence of first-onset temporomandibular disorder: the OPPERA prospective cohort study. *J Pain* 2013;14 (12 Suppl):T51–T62.
13. Caldas W, Conti AC de CF, Janson G, Conti PCR. Occlusal changes secondary to temporomandibular joint conditions: a critical review and implications for clinical practice. *J Appl Oral Sci* 2016;24(4):411–419.
14. Owen AH 3rd. Unexpected TMJ responses to functional jaw orthopedic therapy. *Am J Orthod Dentofacial Orthop* 1988;94(4):338–349.
15. Al-Moraissi EA, Wolford LM, Perez D, Laskin DM, Ellis E 3rd. Does orthognathic surgery cause or cure temporomandibular disorders? A systematic review and meta-analysis. *J Oral Maxillofac Surg* 2017;75(9):1835–1847.
16. Schimmel M, Aarab G, Baad-Hansen L, Lobbezoo F, Svensson P. A conceptual model of oro-facial health with an emphasis on function. *J Oral Rehabil* 2021;48(11):1283–1294.
17. Bair E, Ohrbach R, Fillingim RB, Greenspan JD, Dubner R, Diatchenko L, et al. Multivariable modeling of phenotypic risk factors for first-onset TMD: The OPPERA prospective cohort study. *J Pain* 2013;14 (12 Suppl):T102-T115.
18. Michelotti A, Liguori R, Toriello M, D’Antò V, Vitale D, Castaldo G, et al. Catechol-O-methyltransferase (COMT) gene polymorphisms as risk factor in temporomandibular disorders patients from Southern Italy. *Clin J Pain* 2014;30(2):129–133.
19. Sharma S, Wactawski-Wende J, LaMonte MJ, Zhao J, Slade GD, Bair E, et al. Incident injury is strongly associated with subsequent incident temporomandibular disorder: results from the OPPERA study. *Pain* 2019;160(7):1551–1561.
20. Kandasamy S, Rinchuse DJ, Greene CS, Johnston LE Jr. Temporomandibular disorders and orthodontics: What have we learned from 1992-2022? *Am J Orthod Dentofacial Orthop* 2022;161(6):769–774.
21. de Kanter RJAM, Battistuzzi PGFCM, Truin G-J. Temporomandibular disorders: “occlusion” matters! *Pain Res Manag* 2018;2018:8746858.
22. Roth RH. Temporomandibular pain-dysfunction and occlusal relationships. *Angle Orthod* 1973;43(2):136–153.

23. Greene CS, Obrez A. Treating temporomandibular disorders with permanent mandibular repositioning: is it medically necessary? *Oral Surg Oral Med Oral Pathol Oral Radiol* 2015;119(5):489–498.
24. Kandasamy S, Greene CS, Obrez A. An evidence-based evaluation of the concept of centric relation in the 21st century. *Quintessence Int* 2018;49(9):755–760.
25. Kandasamy S, Boeddinghaus R, Kruger E. Condylar position assessed by magnetic resonance imaging after various bite position registrations. *Am J Orthod Dentofacial Orthop* 2013;144(4):512–517.
26. Zonnenberg AJJ, Türp JC, Greene CS. Centric relation critically revisited—What are the clinical implications? *J Oral Rehabil* 2021;48(9):1050–1055.
27. Türp JC, Schlenker A, Schröder J, Essig M, Schmitter M. Disk displacement, eccentric condylar position, osteoarthritis – misnomers for variations of normality? Results and interpretations from an MRI study in two age cohorts. *BMC Oral Health* 2016;16(1):124.
28. Paknahad M, Shahidi S, Iranpour S, Mirhadi S, Paknahad M. Cone-beam computed tomographic assessment of mandibular condylar position in patients with temporomandibular joint dysfunction and in healthy subjects. *Int J Dent* 2015;2015:301796.
29. Bonilla-Aragon H, Tallents RH, Katzberg RW, Kyrkanides S, Moss ME. Condyle position as a predictor of temporomandibular joint internal derangement. *J Prosthet Dent* 1999;82(2):205–208.
30. Rinchuse DJ, Kandasamy S. Centric relation: A historical and contemporary orthodontic perspective. *J Am Dent Assoc* 2006;137(4):494–501.
31. Kircos LT, Ortendahl DA, Mark AS, Arakawa M. Magnetic resonance imaging of the TMJ disc in asymptomatic volunteers. *J Oral Maxillofac Surg* 1987;45(10):852–854.
32. Bean LR, Thomas CA. Significance of condylar positions in patients with temporomandibular disorders. *J Am Dent Assoc* 1987;114(1):76–77.
33. Türp JC, Schlenker A, Schröder J, Essig M, Schmitter M. Disk displacement, eccentric condylar position, osteoarthritis - misnomers for variations of normality? Results and interpretations from an MRI study in two age cohorts. *BMC Oral Health* 2016;16(1):124.
34. Pullinger A. Establishing better biological models to understand occlusion. I: TM joint anatomic relationships. *J Oral Rehabil* 2013;40(4):296–318.
35. Greene CS. “The Ball on the Hill”: A new perspective on TMJ functional anatomy. *Orthod Craniofac Res* 2018;21(4):170–174.
36. Manfredini D, Lombardo L, Siciliani G. Temporomandibular disorders and dental occlusion. A systematic review of association studies: end of an era? *J Oral Rehabil* 2017;44(11):908–923.
37. Lai YC, Yap AU, Türp JC. Prevalence of temporomandibular disorders in patients seeking orthodontic treatment: a systematic review. *J Oral Rehabil* 2020;47(2):270–280.
38. John MT, Hirsch C, Drangsholt MT, Mancl LA, Setz JM. Overbite and overjet are not related to self-report of temporomandibular disorder symptoms. *J Dent Res* 2002;81(3):164–169.
39. Hirsch C, John MT, Drangsholt MT, Mancl LA. Relationship between overbite/overjet and clicking or crepitus of the temporomandibular joint. *J Orofac Pain* 2005;19(3):218–225.
40. Iodice G, Cimino R, Vollaro S, Lobbezoo F, Michelotti A. Prevalence of temporomandibular disorder pain, jaw noises and oral behaviours in an adult Italian population sample. *J Oral Rehabil* 2019;46(8):691–698.
41. Olliver SJ, Broadbent JM, Thomson WM, Farella M. Occlusal features and TMJ clicking: a 30-year evaluation from a cohort study. *J Dent Res*. 2020;99(11):1245-1251.
42. Amer NM, Aboalnaga AA, Salah Fayed MM, Labib AH. Transverse malocclusion and temporomandibular disorders: verification of the controversy. *J Oral Facial Pain Headache* 2019;33(4):355–361.
43. Aboalnaga AA, Amer NM, Elnahas MO, Salah Fayed MM, Soliman SA, ElDakrouy AE, et al. Malocclusion and temporomandibular disorders: verification of the controversy. *J Oral Facial Pain Headache* 2019;33(4):440–450.

44. Velly AM, Schiffman EL, Rindal DB, Cunha-Cruz J, Gilbert GH, Lehmann M, et al. The feasibility of a clinical trial of pain related to temporomandibular muscle and joint disorders: the results of a survey from the Collaboration on Networked Dental and Oral Research dental practice-based research networks. *J Am Dent Assoc* 2013;144(1):e1-10.
45. Kakudate N, Yokoyama Y, Sumida F, Matsumoto Y, Gordan V V, Gilbert GH, et al. Dentist practice patterns and therapeutic confidence in the treatment of pain related to temporomandibular disorders in a dental practice-based research network. *J Oral Facial Pain Headache* 2017;31(2):152–158.
46. Tegelberg A, Wenneberg B, List T. General practice dentists' knowledge of temporomandibular disorders in children and adolescents. *Eur J Dent Educ* 2007;11(4):216–221.
47. Michelotti A, Iodice G. The role of orthodontics in temporomandibular disorders. *J Oral Rehabil* 2010;37(6):411–429.
48. McNamara JAJ, Seligman DA, Okeson JP. Occlusion, Orthodontic treatment, and temporomandibular disorders: a review. *J Orofac Pain* 1995;9(1):73–90.
49. Kandasamy S, Greene CS, Rinchuse DJ, Stockstill JW. *TMD and Orthodontics: A Clinical Guide for the Orthodontist*. Switzerland: Springer Cham; 2015.
50. Bucci R, Rongo R, Levate C, Michelotti A, Barone S, Razionale AV, et al. Thickness of orthodontic clear aligners after thermoforming and after 10 days of intraoral exposure: a prospective clinical study. *Prog Orthod* 2019;20(1):36.
51. Macedo CR, Silva AB, Machado MA, Saconato H, Prado GF. Occlusal splints for treating sleep bruxism (tooth grinding). *Cochrane Database Syst Rev* 2007;2007(4):CD005514.
52. Tran J, Lou T, Nebiolo B, Castroflorio T, Tassi A, Cioffi I. Impact of clear aligner therapy on tooth pain and masticatory muscle soreness. *J Oral Rehabil* 2020;47(12):1521–1529.
53. Lou T, Tran J, Castroflorio T, Tassi A, Cioffi I. Evaluation of masticatory muscle response to clear aligner therapy using ambulatory electromyographic recording. *Am J Orthod Dentofacial Orthop* 2021;159(1):e25–e33.
54. Castroflorio T, Bargellini A, Lucchese A, Manuelli M, Casasco F, Cugliari G, et al. Effects of clear aligners on sleep bruxism: randomized controlled trial. *J Biol Regul Homeost Agents* 2018;32(2 Suppl. 2):21–29.
55. Svensson P, Graven-Nielsen T. Craniofacial muscle pain: review of mechanisms and clinical manifestations. *J Orofac Pain* 2001;15(2):117–145.
56. Greene CS, Galang-Boquiren MTS, Bartilotta BY. Orthodontics and the temporomandibular joint: What orthodontic providers need to know. *Quintessence Int* 2017;48(10):799–808.
57. Suvinen TI, Reade PC, Kemppainen P, Könönen M, Dworkin SF. Review of aetiological concepts of temporomandibular pain disorders: Towards a biopsychosocial model for integration of physical disorder factors with psychological and psychosocial illness impact factors. *Eur J Pain* 2005;9(6):613–633.
58. Sharma S, Breckons M, Brönnimann Lambelet B, Chung JW, List T, Lobbezoo F, et al. Challenges in the clinical implementation of a biopsychosocial model for assessment and management of orofacial pain. *J Oral Rehabil* 2020;47(1):87–100.
59. Slade GD, Ohrbach R, Greenspan JD, Fillingim RB, Bair E, Sanders AE, et al. Painful Temporomandibular Disorder: Decade of Discovery from OPPERA Studies. *J Dent Res* 2016;95(10):1084–1092.
60. Al-Moraissi EA, Conti PCR, Alyahya A, Alkebsi K, Elsharkawy A, Christidis N. The hierarchy of different treatments for myogenous temporomandibular disorders: a systematic review and network meta-analysis of randomized clinical trials. *Oral Maxillofac Surg* 2022;26(4):519-533.
61. Al-Moraissi EA, Wolford LM, Ellis E, Neff A. The hierarchy of different treatments for arthrogenous temporomandibular disorders: A network meta-analysis of randomized clinical trials. *J Craniomaxillofac Surg* 2020;48(1):9–23.

62. Sierwald I, John MT, Schierz O, Hirsch C, Sagheri D, Jost-Brinkmann PG, et al. Association of temporomandibular disorder pain with awake and sleep bruxism in adults. *J Orofac Orthop* 2015;76(4):305–317.
63. Naeije M, te Veldhuis AH, te Veldhuis EC, Visscher CM, Lobbezoo F. Disc displacement within the human temporomandibular joint: a systematic review of a “noisy annoyance.” *J Oral Rehabil* 2013;40(2):139–58.
64. Alstergren P, Pigg M, Kopp S. Clinical diagnosis of temporomandibular joint arthritis. *J Oral Rehabil* 2018;45(4):269–81.
65. Rasmussen OC. Clinical findings during the course of temporomandibular arthropathy. *Scand J Dent Res* 1981;89(3):283–288.
66. Han K, Kim MC, Kim YJ, Song Y, Tae I, Ryu JJ, et al. A long-term longitudinal study of the osteoarthritic changes to the temporomandibular joint evaluated using a novel three-dimensional superimposition method. *Sci Rep* 2021;11(1):9389.
67. Talaat WM, Adel OI, Al Bayatti S. Prevalence of temporomandibular disorders discovered incidentally during routine dental examination using the Research Diagnostic Criteria for Temporomandibular Disorders. *Oral Surg Oral Med Oral Pathol Oral Radiol* 2018;125(3):250–259.
68. Jussila P, Kiviahde H, Näpänkangas R, Pääkkilä J, Pesonen P, Sipilä K, et al. Prevalence of temporomandibular disorders in the Northern Finland Birth Cohort 1966. *J Oral Facial Pain Headache* 2017;31(2):159–164.
69. Tasaki MM, Westesson PL, Isberg AM, Ren YF, Tallents RH. Classification and prevalence of temporomandibular joint disk displacement in patients and symptom-free volunteers. *Am J Orthod Dentofacial Orthop* 1996;109(3):249–262.
70. Yoda T, Sakamoto I, Imai H, Honma Y, Shinjo Y, Takano A, et al. A randomized controlled trial of therapeutic exercise for clicking due to disk anterior displacement with reduction in the temporomandibular joint. *Cranio* 2003;21(1):10–16.
71. Poluha RL, De La Torre Canales G, Costa YM, Grossmann E, Bonjardim LR, Conti PCR. Temporomandibular joint disc displacement with reduction: a review of mechanisms and clinical presentation. *J Appl Oral Sci* 2019;27:e20180433.
72. Ukra A, Foster Page LA, Thomson WM, Knight RG, Farella M. Self-report of temporomandibular joint clicking and psychological factors: is there an association? *J Oral Rehabil* 2017;44(7):511–516.
73. Conti PCR, Dos Santos CN, Kogawa EM, Conti ACDCF, De Araujo CDRP. The treatment of painful temporomandibular joint clicking with oral splints: a randomized clinical trial. *J Am Dent Assoc* 2006;137(8):1108–1114.
74. Okeson JP. Management of temporomandibular disorders and occlusion. 7th edition. St. Louis, MO: Mosby; 2013.
75. La Touche R, Boo-Mallo T, Zarzosa-Rodríguez J, Paris-Aleman A, Cuenca-Martínez F, Suso-Martí L. Manual therapy and exercise in temporomandibular joint disc displacement without reduction. A systematic review. *Cranio*. 2022;40(5):440-450.
76. Tatli U, Benlidayi ME, Ekren O, Salimov F. Comparison of the effectiveness of three different treatment methods for temporomandibular joint disc displacement without reduction. *Int J Oral Maxillofac Surg* 2017;46(5):603–609.
77. Khawaja SN, Crow H, Mahmoud RFG, Kartha K, Gonzalez Y. Is there an association between temporomandibular joint effusion and arthralgia? *J Oral Maxillofac Surg* 2017;75(2):268–275.
78. Marinho LH, McLoughlin PM. Lateral open bite resulting from acute temporomandibular joint effusion. *Br J Oral Maxillofac Surg* 1994;32(2):127–128.
79. Peck CC, Goulet JP, Lobbezoo F, Schiffman EL, Alstergren P, Anderson GC, et al. Expanding the taxonomy of the diagnostic criteria for temporomandibular disorders. *J Oral Rehabil* 2014;41(1):2–23.

80. Rongo R, Alstergren P, Ammendola L, Bucci R, Alessio M, D'Anto V, et al. Temporomandibular joint damage in juvenile idiopathic arthritis: diagnostic validity of diagnostic criteria for temporomandibular disorders. *J Oral Rehabil* 2019;46(5):450–459.
81. Ringold S, Cron RQ. The temporomandibular joint in juvenile idiopathic arthritis: frequently used and frequently arthritic. *Pediatr Rheumatol Online J* 2009;7:11.
82. Twilt M, Schulten AJM, Nicolaas P, Dülger A, Van Suijlekom-Smit LWA. Facioskeletal changes in children with juvenile idiopathic arthritis. *Ann Rheum Dis* 2006;65(6):823–825.
83. Twilt M, Arends LR, Cate R Ten, Van Suijlekom-Smit LWA. Incidence of temporomandibular involvement in juvenile idiopathic arthritis. *Scand J Rheumatol* 2007;36(3):184–188.
84. Billiau AD, Hu Y, Verdonck A, Carels C, Wouters C. Temporomandibular joint arthritis in juvenile idiopathic arthritis: prevalence, clinical and radiological signs, and relation to dentofacial morphology. *J Rheumatol* 2007;34(9):1925–1933.
85. Stoustrup P, Kristensen KD, Verna C, Küseler A, Herlin T, Pedersen TK. Orofacial symptoms related to temporomandibular joint arthritis in juvenile idiopathic arthritis: Smallest detectable difference in self-reported pain intensity. *J Rheumatol* 2012;39(12):2352–2358.
86. Stoustrup P, Herlin T, Spiegel L, Rahimi H, Koos B, Pedersen TK, et al. Standardizing the clinical orofacial examination in juvenile idiopathic arthritis: An interdisciplinary, consensus-based, short screening protocol. *J Rheumatol* 2020;47(9):1397–1404.
87. Stoustrup P, Kristensen KD, Küseler A, Verna C, Herlin T, Pedersen TK. Management of temporomandibular joint arthritis-related orofacial symptoms in juvenile idiopathic arthritis by the use of a stabilization splint. *Scand J Rheumatol* 2014;43(2):137–145.
88. Pedersen TK, Carlalberta V. Functional and orthopedic treatment in developing dentofacial growth deviation in juvenile idiopathic arthritis. *Semin Orthod* 2015;21(2):134–139.
89. Stoustrup P, Pedersen TK, Nørholt SE, Resnick CM, Abramowicz S. Interdisciplinary management of dentofacial deformity in juvenile idiopathic arthritis. *Oral Maxillofac Surg Clin North Am* 2020;32(1):117–134.
90. Resnick CM, Frid P, Norholt SE, Stoustrup P, Peacock ZS, Kaban LB, et al. An algorithm for management of dentofacial deformity resulting from juvenile idiopathic arthritis: results of a multinational consensus conference. *J Oral Maxillofac Surg* 2019;77(6):1152.e1-1152.e33.

ORTHOGNATHIC SURGERY-ASSOCIATED CONDYLAR DISPLACEMENT AND CHANGE IN CONTACT MECHANICS

Juliana Batista Melo da Fonte, Laura R. Iwasaki, Saulo Sousa Melo, Deborah Queiroz Freitas, Jeffrey C. Nickel

ABSTRACT

Introduction: This study tested for changes in temporomandibular joint (TMJ) compressive stresses due to proximal segment displacement following mandibular orthognathic surgery. **Methods:** In accordance with university institutional review board oversight, pre-surgical and post-surgical cone beam computed tomography images were collected. Software (Amira, Anatomage InVivoDental) was used to perform three-dimensional reconstruction of right and left TMJs. Minimum articular distances between the condyle and temporal bone were measured from pre-surgery and post-surgery reconstructions. Changes in compressive stresses were performed using an empirical equation derived from laboratory tests of the effect of TMJ disc thickness on peak compressive stress for a 9 Newtons (N) load. Student's t-tests were used to determine if there were pre-surgical to post-surgical changes in peak compressive stresses. **Results:** Twenty-seven females and fourteen males provided complete records. Fifty-six TMJs had mandibular proximal segment displacement post-surgery, resulting in an average reduction of minimum articular distances of -0.7 (range -0.1 to -2.1) mm. Twenty-two TMJs had either no change, or an average increase of the minimum articular distance of 0.7 (range 0 to 2.9) mm post-surgery. Average pre-surgical peak compressive stress of 0.18 (± 0.01) MPa increased to 0.27 (± 0.02) MPa following surgery, which was statistically significantly larger ($p < 0.001$). In TMJs where the inter-articular distance decreased, pre-surgical to post-surgical peak compressive stresses increased by approximately 0.15 MPa, whereas in TMJs where the inter-articular distance increased, pre-surgical to post-surgical peak compressive stresses decreased by approximately 0.07 MPa. **Conclusions:** Displacement of the mandibular proximal segment following orthognathic surgery of the mandible resulted in changes in peak compressive stresses.

KEY WORDS: Orthognathic Surgery, Compressive Stress, CBCT, Temporomandibular Joint.

INTRODUCTION

Orthognathic surgery is widely used to correct maxillofacial discrepancies. These surgical procedures can improve oral function, reduce the apnea/hypopnea index in cases of sleep apnea, and enhance facial appearance and psychosocial well-being [1-5]. In the United States, maxillofacial discrepancies affect 5% of the population and approximately 10,000 orthognathic surgeries are performed annually [6]. A common complication following orthognathic surgery of the mandible is loss of structural integrity of the mandibular condyles [7].

Morphological changes in the condyles after orthognathic surgery may be a natural adaptive process with little biological consequence. However, pathological remodeling occurs if the adaptive capacity of the temporomandibular joint (TMJ) cartilages is exceeded [8]. The extent and impact of morphological changes on TMJ functional characteristics remain controversial [1]. Recently published longitudinal data

have shown that more than half of patients lose 40% of mandibular advancement due to loss of condylar structure [7]. Post-surgical resorption of the mandibular condyle, like that of degenerative TMJ disease, has been considered to result from the increased mechanical demands placed on the TMJ articular surfaces, especially when the change in load exceeds the accommodation capacity of the joint [8-10]. However, to date the pathoetiology of post-surgical loss of condylar structure has not been fully established.

Cone beam computed tomography (CBCT) enables the evaluation and quantitative analysis of degenerative changes in the osseous structures of the TMJ [8-11]. Orthognathic surgical movements, and positional and morphological changes of the mandibular condyles can be accurately evaluated by this imaging modality [7, 9, 12]. Imaging software facilitates the measurement of mandibular condyle volume through three-dimensional (3D) segmentation, and therefore can be applied to compare these volumes in the pre-surgery and post-orthognathic surgery periods [13, 14].

Orthognathic surgery has the potential to change the congruency (shape-matching) between TMJ articulating surfaces [15]. Few studies have focused on the effects of orthognathic surgery on 2D and 3D TMJ loads and stresses [16-18]. The aim of the current study was to test whether or not displacement of the mandibular proximal segment after orthognathic surgery of the mandible resulted in changes in peak compressive TMJ stresses. We tested the null hypothesis that there were no significant differences between pre-surgical and post-surgical peak compressive stresses.

MATERIALS AND METHODS

This retrospective study was conducted under the supervision of the Oregon Health & Science University Institutional Review Board and used case records of individuals who underwent orthognathic surgery of the mandible at a private oral surgery center. All individuals consented to their records being used for research purposes. Subjects were required to be 15 years of age or older at the time of the pre-surgical records and to have CBCT images of the head and jaws before and after surgery. Exclusion criteria included evidence of degenerative TMJ joint disease, syndromic craniofacial deformities, or planned TMJ prostheses or replacement procedures.

Data from CBCT images

All CBCT scans were performed on the same unit, with a voxel size of 0.3 mm and field of view of 160 x 160 x 80 mm. CBCT pre-surgical and post-surgical images were taken with subjects in maximum intercuspation, and were within one month prior to surgery and within one month following surgery. The CBCT image datasets from two time points for each subject were de-identified and coded in pairs to compare before and after orthognathic surgery of the same individual. CBCT software programs (AMIRA, Thermo Scientific, Waltham, MA; InVivoDental, Anatomage, Santa Clara, CA) were used for reconstruction, orientation, and analysis. TMJ images were oriented in a parasagittal view in order to measure the shortest distance between the condylar surface and the temporal bone on each side of the TMJs pre-surgery and post-orthognathic surgery (Figure 1). All measurements were performed by a trained oral and maxillofacial radiologist with more than five years of experience with CBCT scans and measurements.

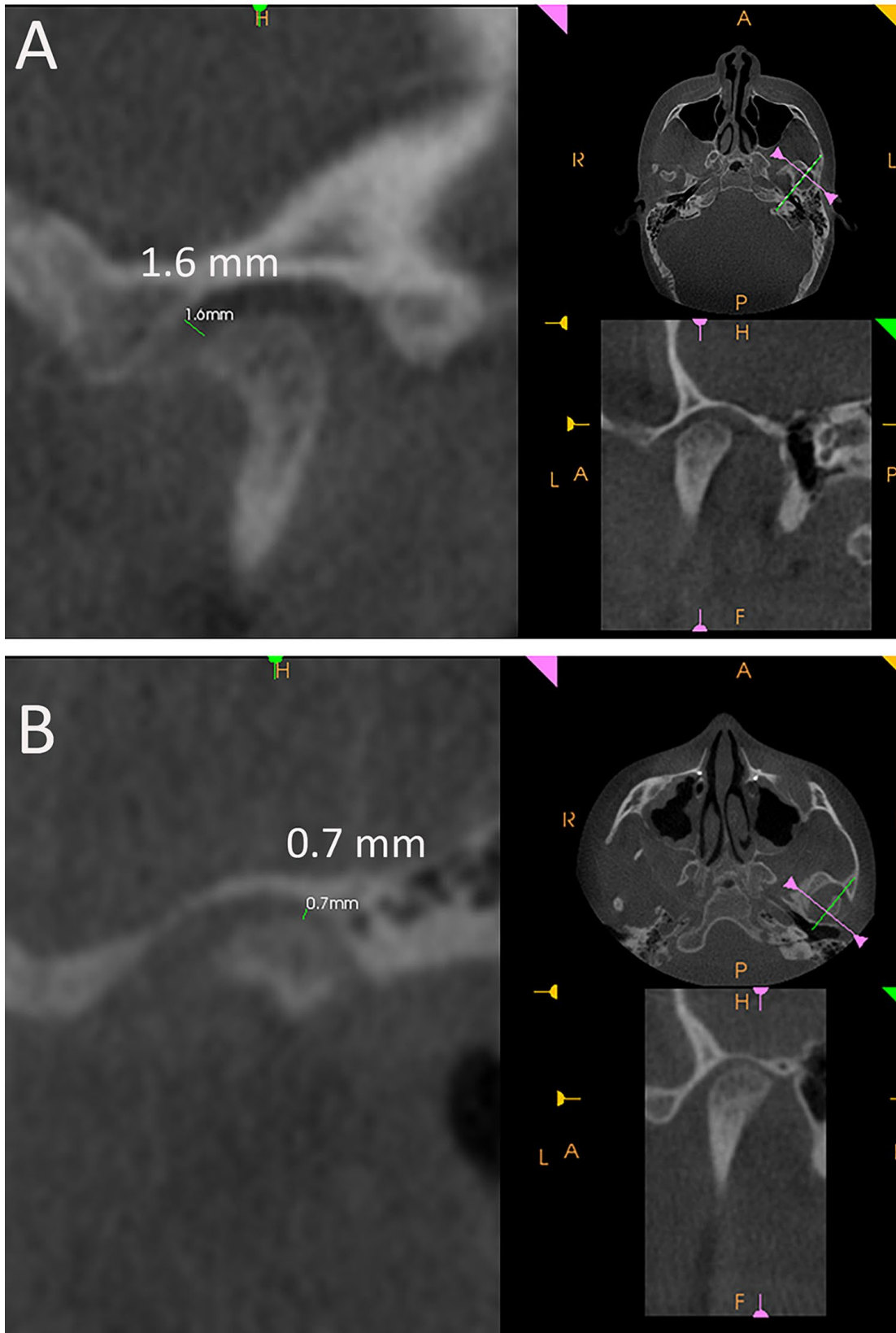


Figure 1. Parasagittal view of left TMJ of a subject. A) Pre-surgery minimum articular distance between condyles and temporal bones of 1.6 mm, B) Post-orthognathic surgery minimum articular distance of 0.7 mm.

Calculations of peak compressive stresses

To calculate pre-surgical and post-surgical peak compressive stresses, the following empirical equation was used:

$$y = -0.0217x^3 + 0.1820x^2 - 0.5097x + 0.5351$$

This equation was derived from laboratory data, which tested the effect of TMJ disc thickness on peak compressive stress in response to a 9 N load [19].

Data and statistical analyses

Student's t-tests were used to determine if there were pre-surgical to post-surgical changes in peak compressive stresses using commercial software (Excel Version 16.72, Microsoft Office, Redmond, WA).

RESULTS

CBCT imaging files from 27 females and 14 males were used to calculate inter-articular distances before and after orthognathic surgery of the mandible. CBCT image quality was sufficient for measurement of inter-articular distances in 78 TMJs. Fifty-six TMJs had mandibular proximal segment displacement post-surgery, resulting in an average reduction of minimum articular distances of -0.7 mm (range -0.1 to -2.1 mm). Twenty-two TMJs had either no change in minimum distance (n = 5) or an average increase of 0.7 mm (range 0 to 2.9 mm, n = 17) post-surgery. Average pre-surgical peak compressive stress of 0.18 (standard error ± 0.01) megapascals (MPa) increased to 0.27 (± 0.02) MPa following surgery, which was statistically significantly larger (p < 0.001, Figure 2). In the 56 TMJs where the inter-articular distance decreased, pre-surgical to post-surgical peak compressive stresses increased by an average of 0.15 MPa, whereas in 22 TMJs where the inter-articular distance increased, pre-surgical to post-surgical peak TMJ compressive stresses decreased by an average of 0.07 MPa (Figure 3).

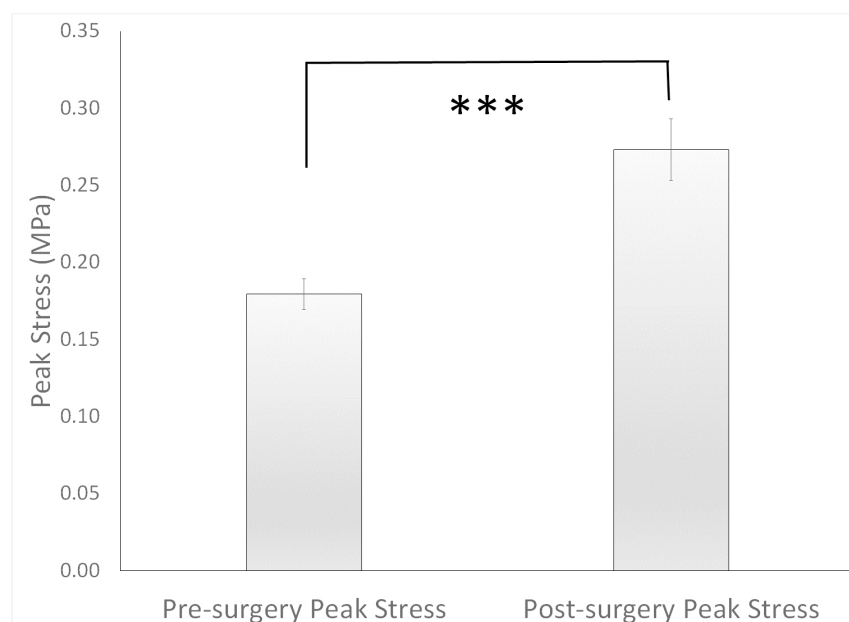


Figure 2. Average peak compressive stresses in response to a 9 N TMJ load. Pre-surgery to post-surgery stresses increased due to decreased average inter-articular surface distance. *** p < 0.0001

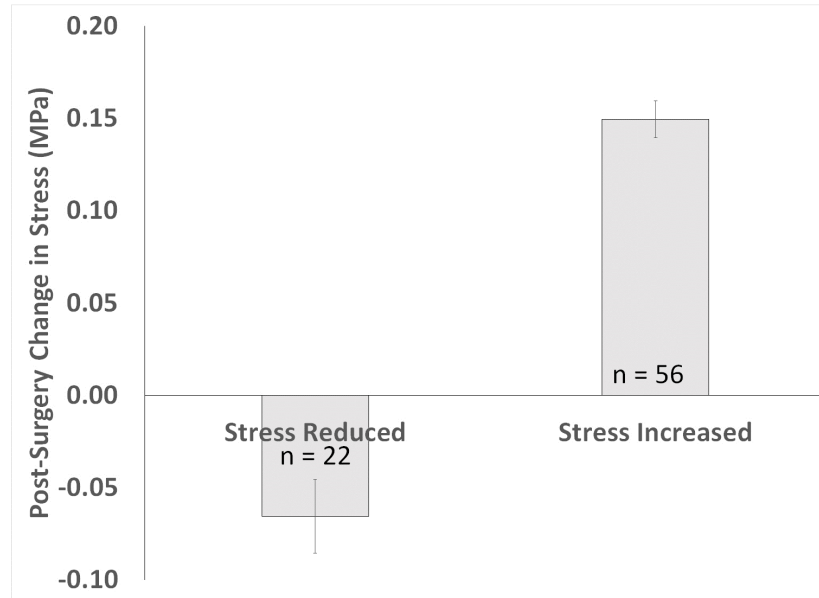


Figure 3. Change in peak TMJ stress where the intra-articular distances increased (decreased stress) and decreased (increased stress). Twenty-two TMJs had post-surgical increases in the minimum articular distance, which resulted in an average decrease in mean peak stress of 0.07 (Std. Error \pm 0.02) MPa. Average post-surgical peak stresses increased by 0.15 MPa (\pm 0.01) in 56 TMJs.

DISCUSSION

Post-surgical condylar resorption, like that of degenerative joint disease of the TMJ, has been thought to be the result of increased mechanical demands imposed on the articulating surfaces. Reported incidences of condylar resorption following surgery range from 1% to 30% [20-22], with increased risk associated with the pre-operative size of the mandibular condyles, amount of anterior movement of the mandible, and steepness of the mandibular plane angle [21, 23-26]. Systematic reviews [21-23, 27] point to the increased risk of post-surgery condylar resorption in young women with retrognathic mandibles and high mandibular plane angles. The current data provide additional information concerning how small changes in the post-surgical position of the mandibular condyle can potentially result in significant changes in compressive stresses within the TMJ.

The results of the current research point to the need for improved control of condylar positioning during orthognathic surgery of the mandible. However, the data have limited generalizability because of a number of limitations, including that a static mechanics approach and common 9 N load were used to calculate peak compressive stresses. Additionally, inter-participant variation in the geometry of the TMJ stress-field during jaw functions was not considered, and likely has a significant effect on compressive stresses. Notably, mechanical fatigue of articular cartilages depends on individual-specific magnitudes and frequencies of energy input to tissues during jaw-use behaviors, which can be measured via TMJ energy densities and jaw muscle duty factors, respectively [28]. Therefore, future prospective studies should include pre-surgical and post-surgical estimates of participant-specific TMJ energy densities and jaw muscle duty factors to test if these measurements predict post-surgical longitudinal changes in TMJ structures. If validated as successful biomarkers for longitudinal changes in TMJ structures, these measurements can be used to develop improved surgical techniques to prevent post-surgical condylar resorption.

CONCLUSIONS

Displacement of the mandibular proximal segment following orthognathic surgery of the mandible resulted in changes in calculated peak compressive stresses. Peak stresses more commonly increased due to a decrease in the minimum inter-articular distance between loading surfaces post-surgery.

ACKNOWLEDGEMENTS

This study was supported in part by the Coordenação de Aperfeiçoamento de Pessoal de Nível Superior – Brasil (CAPES) – Finance Code 001. Dr. Madelyn Stumpus collected the CBCT image data, which were also used in the partial fulfillment of a Master of Science degree.

REFERENCES

1. Hunt OT, Johnston CD, Hepper PG, Burden DJ. The psychosocial impact of orthognathic surgery: a systematic review. *Am J Orthod Dentofacial Orthop* 2001; 120(5):490-497.
2. Pahkala RH, Kellokoski JK. Surgical-orthodontic treatment and patients' functional and psychosocial well-being. *Am J Orthod Dentofacial Orthop* 2007; 132(2):158-164.
3. Togninalli D, Antonarakis GS, Schatz JP. Condylar resorption following mandibular advancement or bimaxillary osteotomies: A systematic review of systematic reviews. *J Stomatol Oral Maxillofac Surg* 2022; 123(6):e948-e955.
4. Yu Z, Cheng JX, Zhang D, Yi F, Ji Q. Association between obstructive sleep apnea and type 2 diabetes mellitus: a dose-response meta-analysis. *Evid Based Complement Alternat Med* 2021; 1337118.
5. Zaghi S, Holty JE, Certal V, Abdullatif J, Guilleminault C, Powell NB, Riley RW, Camacho M. Maxillomandibular advancement for treatment of obstructive sleep apnea: a meta-analysis. *JAMA Otolaryngol Head Neck Surg* 2016; 142(1):58-66.
6. Berlin NL, Tuggle CT, Steinbacher DM. Improved short-term outcomes following orthognathic surgery are associated with high-volume centers. *Plast Reconstr Surg* 2016; 138(2):273e-281e.
7. Ehardt L, Ruellas A, Edwards S, Benavides E, Ames M, Cevidanes L. Long-term stability and condylar remodeling after mandibular advancement: a 5-year follow-up. *Am J Orthod Dentofacial Orthop* 2021; 159(5):613-626.
8. Verhelst PJ, Verstraete L, Shaheen E, Shujaat S, Darche V, Jacobs R, Swennen G, Politis C. Three-dimensional cone beam computed tomography analysis protocols for condylar remodelling following orthognathic surgery: a systematic review. *Int J Oral Maxillofac Surg* 2020; 49(2):207-217.
9. Quast A, Santander P, Trautmann J, Moser N, Schliephake H, Meyer-Marcotty P. A new approach in three dimensions to define pre- and intraoperative condyle-fossa relationships in orthognathic surgery - is there an effect of general anaesthesia on condylar position? *Int J Oral Maxillofac Surg* 2020; 49(10):1303-1310.
10. van Luijn R, Baan F, Shaheen E, Berge S, Politis C, Maal T, Xi T. Three-dimensional analysis of condylar remodeling and skeletal relapse following LeFort-I osteotomy: A one-year follow-up bicenter study. *J Craniomaxillofac Surg* 2022; 50(1):40-45.
11. Shaheen E, Shujaat S, Saeed T, Jacobs R, Politis C. Three-dimensional planning accuracy and follow-up protocol in orthognathic surgery: a validation study. *Int J Oral Maxillofac Surg* 2019; 48(1):71-76.

12. Xi T, van Luijn R, Baan F, Schreurs R, de Koning M, Berge S, Maal T. Three-dimensional analysis of condylar remodeling and skeletal relapse following bimaxillary surgery: a 2-year follow-up study. *J Craniomaxillofac Surg* 2017; 45(8):1311-1318.
13. Baan F, Liebrechts J, Xi T, Schreurs R, de Koning M, Bergé S, Maal T. A new 3D tool for assessing the accuracy of bimaxillary surgery: the OrthoGnathicAnalyser. *PLoS One* 2016; 11(2):e0149625.
14. Xi T, Schreurs R, Heerink WJ, Bergé S, Maal TJ. A novel region-growing based semi-automatic segmentation protocol for three-dimensional condylar reconstruction using cone beam computed tomography (CBCT). *PLoS One* 2014; 9(11):e111126.
15. Glovsky TE, Iwasaki LR, Wu Y, Liu H, Liu Y, Sousa Melo SL, Nickel JC. Orthognathic surgery effects on temporomandibular joint compressive stresses. *Orthod Craniofac Res* 2023; Mar 31. doi: 10.1111/ocr.12659. Epub ahead of print. PMID: 37000157.
16. Dicker GJ, Tuijt M, Koolstra JH, Van Schijndel RA, Castelijns JA, Tuinzing DB. Static and dynamic loading of mandibular condyles and their positional changes after bilateral sagittal split advancement osteotomies. *Int J Oral Maxillofac Surg* 2012; 41(9):1131-1136.
17. Nickel JC, Yao P, Spalding PM, Iwasaki LR. Validated numerical modeling of the effects of combined orthodontic and orthognathic surgical treatment on TMJ loads and muscle forces. *Am J Orthod Dentofacial Orthop* 2002; 121(1):73-83.
18. Shu J, Zhang Y, Liu Z. Biomechanical comparison of temporomandibular joints after orthognathic surgery before and after design optimization. *Med Eng Phys* 2019; 68:11-16.
19. Nickel JC, McLachlan KR. In vitro measurement of the stress-distribution properties of the pig temporomandibular joint disc. *Arch Oral Biol* 1994; 39(5):439-448.
20. Politis C, Van De Vyvere G, Agbaje JO. Condylar resorption after orthognathic surgery. *J Craniofac Surg* 2019; 30(1):169-174.
21. Catherine Z, Breton P, Bouletreau P. Condylar resorption after orthognathic surgery: A systematic review. *Rev Stomatol Chir Maxillofac Chir Orale* 2016; 117(1):3-10.
22. Mousoulea S, Kloukos D, Sampaziotis D, Vogiatzi T, Eliades T. Condylar resorption in orthognathic patients after mandibular bilateral sagittal split osteotomy: a systematic review. *Eur J Orthod* 2017; 39(3):294-309.
23. Nunes de Lima V, Faverani LP, Santiago JF, Jr., Palmieri C, Jr., Magro Filho O, Pellizzer EP. Evaluation of condylar resorption rates after orthognathic surgery in class II and III dentofacial deformities: a systematic review. *J Craniomaxillofac Surg* 2018; 46(4):668-673.
24. Xi T, de Koning M, Bergé S, Hoppenreijts T, Maal T. The role of mandibular proximal segment rotations on skeletal relapse and condylar remodelling following bilateral sagittal split advancement osteotomies. *J Craniomaxillofac Surg* 2015; 43(9):1716-1722.
25. Xi T, Schreurs R, van Loon B, de Koning M, Bergé S, Hoppenreijts T, Maal T. 3D analysis of condylar remodelling and skeletal relapse following bilateral sagittal split advancement osteotomies. *J Craniomaxillofac Surg* 2015; 43(4):462-468.
26. Chen Y, Zhang J, Han Y, Ferraro N, August M. Interaction analysis of risk factors for long-term skeletal relapse following mandibular advancement with bilateral sagittal split osteotomy. *Int J Oral Maxillofac Surg* 2020; 49(3):350-355.
27. Bermell-Baviera A, Bellot-Arcís C, Montiel-Company JM, Almerich-Silla JM. Effects of mandibular advancement surgery on the temporomandibular joint and muscular and articular adaptive changes--a systematic review. *Int J Oral Maxillofac Surg* 2016; 45(5):545-552.
28. Iwasaki LR, Gonzalez YM, Liu Y, Liu H, Markova M, Gallo LM, Nickel JC. Mechanobehavioral Scores in Women with and without TMJ Disc Displacement. *J Dent Res* 2017; 96(8):895-901.

©2024 by the Department of Orthodontics and Pediatric Dentistry,
School of Dentistry, University of Michigan
Ann Arbor, MI 48109