

CASE PROFILE: RENAL ANGIOMYOLIPOMA

PROFILE

A thirty-three-year-old white male was admitted for evaluation of pain in the right flank of four days' duration, unassociated with fever, dysuria, or hematuria. Past medical history was negative for calculous disease or trauma. The diagnosis of tuberous sclerosis had been made previously for which seizure activity was controlled with diphenylhydantoin and phenobarbital.

Findings on physical examination revealed slight mental retardation and characteristic tuberous lesions of the skin. Blood pressure was 130/80

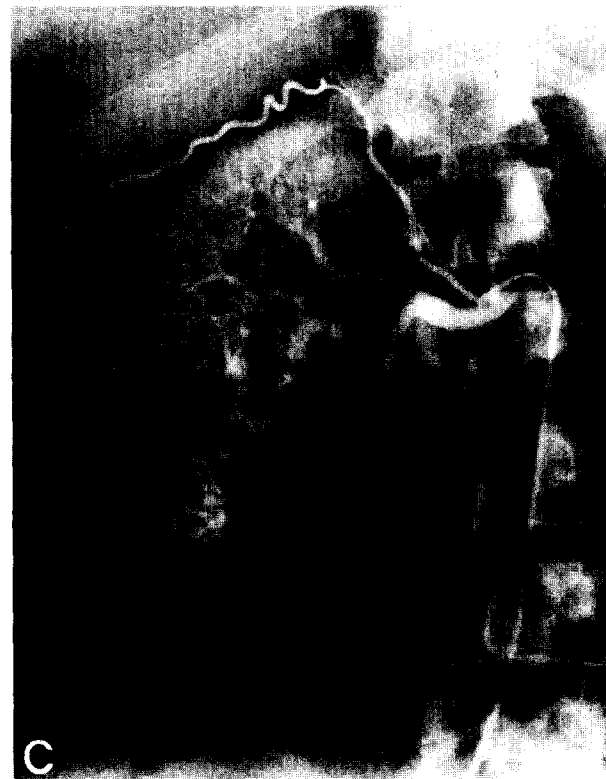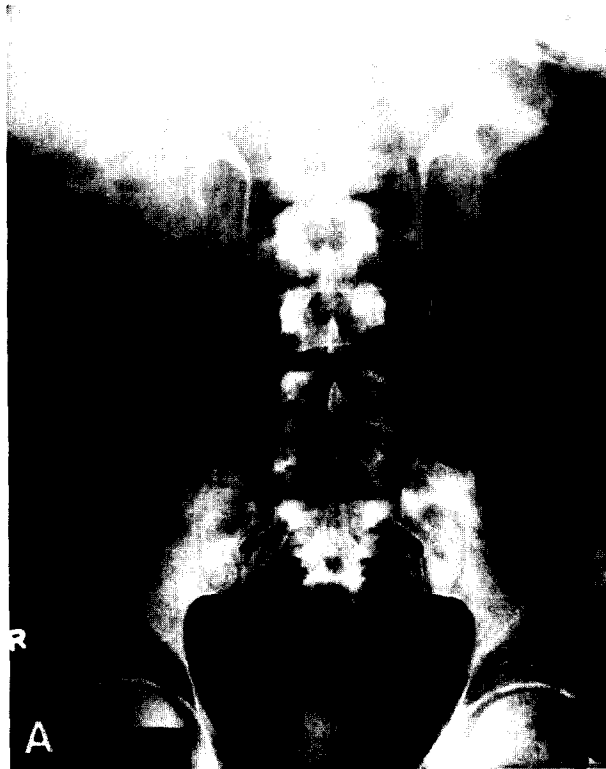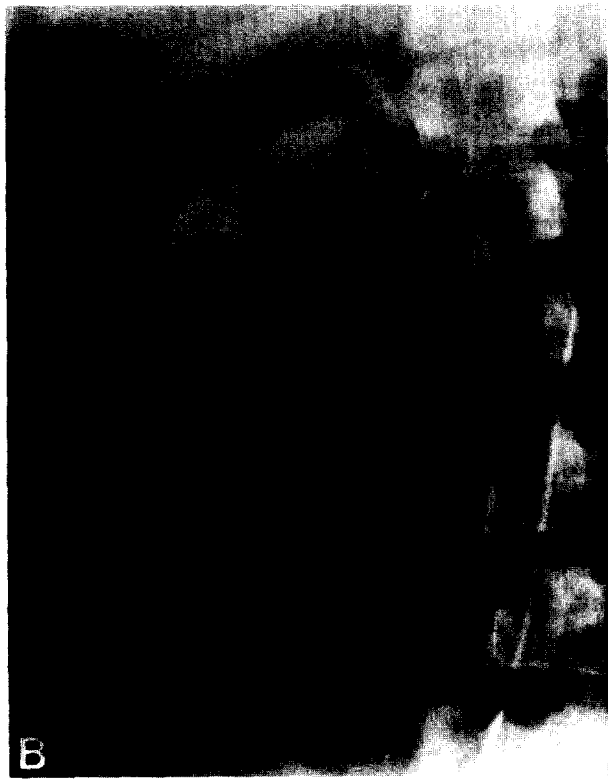


FIGURE 1. (A) Excretory urogram demonstrating typical sclerotic areas in spine and pelvis with bilateral renal masses. (B) Nephrogram phase of right renal angiogram demonstrating large tumor deformity with lucent areas. (C) Right renal angiogram demonstrating neovascularity, contrast pooling, and lucent areas within masses.

mm. Hg. Hematocrit was 41 and creatinine 1.1 mg. per 100 ml. The urine was clear and acellular. Excretory urogram showed bilateral solid kidney masses (Fig. 1A). Bilateral renal arteriograms revealed masses of both kidneys with neovascularity and contrast pooling interspersed with lucent areas (Fig. 1B and C). Renal venogram disclosed no renal vein involvement.

The diagnosis of renal angiomyolipoma was made on the basis of the clinical findings of tuber-

ous sclerosis, bilateral urographic abnormalities, and particularly the large amount of fat within the tumor producing the radiolucent areas. With spontaneous clearing of the patient's flank pain, no surgical intervention was performed at this time, and he is scheduled for periodic follow-up examinations.

Robert K. Vinson, M.D.
University of Michigan Medical Center
Ann Arbor, Michigan 48109

NOTE — Urograms of interest to our readers are welcome from urologists and radiologists. Contributions, including an abbreviated history and legend for the films, are to be sent to Arthur N. Tessler, M.D., feature editor.
