

OPERATIVE TECHNIQUE FOR STRESS URINARY INCONTINENCE

JACK LAPIDES, M.D.

From the Department of Surgery, Section of Urology,
University Hospital, The University of Michigan
Medical Center, Ann Arbor, Michigan

The most common type of stress urinary incontinence is caused by an anatomic abnormality resulting in laxness of the tissues supporting the urethrovesical junction. The stretching of these musculofascial elements results in a shortening of the length of urinary sphincter on standing or increased intra-abdominal pressure with uncontrolled loss of urine. Treatment may be surgical in nature and involves fixation of the urethrovesical junction to adjacent structures so that it cannot descend on exertion and decrease the length of the posterior urethra. Sutures and fibrous tissue formation are substituted for the defective, stretched musculofascial structures.

Before performing the operative procedure, it is mandatory to delineate accurately the type of urinary incontinence by a complete urologic examination, including excretory urography,

cystometry, electromyography of periurethral striated muscle, and endoscopy.^{1,2}

The surgical procedure is performed under spinal anesthesia with the patient in the supine position and her knees slightly flexed and abducted. The suprapubic region and vagina are prepared and draped. A 20 French self-retaining catheter, calibrated in centimeters, is then passed through the urethra into the bladder and the balloon inflated to 5 ml. capacity. Gentle traction is placed on the catheter, and the urethral length noted.

The operative approach is made through a transverse incision approximately 2 cm. above or cephalad to the superior margin of the pubis and traversing skin, subcutaneous tissue, and rectus fascia. The underlying rectus muscles are freed from the rectus fascia and from each other

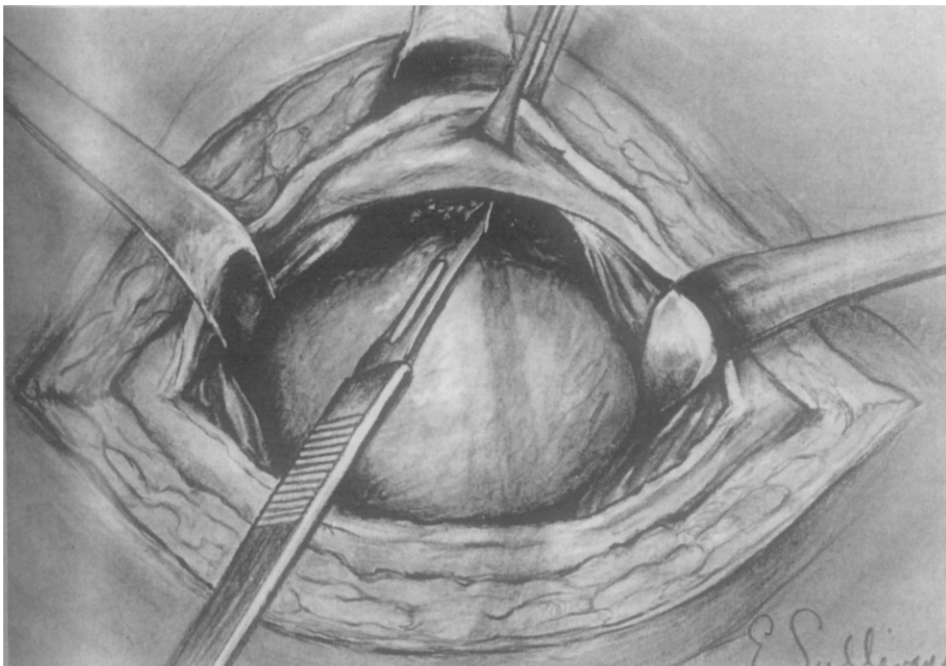


FIGURE 1. *Urethral adventitia and pubic periosteum are scarified.*

FIGURE 2. *Initial suture taken through bladder wall in region of urethrovesical junction.*

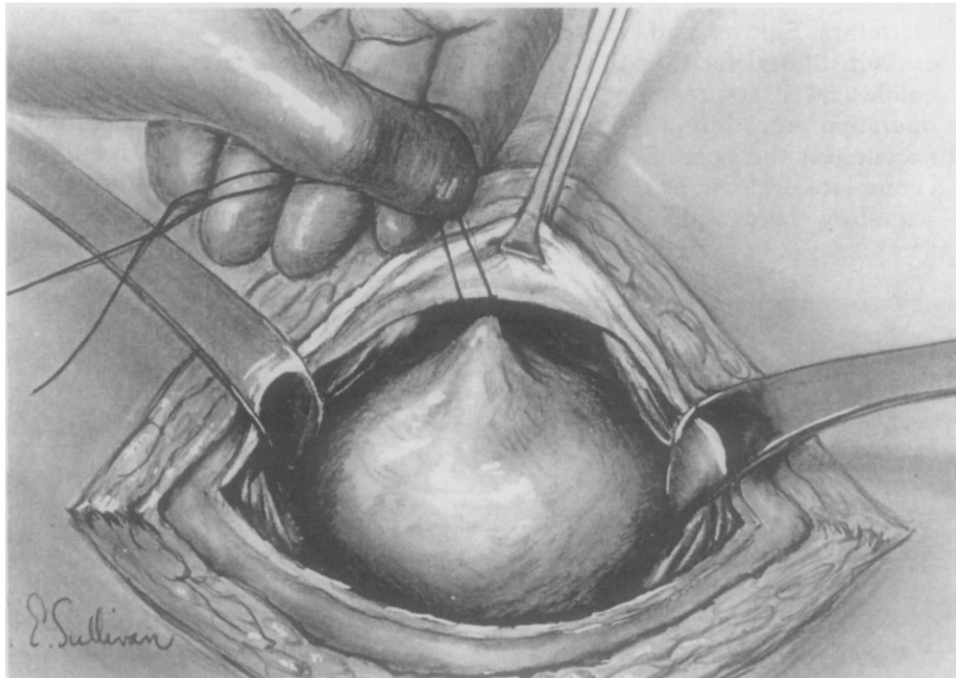
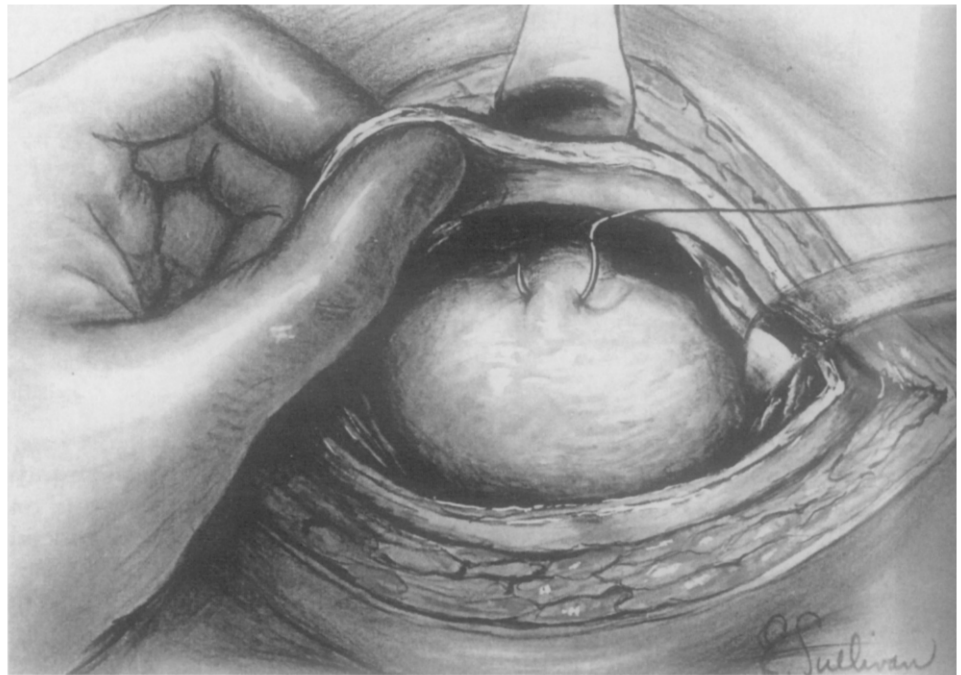

FIGURE 3. *Traction placed on suture to ascertain area of rectus fascia through which suture must be taken to lengthen urethra.*

in the midline, and retracted laterally. Urethra and bladder are identified, and the adventitia of the urethra is exposed by gently dissecting away the periurethral fat and plexus of veins. The urethral adventitial surface and periosteum of the pubis are carefully scarified with a scalpel blade (Fig. 1).

A 0-chromic catgut suture is passed through the anterior wall of the bladder in the region of the urethrovesical junction using a heavy round point or K needle. The "bite" includes about 1 cm. of tissue and enters the lumen of the bladder (Fig. 2). It is extremely important that the surgeon incorporate at least 1 cm. of urethral or

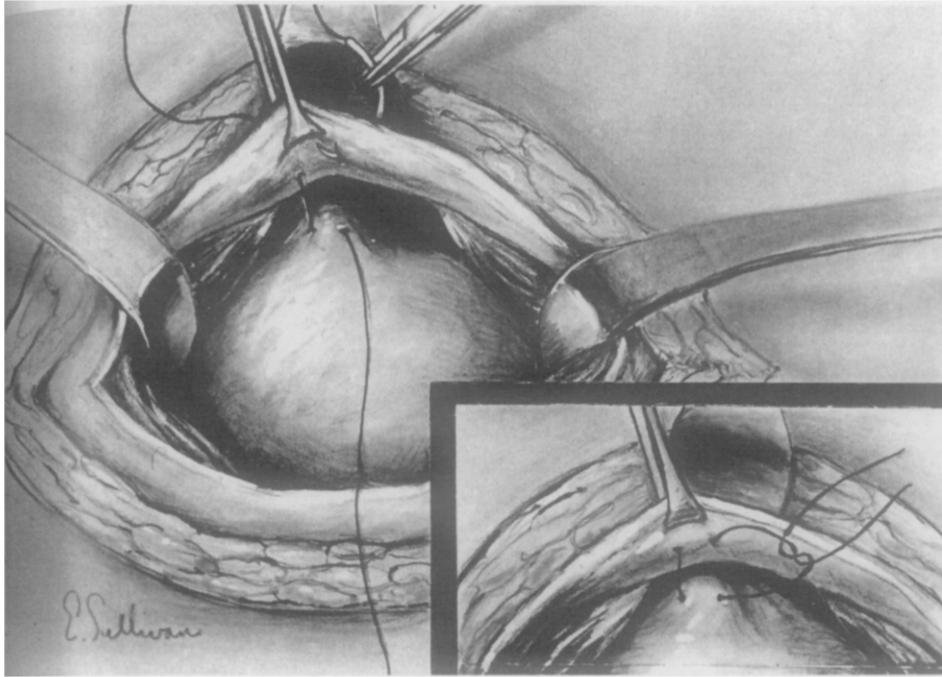


FIGURE 4. *Mattress-type stitch taken through rectus fascia.*

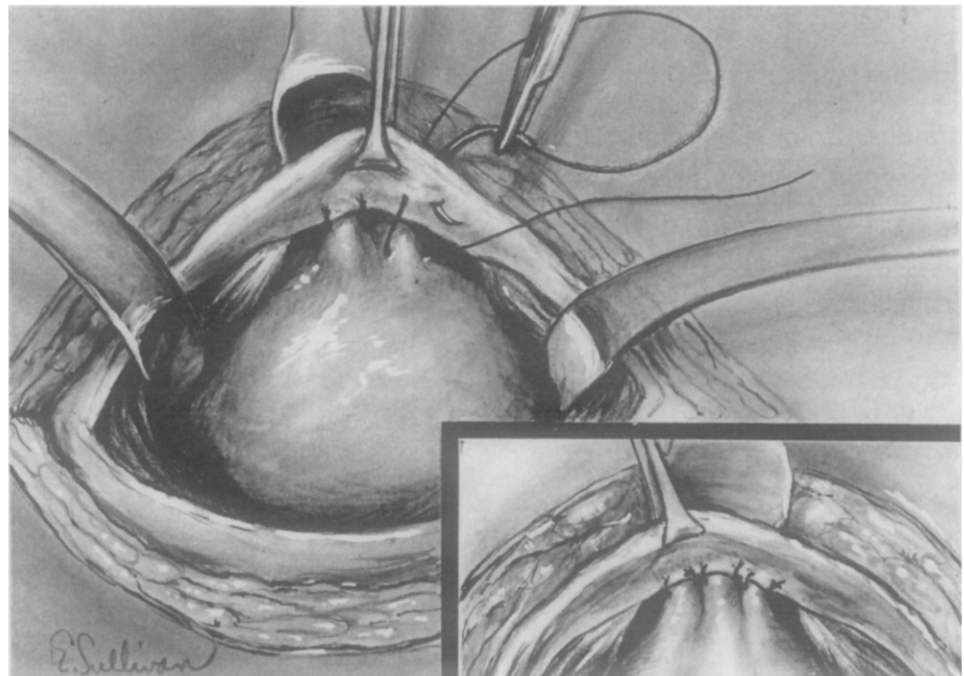


FIGURE 5. *Several more sutures placed in similar fashion in same general region.*

vesical wall in each bite and that the suture traverse the urethral or bladder cavity in the process. This is done to insure that the urethrovesical fixation does not pull loose before the patient's own fibrous tissue formation occurs and takes over for the sutures. Traction is applied to the two ends of the suture in a cephalad direc-

tion so that the urethra is stretched, and the bladder is brought into contact with the under-surface of the rectus fascia (Fig. 3). This maneuver serves to pinpoint the area on the under-surface of the rectus fascia through which the suture must be passed to fix the urethra in a lengthened state. A mattress-type stitch is then

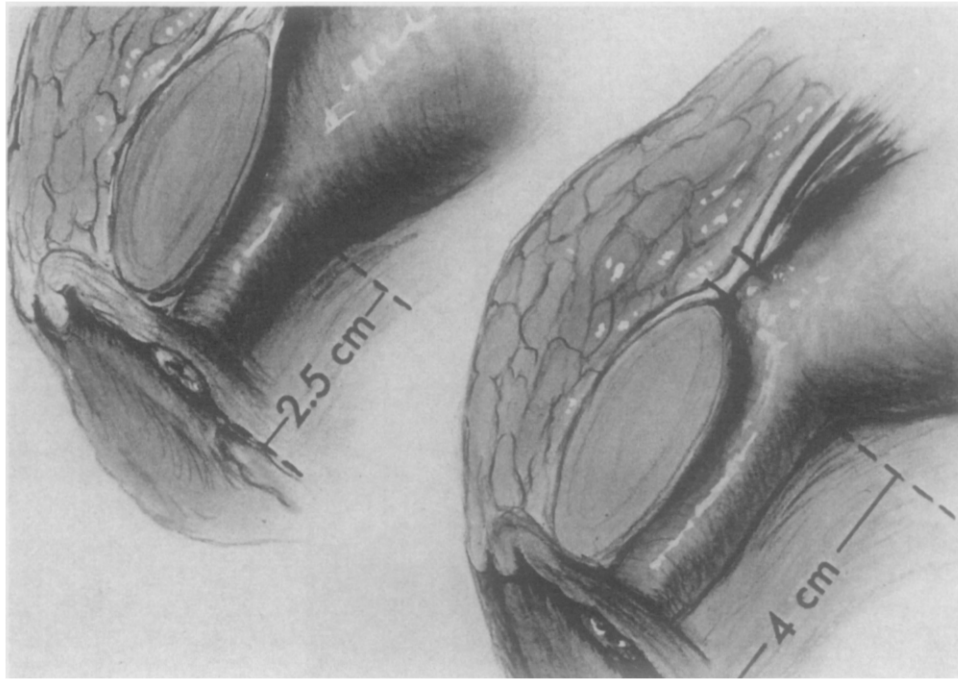


FIGURE 6. Pre- and post-operative positions and lengths of urethra and relationship of sutures to rectus fascia and urethrovaginal junction.

taken through the rectus fascia and tied (Fig. 4). Several more sutures of the same type are taken in the same general area as shown in Figure 5. Figure 6 depicts the increased length of the urethra obtained and the anatomic relationships of urethra, pubic bone, rectus fascia, and fixating sutures. It should be emphasized that the urethra need not be stretched beyond the length attained on gentle traction. Excessive tension may tear the tissue of the urethral wall with resultant postoperative pollakiuria, bladder spasm, and urethralgia.

A rubber drain is left in place, and the various layers of the abdominal wall closed. The bladder is drained by an indwelling urethral catheter for three to five days. The drain is usually removed within five to seven days.

1405 E. Ann Street
Ann Arbor, Michigan 48104

References

1. LAPIDES, J., *et al.*: Physiopathology of stress incontinence, *Surg. Gynec. and Obstet.* **111**: 224 (1960).
2. LAPIDES, J.: Simplified operation for stress incontinence, *J. Urol.* **105**: 262 (1971).