

PSEUDOURETEROCELE: A URORADIOLOGIC ENTITY

ROBERT K. VINSON, M.D.
TERRY M. SILVER, M.D.
JOHN R. THORNBURY, M.D.

From the Departments of Surgery, Section of Urology,
and Radiology, University of Michigan Medical Center,
Ann Arbor, Michigan

ABSTRACT — *An analysis of 5 patients with an acquired dilatation of the distal ureter, simulating a simple ureterocele, is herein reported. Radiologically, pseudoureteroceles are more likely to be associated with ipsilateral upper tract obstruction and have asymmetric intravesical dilatation. The urologist should be aware of this urographic deformity, for the majority of pseudoureteroceles are related to malignancy involving or invading the bladder.*

The presence of a cystic dilatation of the distal ureter seen on excretory urography should not always be equated with a simple adult ureterocele. The following 5 case reports represent examples of "pseudoureteroceles"; an analysis of these urographic abnormalities compared with simple ureteroceles is the basis for this article.

Case Reports

Case 1

A sixty-year-old black female was evaluated for abnormal uterine bleeding of one year's duration. A complete gynecologic workup revealed squamous cell carcinoma of the cervix, Stage

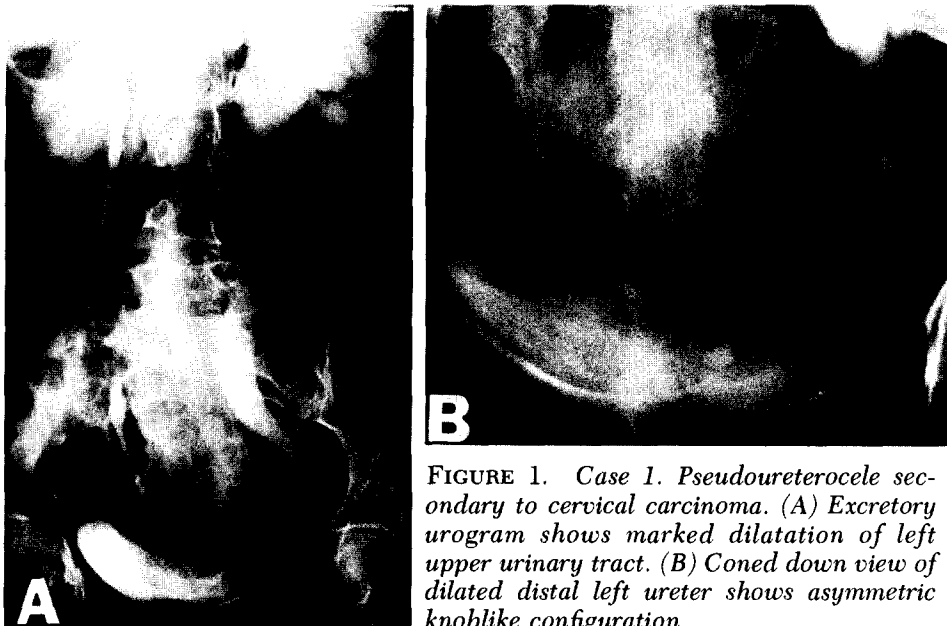


FIGURE 1. Case 1. Pseudoureterocele secondary to cervical carcinoma. (A) Excretory urogram shows marked dilatation of left upper urinary tract. (B) Coned down view of dilated distal left ureter shows asymmetric knoblike configuration.

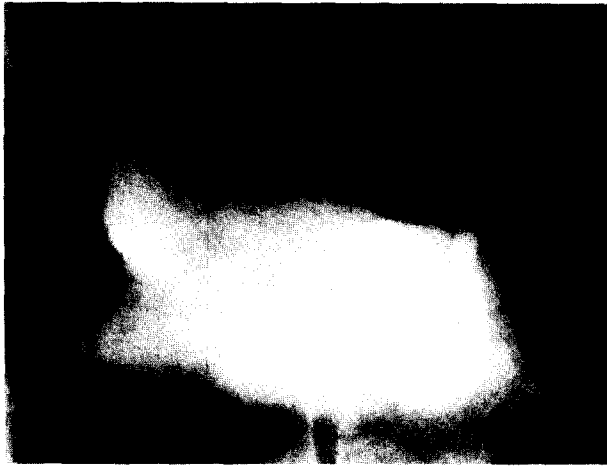

FIGURE 2. Case 2. Pseudoureterocele due to cervical carcinoma. There is fusiform dilatation of intramural segment of left ureter which is also dilated proximally.

IIB. An excretory urogram (Fig. 1A) demonstrated marked left hydroureteronephrosis with an ovoid dilatation of the left distal ureter, with no surrounding halo (Fig. 1B). At cystoscopy, elevation of the left trigone with bullous edema was noted, but no ureterocele was seen. A biopsy revealed bullous edema and chronic cystitis. The patient was treated with radiation therapy and subsequently underwent right to left transureteroureterostomy with left cutaneous ureterostomy for a vesicovaginal fistula.

Case 2

A forty-eight-year-old white female was seen with a one-month history of postmenopausal bleeding. Pelvic examination revealed an extensive cervical neoplasm. Excretory urography

demonstrated mild dilatation of the left ureter with fusiform dilatation of the distal segment (Fig. 2). Cystoscopic examination showed a markedly elevated left trigone but no evidence of ureterocele. Biopsy of this area confirmed squamous cell carcinoma of the cervix. After a positive percutaneous lung aspiration revealed squamous cell carcinoma, the patient was staged IV, and placed on combined radiation and chemotherapy.

Case 3

A fifty-year-old white male was evaluated for recurrent urinary tract infections and chronic prostatitis. He had undergone left nephrectomy several years ago for chronic pyelonephritis and calculus disease. An excretory urogram demonstrated a calculus impacted in what appeared to be a ureterocele on the right side (Fig. 3). The right upper urinary tract was not dilated. Cystoscopy revealed bullous edema of the right ureteral orifice, without evidence of ureterocele. A ureteral meatotomy was performed. The stone was passed spontaneously, and repeat urography two months later showed no trace of stone or ureterocele.

Case 4

A sixty-four-year-old black male was evaluated for gross painless hematuria. An excretory urogram demonstrated right hydroureteronephrosis with an ovoid dilatation and halo of the distal ureter (Fig. 4). Cystoscopy and transurethral resection of an infiltrating neoplasm of the right base of the bladder was undertaken. No ureterocele was noted. Pathology revealed grade IV transitional cell carcinoma of

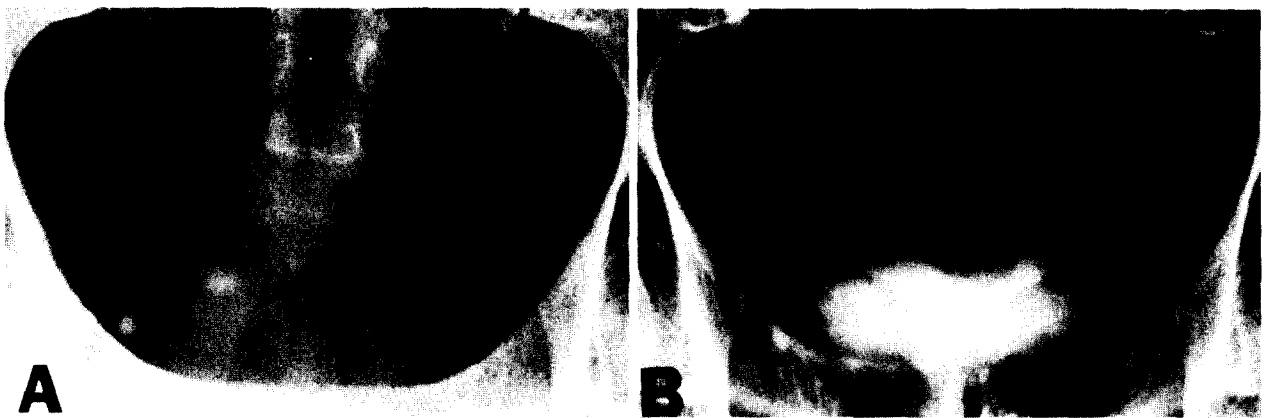


FIGURE 3. Case 3. Pseudoureterocele secondary to impacted calculus. (A) Plain radiograph of pelvis shows distal right ureteral calculus (arrow). (B) On excretory urography, calculus is obscured by contrast in pseudo-ureterocele.

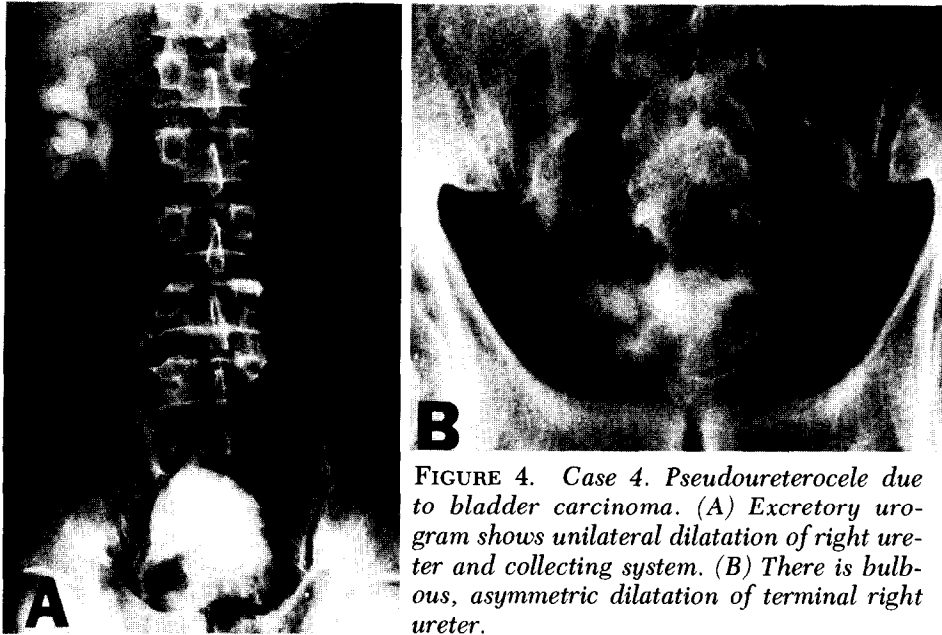


FIGURE 4. Case 4. Pseudoureterocele due to bladder carcinoma. (A) Excretory urogram shows unilateral dilatation of right ureter and collecting system. (B) There is bulbous, asymmetric dilatation of terminal right ureter.

the bladder. The patient died one month later of diffuse metastases.

Case 5

A sixty-nine-year-old black female was admitted for evaluation of urgency, frequency, and hematuria. An excretory urogram revealed distal ureteral dilatation with a surrounding halo and mild hydroureteronephrosis on the right. The patient previously had a right oophorectomy for granulosa cell carcinoma of the ovary in 1961. A course of 4,900 rads of cobalt-60 radiation therapy produced radiation proctitis and cystitis, requiring multiple blood transfusions. Cystoscopy and biopsy confirmed radiation cystitis and bullous edema; no evidence of ureterocele was seen (Fig. 5).

Comment

A simple adult ureterocele may be defined as a congenital cystic dilatation of the submucosal portion of the intravesical ureter.¹ The etiology of simple ureterocele is thought to be a congenital weakness of Waldeyer's sheath, plus incomplete absorption of Chwalla's membrane producing a stenosis of the ureteral orifice.^{2,3} In general, simple ureterocele is asymptomatic, nonobstructive, and considered innocuous congenital anomalies when discovered on excretory urography.

Although the characteristic "halo" and "cobra head" deformity have been regarded as pathognomonic of simple adult ureterocele,³ recent

reports have introduced the concept of the "false ureterocele,"⁴ "ureterocele in disguise,"⁵ and the "pseudoureterocele."^{6,10}

Datta *et al.*⁶ first introduced the term pseudoureterocele in describing three examples of an impacted distal ureteral calculus appearing radiographically as a simple ureterocele. Additional case reports have included stricture of the

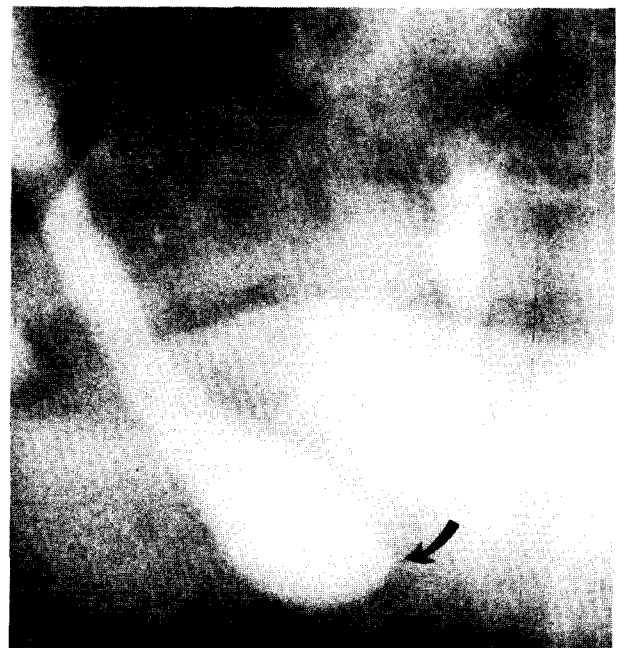

FIGURE 5. Case 5. Pseudoureterocele secondary to radiation cystitis. Dilated terminal ureter has small beaklike projection medially (arrow) and asymmetric halo.

ureteral orifice after transurethral resection of the prostate,⁷ post-ureteral catheterization,⁵ infiltrating transitional cell carcinoma of the bladder,^{5,8} and pheochromocytoma arising from the ureteral wall.⁹ This report adds squamous cell carcinoma of the cervix and radiation cystitis to the list of possible etiologies of pseudoureterocele. It is apparent that edema, inflammation, and local tissue reaction in the area of the distal ureter produce this ureterocele-like abnormality.

In an effort to discern any radiographic differences between simple adult ureterocele and pseudoureterocele, we compared the urographic findings in the 5 cases reported herein to 13 simple ureterocele, confirmed by cystoscopy.¹⁰ The majority of the pseudoureterocele varied considerably from the symmetric fusiform or bulbous shape seen in simple ureterocele. Dilatation of the ureter and collecting system occurred in 4 of the 5 pseudoureterocele, but only mild dilatation of the ureter was noted in 4 of the 13 simple ureterocele. A "halo sign" was demonstrated in 11 of the 13 cases of simple ureterocele, and 4 of the 5 cases of pseudoureterocele.

Our results parallel the recent reports of pseudoureterocele in that the halo sign and associated upper tract dilatation occurred in 10 of the 12 reported cases.

The distinction between a simple adult ureterocele and a pseudoureterocele is important, for the majority of pseudoureterocele are re-

lated to neoplasm involving or invading the bladder. We do not advocate routine cystoscopy for patients who present with radiographic findings of a simple adult ureterocele with an otherwise negative urologic history, physical examination, and urine analysis. However, further investigation is warranted if the "ureterocele" is asymmetric and/or there is associated upper urinary tract dilatation.

371 Pearl Street
Burlington, Vermont 05401
(DR. VINSON)

References

1. Tanagho EA: Anatomy and management of ureterocele, *J. Urol.* **107**: 729 (1972).
2. Wershub LP, and Kirwin TJ: Ureterocele, its etiology, pathogenesis, and diagnosis, *Am. J. Surg.* **88**: 317 (1954).
3. Thompson GJ, and Kelalis PP: Ureterocele: clinical appraisal of 176 cases, *J. Urol.* **91**: 488 (1964).
4. Datta NS, Singh SM, and Bapna BC: False ureterocele: lower ureteral stone simulating ureterocele, *Br. J. Urol.* **43**: 301 (1971).
5. Sherwood T, and Stevenson JJ: Ureterocele in disguise, *Br. J. Radiol.* **42**: 899 (1969).
6. Datta NS, Ito Y, Eisenman JI, and Bischoff AJ: "Cobra head" deformity; its relationship to ureterocele and "pseudoureterocele," *J. Assoc. Canad. Radiol.* **23**: 284 (1972).
7. Davis JP: Ureteral injury by transurethral electroresection and coagulation, *J. Urol.* **68**: 168 (1952).
8. Morse FP, III, Sears B, and Brown HP: Carcinoma of the bladder presenting as simple adult ureterocele, *ibid.* **111**: 36 (1974).
9. Cabanas VY, Faulconer RJ, and Fekete AM: Pheochromocytoma presenting as a ureterocele, *ibid.* **110**: 389 (1973).
10. Thornbury JR, Silver TM, and Vinson RK: Ureterocele vs. pseudoureterocele in adults: urographic diagnosis, *Radiology* **122**: 81 (1977).