

CLINICAL CHALLENGES

RONALD M. BURDE AND PAUL HENKIND, EDITORS

Seeing But Not Recognizing

JONATHAN R. TROBE, M.D.¹ AND RUSSELL M. BAUER, Ph.D.²

¹Departments of Ophthalmology and Neurology, University of Michigan, Ann Arbor, Michigan, and ²Department of Clinical Psychology, College Health Related Professions, University of Florida, Gainesville, Florida

Abstract. Visual recognition disturbances are caused by lesions that affect visual cortex as well as white matter connections between visual cortex and temporal and parietal cortex. Homonymous visual field defects are often present but do not explain the recognition difficulty. In "alexia without agraphia" (pure alexia), the intact right visual cortex is disconnected from the left parietal language center by a lesion in the splenium. In "prosopagnosia," visual cortex is disconnected bilaterally from temporal cortex. In simultanagnosia, visual association cortex is damaged. The first condition is most commonly caused by left posterior cerebral artery occlusion, the second by bilateral posterior cerebral artery occlusion or head trauma, and the third by watershed infarction, tumors, abscesses, head trauma, leukoencephalopathies and Alzheimer's disease. When such disorders are suspected, the examiner should supplement the routine visual examination with suggested screening maneuvers. (*Surv Ophthalmol* 30:328-336, 1986)

Key words. alexia • prosopagnosia • recognition defects • simultanagnosia • visual agnosia

An ophthalmologist was recently consulted by three patients with unusual complaints. The first patient reported that, "I can see perfectly well, but I cannot read. I can recognize some of the letters, but not the words." The second patient said, "I can no longer recognize faces — even my wife and father are unfamiliar to me until they speak." The third patient complained, "I look at photographs in the newspaper but they don't mean anything to me." On examination, all three patients had normal visual acuity. Two of the three had visual field defects, but not extensive enough to account for their complaints.

These patients are suffering from three different forms of recognition disturbances limited to vision. The first patient has an acquired disorder in reading, "alexia without agraphia" or "pure alexia." The second patient has a different problem: he can read, but he cannot recognize *complex non-verbal* stimuli, of

which faces are the most obvious daily example. His disorder is called "*prosopagnosia*." The third patient cannot recognize either verbal or nonverbal visually presented material if it is part of a *compound array* of two or more elements. His disorder is called "*simultanagnosia*."

Recognition is the ability to extract meaning from a sensation. In the classical literature, recognition abilities have been separated into *perception*, the ability to form a faithful representation of the stimulus (judged by the patient's ability to copy a figure), and *gnosis*, the ability to attach meaning to this representation. Lissauer²⁹ distinguished between "apperceptive" recognition defects, where perception is faulty, and "associative" recognition defects, in which the adequate perception of a stimulus cannot be related to past experience, and is therefore "stripped of its meaning."³⁸

Although this distinction has been useful in clas-

sifying patients with recognition defects (agnosias), some overlap between apperceptive and associative forms of agnosia nearly always exists in clinical practice. It is frequently found, for example, that patients with associative defects do not have absolutely normal perception. In fact, there is even debate about where "primary" visual function ends and "perception" begins. Bay⁵ has argued that visual acuity and visual fields, tested in the usual fashion, do not give an adequate functional measure of the primary visual system — that part responsible for conveying clear, stable images of viewed objects. Bay has claimed that most, if not all, cases of visual agnosia can be explained by an abnormally rapid "local adaptation time" (time for decay of the image) or prolonged "sensation time" (stimulus exposure time necessary for vision to take place). Ettlinger¹² has convincingly discounted Bay's explanation by showing that: 1) patients with visual agnosia performed no worse than did controls on tests of local adaptation time, sensation time, and other elementary visual functions; and 2) patients with various combinations of visual field defects, perceptual dysfunction, and dementia who had impairments in time-dependent vision tests did *not* display the clinical signs of visual agnosia. In fact, some patients with profound prosopagnosia performed at a higher level on these time-dependent vision tests than did nonagnosic patients. Therefore, the presence of such defects are, by themselves, neither necessary nor sufficient for the production of recognition defects.

Bender and Feldman⁶ argued that visual agnosias are explained by a complex interaction between primary visual abnormalities, reduced eye movements, inattention, and dementia. They presented a retrospective analysis of patients diagnosed as visual agnosics, and found dementia in all cases. This led them to conclude that "visual agnosia is the result of the total cerebral activity which renders performance of visual and/or other sensory functions inadequate." But if the presence of dementia (by itself or combined with subtle visual loss) were sufficient to produce agnosic defects, visual agnosia would be much more prevalent than it actually is in the population of patients with dementia. Moreover, bona fide cases of visual agnosia occur in nondemented patients.

A better hypothesis for visual recognition defects in the presence of adequate visual acuity and field is damage to the visual association cortex or to white matter connections between visual association cortex and other cortical memory or language centers.¹¹ *Alexia without agraphia* ("pure alexia") probably represents a disconnection between the visual cortex and the language area in the left parietal region.

Verbal information, apprehended visually, cannot be comprehended because it never reaches the language area, so that patient is unable to read. However, because a substantial portion of visual cortex is intact, the patient can see quite well; because language regions are intact, he can understand spoken words, can write normally, and is otherwise not aphasic. *Prosopagnosia* probably results from damage to visual association cortex (producing subtle perceptual disturbances) and damage to white matter tracts that connect visual association cortex and memory centers in the temporal/limbic regions. The disconnection also produces a disorder of visual recent memory. *Simultanagnosia* is likely to be a fundamental perceptual disorder resulting from profound impairment of visual association cortex, such that the patient cannot recognize more than one visual stimulus at a time. Using Lissauer's model, alexia without agraphia and prosopagnosia would be disorders of "association", whereas the defect underlying simultanagnosia presumably would exist at the "apperceptive" level. To elucidate the neurobehavioral mechanisms underlying these three disorders, each patient will be presented in detail, followed by a discussion of the clinical findings in related cases.

Alexia Without Agraphia

A 65-year-old diabetic patient awoke to discover that the morning newspaper was completely incomprehensible to him. He could make out occasional letters with difficulty, but words were meaningless. This was puzzling to him since his vision seemed otherwise unimpaired.

Ophthalmologic examination disclosed normal acuity and a complete right homonymous hemianopia. He could read some single letters but not words ("verbal alexia"). However, if he read unrecognized words letter-by-letter, he achieved rapid and accurate word identification. Oral spelling, auditory comprehension, and writing were unimpaired. Spontaneous speech and repetition of spoken phrases were flawless.

He had no difficulty copying complex line drawings, performing block designs, or recognizing faces. He could name objects but not colors. However, he sorted hues perfectly on the Farnsworth D-15 test, and, upon questioning, could tell the examiner that the sky was blue, grass was green, blood was red, and a banana was yellow. This suggested that his color naming defect did not result from a loss of color concepts.

The patient's CT scan revealed a lesion involving the entire left primary visual cortex, the mesial occipital-temporal junction, and probably the caudal portion (splenium) of the corpus callosum (Fig. 1).

The lesion was considered to represent an infarct in the region of the left posterior cerebral artery. The patient made a gradual recovery so that after three months, he could read simple words, and performed at about the third grade level on quantitative reading tests.

His deficits could be explained entirely by the concept of a "visual-verbal disconnection."¹⁴ The right visual cortex was normal but was disconnected from the left parietal cortex because of damage to the crossing splenic fibers. The left visual cortex was severely impaired, and thus unable to participate in ongoing visual functions. The result of these two circumstances is alexia. However, the patient is able to write because the lesions only impair anatomic regions subserving visual-verbal functions. As a consequence, the alexia occurs without agraphia (inability to write).

The color naming defect (color anomia) presumably results from the same mechanism. The visual apprehension of color, occurring in visual association cortex, cannot be related to left parietal language centers for assignment of the correct name. These patients perform perfectly well on color tasks that *do not require naming* of visually presented colors. For example, they answer correctly when asked the color that typically fits with a named stimulus (e.g., "what color is a banana?"), and perform well when asked to appropriately color a stimulus from a coloring book. In effect, these patients perform well on color tasks that are entirely verbal, or entirely visual, but fail whenever they are required to perform a visual-verbal color association. Incidentally, the inability to name colors (color anomia) is not always present in patients who have alexia without agraphia; it occurs only if the lesion involves the *mesial occipito-temporal cortex*.

If the patients have pure alexia on the basis of a visual-verbal disconnection, how can they name objects presented visually? That is, why is a visual *object* naming defect not invariably associated with a color-naming defect? The answer to this question is unclear, though Geschwind¹⁴ suggests that objects evoke a rich network of nonvisual (e.g., tactile) associations, such that messages may reach the language area from contralateral parietal somesthetic association cortex via pathways that cross in the corpus callosum anterior to the splenium.

Alexia without agraphia most commonly occurs after infarction of the left posterior cerebral artery, although ruptured aneurysm,²⁸ meningioma,¹⁶ metastasis,³⁹ and subdural hematoma³³ have been reported as causative.¹⁷

Although alexia without agraphia most frequently exists in the context of right homonymous hemianopia, it may rarely occur with normal visual

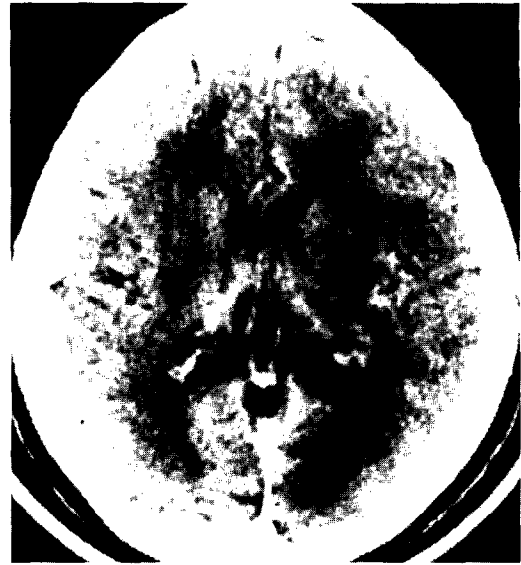

Fig. 1. Axial brain CT shows a radiolucent area (infarct) extending from splenium (anteriorly) to visual cortex (posteriorly) on left side. Patient manifested alexia without agraphia (pure alexia) and right homonymous hemianopia. Visual acuity was normal.

fields. Greenblatt¹⁷ distinguishes between these two types of "splenio-occipital" alexias (SOAs), and suggests that they derive from lesions in different locations. *SOA with hemianopia* results from the classic pattern of lesions described above: a left medial occipital lobe lesion coupled with a lesion of the splenium of the corpus callosum. *SOA without hemianopia*, which is extremely rare, involves the splenium as well, but the left calcarine region and its afferent connections are preserved. Lesions of the deep white matter tracts connecting calcarine cortex with the angular gyrus (the transverse fasciculus of the lingual gyrus and the vertical occipital fasciculus) have been implicated in this form of alexia.^{1,18,21} Unlike *SOA with hemianopia*, *SOA without hemianopia* is not usually caused by strokes but by tumors, arteriovenous malformations, and trauma.¹⁷ Another distinction between these two forms of alexia is that patients with *SOA without hemianopia* have no color naming defect.^{17,18,23}

Detecting the nonhemianopic form of SOA will be particularly difficult, since both verbal and visual functions will be normal. What is more, many alexic patients can adequately read single letters ("verbal alexia"), and thus acuity testing may not provide a clue to their defect. The diagnosis will only become evident if, during the course of the examination, the patient is asked to read a paragraph from a magazine or newspaper.

Prosopagnosia

A 39-year-old man awoke from a week-long coma after head trauma in an automobile accident. As he regained consciousness, he discovered that he could not recognize the faces of visitors (family or friends) or of personnel who attended him unless they had distinctive facial features such as a beard, moustache, or an unusual hairstyle. As he was gradually allowed to leave his room and navigate about the ward in a wheelchair, he noted that he could not find his way back to his room unless he recited verbal directions. He also noted that objects had lost their hues, appearing as shades of dirty gray.

Ophthalmologic examination revealed visual acuities of 20/20 in each eye; visual fields showed bilateral superior altitudinal hemianopias and a left inferior congruous homonymous hemianopia. The only other abnormalities were noted on neuropsychological examination.

The most striking finding was that he could not recognize familiar faces, including pictures of famous faces, actual confrontations with family members, or even mirror images of his own face. Curiously, he could perform facial discrimination problems provided that faces were all presented *at the same time*. He could accurately describe all the details of a face as it was shown to him. However, when he was shown a face and then, 90 seconds later, asked to pick the face from a larger array, his accuracy at identifying that face was no better than chance. If his doctor walked out of the room and returned a minute later without his white coat, the patient did not recognize him until he spoke. If the doctor put on his white coat, the patient evidenced tentative recognition, implying that he understood the medical context and knew which personalities belonged in that context. He never immediately recognized others by their facial features, unless there was something distinctive or unusual about them (a mole, or an unusual moustache or hairstyle). The patient was *always* able to identify individuals if they were allowed to speak to him, or if he could use other distinctive extrafacial features such as a bow-tie or a belt buckle.

The patient's recognition defect was not limited to faces. It involved all visually presented stimuli or problems that were not easily handled by words.^{4,10} For example, when he viewed a single screwdriver, he was able to easily recognize it later within an array containing the screwdriver, a watch, a key-chain, and a knife. But if the array consisted of several different screwdrivers, he performed at a chance level. He could remember details of stories read to him, and could follow verbal directions quite well. However, without such verbal instructions, he quickly lost his way. He failed abjectly in reproduc-

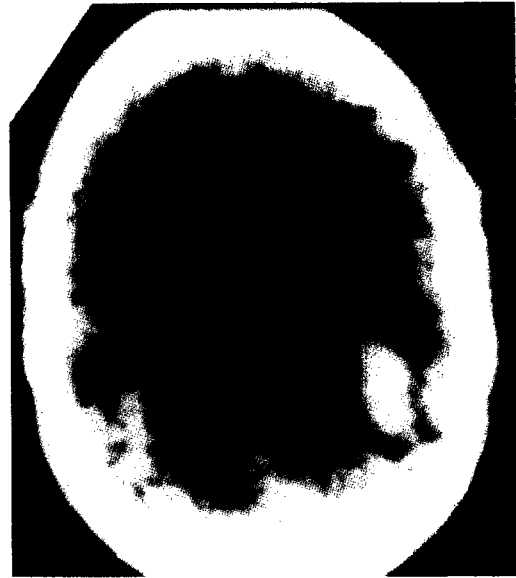


Fig. 2. Axial brain CT shows bilateral hemorrhagic radiodense areas in the temporal and occipital lobes, involving visual association cortex and occipito-temporal white matter connections. Patient manifested prosopagnosia and visual recent memory loss, as well as cerebral (central) achromatopsia and bilateral superior altitudinal visual field defects.

ing line drawings from memory.

As poorly as he performed in nonverbal memory tasks, he had much less difficulty with perceptual tests not involving a memory demand. For example, he could describe action in complex pictures and could flawlessly copy even complex geometric designs and build block designs from models, provided they all remained in his view. Still, his perceptual ability was not absolutely normal. For example, he could often not identify objects from incomplete line drawings, and he engaged in a feature-by-feature analysis of all visual stimuli shown to him instead of describing the totality at once. It was as if his perceptual abilities had lost their "gestalt," organizational character.

The patient had a color deficit which was different than that seen in the first patient. While he could correctly name colors of objects shown to him, he made several mistakes in fine hue distinctions when sorting the colored chips of the Munsell-Farnsworth 100 hue test.

CT scan revealed bilateral radiodense lesions (neumatomas) involving ventromedial occipital cortices (Fig. 2). Areas 18 and 19 of visual association cortex, as well as underlying white matter, were involved.

Lesions producing prosopagnosia appear to in-

volve visual association cortex and disrupt occipito-temporal corticocortical connections, such as the inferior longitudinal fasciculus.^{4,10} These lesions produce a subtle perceptual impairment sometimes described as a defect in "visual categorization";^{13,42} the lesions also prevent visual information from reaching memory stores.^{3,7,36} That the patient's recent memory stores themselves are unimpaired is evident from his above average performance on auditory-verbal memory tasks (recalling the details of a story told to him). The discrepancy between auditory and visual recent memory implies that while memory stores are intact and accessible by auditory inputs, they cannot be reached by visual inputs ("visual recent memory loss").³⁶ Whenever the patient was able to verbally "tag" a visual object (including a face) with a word, he was able to remember it. He could do this for many objects, but not for most complex figures, of which faces appear to be the most common and striking example in everyday life.

Prosopagnosia probably results, then, from both perceptual impairment (from visual association cortex lesions) *and* memory impairment (from disconnection of visual and temporal cortex).⁴ Neither perceptual nor memory impairment alone is sufficient; both seem necessary for producing the recognition defect. Support for this hypothesis comes from the following observations: (a) prosopagnosia seems poorly correlated with the degree of perceptual dysfunction;¹² (b) at least one reported patient with isolated visual recent memory loss did not have prosopagnosia;³⁶ and (c) prosopagnosics perform well in perceptual matching tasks where there are no memory demands.³² The perceptual defect in prosopagnosia may be subtle, but it results in mild deformation of the visual signal. If that signal is further interrupted by a white matter tract lesion, it will be unable to select the proper memory template from storage.¹⁰ Subtle perceptual flaws not apparent in other tasks may disturb the most exacting of visual discrimination tasks — the everyday recognition of faces.

Prosopagnosia usually occurs in the setting of extensive and *bilateral* mesial occipital lobe damage resulting from stroke, hypoxia, or trauma. If visual association cortex is not extensively damaged, and damage mainly involves the inferior longitudinal fasciculus (ILF), then visual recent memory loss occurs without prosopagnosia. But if visual association cortex is extensively damaged, prosopagnosia accompanies the loss of visual recent memory. Only if the lesions extend more superiorly to include occipital-parietal connections (as well as the occipital-temporal connections) will it become difficult for patients to recognize visually presented objects. Under these circumstances, the patient becomes un-

able to name or demonstrate the use of visually presented objects, though able to immediately identify them if allowed to tactually manipulate them ("visual object agnosia").

The concurrence of prosopagnosia and cerebral (central) achromatopsia reflects involvement of inferior occipital lobe. The two defects may occur in isolation but are frequently seen together. Prosopagnosia requires bilateral occipital-temporal lesions; achromatopsia requires fusiform and lingual gyrus lesions, and may occur with unilateral involvement, in which case the color blindness will be confined to the opposite hemifield.¹⁰ The occurrence of cerebral achromatopsia with inferior occipital lesions has an interesting animal correlate: studies in Rhesus monkey show that color coding occurs in an area distinct from form coding.⁴⁵

Simultanagnosia

A 62-year-old man noted profound visual difficulties upon recovering from a ten-hour period of unresponsiveness after cardiac arrest. He described his problem in the following manner: "I will look at things around me, and although I can see them clearly, they don't make sense. I look at pictures in the newspaper, and I don't know what's going on." He also complained of a specific inability to read large print, while fine print presented no problem. Additional complaints included difficulty with calculation, three-dimensional and geographical relationships, and dressing.

Neuropsychological testing revealed superior verbal intelligence (Wechsler Adult Intelligence Scale), normal language, excellent conversational ability and fund of general information, and excellent auditory-verbal memory. He could recognize fragmented parts of objects or drawings, but he could not form an impression of the whole stimulus. He could identify a single stimulus, but he was totally unable to recognize more than one object at a time. It often appeared as if he were looking through a peephole which was too narrow to include the entire stimulus. The absolute size of the stimulus was an unimportant determinant; what mattered was whether the stimulus was alone in the array. If it was, then recognition was possible; if it was presented along with another stimulus, the patient was unable to recognize either stimulus.

Response times were extraordinarily slow; he would often take more than two minutes to identify a simple drawing or to locate a specific stimulus in a larger array. He adopted a "haphazard" rather than systematic approach to the detection and processing of relevant stimulus features. By using this strategy, a peripheral element would lead him astray. For example, in scrutinizing a line drawing of a baseball, he fixed on the seams and called it a picture of a

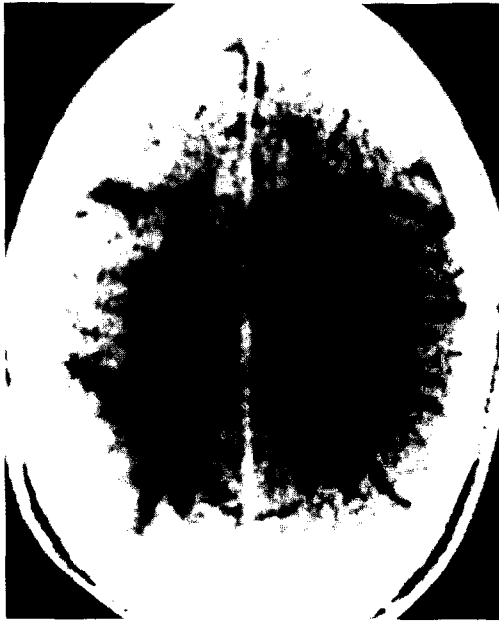

Fig. 3. Axial brain CT shows bilateral radiolucencies in the parieto-occipital regions believed to be watershed infarctions. Patient manifested simultanagnosia.

railroad track.

When reading, the patient failed to recognize whole letters, but could occasionally achieve letter recognition by arduously searching the features of a letter stimulus. For example, when viewing the letter "R," he first noticed the straight line on the left, then the curved line in the upper right. On the basis of this, he guessed that the letter "must be a 'D'." On further examination (which took approximately three minutes), he noticed the straight diagonal in the lower right, exclaimed that "D's don't have this line here . . . (pause) . . . it must be an 'R'." This entire process required almost four minutes.

Ophthalmological evaluation revealed shallow, evanescent bilateral paracentral scotomata, insufficient in severity to account for his profound visuo-perceptual and recognition deficits. Computerized tomography revealed bilateral occipitoparietal radiolucencies consistent with infarcts in parasagittal watershed regions (Fig. 3). This was consistent with previous reports on the location of lesions in this syndrome of "simultaneous agnosia" or "simultanagnosia."^{18,19,20}

"Simultanagnosia" is a term introduced by Wolpert¹⁴ to refer to a condition in which the patient is unable to recognize or abstract the meaning of a whole stimulus array (e.g., picture) even though the details (singular stimulus elements) are correctly appreciated. The patient with simultanagnosia can

recognize and describe specific elements of a compound stimulus, but cannot integrate these elements to achieve recognition of the picture. Simultanagnosia involves a defect of visual attention that appears to result in a dynamic narrowing of the "effective visual field."^{20,26} This defect is sometimes seen together with (1) "*psychic gaze paralysis*," an inability to voluntarily look into the peripheral field,^{21,40} and (2) *optic ataxia*, a clumsiness or inability to respond manually to visual stimuli, with mislocalization when reaching for or pointing to visual targets.^{8,9,19,27} The three defects of simultanagnosia, gaze paralysis, and optic ataxia comprise the clinical entity known as Balint's syndrome.² Although these features tend to be seen together, they may occur in isolation.

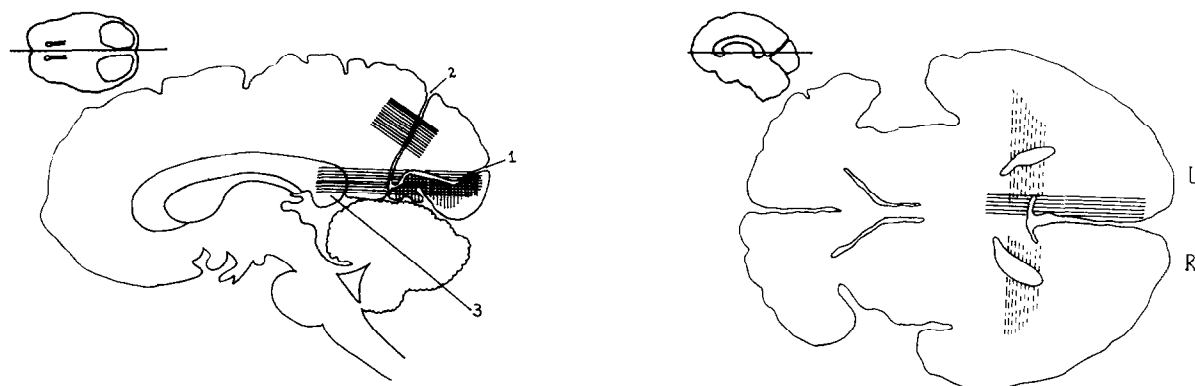
In the patient with simultanagnosia, visual fields may be normal by standard perimetric testing, but will shrink to "shaft vision" when the patient concentrates on the visual environment. Performance may be worse in one hemifield, more often on the left. A striking example of narrowing of the effective visual field is given by Hecaen and Ajuriaguerra²⁰. While their patient's attention was focused on the tip of a cigarette held between his lips, he failed to see a match flame offered to him several inches away.

Although quite rare, the full-blown syndrome of simultanagnosia is significant in that it is one of the best examples of an "apperceptive" agnosia. Several theories of the nature of simultanagnosia have been proposed. Wolpert¹⁴ felt that the disorder involved a defect in the "appreciation of the whole" (*Gesamtauffassung*). Holmes²² postulated that such patients had lost appropriate visual coordinates ("visual orientation") and suffered from grossly restricted visual attention. Pavlov³¹ regarded simultanagnosia as a result of a general reduction in cortical excitation. He wrote,

"The occipital region is inhibited to such a considerable degree that it cannot endure two simultaneous stimulations . . . hence the patient sees a distinct person, object, etc., but is unable simultaneously to perceive anything else, since the notion of space escapes him. Everything is confined to the point which is stimulated at the given moment. There are no traces whatsoever, and that is why the patient feels "lost in the world'."

Levine and Calvanio²⁶ studied the ability of simultanagnosic patients to identify letters presented rapidly in a tachistoscope. They found that their patients could identify single letters quite well, but performed poorly on multiple letter presentations, even though exposure durations were long enough to permit normal subjects to foveate the letters one

Fig. 4. Schematic brain sections showing the location of lesions causing visual recognition defects: Top — coronal; Bottom left: — sagittal; Bottom right: — axial. Vertical solid lines: lesion causing superior homonymous hemianopia and hemiachromatopsia. Horizontal solid lines: lesion causing alexia without agraphia (pure alexia) and right homonymous hemianopia. Vertical dashed lines: lesions (bilateral) causing prosopagnosia, achromatopsia, and visual recent memory loss. Diagonal solid lines: lesions (bilateral) causing simultanagnosia and possibly optic ataxia. 1 — calcarine fissure, 2 — parieto-occipital fissure, 3 — splenium, 4 — lingual gyrus, 5 — fusiform gyrus, 6 — inferior longitudinal fasciculus.



at a time. They interpreted simultanagnosia as a deficit in the perceptual analysis of *compound* (multiple) visual arrays, and proposed that defective short-term visual memory could also be partly responsible.

Kinsbourne and Warrington²⁵ called this defect a disorder of "simultaneous form perception," believing that a basic deficit of form perception underlies the faulty picture interpretation and accounts for the verbal alexia (inability to read whole words) frequently seen as an associated sign.^{26,41} They agreed with Stauffenberg³⁷ that "there is often an inability to pick out important details . . . instead, prominence is lent to important or irrelevant ones." Kinsbourne and Warrington²⁵ postulated that picture interpretation involves multiple steps, including the perception of parts of the picture, rapid succession of individual part-perceptions, and the use of eye movements to synthesize parts together in temporal and spatial sequence. Their observations led them to suggest that the patient with simultanagnosia cannot perceive more than one thing at a time, and that the amount of time necessary between two perceptual acts is excessively long in simultanagnosia. The net result of these two defects is that the patient is profoundly impaired in the ability

to synthesize the results of the individual perceptual acts into coherent wholes.

Upper and Lower Syndromes

A convenient way of categorizing these higher order visual deficits is to think of them on a vertical anatomic continuum from bottom to top (Table 1 and Fig. 4).

The five lower syndromes fall into the domain of the posterior cerebral artery; occlusion of this vessel is the principal cause of all of them. The two upper syndromes occur in a watershed zone between posterior and middle cerebral artery distributions; global cerebral ischemia and hypoxia, rather than vascular occlusion, are common causes, together with metastatic tumors, abscesses, head trauma and degenerative disorders, including leukoencephalopathies and Alzheimer's disease.

Examining the Patient With Visual Recognition Defects

The preceding three cases underscore the point that patients may be able to pass the routine ophthalmological tests and still have disabling visual deficits. If the regular ophthalmologic examination fails to explain persistent complaints, it may be that

TABLE 1
Higher Order Visual Disturbances

Lower Syndromes			
Condition	Deficit	Lesion	Common Causes
1. Cerebral (central) achromatopsia	Inability to sort colors. May be limited to hemifield	Lingual and fusiform gyri. Often unilateral	Posterior cerebral artery occlusion
2. Prosopagnosia	Inability to recognize familiar faces (famous and family); visual memory frequently disturbed; visuoperceptive skills mildly disturbed	Bilateral inferior visual association cortex and its connections to limbic temporal cortex	Bilateral posterior cerebral artery occlusions, head trauma
3. Visual object agnosia	Inability to name or demonstrate use of visually presented (but not tactually-presented) objects	Bilateral occipito-temporal	Bilateral posterior cerebral artery occlusions, head trauma. (Very rare)
4. Alexia without agraphia (Pure alexia)	Inability to read; other language functions intact. Usually associated with right homonymous hemianopia. May have color anomia	Left primary visual cortex and splenium; rarely, primary visual cortex spared, and only its connections to left angular gyrus involved (no hemianopia)	Left posterior cerebral artery occlusion
5. Color anomia	Inability to name colors; ability to sort colors intact	Left mesial occipital-temporal cortex	Left posterior cerebral artery occlusion
Upper Syndromes			
1. Simultanagnosia	Inability to recognize compound visual arrays	Bilateral superior visual association cortex and connections to parietal cortex	Hypoxia, watershed infarcts in border zone between middle and posterior cerebral arteries; degenerative diseases and tumors
2. Optic ataxia	Inability to localize visual objects in space; may be restricted to one hand and one hemifield	Occipito-parietal. May be unilateral	Hypoxia, watershed infarcts in border zone between middle and posterior cerebral arteries; degenerative diseases and tumors

they reflect "higher level" visual dysfunction. In such cases, the routine examination must be supplemented with some simple screening maneuvers, such as:

1) Reading a paragraph from a newspaper. This will detect most alexics.

2) Copying a line drawing. This will detect most perceptual disorders.

3) Providing a detailed description of what patients see as they explore an object or picture. This will provide more evidence of a perceptual disorder.

4) Identifying photographs of famous personages. This will detect most prosopagnosics.

5) Reaching for objects in space. If the patients

misreach, they may have "optic ataxia." (Each hemifield must be tested.)

6) Naming and sorting colors. If patients misname colors, they may have color anomia; if they also mis-sort colors (Farnsworth D-15 or D-100), they may have central achromatopsia.

If these screening tests give a hint that a higher order visual disorder is present, patients will require more detailed examination by a neurologist, neuroophthalmologist, or neuropsychologist. Although a cure may not be forthcoming, at least the patients will get an acknowledgment and an explanation for not being able to recognize what they may see so clearly.

References

1. Ajax ET: Dyslexia without agraphia. *Arch Neurol* 17:645-652, 1967
2. Balint R: Seelenlahmung des "Schauens", optische Ataxie, raumliche Störung der Aufmerksamkeit. *Monatsschr Psychiatr Neurol* 25:57-71, 1909
3. Bauer RM: Visual hypoemotionality as a symptom of visual-limbic disconnection in man. *Arch Neurol* 39:702-708, 1982
4. Bauer RM, Trobe JD: Visual memory and perceptual impairments in prosopagnosia. *J Clin Neuro Ophthalmol* 4:39-45, 1984
5. Bay E: Disturbances of visual perception and their examination. *Brain* 76:515-550, 1953
6. Bender MB, Feldman M: The so-called "visual agnosias". *Brain* 95:173-186, 1972
7. Benton AL, Van Allen MW: Prosopagnosia and facial discrimination. *J Neurol Sci* 15:167-172, 1972
8. Boller F, Cole M, Kim Y, Mack JL, et al: Optic ataxia: Clinical-radiological correlations with the EMI scan. *J Neurol Neurosurg Psychiatr* 38:954-958, 1975
9. Damasio AR, Benton AL: Impairment of hand movements under visual guidance. *Neurology (Minneapolis)* 29:170-174, 1979
10. Damasio AR, Damasio H, Van Hoesen GW: Prosopagnosia: Anatomic basis and behavioral mechanisms. *Neurology (NY)* 32:331-341, 1982
11. Damasio AR, Damasio H: The anatomic basis of pure alexia. *Neurology* 33:1573-1583, 1983
12. Ettlinger G: Sensory deficits in visual agnosia. *J Neurol Neurosurg Psychiatr* 19:297-307, 1956
13. Faust C: *Die zerebralen Herderscheinungen bei Hinterhauptverletzungen und ihre Beurteilung*. Stuttgart, Germany: Thieme Verlag, 1955
14. Geschwind N: Disconnexion syndromes in animals and man. *Brain* 88:237-294; 585-644, 1965
15. Geschwind N, Fusillo M: Color-naming defects in association with alexia. *Arch Neurol* 15:137-146, 1966
16. Gloning I, Gloning K, Jellinger K: Tschabitscher: Zur dominanzfrage beim syndrom: Reine wortblindheit-farbagnosie. *Neuropsychologia* 4:27-40, 1966
17. Greenblatt SH: Localization of lesions in alexia. In: A. Kertesz (Editor). *Localization in Neuropsychology*. New York: Academic Press, pp. 323-356, 1983
18. Greenblatt SH: Alexia without agraphia or hemianopsia. *Brain* 96:307-316, 1973
19. Haaxma R, Kuypers HGJM: Intrahemispheric cortical connections and visual guidance of hand and finger movements in the rhesus monkey. *Brain* 98:239-260, 1975
20. Hecaen H, Ajuriaguerra J de: Balint's syndrome (psychic paralysis of visual fixation) and its minor forms. *Brain* 77:373-400, 1954
21. Hoff J, Potzl O: Reine wortblindheit bei hirntumor. *Nervenarzt* 10:385-394, 1973
22. Holmes G: Disturbances of visual orientation. *Br J Ophthalmol* 2:449-468, 1918
23. Johansson T, Fahlgren H: Alexia without agraphia: Lateral and medial infarction of left occipital lobe. *Neurology* 29:390-393, 1979
24. Karpov BA, Meerson YA, Tonkonogii IM: On some peculiarities of the visuomotor system in visual agnosia. *Neuropsychologia* 17:281-294, 1979
25. Kinsbourne M, Warrington EK: A disorder of simultaneous form perception. *Brain* 85:461-486, 1962
26. Levine DN, Calvanio R: A study of the visual defect in verbal alexia-simultanagnosia. *Brain* 101:65-81, 1978
27. Levine DN, Kaufman KJ, Mohr JP: Inaccurate reaching associated with a superior parietal lobe tumor. *Neurology* 28:556-561, 1978
28. Levitt LP, Gastinger J, McClintic W, Lin F: Alexia without agraphia due to aneurism. *Penn Med* 81:86-87, 1978
29. Lissauer W: Ein Fall von Sellenblindheit nebst einem Beitrage zur Theorie derselben. *Arch Psychiatr* 21:222-270, 1890
30. Luria AR: Disorders of "simultaneous perception" in a case of bilateral occipito-parietal brain injury. *Brain* 82:437-449, 1959
31. Marshall J, Newcombe F: Patterns of paralexia: A psycholinguistic approach. *J Psycholinguistic Res* 2:175-200, 1973
32. Meadows JC: The anatomic basis of prosopagnosia. *J Neurol Neurosurg Psychiatr* 37:489-501, 1974
33. Papadakis N: Subdural hematoma complicated by homonymous hemianopia alexia. *Surg Neurol* 2:131-132, 1974
34. Parlov IP: *Selected Works*. Moscow, USSR, 1959
35. Poppelreuter W: *Die psychischen Schädigungen durch kopfschuss in kriege*. Voss: Leipzig, 1917
36. Ross ED: Sensory specific and fractional disorders of recent memory in man. I. Isolated loss of visual recent memory. *Arch Neurol* 37:183-200, 1980
37. Stauffenberg V: *Über Seelenblindheit*. *Arbeiten aus dem Hirnanatomischen Institut in Aurich* Heft 8. Wiesbaden: Bergman, 1914
38. Teuber HL: Alteration of perception and memory in man. In: *Analysis of Behavior Change*, L. Weiskrantz (Editor). New York: Harper & Row, 1968
39. Turgman J, Goldhammer Y, Braham J: Alexia without agraphia, due to brain tumor: A reversible syndrome. *Ann Neurol* 6:265-268, 1979
40. Tyler HR: Abnormalities of perception with defective eye movements (Balint's syndrome). *Cortex* 4:154-171, 1968
41. Warrington EK, Shallice T: Word-form dyslexia. *Brain* 103:99-112, 1980
42. Whiteley AM, Warrington EK: Prosopagnosia: A clinical, psychological, and anatomic study of three patients. *J Neurol Neurosurg Psychiatr* 40:395-403, 1977
43. Wolpert I: Die Simultanagnosie: Störung der gesamtaufassung. *Z Gesamte Neurol Psychiatr* 93:397-413, 1924
44. Zeki SM: Colour coding in rhesus monkey prestriate cortex. *Brain Res* 53:422-427, 1973
45. Zeki SM: Colour coding in the superior temporal sulcus of rhesus monkey visual cortex. *Proc R Soc Lond [Biol]* 197:195-223, 1977

Supported in part by an unrestricted departmental grant from Research to Prevent Blindness, Inc., New York, New York.

Reprint requests should be addressed to Jonathan D. Trobe, M.D., W. K. Kellogg Eye Center, 100 Wall St., Ann Arbor, MI 48105.