

CT FINDINGS OF HYPERVASCULAR MALIGNANT PERITONEAL MESOTHELIOMA

DEBORAH S. GRANKE,* JAMES H. ELLIS and BRUCE D. RICHMOND
Radiology Service (114), Veterans Administration Medical Center and Department of Radiology,
University of Michigan Medical School, Ann Arbor, MI 48105, U.S.A.

(Received 19 June 1986; in revised form 27 October 1986; received for publication 6 November 1986)

Abstract—A case of peritoneal mesothelioma is presented in which CT demonstrated abnormal regions of increased vascularity in the omentum corresponding to hypervascular omental lesions shown by angiography. This CT appearance has not been described in prior reports of CT in peritoneal mesothelioma.

Mesothelioma, peritoneal Angiography Computed tomography

INTRODUCTION

Reports of computed tomography (CT) in mesothelioma describe peritoneal involvement that may be extensive, with confluent tumor in layers, masses, and/or nodules and mesenteric infiltration [1, 2]. A recent report of arteriography in peritoneal mesothelioma described three cases of mildly to moderately hypervascular omental lesions without arteriovenous shunting; however, the one CT scan performed was nondiagnostic [3]. We report a case of peritoneal mesothelioma where CT demonstrated abnormal regions of increased vascularity in the omentum corresponding to the hypervascular omental lesions shown by angiography.

CASE REPORT

A 54-year-old white male presented with a 3-month history of insidious onset of diffuse abdominal tenderness, early satiety, abdominal bloating, and crampy abdominal pain. His physical exam was unremarkable, and routine laboratory tests, sigmoidoscopy, and barium enema were normal. An upper gastrointestinal examination demonstrated gastroesophageal reflux, hiatal hernia, and calcified gallstones.

Worsening symptoms of anorexia and weight loss prompted surgical evaluation for cholecystectomy. Because of atypical pain for biliary colic, further work-up was performed. Ultrasound demonstrated a moderate amount of ascitic fluid and cholelithiasis. To exclude mesenteric ischemia, an angiogram was performed. This showed a hypertrophied right gastroepiploic artery and enlarged epiploic branches supplying several hypervascular lesions in the omentum (Fig. 1) with enlarged draining epiploic veins (Fig. 2). Subsequent CT (Figs 3 and 4) showed ascites and abnormal increased small vessels in the omentum corresponding to the regions of hypervascularity identified on the angiogram. A stellate mesenteric pattern was suggested on two images (not shown).

Peritoneal fluid was obtained under ultrasound guidance. Cytologic evaluations using both microscopic and electron microscopic techniques were consistent with mesothelioma. Chest radiograph showed a right pleural effusion and pleural fluid cytology was also positive. With involvement above and below the diaphragm, a diagnosis of Stage III mesothelioma was made. The patient had no known history of asbestos exposure.

* To whom correspondence and reprint requests should be addressed: Deborah S. Granke, M.D., Radiology Service (114), VA Medical Center, 2215 Fuller Road, Ann Arbor, MI 48105, U.S.A.




Fig. 1. Arterial phase of selective common hepatic arteriogram reveals dilated right gastroepiploic artery (arrowheads) and multiple dilated epiploic branch vessels (arrows) supplying four areas of hypervascularity. Fine neovascularity identified in tangle of vessels adjacent to lower edge of liver. G, gastroduodenal artery.

DISCUSSION

Malignant mesothelioma is a rare and nearly uniformly fatal tumor arising from cells of mesodermal origin that line serosal cavities. The incidence of this neoplasm appears to be increasing, both from increased recognition and true increased rate of occurrence [4, 5]. Peritoneal origin is 2-5




Fig. 2. Multiple dilated epiploic veins draining the four hypervascular areas seen in arterial phase. Gastroepiploic vein (V) drains inferiorly into faintly opacified superior mesenteric vein (arrowheads). Ascites demonstrated by displacement of liver edge from chest wall (arrows).




Fig. 3. Abdominal CT with oral and intravenous contrast showing multiple dilated vessels within the omentum (arrowheads). Ascites and incidental gallstones.

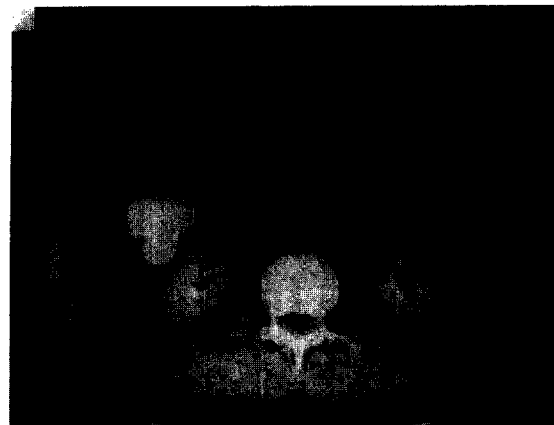


Fig. 4. Omentum defined by innumerable increased small vascular structures (arrowheads). Large draining vein (arrow) coursing towards superior mesenteric vein represents dilated gastroepiploic vein.

times less common than pleural [5]. Association with asbestos exposure appears stronger for peritoneal than pleural primaries [6].

Diagnosis of peritoneal mesothelioma is often delayed until exploratory surgery or autopsy. Presenting symptoms are nonspecific such as vague abdominal pain, weight loss, and abdominal distention. Physical exam may be initially normal or demonstrate ascites but only occasionally an abdominal mass [4–6]. Routine radiographic work-up is often negative or nonspecific. Chest radiographs may show signs of asbestosis in approximately half of these patients and concomitant pleural involvement may be evident [5]. GI studies may show a desmoplastic mesenteric process with or without focal mass effect [7].

Prior CT reports of peritoneal mesothelioma describe involvement of the peritoneum and mesentery that may be extensive [1, 2]. Descriptions include a pleated appearance or stellate pattern of the mesentery with fixation of bowel loops, peritoneal thickening and irregularity and/or a nodular pattern, and mantle-like soft tissue mass in the anterior abdominal cavity in the distribution of the omentum. Ascites and pleural effusion are common. Liver and bone metastases and retroperitoneal lymphadenopathy have been reported. The major differential diagnosis for this CT and gross pathologic appearance is abdominal carcinomatosis and abdominal carcinoid tumor [8].

Our case showed ascites and a suggestion of the stellate mesenteric pattern reported in malignant peritoneal mesothelioma. However, the major CT findings were subtle regions of increased vascularity in the omentum. These corresponded to areas of angiographic hypervascularity. Hypervascularity in peritoneal mesothelioma was recently reported in three angiographic cases [3]. This may represent an early or variant pattern of presentation of peritoneal mesothelioma.

We do not expect this CT appearance of increased vascularity in the omentum to be specific for peritoneal mesothelioma. Non-homogeneity of omental fat also could occur in other conditions including recent surgery, trauma, inflammatory processes, and with vascular or lymphatic obstruction. However, earlier diagnosis of peritoneal mesothelioma may result when the diagnosis is suggested by the radiologist, since specific cytochemical stains and electron microscopic evaluation are needed for pathologic confirmation [9]. Unnecessary surgery may be prevented if specific cytologic preparation leads to an early correct diagnosis.

REFERENCES

1. K. Reuter, V. Raptopoulos, F. Reale, F. J. Krolkowski, C. J. D'Orsi, S. Graham and E. H. Smith, Diagnosis of peritoneal mesothelioma: Computed tomography, sonography and fine-needle aspiration biopsy, *Am. J. Roentg.* **140**, 1189-1194 (1983).
2. N. O. Whitley, D. E. Brenner, K. H. Antman, D. Grant and J. Aisner, CT of peritoneal mesothelioma: Analysis of eight cases, *Am. J. Roentg.* **138**, 531-535 (1982).
3. K. Marini and J. F. Walter, Angiography of omental mesothelioma, *Am. J. Roentg.* **143**, 1075-1077 (1984).
4. C. G. Moertel, Peritoneal mesothelioma, *Gastroenterology* **63**, 346-350 (1972).
5. K. H. Antman, Clinical presentation and natural history of benign and malignant mesothelioma, *Semin. Oncol.* **8**, 313-320 (1981).
6. P. C. Elmers and J. C. Simpson, The clinical aspects of mesothelioma, *Q. J. Med.* **45**, 427-449 (1976).
7. M. P. Banner and V. K. Gohel, Peritoneal mesothelioma, *Radiology* **129**, 637-640 (1978).
8. B. M. Cockey, E. K. Fishman, B. Jones and S. S. Siegelman, Computed tomography of abdominal carcinoid tumor, *J. Comput. assist. Tomogr.* **9**, 38-42 (1985).
9. Y. Suzuki, Pathology of human malignant mesothelioma, *Semin. Oncol.* **8**, 268-282 (1980).

About the Author—DEBORAH S. GRANKE received her B.S. degree in 1976 and her M.D. degree in 1980, both from the University of Michigan. After a year of internship at William Beaumont Hospital in Royal Oak, Michigan, she completed her radiology residency at the University of Michigan in 1984. She is currently a staff member at the Veterans Administration Hospital in Ann Arbor and is an instructor in radiology at the University of Michigan.

About the Author—JAMES H. ELLIS graduated from the University of Michigan Medical School. Following residency in diagnostic radiology at Indiana University Medical Center, he joined the staff of Indiana University Hospital. He is currently Assistant Professor of Radiology at the University of Michigan Medical Center and Chief of the Radiology Service at the Ann Arbor Veterans Administration Medical Center.

About the Author—BRUCE DALE RICHMOND received his B.S. degree from the University of Michigan in 1971 and his M.D. degree from the University of Michigan in 1975. After completing a residency in diagnostic radiology at Indiana University in 1978, he remained on their faculty until 1984. During that time, he was chief of neuroradiology and angiography at the Veterans Administration Hospital. In 1984 he assumed a similar position at the University of Michigan and is currently an assistant professor at that institution. He is the author of numerous scientific publications and exhibits in the area of interventional radiology.