

# Applications of [ $^{131}\text{I}$ ]m-Iodobenzylguanidine ([ $^{131}\text{I}$ ]MIBG)

WILLIAM H. BEIERWALTES

Division of Nuclear Medicine, Department of Internal Medicine, University of Michigan Medical Center,  
Ann Arbor, MI 48109, U.S.A.

The development of the aralkylguanidine [ $^{131}\text{I}$ ]m-iodobenzylguanidine ([ $^{131}\text{I}$ ]MIBG) in the University of Michigan Nuclear Medicine Division has led to diagnostic and therapeutic evaluations of all the neuroendocrine tumors. These tumors share the property of uptake, storage and release of [ $^{131}\text{I}$ ]MIBG uptake in chromaffin granules. This property has allowed the detection of pheochromocytomas, the detection of metastases in 46% of such patients, the treatment of malignant pheochromocytomas, the detection of neuroblastoma metastases, the treatment of neuroblastomas and the detection of a percent of apudomas. We have learned how to improve our results and this is discussed.

## Development of

### [ $^{131}\text{I}$ ]m-Iodobenzylguanidine ([ $^{131}\text{I}$ ]MIBG)

Attempts to use radiolabeled precursors of epinephrine as an imaging agent for adrenergic tumors showed that  $^{14}\text{C}$  dopamine was the most promising and  $^{14}\text{C}$  norepinephrine the second most promising agent (Morales *et al.*, 1976). This led to a series of experiments that attempted to develop radiolabeled dopamine analogs for the diagnosis and treatment of adrenergic tumors (Ice *et al.*, 1975; Beierwaltes *et al.*, 1978). Although promising, none of these agents were sufficiently successful to take to the human. Wieland *et al.* (1979, 1980), utilizing the lead of Counsell developed the first successful agent for humans, [ $^{131}\text{I}$ ]m-iodobenzylguanidine ([ $^{131}\text{I}$ ]MIBG). This compound, a structural analog of guanethidine, has certain structural similarities to norepinephrine. It was shown that the mechanism of uptake of MIBG in catecholamine storage granules in sympathetic nerve endings and the adrenal medulla is almost identical to that of norepinephrine (Wieland *et al.*, 1980). The biological half-life of norepinephrine, however, is only a few hours in the sympathetic nerve endings while that of [ $^{131}\text{I}$ ]MIBG in adrenergic tumors is several days.

## Pheochromocytomas

The [ $^{131}\text{I}$ ]MIBG scan proves that the mass found by CAT scanning in a pheochromocytoma because it has "specific uptake". A CAT scan is relatively insensitive in detecting extra adrenal pheochromocytomas in the abdomen or the chest. The [ $^{131}\text{I}$ ]MIBG scan has excellent sensitivity in localizing pheochromocytomas in both of these areas.

### *In the chest*

Figure 1, a posterior view of [ $^{131}\text{I}$ ]MIBG scintiphoto of the chest, shows the sharp localization of a pheochromocytoma in the region of the upper part of the heart in the mediastinum of a 20 year old woman. This woman, in 1977, developed a classical picture and laboratory evidence diagnostic of pheochromocytoma. In 1978, she had extensive invasive and traumatic studies in two outstanding Medical Centers. These studies included intravenous pyelograms and nephrotomograms, arteriography of the abdomen twice, the pelvis once, the chest once, and blood sampling from the vena cava on three different occasions, CAT scans of the chest and abdomen, tomograms of the mediastinum and mastoids, and finally a non-productive exploratory laparotomy. All of these studies were non-diagnostic and yet her plasma norepinephrine was diagnostic at 16,000 pg/mL (normal  $\leq 300$  pg/mL).

After localization by [ $^{131}\text{I}$ ]MIBG scintigraphy, a thoracotomy resulted in the successful removal of pheochromocytoma, her symptoms disappeared and her plasma and urinary catecholamines returned to normal.

### *In the abdomen*

Figure 2 shows the posterior abdominal [ $^{131}\text{I}$ ]MIBG image demonstrating two areas of uptake between the kidneys (the  $^{99\text{m}}\text{Tc}$ -DTPA was superimposed on the adrenal scan) of a 30 year old patient. This patient illustrates the detection of residual pheochromocytoma tissues post-operatively when the patient has persistent catecholamine excess. The tissue near the left kidney was only 4 mm in diameter and was a persistent or recurrent pheochromo-

cytoma, while the tissue near the right kidney was 2 cm in diameter.

### Malignant Potential of Pheochromocytoma: Implications for Follow-up

Forty-six percent of 176 patients with pheochromocytoma studied at the University of Michigan over the past 5½ years have had metastases (Beierwaltes *et al.*, 1986) compared to the 10% figure usually reported (Mangner and Dufford, 1983). All 176 patients seen had a review of the original histopathology, repeated plasma and urinary catecholamine measurements, [<sup>131</sup>I]MIBG scintigraphy and comparison with other imaging and localizing modalities. For the first 400 patients imaged for pheochromocytomas with [<sup>131</sup>I]MIBG, the sensitivity of [<sup>131</sup>I]MIBG imaging for malignant pheochromocytomas reached 92.4% and the specificity was 100% (Shapiro *et al.*, 1985). The criteria for the diagnosis of the malignant pheochromocytoma were the presence of metastases in the liver, bone, lymph nodes and/or lungs.

A review of the 176 patients with pheochromocytomas reached 92.4% and the specificity 100% (Shapiro *et al.*, 1985). The criteria for the diagnosis. The other half of the patients have had metastases detected. Roughly half of these ( $n = 38$ ) had their metastases detected at the time of the primary operation. The other half ( $n = 43$ ) had their metastases detected later. Reviews of the histopathology of these three groups showed no statistically significant difference histopathologically.

Figure 3 shows the cumulative incidence of detection of metastases ( $n = 81$ ) in percent of patients with malignant pheochromocytomas on the ordinate and time in years after histopathological diagnosis of pheochromocytoma on the abscissa. It is of interest

that the cumulative incidence after the primary surgery was 5% per year for the first 9 y and then 0.6% per year from 9–29 y after the primary surgery. This graph indicates that there is an increasing incidence of demonstrable metastases with the passage of time following surgical removal of the “benign” pheochromocytoma. This observation is accentuated by the additional data that our median follow-up after the first histopathologic proof of a pheochromocytoma was only 2.5 y. In addition, the median period between the primary surgery and the detection of metastases was only 4.2 y.

These figures made us begin to suspect that the duration of follow-up was an additional cause for the higher than reported 10% incidence of malignant pheochromocytoma (in addition to the fact that the majority of the patients referred to us were for known metastases). Our referral pattern gave “instantaneous” longer follow-up. In addition, Freier (1973, 1980) and Thompson (1986) had given us a heritage of carefully followed patients. Most importantly, we began to discover that metastases were detected in some of our own patients on whom metastases had not been detected during the first year of study. [<sup>131</sup>I]MIBG occasionally detected metastases not detected by all other diagnostic or localizing modalities. The following are brief summaries of four of these patients.

The first patient illustrates a positive [<sup>131</sup>I]MIBG scan with normal catecholamines. This patient also demonstrates the Armed Forces Fascicle No. 9 statement that in effect all adrenergic tissue is embryologically paragangliomas, including the normal adrenals (Glenner and Grimly, 1973).

The second patient showed normalization of catecholamines during [<sup>131</sup>I]MIBG treatment for malignant pheochromocytoma metastases but [<sup>131</sup>I]MIBG imaging remains positive.

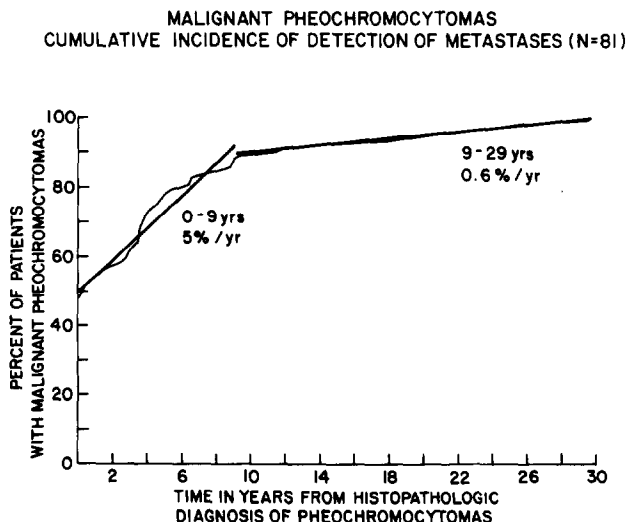


Fig. 3. Cumulative incidence of detection of metastases ( $n = 81$ ) in percent of patients with malignant pheochromocytomas, on the ordinate and time in years after histopathological diagnosis of pheochromocytoma on the abscissa.

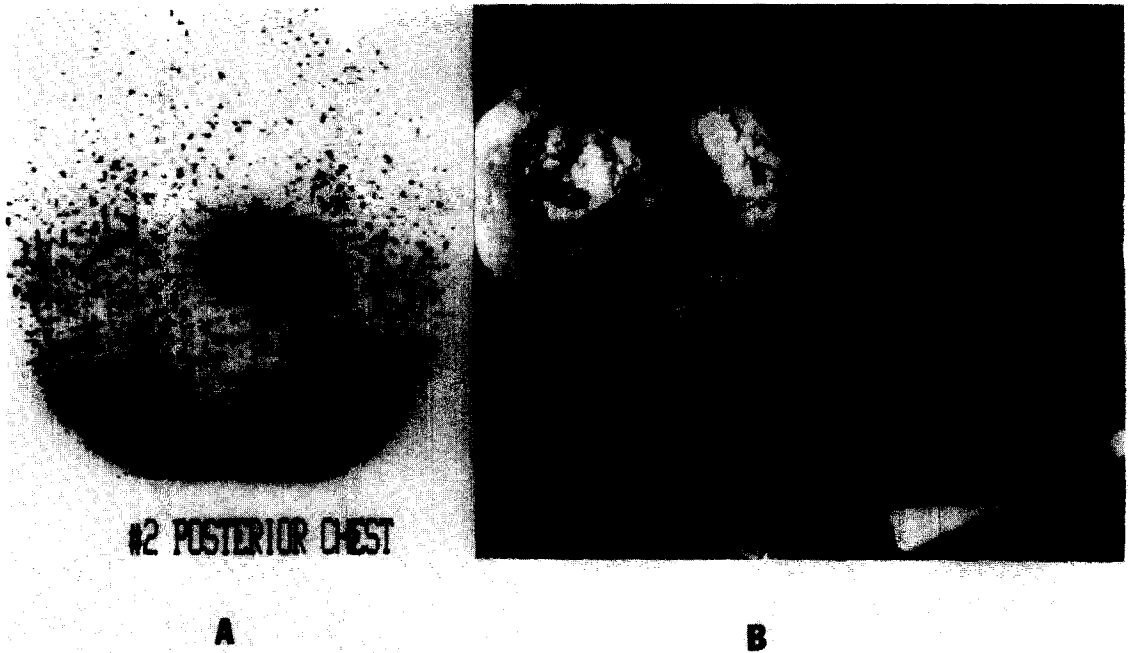


Fig. 1. Posterior view of MIBG scintiphoto of the chest, showing sharp localization of a pheochromocytoma in the region of the upper part of the heart in the mediastinum of a 20 year old woman.




Fig. 2. Posterior abdominal MIBG image localizing two areas of uptake between the kidneys (imaged with DTPA and superimposed on the MIBG scintigram in a patient who had recurrent symptoms of pheochromocytoma after an apparent "cure" by removal of a pheochromocytoma. Upon operation, the tissue near the left kidney was a pheochromocytoma 4 mm in diameter and the pheochromocytoma near the right kidney was 2 cm in diameter.

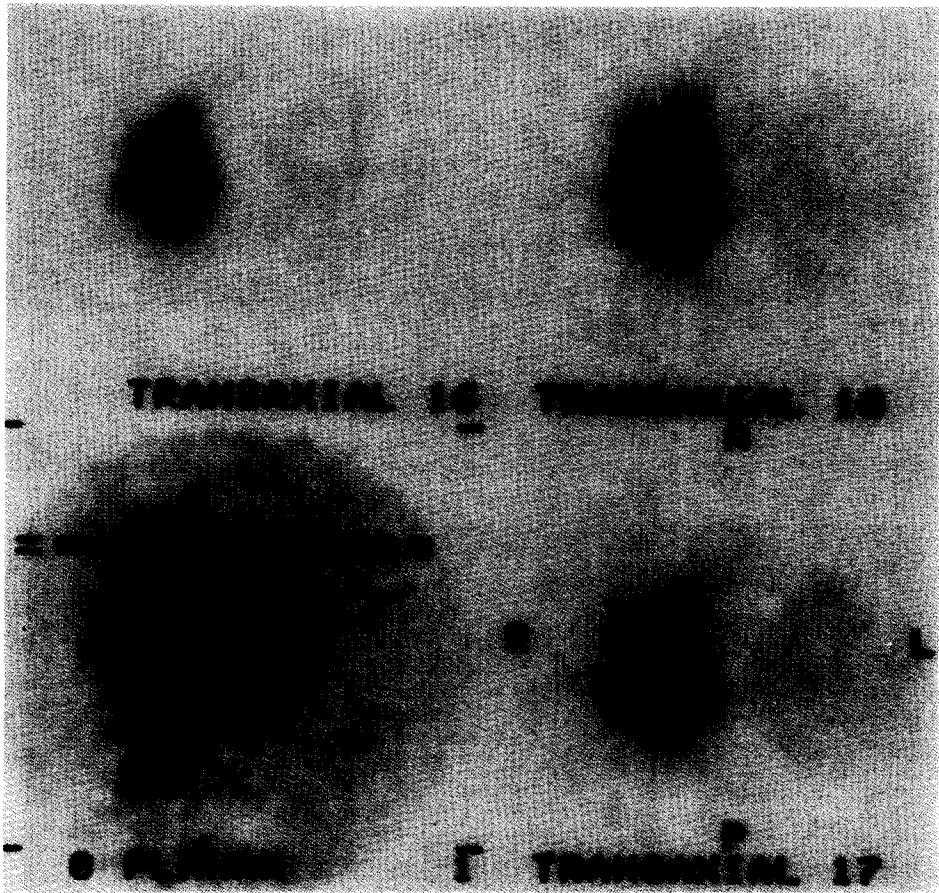


Fig. 4. Shows a single photon tomography scintiphoto with MIBG of a malignant pheochromocytoma. Uptake of MIBG shows that much of the mass does not concentrate MIBG, probably due to necrosis (but possibly also to heterogeneity of uptake).

The third patient showed development of metastases during our follow-up, more bone metastases than could be detected by bone scan or CAT scan, and pain as the presenting symptom after three months of normal plasma urinary catecholamines and 1.25 years after a normal [<sup>131</sup>I]MIBG image.

The fourth patient showed metastases detected coincidental to a work-up for an intercurrent illness.

Because of the findings illustrated by these patients, we have begun to obtain yearly [<sup>131</sup>I]MIBG scans on all patients after primary surgery for removal of a benign pheochromocytoma.

### [<sup>131</sup>I]MIBG Treatment of Adrenal Malignant Pheochromocytomas

The hypotheses and goals in using [<sup>131</sup>I]MIBG for the treatment of unresected pheochromocytomas (Sisson *et al.*, 1983, 1984) were based on the fact that this treatment would result in less symptoms, lower blood pressure, reduced catecholamine secretion, and smaller tumors without significant toxicity to the bone marrow and the autonomic nervous system. The criteria used to select patients for this treatment were based on tracer dose studies that further indicated that tumors would receive greater than 2000 cGy/3.7 GBq (2000 rad/100 mCi conjugate view daily quantitation of radioactivity in tumor, two dimensional CAT scans quantitation of volume of tumors) doses. Lastly, the criteria for selection included that the tumors were not likely to be lethal to the patients in one year, in order to give them time to benefit from the therapy dose so that they can return for second, third or fourth treatments if necessary.

The results of our treatment of the first five patients with malignant pheochromocytomas were particularly interesting because the first two patients enjoyed objective responses while the next three had no objective response. The responders were both over 60 years of age and the nonresponders were all under 34 years of age. The metastases in the two responders were in soft tissues and the metastases in the nonresponders were in bone. The responders demonstrated growth of their metastases in the preceding year, with the first patient showing almost a doubling of tumor size during the previous year. The nonresponders showed no growth in the first two and doubtful growth in the third patient. The responders both received over 15,000 cGy and the non-

responders all received under 13,000 cGy cumulative dosage. We were handicapped in the first two patients because we did not want to give over 5 mg of [<sup>131</sup>I]MIBG, and thus the patients received under 3.7 GBq (100 mCi), in each of the first two doses. Fortunately, the first patient showed 55% of his administered dose in the abdominal tumor at 24 h and the <sup>131</sup>I had a biologic half life of 4.8 days with  $t_{1/2\text{eff}}$  at 3.0 days for a dose of 8000 cGy for 3.6 GBq (97 mCi). At this time the volume of his abdominal tumor was 327 cm<sup>3</sup>. After the fourth dose the size of the tumor had decreased to 140 cm<sup>3</sup>. It is of importance that the biologic half-life decreased after each dose from 4.8 to 2.7 to 2.0 to 1.6 days, respectively. As a result, his rad dose progressively decreased. Nevertheless, he received a total dose of 19,790 cGy. This decreasing half-life and uptake of each successive dose is also true in the treatment of well-differentiated thyroid cancer with sodium <sup>131</sup>I.

Our conclusions were that [<sup>131</sup>I]MIBG will produce clinical and laboratory benefits in some patients with malignant pheochromocytomas. Untoward responses have been absent or modest. Predictors of success were uncertain but high rad dose was necessary.

### [<sup>131</sup>I]MIBG Treatment of Neuroblastomas

Present methods of staging neuroblastoma are imperfect. Failure to respond to "appropriate" therapy may be due to errors of staging. [<sup>131</sup>I]MIBG is a more sensitive method of staging than all modalities in some cases (Geatti *et al.*, 1985).

We have found that [<sup>131</sup>I]MIBG has been more sensitive than all imaging modalities in differentiating stage I and II. Three out of the first eleven patients treated for neuroblastoma have had an objective remission as shown by pre- and post-treatment CAT scans. These three responders had the slowest growth of the tumor of any of the first 11 patients who were treated. They also received the largest doses (approximately 200 mCi (7.4 GBq)) given three times to each patient. We are now making arrangements to give [<sup>131</sup>I]MIBG as the first treatment in the patients found by serum studies to have a poor prognosis. Patients with a good prognosis will have [<sup>131</sup>I]MIBG administered if they fail to respond to conventional methods of treatment.

Table 1. <sup>131</sup>I Distribution in tumors

	[ <sup>131</sup> I]MIBG in <sup>a</sup> malignant pheochromocytoma	[ <sup>131</sup> I]Fab <sup>b</sup> fragments in malignant melanoma
Percent dose/g	0.18	0.04
Maximum $T_{1/2}$ (days)	4.8	2.0
Percent dose uptake/tumor	55.0 (solid & cystic)	17.2 (solid parts only)
Maximum tumor:liver ratio	680:1	2:1
Maximum tumor dose in rad/100 mCi	8000	1000

<sup>a</sup>Sisson *et al.* (1984) *J. Nucl. Med.* **24**, 197.

<sup>b</sup>Larson (1983) *J. Clin. Invest.* **72**(6), 2101.

### **[<sup>131</sup>I]MIBG in Neuroendocrine Tumors other than Pheochromocytomas and Neuroblastomas**

Shapiro *et al.* (1986) reported that good imaging of carcinoids in the first four of ten patients, three of three non-secreting paragangliomas, one of five sporadic medullary thyroid cancers, and one of 25 familial medullary thyroid cancers.

Recently, the uptake of [<sup>131</sup>I]MIBG in two of five chemodectomas, none of four oat cell carcinomas, one of one choriocarcinomas, one of one atypical schwannoma, one of one Merkel cell skin cancer, and none of one eye lid cell carcinoma has been demonstrated by scintigraphy. We have a diagnostic and therapeutic IND for the continued diagnosis and therapy of apudoma patients.

#### *Comparison of possible therapeutic parameters with <sup>131</sup>I labeled monoclonal antibodies*

Table 1 shows that the usual parameters for evaluating the possible therapeutic benefit from [<sup>131</sup>I]MIBG are strikingly better (Sisson *et al.*, 1984) than when these parameters are applied to the treatment of malignant melanomas with a radioiodinated monoclonal antibody fragment to the P-97 antigen in malignant melanomas. The percent dose of [<sup>131</sup>I]MIBG per gram localizing the tumor is an order of magnitude greater than with the [<sup>131</sup>I]P-97-MOAb. The biological half-life is twice as long, the percent dose uptake per tumor mass is more than twice as great, and the maximum tumor to liver ratio is orders of magnitude higher with [<sup>131</sup>I]MIBG than with the MOAb. As a result, the maximum tumor dose in cGy (rad)/100 mCi (3.7 GBq) is 8000 cGy from [<sup>131</sup>I]MIBG compared to 1000 cGy with the monoclonal antibody.

### **The Future of [<sup>131</sup>I]MIBG**

We are now using single photon tomography to refine the calculation of the absorbed rad dose to actively metabolizing cells. Figure 4 shows a single photon tomography image with [<sup>131</sup>I]MIBG of a patient with malignant pheochromocytoma. If this image demonstrates the abdominal mass in patient 1 and if these images show that only 1/10 of the abdominal tumor was actively concentrating and metabolizing the [<sup>131</sup>I]MIBG, the dose to the tumor in this patient is calculated to be 19,790 cGy, assuming uniform distribution of the [<sup>131</sup>I]MIBG throughout the tumor. If the single photon tomography with [<sup>131</sup>I]MIBG had shown that 10% of the total tumor was actively metabolizing cancer cells, then the total of the absorbed dose might be 10 × 19,790 cGy or 197,900 cGy.

A second potential application for [<sup>131</sup>I]MIBG is demonstrated by a second patient that was treated for malignant pheochromocytoma who showed marked regression of liver metastases. This patient was the only patient with this disease exhibiting an increase in uptake of [<sup>131</sup>I]MIBG with each successive therapy

dose and was the only patient whose urine showed 5 hydroxylated [<sup>131</sup>I]MIBG. We are therefore searching for metabolic differences between those that might be good responders and those that might be poor responders.

Devita (1983) emphasized that cancer chemotherapy is at its best in the treatment of rapidly growing cancers. Unfortunately, slow growing cancers account for most cancer deaths. These slow growing cancers are carcinoma of bowel, the lung, prostate and breast. Radiopharmaceutical treatment of cancer, on the other hand, is at its best in the slow growing cancers. For example, sodium [<sup>131</sup>I]iodide for treating metastatic thyroid cancer and [<sup>131</sup>I]MIBG for treating metastatic carcinoma of the adrenal medulla, neuroblastomas and possibly for apudomas have been shown to be effective therapeutic agents.

*Acknowledgements*—I am indebted to Doctors J. Sisson and B. Shapiro in our Nuclear Medicine Division and to R. Hutchison in Pediatric Oncology for their handling and data collection in most of these patients. Mrs Vi Rhodes typed and expedited the processing of this manuscript.

### **References**

- Beierwaltes W. H., Wieland D. M., Yu T., Swanson D. P. and Mosley S. T. (1978) Adrenal imaging agents: Rationale, synthesis, formulation and metabolism. *Semin. Nucl. Med.* **8**, 5.
- Beierwaltes W. H., Sisson J. C., Shapiro B. and Lloyd R. V. (1986) Malignant potential of pheochromocytoma (P): Implications for follow-up. *Clin. Res.* **34**, 713A.
- DeVita V. T. Jr (1983) The James Ewing Lecture: The relationship between tumor mass and resistance to chemotherapy. Implications for surgical adjuvant treatment of cancer. *Cancer* **51**, 1209.
- Freier D. T. and Harrison T. S. (1973) Rigorous biochemical criteria for the diagnosis of pheochromocytoma. *J. Surg. Res.* **14**, 177.
- Freier D. T., Eckhauser F. E. and Harrison T. S. (1980) Pheochromocytoma: A persistently problematic and still potentially lethal disease. *Arch. Surg.* **115**, 388.
- Geatti O., Shapiro B., Sisson J. C., Hutchinson R. J., Mallette S., Eyre P. and Beierwaltes W. H. (1985) <sup>131</sup>I metaiodobenzylguanidine (131-I-MIBG) scintigraphy for the location of neuroblastoma: Preliminary experience in 10 cases. *J. Nucl. Med.* **26**, 736.
- Glenner G. G. and Grimly P. M. (1973) Tumors of the extraadrenal paraganglioma system (including chemoreceptors). *Atlas of Tumor Pathology*, second series, Fascicle 9. Armed Forces Institute of Pathology, Washington, D.C.
- Ice R. D., Wieland D. M., Beierwaltes W. H., Lawton R. G. and Redmond M. J. (1975) Concentration of dopamine analogs in the adrenal medulla. *J. Nucl. Med.* **16**, 1147.
- Mangner W. M. and Dufford R. W. Jr (1983). Hypertension secondary to pheochromocytoma. *Bull. N.Y. Acad. Med.* **58**, 139.
- Morales J. O., Beierwaltes W. H., Counsell R. E. and Meier D. E. (1976) The concentration of radioactivity from labeled epinephrine and its precursors in the dog adrenal medulla. *J. Nucl. Med.* **8**, 800.
- Shapiro B., Copp J. E., Sisson J. C., Eyre P. L. and Beierwaltes W. H. (1985) <sup>131</sup>I-metaiodobenzylguanidine for the locating of suspected pheochromocytoma. Experience in 400 cases. *J. Nucl. Med.* **26**, 576.
- Shapiro B., Von Moll L., McEwan A., Sisson J. C., Gross

- M., Beierwaltes W. H. and Thompson N. (1986) I-131-meta-iodobenzylguanidine (MIBG) uptake by a wide range of neuroendocrine tumors other than pheochromocytoma and neuroblastoma. *J. Nucl. Med.* **27**, 908.
- Sisson J. C., Shapiro B., Beierwaltes W. H., Nakajo M., Glowniak J. V., Mangner T., Carey J. E., Swanson D. P., Copp J., Satterlee W. and Wieland D. (1983) Treatment of malignant pheochromocytoma with a new radiopharmaceutical. *Trans. Assoc. Am. Phys.* **96**, 209.
- Sisson J. C., Shapiro B., Beierwaltes W. H., Glowniak J. V., Nakajo M., Mangner T. J., Carey J. E., Swanson D. P., Copp J. E., Satterlee W. G. and Wieland D. M. (1984) Radiopharmaceutical treatment of malignant pheochromocytoma. *J. Nucl. Med.* **24**, 197.
- Wieland D. M., Swanson D. P., Brown L. E. and Beierwaltes W. H. (1979) Imaging the adrenal medulla with an I-131-labeled antiadrenergic agent. *J. Nucl. Med.* **20**, 155.
- Wieland D. M., Wu J. L., Brown L. E., Mangner T. J., Swanson D. P. and Beierwaltes W. H. (1980) Radio-labeled adrenergic neuron blocking agents: Adrenomedullary imaging with [<sup>131</sup>I]-iodobenzylguanidine. *J. Nucl. Med.* **21**, 349.