



SPECT IMAGING OF MOYAMOYA DISEASE USING ^{99m}Tc -HM-PAO COMPARISON WITH COMPUTED TOMOGRAPHY FINDINGS

JAMES M. MOUNTZ, MD, PhD, NORMAN L. FOSTER, MD,
ROBERT J. ACKERMANN, CNMT, LAURIE BLUEMLEIN, BSN,
MS, NEIL A. PETRY, MS, RPh AND DAVID E. KUHL, MD

^{99m}Tc -HM-PAO was used to evaluate regional cerebral blood flow in a 26-year-old woman with Moyamoya disease. This patient had an 18-month history of recurrent neurologic deficits and had angiographic evidence of Moyamoya disease. She had used oral contraceptives and cigarettes, but had no other risk factors for stroke. Single photon emission computed tomographic images showed bilateral and asymmetric reductions in blood flow to anterior and lateral brain regions. These findings correlated better with clinical symptomatology and suggested more extensive brain involvement than did computed tomography.

KEY WORDS:

SPECT; ^{99m}Tc -HM-PAO; Moyamoya; Stroke

Cerebral blood flow imaging with single photon emission computed tomography (SPECT) has proven useful in the evaluation of stroke and transient ischemia attacks (1-4). Although several radionuclide blood flow agents are used for SPECT imaging of the brain, we chose the compound ^{99m}Tc -HM-PAO because it depicts excellent blood flow images (5), has more counts per administered

dose compared with the ^{123}I -labeled compounds, and can be easily prepared from a kit that is injected with sodium pertechnetate obtained from a standard $^{99}\text{Mo}/^{99m}\text{Tc}$ generator.

Moyamoya disease is a rare cause of stroke that can present clinically in young adults as chronic progressive ischemia or recurrent stroke (6,7). Cerebral angiography characteristically shows narrowing or occlusion of the distal internal carotid arteries associated with a profuse vascular network in the basal ganglia. Cerebral hemodynamics in patients with Moyamoya disease usually show a pattern of bilateral low mean hemispheric blood flow with low regional blood flow to the frontal hemispheres (8).

CASE REPORT

A 26-year-old right-handed woman was well until 18 months prior to admission when she developed recurrent, transient episodes of right arm numbness and weakness and difficulty with her speech. Three months prior to admission the patient awoke with left leg weakness and incoordination that slowly improved. At the time of admission the patient had a new episode of left arm and leg weakness and numbness and difficulty with speech. The neurologic examination demonstrated a nonfluent aphasia, and there was weakness and numbness involving the entire left arm and leg as well as residual neurologic impairment involving the right side of the body. She had been taking oral contraceptives and smoking two packs of cigarettes per day. A cranial computed tomography (CT) scan was performed (Figure 1) at the time of the SPECT scan and showed a small left centrum semiovale lacunar infarct and an

From the Department of Internal Medicine, the Division of Nuclear Medicine, and the Department of Neurology, University of Michigan Medical Center, Ann Arbor, Michigan.

Address reprint requests to: James M. Mountz, MD, PhD, Assistant Professor of Internal Medicine, University of Michigan Medical Center, Department of Internal Medicine, Division of Nuclear Medicine, Ann Arbor, Michigan 48109-0028.

Received October 1987.

© 1988 by Elsevier Science Publishing Co., Inc.
655 Avenue of the Americas, New York, NY 10010
0149-936X/88/\$3.50

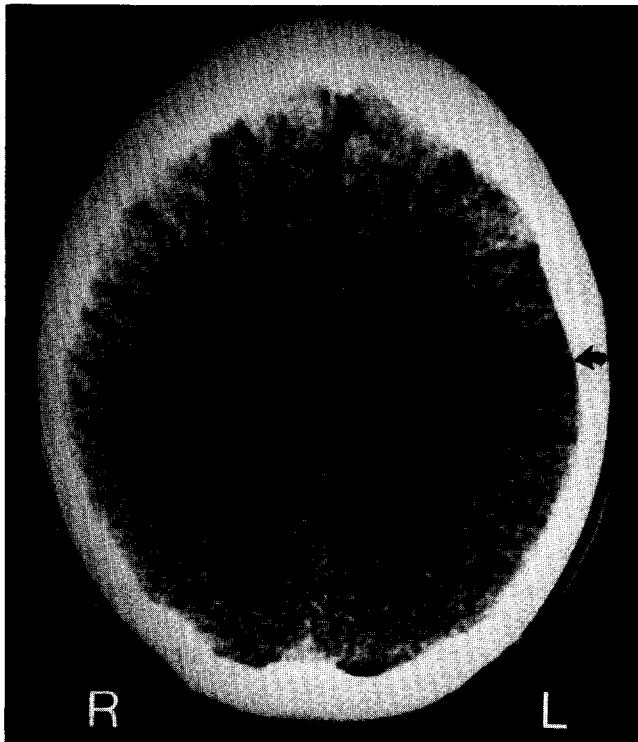

FIGURE 1. CT transverse section of the brain showing a region of low attenuation in the high left parietal lobe (arrow) representing the left parietal infarction. The small left centrum semiovale lacunar infarct is seen just medial to the cortical infarct.

area of cortical substance loss in the high left mid-parietal region consistent with an old infarction. A cerebral angiogram was performed (Figure 2) that showed bilateral narrowing of the supraclinoid arteries, measured to be 30% of normal diameter on the right and 20% of normal diameter on the left. There was a prominent collateral network of vessels extending into the basal ganglia (the Moyamoya vessels).

METHODS

^{99m}Tc -Hexamethylpropyleneamine oxime (^{99m}Tc -HM-PAO) (Ceretek, Amersham Corporation, Arlington Heights, IL) is a new lipophilic brain bloodflow imaging agent with high brain uptake and retention without evidence of redistribution for at least 8 hours (5, 9–11). The utilization of ^{99m}Tc -HM-PAO in patients with stroke was approved by the Human Studies Committee of the University of Michigan.

Unit dose kits for the preparation of ^{99m}Tc -HM-PAO were supplied by the Amersham Corporation and were reconstituted with 25–30 mCi of sodium pertechnetate in 5 mL of sterile saline eluted from

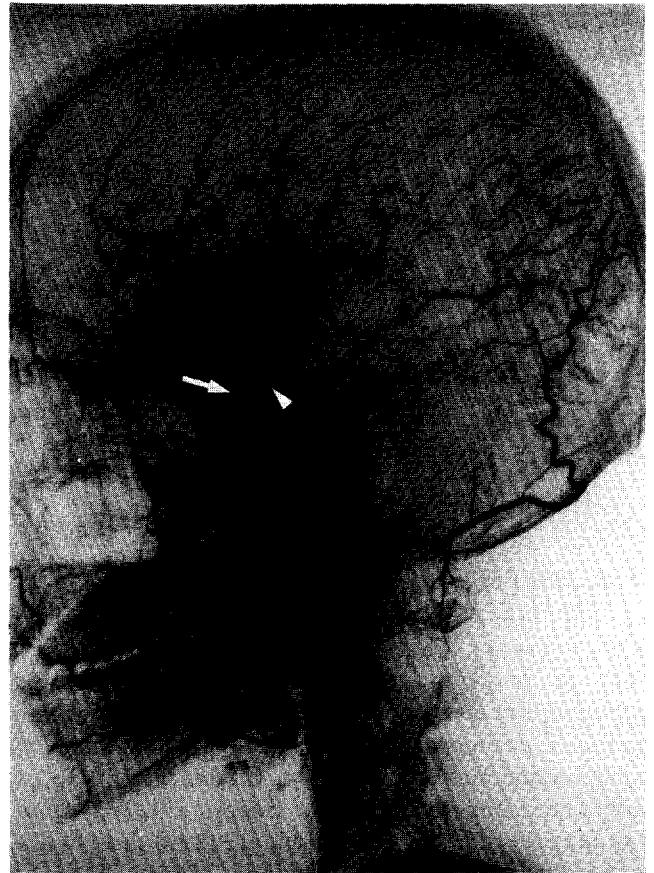


FIGURE 2. Lateral skull angiogram showing narrowing of the supraclinoid portions of the internal carotid artery (arrow) and the Moyamoya vessels (arrowhead).

a commercially available $^{99}\text{Mo}/^{99m}\text{Tc}$ generator. Chromatographic analysis at the time of administration indicated that 98% of the administered activity was associated with the desired lipophilic ^{99m}Tc -HM-PAO complex. After receiving IV bolus of 19.8 mCi of ^{99m}Tc -HM-PAO, imaging was performed using a General Electric 400AC gamma camera equipped with an all-purpose collimator interfaced to a Siemens Micro-Delta computer. Five million total counts were obtained over 64 angular views, 25 sec/stop, 64 stops.

Regions of Interest and Qualitative Estimation of Cerebral Blood Flow

Computed tomographic volume sizes were determined by hand drawing regions around brain tissue loss (presumed infarcted), summing the areas, and multiplying by the CT plane width. For quantification of cerebral blood flow, arterial sampling needs to be performed to provide the tracer input function to the brain for the application of a kinetic model

(12). Because arterial sampling was not done, a qualitative analysis was performed by comparing ratios of tracer uptake in regions of suspected abnormality with the tracer uptake within the whole slice containing the abnormality. These ratios were compared with ratios obtained from mirrored regions of interest taken from the contralateral hemisphere. Volume sizes on the SPECT images were determined by hand drawing regions around areas of visibly decreased tracer activity (presumed to be regions of diminished blood flow) on each image and summing the total pixels (1 pixel = 0.625 cm³).

RESULTS

The ^{99m}Tc-HM-PAO SPECT scan showed a flow defect involving a large portion of the left parietal cortex, with a second focal area of decreased flow in the "watershed" area of the left anterior cerebral/middle cerebral arteries (Figure 3). The scan also showed slightly diminished tracer uptake involving the right parietal and frontal cortex. The size of the area of decreased flow in the mid-left parietal region seen on the SPECT images was much larger than suggested by the CT scan. The size of the region of decreased flow was measured to involve 78 cm³ of

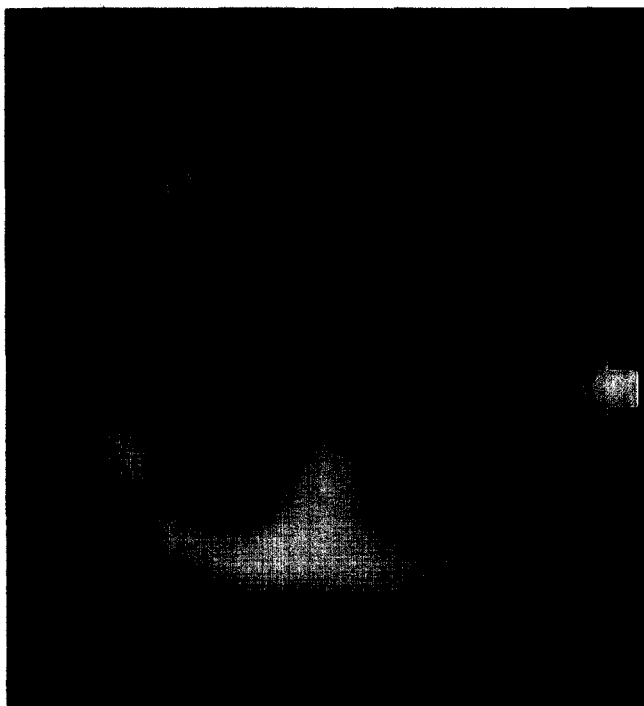

FIGURE 3. ^{99m}Tc-HM-PAO SPECT scan, transverse section showing region of decreased flow in the midleft parietal cortex (arrow) and anterior left frontal-parietal region (arrowhead). The right parietal and frontal cortex also demonstrates slightly decreased tracer uptake.

brain, while the size of cortical volume loss presumed due to infarction measured by CT was 3.4 cm³. The parietal cortex flow ratio, measured through the region of abnormality from the coronal projection, was left to right, .66, representing a significant diminution of flow to the left parietal cortex compared with the flow in the corresponding region of the right parietal cortex.

DISCUSSION

^{99m}Tc-HM-PAO is a new brain bloodflow tracer that has the ideal radiopharmacologic properties of ease of preparation, relatively high brain uptake, and stability in the brain (10). It also has the ideal imaging properties associated with its 140 keV gamma emission, which is routinely imaged by the standard Anger gamma camera. These advantages allow the tracer to provide excellent images of cerebral blood flow without the limitations of some of the earlier agents (5).

Moyamoya disease is a relatively rare disease that usually presents as progressive ischemia or stroke in children. The case presented here is unusual because our patient was older. In addition, the patient was taking oral contraceptives and smoked two packs of cigarettes per day. These two factors appear to increase the risk of developing Moyamoya in young women, and it has been suggested that improvement occurs when those factors are discontinued (13). Follow-up serial examinations of cerebral blood flow in these patients using ^{99m}Tc-HM-PAO SPECT might provide objective evidence of this pathogenetic mechanism. Noninvasive determination of regional blood flow by SPECT was superior to CT in demonstrating the extent and location of this patient's neurologic impairment. The SPECT images showed bilaterally decreased anterior brain circulation (explaining both the right- and left-sided symptoms), and, unlike the CT scan, demonstrated a lesion in the left anterior/middle cerebral artery distribution, explaining the patient's nonfluent aphasia. The larger area of flow deficit in the left parietal region was a better reflection of the significant loss of both upper and lower extremity sensory and motor function on the right side of the body, whereas CT suggested a lesser deficit. Moyamoya causes progressive ischemic changes due to gradual narrowing of proximal portions of the major intracranial vessels. The slow development of this narrowing permits collateral circulation to develop, in part, to compensate for these changes. If collaterals prove to be completely insufficient, infarction develops and deficits become fixed with correspond-

ing loss of brain substance, as represented in the left parietal region in our patient. On the other hand, when collateral development is insufficient to permit adequate perfusion, but adequate to prevent infarction, deficits are reversible and do not cause loss of structural integrity. Consequently, Moyamoya disease serves as an ideal clinical model for reversible ischemic neurologic deficits. Such ischemic regions are well documented in the present study, both in the "penumbra" surrounding the left parietal infarct seen by CT and in the right hemisphere where clinical symptoms developed with intermediate decreases in blood flow but without tissue destruction. Thus, in this patient the ^{99m}Tc -HM-PAO SPECT study both presages the extent of brain subject to future infarction and offers a noninvasive method of evaluating benefits from further therapeutic interventions.

CONCLUSION

^{99m}Tc -HM-PAO SPECT scanning of the brain can be easily performed and yields clinically relevant information about regional cerebral blood flow. The areas of abnormality seen on SPECT scanning appear more extensive than revealed by CT scanning alone, and more closely reflect the nature and probable source of the patient's symptoms. By providing a noninvasive method of measuring blood flow, the cause of Moyamoya disease and its response to therapy can be further evaluated.

The secretarial assistance of Ms. Michele Curro and Mrs. Annise Johnson is greatly appreciated. We express gratitude to Ms. Meribeth Adams for her assistance in this work and extend our appreciation to the Amersham Corporation for providing the radiopharmaceutical. This work was supported in part by the USPHS Research Grant #5 R01-NS24896.

REFERENCE

1. Brott TG, Gelfand MJ, Williams CC, Spilker JA, Hertzberg VS. Frequency and patterns of abnormality detected by Iodine-123 amine emission CT after cerebral infarction. *Radiology* 1986;158:729-34.
2. Hill TC, Magistretti PL, Holman BL, et al. Assessment of regional cerebral blood flow (rCBF) in stroke using SPECT and N-isopropyl-(I-123)-p-iodoamphetamine (IMP). *Stroke* 1984; 15(1):40-5.
3. Holman BL, Hill TC, Polak JF, et al. Cerebral perfusion imaging with Iodine 123-labeled amines. *Arch Neurol* 1984; 41:1060-3.
4. Burt RW, Reddy RV, Mock BM, et al. Acetazolamide enhancement of HIPDM brain flow distribution imaging. *J Nucl Med* 1986; 27:1627-31.
5. Podreka I, Suess E, Goldenberg G, et al. Initial experience with technetium-99m HM-PAO brain SPECT. *J Nucl Med* 1987; 28:1657-66.
6. Wood CH, Jeans WD, Coakham HB. Case report, Moyamoya disease: An unusual cause of cerebral infarction. *Clin Radiol* 1986; 37:289-92.
7. Fukuyama Y, Umezu R. Clinical and cerebral angiographic evolutions of idiopathic progressive occlusive disease of the circle of Willis ("Moyamoya" disease) in children. *Brain Dev* 1985; 7:21-37.
8. Takeuchi S, Tanaka R, Ishii R, et al. Cerebral hemodynamics in patients with Moyamoya disease. *Surg Neurol* 1985; 23:468-74.
9. Ell PJ, Hocknell JML, Jarritt PH, et al. A ^{99m}Tc -labelled radiotracer for the investigation of cerebral vascular disease. *Nucl Med Comm* 1985; 6:437-41.
10. Sharp PF, Smith FW, Gemmell HG, et al. Technetium 99m HM-PAO stereoisomers as potential agents for imaging regional cerebral blood flow: Human volunteer studies. *J Nucl Med* 1986; 27:171-7.
11. Holmes RA, Chaplin SB, Royston KG, et al. Cerebral uptake and retention of ^{99m}Tc -hexamethylpropyleneamine oxime (^{99m}Tc -HM-PAO). *Nucl Med Comm* 1985; 6:443-47.
12. Kuhl DE, Barrio JR, Huang S-C, et al. Quantifying local cerebral blood flow by N-isopropyl-p-[^{123}I] iodoamphetamine (IMP) tomography. *J Nucl Med* 1982; 23:196-203.
13. Levine SR, Knake JE, Young AB. Atypical progressive stroke syndrome associated with oral contraceptives and cigarette use. *Stroke* 1987; 18:519-23.