

CASE REPORT

Malignant Placental Site Trophoblastic Tumor Associated with Placental Abruption, Fetal Distress, and Elevated CA-125

MICHAEL P. HOPKINS, M.D.,*¹ CHARLES W. DRESCHER, M.D.,* ANNE McQUILLAN, M.D.,† JOHN KEYSER, M.D.,‡
AND ROBERT SCHMIDT, M.D.†

*Departments of *Obstetrics & Gynecology and †Pathology, University of Michigan Medical Center, Ann Arbor, Michigan;
and ‡Port Huron Hospital, Port Huron, Michigan*

Received February 12, 1992

The second pregnancy of 27-year-old woman, gravida 2, para 2 was complicated by a low α -fetoprotein and symptoms of chronic placental abruption. She delivered by cesarean section at 35 weeks for fetal distress at which time a biopsy of the uterus revealed a placental site trophoblastic tumor (PSTT). She rapidly developed intraabdominal spread of the neoplasm which did not respond to chemotherapy and she died 10 weeks later. Her CA-125 was elevated to 5360 u/ml and this decreased after hysterectomy. This patient is reported to highlight a very malignant course of PSTT that was associated with a live-born male infant.

© 1992 Academic Press, Inc.

INTRODUCTION

Placental site trophoblastic tumor (PSTT) was described in 1976 as a probably benign tumor [1]. Initially called pseudotrophoblastic tumor, reports of 10 patients with metastases who succumbed to their disease have led to a different philosophy concerning the benign course of this tumor. Thus, it is currently called placental site trophoblastic tumor [2-12]. The PSTT is thought to arise from the placental implantation site. It is usually diagnosed at some interval after pregnancy, and it is most frequently associated with what is thought to be a spontaneous abortion. There has been only 1 case reported in which PSTT was diagnosed in conjunction with a potentially viable fetus. This patient, reported by Finkler *et al.*, was at 21 weeks estimated gestational age when she spontaneously lost the pregnancy [5]. Recently we treated a patient with PSTT who was diagnosed at cesarean sec-

tion performed for placental abruption. The patient is being reported on in detail to highlight the malignant course of her PSTT and the previously unreported association of this disease with a viable pregnancy and an elevated serum CA-125.

CASE REPORT

N.K., a 27-year-old, gravida 2, para 2 woman, delivered her first child, a normal female, by low transverse cesarean section for failure to progress 2 years prior to the present pregnancy. Her uterus and placenta were normal at that time and her postoperative course was unremarkable. Normal regular menses resumed after the first pregnancy. She conceived again 2 years later without difficulty and was initially seen at 8 weeks estimated gestational age. Pelvic examination was appropriate for gestational age and routine prenatal laboratory studies were normal. An α -fetoprotein performed at 14 weeks was 10.2 IU/ml, which was 0.4 multiples of the median (normal range, 0.5 to 2.2 multiples of the median). After full genetic consultation the patient underwent an amniocentesis. The amniocentesis showed a normal 46XY karyotype. Ultrasound at the time of amniocentesis was normal and the posterior placenta appeared normal. The pregnancy proceeded uneventfully until 30 weeks estimated gestational age when the patient began to experience vaginal bleeding and cramping. An ultrasound at this time showed a posterior echogenic area in the region of the cervix thought to be a fibroid. Over the next 5 weeks, she experienced intermittent fevers to approximately 39°C. She was also admitted three times for bleeding. The diagnosis of a small but chronic abruption was made based on the clin-

¹ To whom reprint requests should be addressed at Northeastern Ohio Universities College of Medicine, 400 Wabash Avenue, Akron, Ohio 44307.

ical parameters. No etiology for the fever could be determined. At 35 weeks estimated gestational age, the patient was admitted with increasing uterine contractions and vaginal bleeding. Biophysical profile disclosed oligohydramnios and evidence for fetal distress. The patient was delivered by emergency vertical cesarean section of a live-born male weighing 5 lb. 8 oz. He is now 24 months old and normal. The uterus appeared thickened and abnormal with a "cardboard-like appearance" at the time of delivery. A myometrial biopsy showed PSTT.

The patient's postoperative course was unremarkable for the first 4 days. She then began to have daily temperature elevations to 39–40°C. She did not respond to penicillin, gentamycin, and clindamycin antibiotic therapy. A CAT scan suggested an abscess. Surgical reexploration disclosed that only peritoneal fluid and cultures were negative. No abscess was identified at this time. The patient continued to have an elevated baseline temperature at approximately 38°C with nightly temperature elevations to 39–40°C. Intravenous heparin was added to the antibiotic therapy without improvement in the temperature curve. Because of the patient's continuing febrile course as well as the established diagnosis of PSTT, the patient was transferred to the University of Michigan Medical Center (UMMC). Upon admission to the UMMC, the patient had nightly febrile episodes to 40°C which did not respond to ampicillin, tobramycin, and Flagyl antibiotic therapy. Multiple cultures from all sites failed to identify an infectious source. Pelvic examination revealed an enlarged uterus that was not involuting at the expected rate. The cervix appeared abnormal and multiple nodules were palpated in the posterior vaginal wall. Biopsies of the cervix, as well as the vagina, showed PSTT. The source for the patient's fever was thought to be a large amount of necrotic PSTT in the uterus. Three weeks following her cesarean section she was again surgically explored. At the time of this surgery, the patient's abdomen was remarkably different from what had previously been found. At the time of cesarean section, the abdomen was normal while at her second laparotomy the abdominal contents were visible with only a few adhesions. Three weeks later, generalized neoplastic spread was present. The entire small bowel was encased in neoplasm. The neoplasm extended onto the liver and from the omentum along the entire length of the greater curvature of the stomach. The uterus and adnexa were completely replaced with neoplasm and after extensive dissection, a supracervical hysterectomy and bilateral salpingo-oophorectomy were performed. This was performed in the hope of removing a possibly infectious source for her fever. Biopsy of both the omentum and a thickened area in the previous abdominal incision showed PSTT. Postoperatively, the patient experienced contin-

uing nightly fevers to 40–41°C. Her bowel function initially returned 3 days postoperatively. However, on Postoperative Day 12, a complete bowel obstruction developed. Chemotherapy was begun consisting of methotrexate, actinomycin, VP-16, and *cis*-platinum. Despite chemotherapy, the upper abdominal tumor mass enlarged by palpation. She received one cycle of chemotherapy, but due to a worsening performance status and the nonresponsiveness of the tumor no further chemotherapy was administered. The patient continued on nasogastric suction and central hyperalimentation until she died from progressive disease, 10 weeks from the time of her cesarean section. The patient's family refused autopsy.

Immediately postcesarean section, the patient's serum HCG was 80 mIU/ml. This rapidly decreased to a non-detectable level 2 weeks after delivery and despite an extensive amount of tumor in her abdomen, her HCG remained nondetectable. Serum HPL was 0.3 μ gm/ml with a normal range at 34 weeks gestational age of 3.9–13.0. Prehysterectomy, her CA-125 was 5360 u/ml (normal, 0–35) and 1 week after hysterectomy, 1645 u/ml. The patient's blood type was O, Rh negative and her husband was O, Rh positive.

PATHOLOGY

The endometrial cavity of the 540-g partially involuted uterus was lined by a soft grey–tan neoplasm. Although the neoplasm covered the entire endometrial surface, it formed a prominent 4 × 4-cm mass on the posterior wall. This nodule was consistent with the ultrasound findings in late pregnancy. The tumor extended transmurally in several areas and involved both adnexa.

Microscopically, the neoplasm was composed of sheets of polyhedral cells with large vesicular nuclei and eosinophilic to clear cytoplasm. Although occasional giant cells were noted, the majority of cells were intermediate in type with features of both cytotrophoblast and syncytiotrophoblast (Figs. 1,2). The dimorphic cell population characteristic of choriocarcinoma was not seen. The tumor exhibited a high mitotic rate, with as many as 15 mitotic figures per single high-power field. The neoplastic cells spread extensively in cords and medullary nests between fibers of smooth muscle within the myometrium. Extensive hemorrhage within the tumor was not noted. Extensive vascular and lymphatic invasion was seen in the myometrium and adnexa, including the ovaries. The omentum and abdominal wall contained the same neoplasm. Immunohistochemical staining revealed that the tumor cells were diffusely positive for broad spectrum keratin. Five to ten percent was positive for placental alkaline phosphatase, slightly less (2–5%) was positive for HPL, and only rare cells were positive for HCG.

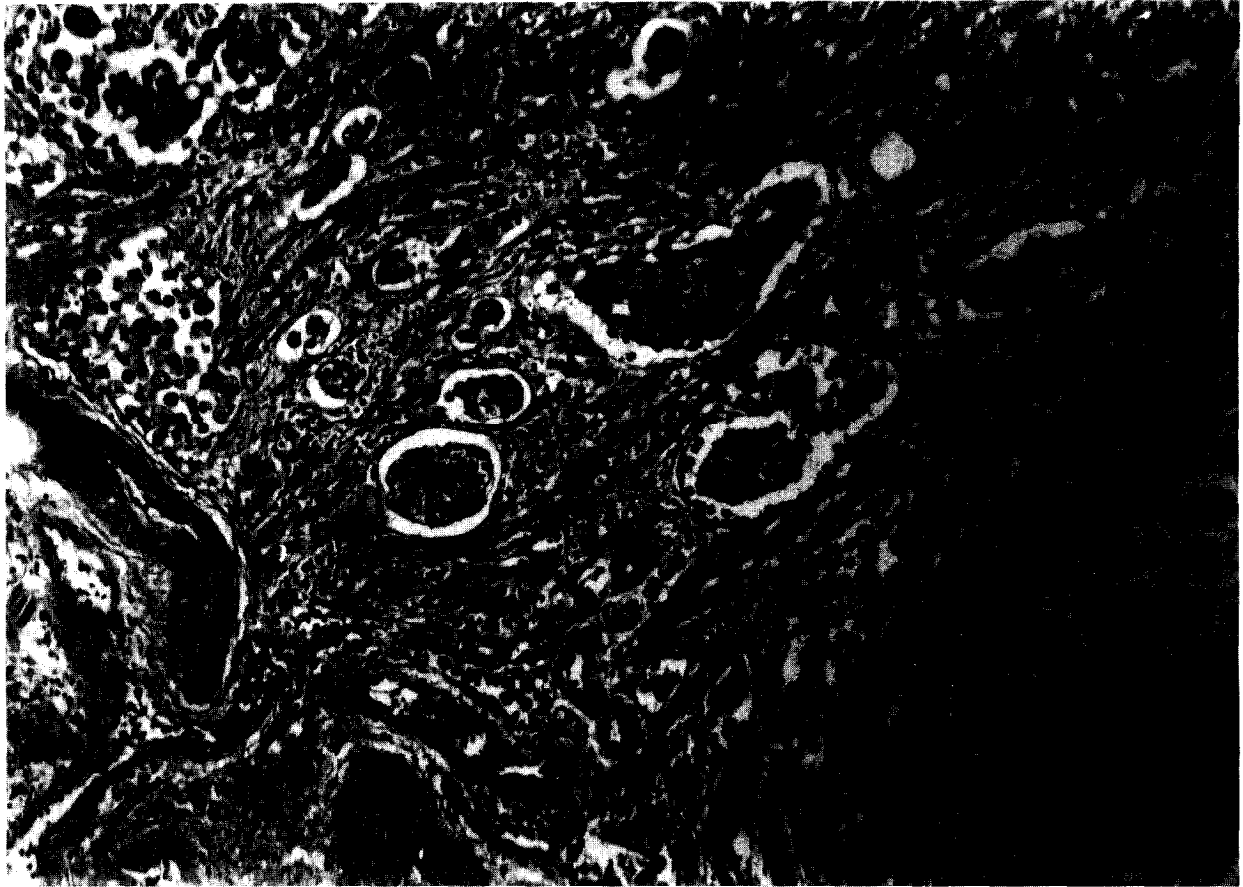


FIG. 1. Neoplasm diffusely infiltrating myometrium (10 \times).

The 14 \times 14-cm 350-g discoid placenta had a paramarginal insertion of a three-vessel umbilical cord. The fetal surface was smooth, glistening, and grey-blue, with a normal vascular pattern. The membranes were focally thickened but still translucent with a marginal insertion. The maternal surface was composed of intact cotyledons, with one 4 \times 4-cm area near one area which was thinned and covered by a grey-tan exudate. No grossly identifiable tumor involved the placenta.

Microscopic sections of the placenta revealed foci of partially necrotic tumor adherent to membrane but no tumor involved the placenta. The maternal surface of the placenta was intact.

DISCUSSION

PSTT is a rare tumor which is usually diagnosed at some interval after pregnancy. This is the first patient to our knowledge with PSTT and a viable pregnancy. The diagnosis was based on the morphologic features of the tumor cells, their pattern of infiltration of the myometrium, the lack of extensive hemorrhage or intravascular growth, and the much higher percentage of cells positive

for HPL compared to HCG. The posterior placenta was located over the necrotic nodule found at hysterectomy, suggesting that this was the site of origin. Additionally, the tumor extended to the placenta and onto the fetal membranes but was not intraamniotic. The low α -feto-protein early in pregnancy and the placental abruption most likely relate to an abnormal placentation. However, the infant was normally developed and of appropriate size for gestational age, indicating that she was able to maintain the necessary placental function to obtain a viable pregnancy. The infant appeared unaffected by the presence of the neoplasm and is developing normally. This patient and the patient reported by Finkler *et al.* who was 21 weeks gestational age demonstrate that as with trophoblastic disease, this entity can be associated with a viable fetus [5]. The pregnancy reported here also resulted in a male infant (normal XY). A previous report summarizing the literature, associated PSTT with a previous female infant [6]. This patient also had a previous female infant 2 years prior to conception. It is possible but unlikely that the PSTT was related to her prior pregnancy as she resumed completely normal menses after

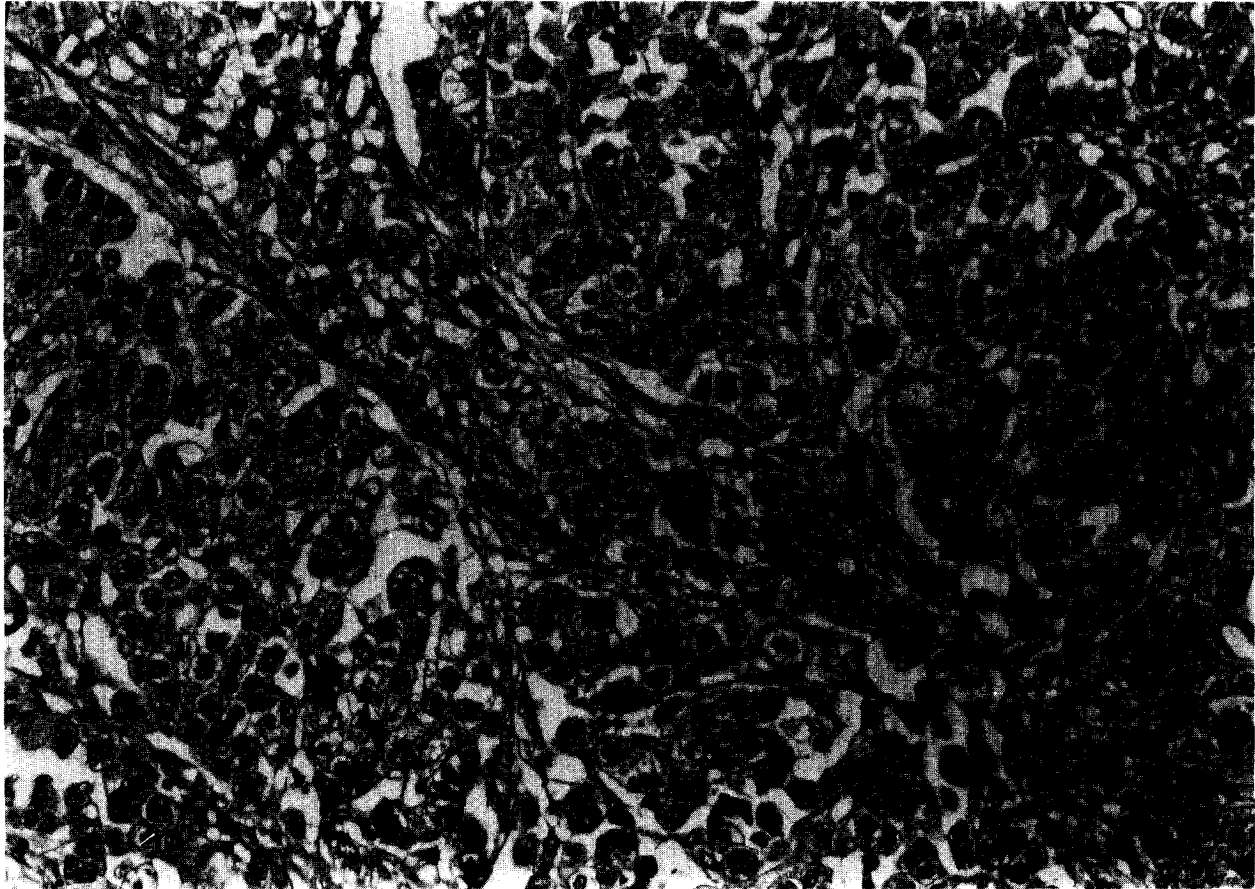


FIG. 2. Sheets of intermediate-type trophoblast cells include only a rare multinucleated giant cell. Extensive hemorrhage is not present (20 \times).

her first pregnancy and experienced no interval abnormal bleeding.

The spread of this patient's neoplasm is in accordance with those of previously reported patients in whom the neoplasm can involve the cervix, vagina, ovaries, and intraabdominal structures. Following cesarean section, this neoplasm followed a most aggressive course, spreading throughout the abdomen, eventually leading to intraabdominal spread and small bowel obstruction. She did not have an initial response to chemotherapy and rapidly followed a downhill course. The prediction of response to chemotherapy may lie in the presence or absence of HCG-producing trophoblast. The intermediate trophoblast of PSTT produces variable amounts of HCG and as reviewed by Lathrop, 6 of the 10 reported patients showed a partial response to the chemotherapy [6,13]. In a previous patient reported by Hopkins *et al.*, when the HCG value was extremely high, the response to chemotherapy was rather dramatic. Once the HCG reached lower levels, the response to chemotherapy then ceased [2]. In this patient, where HCG levels were nondetectable there appeared to be no response to chemotherapy. This may suggest that the trophoblast which is producing HCG

is responsive to conventional chemotherapeutic agents and non-HCG-producing trophoblast is resistant.

Elevated levels of serum CA-125 associated with pregnancy have been reported. The levels appear to peak at approximately 10 weeks gestational age, return to normal, and then rise at the time of placental separation [14]. High concentrations of CA-125 are found in chorionic and decidual tissue extracts while amniotic and placental extracts lack CA-125 [15,16]. The extremely high levels in this patient suggest that the PSTT may have been associated with these elements of the placenta. It is possible that CA-125 will become another tumor marker that can be used to follow the clinical course of this disease.

The malignant form of PSTT appears to follow a very aggressive course. Young and Scully reported that this is related to the number of mitoses per 10 high-power fields [17]. This patient had extensive mitoses per high-power field with some fields having 15 mitoses per individual high-power field. In this young patient, metastatic PSTT followed a fulminate aggressive course. Other patients reported with metastatic PSTT have survived a period of months to years before succumbing to the disease. This patient had no response to chemotherapy and was never

able to leave the hospital. This patient's more aggressive course may in part have been due to her altered immunologic status associated with the pregnancy. Like choriocarcinoma when PSTT is associated with a term pregnancy, it may represent a high-risk situation.

ACKNOWLEDGMENT

The authors would like to acknowledge the assistance of James W. Mitchener, M.D., Department of Pathology, Port Huron Hospital.

REFERENCES

1. Kurman, R. J., Scully, R. E., and Norris, H. J. Trophoblastic pseudotumor of the uterus, *Cancer* **38**, 1214–1226 (1976).
2. Hopkins, M. P., Nunez, C., Murphy, J. R., and Wentz, W. B. Malignant placental site trophoblastic tumor, *Obstet. Gynecol.* **66**, 98s–100 (1985).
3. Twiggs, L. B., Okagaki, T., Phillips, G. L., Stroemer, J. R., and Adcock, L. L. Trophoblastic pseudotumor—Evidence of malignant disease potential, *Gynecol. Oncol.* **12**, 238–248 (1981).
4. Samlowski, W. E., Abbott, T. M., Kepas, D. E., and Eyre, H. J. Placental-site trophoblastic tumor (trophoblastic pseudotumor): Case report demonstrating failure of chemotherapy, surgery, and radiotherapy to control metastatic disease, *Gynecol. Oncol.* **21**, 111–117 (1985).
5. Finkler, N. J., Berkowitz, R. S., Driscoll, S. G., Goldstein, D. P., and Bernstein, M. R. Clinical experience with placental site trophoblastic tumors at the new england trophoblastic disease center, *Obstet. Gynecol.* **71**, 854–857 (1988).
6. Lathrop, J. C., Lauchlan, S., Nayak, R., and Ambler, M. Clinical characteristics of placental site trophoblastic tumor (PSTT), *Gynecol. Oncol.* **31**, 32–42 (1988).
7. Gloor, E., Ribolzi, J., Djalidas, J., Barrelet, L., and Hurlimann, J. Placental site trophoblastic tumor (trophoblastic pseudotumor) of the uterus with metastases and fatal outcome: Clinical and autopsy observations of a case, *Am. J. Surg. Pathol.* **7**, 483–486 (1983).
8. Scully, R. E., Young, R. H. Trophoblastic pseudotumor: A reappraisal, *Am. J. Surg. Pathol.* **5**, 75–76 (1981).
9. Eckstein, R. P., Paradina, F. J., and Bagshaw, E. Placental site trophoblastic tumor (trophoblastic pseudotumor): A study of four cases requiring hysterectomy including one fatal case, *Histopathology* **6**, 211–226 (1982).
10. Eckstein, R. P., Russell, P., Friedlander, M. L., Tattersall, M. H. N., and Bradfield, A. Metastasizing placental site trophoblastic tumor: A case study, *Hum. Pathol.* **16**, 632–636 (1985).
11. Blackwell, J. B., and Papadimitriou, J. M. Trophoblastic pseudotumor of the uterus, *Cancer* **43**, 1734–1741 (1979).
12. Alvero, R., Renimenga, S., O'Conner, D., Barnhill, D., and Park, R. Metastatic placental site trophoblastic tumor, *Gynecol. Oncol.* **37**, 445–449 (1990).
13. Kurman, R. J., Young, R. H., Norris, H. J., Main, C. S., Lawrence, W. D., and Scully, R. E. Immunocytochemical localization of placental lactogen and chronic gonadotropin in the normal placenta and trophoblastic tumors, with emphasis on intermediate trophoblast and the placental site trophoblastic tumor, *Int. J. Gyn. Pathol.* **3**, 101–121 (1984).
14. Kobayaski, F., Sagawa, N., Nakamura, K., Nonogaki, M., Ban, C., Fujii, S., and Mori, T. Mechanism and clinical significance of elevated CA-125 levels in the sera of pregnant women, *Am. J. Obstet. Gynecol.* **160**, 563–566 (1989).
15. O'Brien, T. J., Hardin, J. W., Bannon, G. A., Norris, J. S., and Quirk, J. G. CA-125 antigen in human amniotic fluid and fetal membranes, *Am. J. Obstet. Gynecol.* **155**, 50–55 (1986).
16. Quirk, J. G., Brunson, G. L., Long, C. A., Bannon, G. A., Sanders, M., and O'Brien, T. J. CA-125 in tissues and amniotic fluid during pregnancy, *Am. J. Obstet. Gynecol.* **159**, 644–649 (1988).
17. Young, R. H., and Scully, R. E. Placental-site trophoblastic tumor: Current status, *Clin. Obstet. Gynecol.* **27**, 248–260 (1984).