

AURICULAR PAROXYSMAL TACHYCARDIA WITH AURICULOVENTRICULAR BLOCK

PAUL S. BARKER, M.D., FRANK N. WILSON, M.D.,
FRANKLIN D. JOHNSTON, M.D., ANN ARBOR, MICH., AND
SHELBY W. WISHART, M.D., EVANSVILLE, IND.

AURICULAR paroxysmal tachycardia is a condition in which the heart beats rapidly and regularly in response to impulses arising in the auricles. The attacks are characterized by abrupt transitions, from normal rhythm to tachycardia at their onset, and from tachycardia to normal rhythm at their termination. They usually last a few minutes or a few hours, rarely much longer. The rate is usually between 150 and 220 per minute, commonly near 200. The ventricles respond, as a rule, to each auricular beat. The attacks can often be stopped by pressure upon the carotid sinus, or by large doses of digitalis, less commonly by quinidine. The precise mechanism of the auricular tachycardia is not understood. It is commonly believed that a rapid succession of impulses arises from an ectopic focus in the auricles. It is possible that in some manner each beat initiates the succeeding beat, or that the tachycardia depends upon the establishment of a circus rhythm in the auricular muscle. This last possibility has been discussed in considerable detail by Lewis.¹ It is of interest that auricular paroxysmal tachycardia seldom occurs in patients who have had previous attacks of auricular flutter or fibrillation, and that these disturbances, which are caused by circus rhythm, are uncommon in patients who have had auricular paroxysmal tachycardia.

In auricular flutter the auricular activity is characterized by a high degree of regularity and uniformity. The auricular rate is usually between 240 and 375 per minute. The ventricles very rarely respond to each auricular impulse; there is nearly always partial atrioventricular block, commonly 2:1. The abnormal mechanism is usually more persistent than auricular paroxysmal tachycardia, and often lasts for weeks or months, but repeated short attacks sometimes occur. Carotid sinus pressure slows the ventricles but does not alter the auricular mechanism. Digitalis slows the ventricles, and, when large amounts are given, usually converts auricular flutter into auricular fibrillation. Quinidine always slows the auricular rate, but does not often restore normal rhythm.

In rare instances of auricular paroxysmal tachycardia, the ventricles do not respond to each auricular beat in the usual manner. There may

From the Department of Internal Medicine, University of Michigan Medical School and the University Hospital.

Read in part before the Central Society for Clinical Research, Chicago, Nov. 4, 1938.

The collection of the material upon which this paper is based was aided by a grant to F. N. Wilson from the Horace H. Rackham School of Graduate Studies.

Received for publication Aug. 4, 1942.

TABLE
AURICULAR PAROXYSMAL TACHYCARDIA

	AUTHORS	AGE	SEX	DURATION OF SYMPTOMS	FREQUENCY OF ATTACKS	DURATION OF ATTACKS	AUR. RATE	DEGREE OF A-V BLOCK	P WAVES*		
									LI	LII	LIII
1.	Koplik, 1917	10	M	2 years			200	2:1 to 3:1			
2.	Singer and Winterberg, 1922	70	M				184	complete		+	
3.	Gallavardin, 1923	60	F	a few hours	one attack	a few hours	180	2:1		+	
4.	Lenhartz and Samet, 1924	29	F	3 years	3 attacks	up to 94 days	196 to 188	2:1	-	+	+
5.	Sprague and White, 1925	48	F	10 years	4 days to 7 months	several hours	190 to 270	2:1	+	-	-
6.		23	F	6 months	20 attacks	2 hours to 5 days	220	2:1	+	+	+
7.		26	M	10 years	daily to 7 months	a few minutes	166 to 190	2:1		+	
8.	Wenckebach & Winterberg, 1927					several hours	180	3:1 to 6:1			-
9.		20	M	7 weeks	numerous	variable	180	3:2 to 2:1		+	
10.				many years		4 weeks	205	dropped beats	(+, lead not stated)		
11.	Dock, 1928	38	F	22 days	one attack	22 days	186 to 180	2:1 to 4:1	?	+	+
12.	Mackinnon, 1934	17	M	at least 5 days	one attack	at least 5 days	121	2:1	(+, lead not stated)		
13.		45	F	2 years	daily	a few minutes	150	dropped beats	(?, lead not stated)		
14.	Brown, 1936	40	F	8 years		a few minutes, persistent	214	2:1	-	+	+
15.	Maddox, 1937	39	F	17 years	2 to 5 years	up to 69 days	120 to 170	1:1 to 3:1	+	-	-
16.	Maarsø, 1937	8	M	1 year		1 month	182 to 160	dropped beats, 2:1	?	?	+
17.	Fine and Miller, 1940	16	F	several years	daily	brief	120 to 200	dropped beats	-	+	+
18.	Case 1	39	M	9 years	upon exertion	brief	170, 150	1:1 to 3:1		+	
19.	2	32	M	10 years	daily to several weeks	up to 26 days	200	1:1 to 2:1	+	+	-

*During paroxysmal tachycardia. +, upright; -, inverted; ±, diphasic, upward and then downward; †, diphasic, downward and then upward; ‡, not visible.

I

WITH AURICULOVENTRICULAR BLOCK

DIS-ABILITY	CONGES-TIVE FAILURE	ORGANIC HEART DISEASE	INEFFEC-TIVE TREATMENT	EFFECTIVE TREATMENT	RESULT	REMARKS
moderate	none	none				electrocardiograms not published
				quinine	stopped the paroxysm	
		syphilitic aortitis			normal rhythm	
marked	none	none	quinine	digitalis and physostigmine	normal rhythm	aur. rate slowed by quinine and by digitalis and physostigmine
moderate	none	none	quinidine	digitalis, removal of cervical ribs	normal rhythm	
moderate	none	none	quinidine	digitalis, rest	normal rhythm	
slight	none	none	quinidine	digitalis	normal rhythm	
				quinine	normal rhythm	
		none			normal rhythm	
				quinine	normal rhythm	
marked	present	mitral stenosis	digitalis		A-V bradycardia	
marked	present	mitral stenosis, aortic regurg.		digitalis	increased block, normal rhythm	
slight	none	mitral lesion		carotid sinus pressure	normal rhythm	probable case. P not identified
marked	acute edema of lungs	mitral and pulmonary lesions or congenital heart		digitalis	normal rhythm	changed to aur. fibr. and then to normal rhythm after digitalis
moderate	none	none	quinine quinidine digitalis acetylcholine	rest	normal rhythm	? sinus tachycardia influenced by rest, exercise, emotion, sleep; auricular rate slowed by digitalis
present	none	enlargement	digitalis			
moderate	none	none	carotid sinus pressure	digitalis, quinidine	normal rhythm	rate influenced by posture
slight	none	none	quinidine	digitalis	increased degree of block	normal rhythm later
marked	none	mitral stenosis	quinidine quinine mecholy	digitalis, rest	increased degree of block, improved	also auricular flutter and fibrillation

TABLE

	AUTHORS	AGE	SEX	DURATION OF SYMPTOMS	FREQUENCY OF ATTACKS	DURATION OF ATTACKS	AUR. RATE	DEGREE OF A-V BLOCK	P WAVES*		
									LI	LII	LIII
20.	3	41	M	1 year	a few days to 6 months	a few minutes	174 to 218	1:1 to 3:1	+	+	+
21.	4	15	M	3 months	almost continuous	up to 60 days	167 to 129	1:1 to 3:2	?	±	+
22.	5	62	F	10 months		1 day	167, 158	dropped beats	+	+	+
23.	6	19	M	6 months	upon exertion	at least 13 days	136 to 160	1:1 to 3:1	+	-	-
24.	7	67	M		4 to 14 days	up to 2 days	188 to 235	1:1 to 3:1	?	+	+
25.	8	53	M	2 days	one attack	2 days	188	usually 2:1	?	+	+
26.	9	23	F	6 months	up to 7 days	1 hour to 2 days	195	1:1 to 2:1	+	+	+
27.	10	54	M	4 days	one attack	4 days	200	2:1 or greater	+	+	+
28.	11	52	M	3 days	one attack	3 days	161 to 167	dropped beats	+	+	+
29.	12	80	M	3 days	one attack	3 days	215	usually 4:1	+	+	+
30.	13	68	M	2 days	one attack	2 days	137	2:1	+	+	+
31.	14	17	F	2 days	one attack	2 days	130	dropped beats	+	+	+
32.	15	64	M	9 months	several times daily	a few minutes	192 to 250	2:1 briefly	+	-	-
33.	16	26	F	9 months	9 months		160	complete	+	+	+
34.	17	48	M	3 days	one attack	3 days	180 to 163	2:1	±	+	+
									+	+	+
35.	18	45	M	10 days	2 attacks	1 hour and 2 days	212	2:1 to 3:1	+	+	+

*See footnote, p. 766.

be occasional dropped ventricular beats, or 2:1 or higher grades of auriculoventricular block. Auricular paroxysmal tachycardia associated with heartblock differs in several important respects from ordinary paroxysmal tachycardia of auricular origin, and resembles auricular flutter in some particulars. The purpose of this paper is to review seventeen previously reported cases, to present eighteen additional cases, and to describe some of their peculiarities. The important features of these thirty-five cases have been tabulated (Table I).

I—CONT'D

DIS-ABILITY	CONGES-TIVE FAILURE	ORGANIC HEART DISEASE	INEFFEC-TIVE TREATMENT	EFFECTIVE TREATMENT	RESULT	REMARKS
moderate to marked	none	none	quinidine mecholyl	digitalis	increased degree of block	normal rhythm later, aur. rate slowed by quinidine
marked	present	none	quinidine digitalis	none	died 84 days after onset	aur. rate slowed by quinidine. Autopsy
slight	none	none		digitalis	normal rhythm	
moderate to marked	none	? mitral lesion	digitalis mecholyl	quinidine	normal rhythm; died suddenly	aur. rate slowed by quinidine. Autopsy
moderate	none	hypertension, arteriosclerosis, emphysema	digitalis	quinidine	normal rhythm	
inci-dental	present	right-sided enlargement	digitalis		died	autopsy; bronchiectasis
moderate	none	mitral stenosis, aortic regurg.	digitalis	quinidine	normal rhythm	
slight	none	hypertension, slight enlargement	digitalis (overdigitalized)	stopped digitalis	normal rhythm	changed to aur. fibr. and then to normal rhythm
marked	present	hypertension, enlargement		digitalis	normal rhythm	developed acute edema of lungs
inci-dental	none	arteriosclerosis	digitalis			changed to auricular fibrillation
none	none	arteriosclerosis			normal rhythm	
none	none	exophthalmic goitre			normal rhythm	
slight	none	arteriosclerosis, slight enlargement	quinidine	digitalis	normal rhythm	A-V block very brief
marked	present	hypertension, enlargement		digitalis	normal rhythm	
inci-dental	acute edema of lungs	acute myocardial infarction, hypertension, enlargement	digitalis		normal rhythm	P waves vary in form
inci-dental	present	old myocardial infarction	digitalis		normal rhythm	

PREVIOUSLY REPORTED CASES

The first report of auricular paroxysmal tachycardia with partial A-V block was by Koplik,² in 1917. The patient was a 10-year-old boy. Many electrocardiograms were obtained, but none were published. In 1922, Singer and Winterberg³ published curves from a 70-year-old man whose A-V block was complete, with a ventricular rate of 26 per minute. The auricular paroxysmal tachycardia was stopped by quinine given intravenously. Gallavardin,⁴ in 1923, described a case in which there were frequent dropped ventricular beats and short periods of 2:1 A-V

block interspersed with short runs of 1:1 response. He pointed out that such a disturbance could give rise to almost complete irregularity of the ventricles at a rapid rate, closely resembling auricular fibrillation clinically. In 1924, Lenhartz and Samet⁵ reported a case in a 29-year-old nurse who for a long time was thought to have auricular fibrillation. Normal rhythm was finally restored by the combined use of physostigmine and digitalis after the attack had lasted ninety-four days. Sprague and White,⁶ in 1925, reported three cases, and briefly compared and contrasted them with auricular flutter. They pointed out that the attacks occurred over a period of years, often lasted several days, and were not influenced favorably by quinidine, but could often be stopped by digitalis in full doses. In 1927, Wenekebach and Winterberg⁷ reported three cases, in two of which normal rhythm was restored by quinine. Dock,⁸ in 1928, described a case in which the auricular paroxysmal tachycardia lasted for twenty-two days and was accompanied by partial A-V block varying in degree from 2:1 to 4:1, and was not affected appreciably by pressure upon the carotid sinus or the eyes or by large amounts of digitalis. In 1934, Mackinnon⁹ reported two cases. One of these was clearly an instance of auricular paroxysmal tachycardia with partial A-V block. The other was similar in most important respects, but can be considered only as a probable case because the auricular waves could not be identified in the records. The author pointed out that in occasional cases of auricular paroxysmal tachycardia the ventricular rhythm may be irregular, and that the usual cause for this irregularity is defective conduction in the A-V bundle.

Brown,¹⁰ in 1936, presented esophageal leads of two patients, which he interpreted as showing auricular paroxysmal tachycardia with partial A-V block. The first of these curves is susceptible of an alternative interpretation, namely, that, while the rate was rapid, the ventricular complexes were slightly aberrant and thus gave the curve an appearance which somewhat resembled auricular paroxysmal tachycardia with partial A-V block. The second case, however, is clearly a very interesting example of the condition under discussion, and illustrates the value of digitalis in its treatment. The author called attention to the differences between auricular paroxysmal tachycardia and auricular flutter as shown by esophageal leads. In the former the auricular deflections are separated one from another by intervals during which the tracing remains at the isoelectric level. In flutter, however, the auricular activity produces a continuous oscillation of the tracing, with no isoelectric intervals, suggesting continuous excitation.

In 1937, Maddox¹¹ reported a case of auricular paroxysmal tachycardia with variable A-V conduction and periods of 2:1 or 3:1 block. His discussion deals mainly with the site of impulse formation and the influence of the extrinsic cardiac nerves. Maarssø,¹² in 1937, reported a case in which an attack of auricular paroxysmal tachycardia lasted longer than one month. At times there was partial A-V block, varying

in degree from frequent dropped beats to 2:1 response. Fine and Miller,¹³ in 1940, reported a remarkable case of orthostatic auricular paroxysmal tachycardia in which the rate was influenced by posture. Sometimes the paroxysmal tachycardia was present while the patient was recumbent, and was then sometimes accompanied by partial A-V block with frequent dropped beats. The attacks of paroxysmal tachycardia could be prevented by either digitalis or quinidine.

Lewis¹ published electrocardiograms of a child with auricular paroxysmal tachycardia and partial A-V block with occasional dropped beats. The auricular rate was 290 per minute, and the P waves were upright in Lead II. Recently, Katz¹⁴ has published the curves of three patients who had partial A-V block during paroxysms of auricular tachycardia. The first of these showed auricular rates of 180 to 125 and block varying in degree from dropped beats to 2:1. The second had an auricular rate of 158 and 2:1 block. The third patient had an auricular rate of 167 and frequent dropped beats. In all three cases the P waves were upright during the paroxysms. These cases are not included in the table because the clinical data were not given.

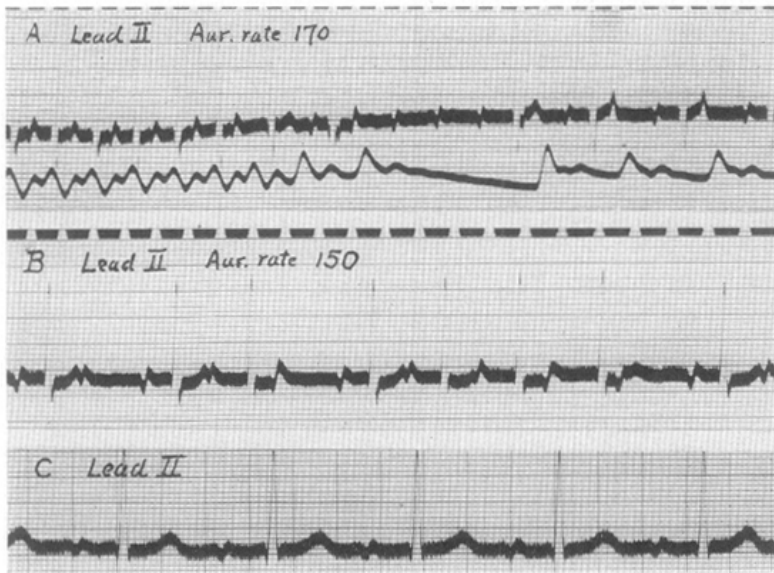

Fig. 1.—Case 1. *A*, March 22, 1922. Lead II and radial pulse. Auricular rate, 170. *B*, Aug. 2, 1922. Lead II. Auricular rate 150. *C*, July 26, 1924. Lead II. Normal rhythm, rate 90.

CASE REPORTS

CASE 1.*—A white man, aged 39 years, was first seen in 1922. He complained of attacks of palpitation and dyspnea brought on by exertion. These began in 1913, and had been worse since 1917. Examination revealed no evidence of organic heart disease and no signs of congestive cardiac failure. The electrocardiogram (Fig. 1, *A* and *B*) showed diphasic P waves, occurring at a rate of 170 per minute.

*This case is included through the kindness of Dr. John Parkinson, London, England, who generously furnished the electrocardiograms and the clinical data.

Partial A-V block of varying degree (1:1, 3:2, 2:1) was present. Full doses of quinidine sulfate had no effect on the auricular deflections. The average ventricular rate was somewhat increased and the ventricular complexes became aberrant. One week later digitalis was given in full doses. This increased the degree of A-V block (frequently 3:1), but had no further effect. In 1924, an electrocardiogram showed normal rhythm with diphasic P waves and a rate of 90 (Fig. 1, *C*). In 1927, the patient stated that he had been fairly well, and tracings again showed normal rhythm with diphasic P waves and a rate of 100.

CASE 2.—A white man, 32 years of age, was first seen Oct. 28, 1937. At the age of 12 years he had rheumatic fever. He had a brief attack of tachycardia in 1928, and another in 1929. After that he had frequent attacks of tachycardia, brought on by slight exertion, by eating large meals, or by constipation, and sometimes relieved by rest. The paroxysms sometimes lasted for several hours or days, and were then accompanied by shortness of breath and soreness in the region of the liver. They became so frequent, so prolonged, so severe, and so resistant to treatment that recourse was had to morphine, with resulting addiction.

When first seen, the patient was exhausted from a prolonged attack of tachycardia. The heart rate was 200, the rhythm regular. Pressure upon the carotid sinus caused no change. Mecholyl, in a dose of 25 mg., was given subcutaneously, and repeated fifteen minutes later. After this the heart rate became a little slower, and upon carotid sinus pressure it fell to a normal level. Almost immediately, however, the rapid beating returned.

At this point the first electrocardiogram was taken; it showed auricular flutter with an auricular rate of 286, and 2:1 ventricular response. Digitalis, in a dose of 0.5 Gm., was given intravenously, and thirty minutes later the electrocardiogram (Fig. 2, *A*) showed auricular flutter with an auricular rate of 275 and a ventricular rate of 82 per minute. On October 29, digitalis, in a dose of 0.35 Gm., was given intravenously. On November 1 the electrocardiogram (Fig. 2, *B*) showed auricular paroxysmal tachycardia with auricular and ventricular rates of 200. Digitalis (0.35 Gm.) was given intravenously, and fifteen minutes later there was 2:1 A-V block; the auricular rate was still 200 (Fig. 2, *C*). After this, digitalis was given orally in rather large amounts. The auricular paroxysmal tachycardia continued, but partial A-V block was maintained, and on November 22 the electrocardiogram (Fig. 2, *D*) showed an auricular rate of 200 and a ventricular rate of 64, sometimes even lower. Precordial leads were used in order to obtain large auricular deflections. At this time digitalis was stopped because of symptoms of mild intoxication. On November 26 there was 1:1 ventricular response with a rate of 200. Carotid sinus pressure caused partial block. After giving mecholyl (25 mg. subcutaneously), carotid sinus pressure caused pronounced slowing of the ventricles. Esophageal leads were used to record this (Fig. 2, *E*), and showed large auricular deflections separated by periods of electrical quiescence. Digitalis was resumed. On Dec. 29, 1937, normal rhythm was present (Fig. 2, *F*). For several months after this there were many attacks of tachycardia. The patient then improved and it was thought that normal rhythm was present much of the time. At this time the murmur of mitral stenosis was heard. On Oct. 28, 1938, however, an electrocardiogram showed auricular flutter in Leads I and II, with an auricular rate of 292 and a 4:1 ventricular response. A minute later, when Lead III was taken, auricular fibrillation was present, with a ventricular rate of 80. In order to bring out the auricular waves more clearly, a precordial lead was used (Fig. 2, *G*).

CASE 3.—A white man, aged 41 years, was first seen on Jan. 5, 1938. For one month he had been having attacks of tachycardia, shortness of breath, and dizziness. They occurred irregularly every few days and lasted a few minutes. They were abrupt in onset and termination, and were brought on by exertion and relieved by

rest. Similar attacks had occurred one year previously and again six months previously, each time for a period of a few weeks.

Physical examination was entirely negative. No abnormality of the heart was detected. The blood pressure was 118/60. The rhythm was regular, the rate, 100. With moderate exercise, however, the rate rose to more than 160; the rhythm was regular. After about thirty seconds the rate dropped abruptly and the rhythm was

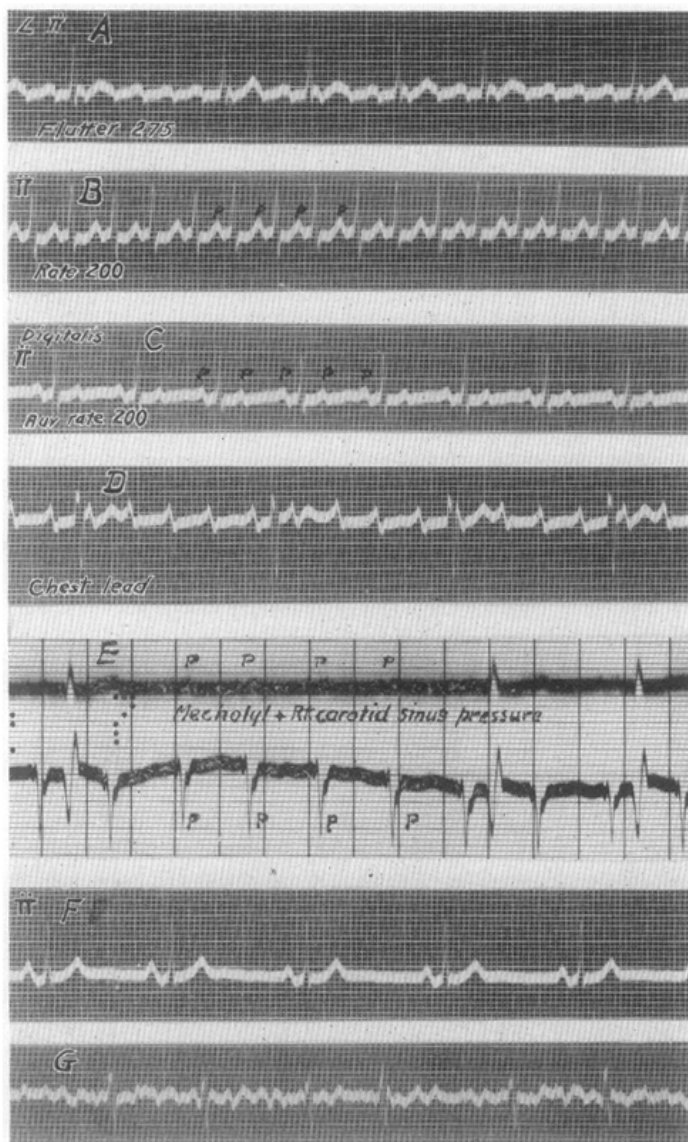


Fig. 2.—Case 2. *A*, Oct. 28, 1937. Lead II. Auricular flutter. Auricular rate 275, ventricular rate, 82. *B*, Nov. 1, 1937. Lead II. Auricular paroxysmal tachycardia with auricular and ventricular rates of 200. Patient had had digitalis (0.85 Gr.). *C*, Nov. 1, 1937. Lead II, 15 minutes after 0.35 Gm. of digitalis intravenously. Auricular paroxysmal tachycardia with 2:1 A-V block. Auricular rate 200. *D*, Nov. 22, 1937. Precordial lead. Auricular paroxysmal tachycardia with high grade partial A-V block. Auricular rate 200. Patient had had large amounts of digitalis. *E*, Nov. 26, 1937. Lead I and esophageal lead. Pressure upon right carotid sinus after 25 mg. of mechohyl subcutaneously. *F*, Dec. 29, 1937. Lead II. Normal rhythm. *G*, Oct. 1, 1938. Precordial lead. Auricular fibrillation.

irregular for 10 or 15 beats. Thereafter the heart beat regularly at a normal rate. The exercise was repeated and the same changes in rate and rhythm were again observed.

An electrocardiogram (Fig. 3, *A*) showed paroxysmal tachycardia with an auricular rate of 200 and partial A-V block, usually 3:1. A precordial lead (Fig. 3, *B*) was employed to show the auricular waves more clearly. Exercise permitted the ventricles to follow the auricles at their full rate for a short time, after which the partial block returned. Carotid sinus pressure and mecholyl failed to terminate the auricular tachycardia. Quinidine sulphate, in a dose of 0.4 Gm. orally, was followed in two hours by slowing of the auricles to 174; the ventricles followed at

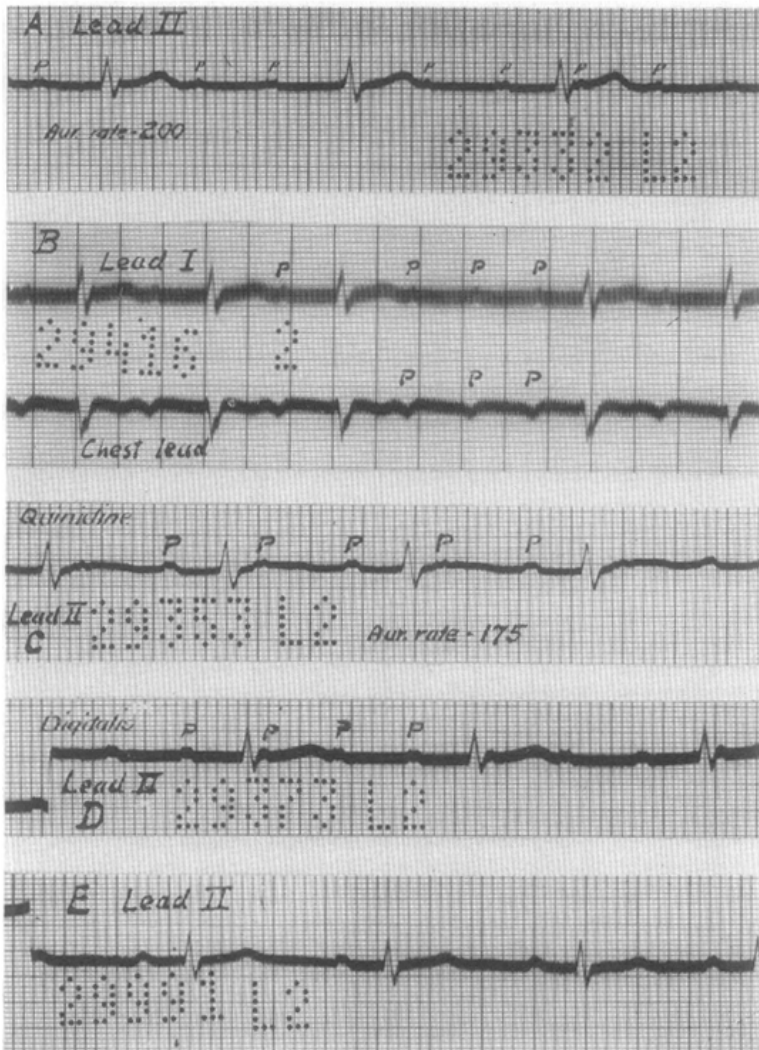


Fig. 3.—Case 3. *A*, Jan. 5, 1938. Lead II. Auricular paroxysmal tachycardia with partial A-V block. Auricular rate 200. Ventricular 78. *B*, Jan. 5, 1938. Lead I above and precordial lead below. Pressure upon right carotid sinus. Auricular rate 200. *C*, Jan. 7, 1938. Lead II, 2 hours after 0.4 Gm. of quinidine sulfate. Auricular paroxysmal tachycardia with 2:1 A-V block. Auricular rate, 175. Ventricular rate, 87. *D*, Jan. 10, 1938. Lead II, after 1.3 Gm. of digitalis. Auricular paroxysmal tachycardia with 3:1 A-V block. Auricular rate, 202. Ventricular rate, 67. *E*, March 17, 1938. Lead II. Normal rhythm, rate 88. Had taken digitalis regularly.

half the auricular rate (Fig. 3, *C*). Normal rhythm, however, was not restored. The patient was then digitalized without affecting the auricular rate. The degree of block, however, was increased, usually to 3:1 (Fig. 3, *D*), and the rapid ventricular beating upon exertion was prevented. After digitalization it was observed that mecholyl, in a dose of 15 mg. subcutaneously, increased the auricular rate from 207 to 218; the ventricular rate rose to 109.

Digitalis was continued. The patient returned January 26, at which time he had complete relief from his symptoms. The auricular rate was 211, and the ventricular rate, 86, with a mixture of 2:1 and 3:1 block. On March 17 the patient stated that he had been entirely free of symptoms, and the electrocardiogram showed normal rhythm (Fig. 3, *E*).

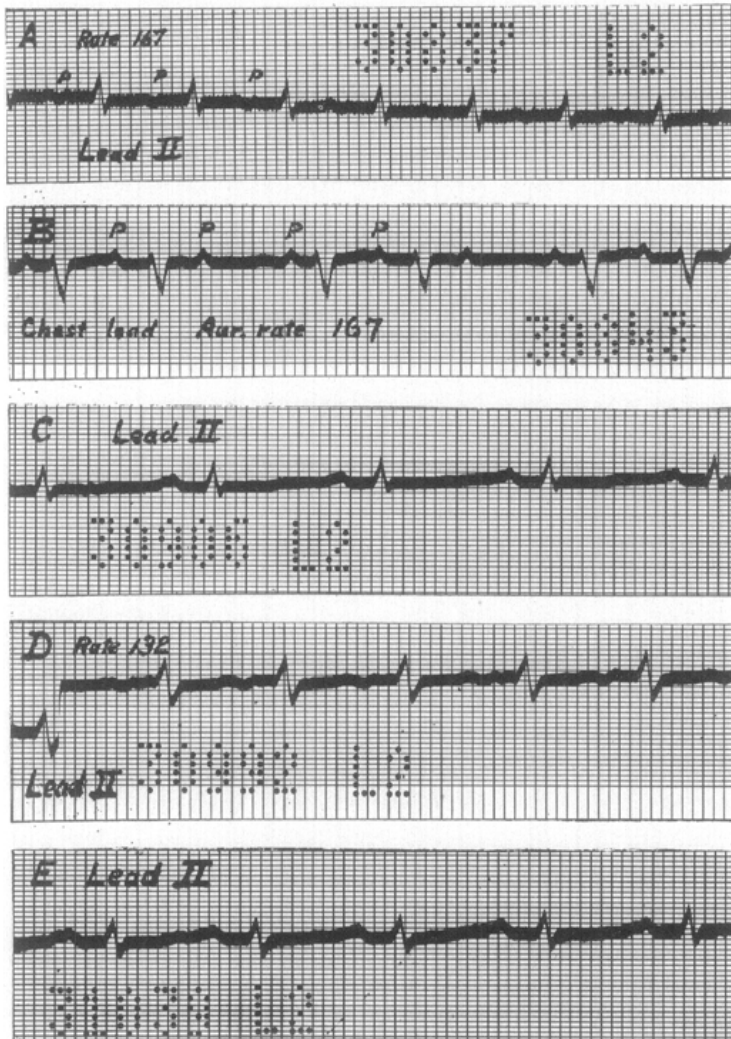


Fig. 4.—Case 4. *A*, June 21, 1938. Lead II. Auricular paroxysmal tachycardia, rate 167. Patient had received quinidine and digitalis. *B*, June 21, 1938. Precordial lead, with carotid sinus pressure. There is partial A-V block with dropped beats. The auricular deflections are shown more clearly. Auricular rate 167. *C*, June 29, 1938. Lead II. Normal rhythm. Rate 97. Had had digitalis and quinidine. *D*, July 11, 1938. Lead II. Auricular paroxysmal tachycardia with 1:1 ventricular response. Rate 132. Had had digitalis and quinidine. *E*, July 18, 1938. Lead II. Normal rhythm. Rate 107.

CASE 4.—A white boy, 15 years of age, was admitted to the hospital June 21, 1938. He had been in excellent health until May 1, 1938 when he began having shortness of breath upon moderate exertion, tachycardia, weakness, and an unproductive cough. The patient was not aware of an abrupt onset, nor was there any known infection at the time. The tachycardia persisted around 200 per minute in spite of rest in bed. The shortness of breath was increased by lying flat. Digitalis slowed the ventricles by producing partial A-V block. Quinidine slowed the auricular rate but was otherwise without appreciable effect. The patient grew weaker and more dyspneic, and the liver became enlarged. He was then referred to the hospital.

Upon physical examination the patient appeared seriously ill, with a dusky cyanosis, and dyspnea upon lying flat. The heart was moderately enlarged. There was a systolic murmur over the entire heart, loudest at the apex. No diastolic murmur was heard. The rate was about 160; the rhythm was not remarkable apart from an occasional, slight irregularity. The blood pressure was 92/70. The lungs were normal. The liver was slightly enlarged. There was no edema.

Roentgenologic examination showed fairly marked cardiac enlargement.

The electrocardiogram showed a heart rate of 167; the rhythm was regular except for occasional dropped beats (Fig. 4, *A*). Precordial leads showed the auricular deflections more clearly. Pressure upon the carotid sinus increased the degree of A-V block, causing frequent dropped beats (Fig. 4, *B*). Quinidine was withheld, and the auricular rate rose to 176; then quinidine was resumed and the auricular rate fell to 150. After the administration of both digitalis and quinidine for several days, normal rhythm returned (Fig. 4, *C*). In a few days, however, the tachycardia returned and persisted, except for a brief period of normal rhythm on July 18 (Fig. 4, *E*). During the ectopic auricular tachycardia, the rate slowed to 132 under digitalis and quinidine (Fig. 4, *D*). The patient grew progressively worse; he showed no improvement during the interludes of normal rhythm or when the rate slowed to 132. Râles appeared in the lungs and edema of the legs developed. The patient died July 24, 1938, of cardiac failure.

At autopsy the heart weighed 350 grams. It showed myocardial hypertrophy microscopically. There were marked subendocardial vacuolar degeneration and moderate subepicardial fatty infiltration. Infarction of the left ventricle in the region of the conduction apparatus was found. There was also a degenerative subendocardial lesion in the left ventricle, with necrosis, lymphocytic infiltration, and fibroblastic proliferation. An organizing mural thrombus was present in the left ventricle. There was endocardial sclerosis.

The lungs showed an acute exacerbation of chronic passive congestion, with edema. There were multiple fresh, and older, hemorrhagic infarctions. There were organizing thrombi in the pulmonary veins. The smaller arteries were sclerotic. There was an embolus in a medium-sized pulmonary artery, and a bland embolus in the main pulmonary artery. Acute purulent bronchitis and terminal purulent lobular pneumonia were present.

The liver and spleen showed chronic passive congestion.

CASE 5.—A white woman, aged 62 years, entered the hospital July 11, 1938. During the previous ten months she had had recurring attacks of left-sided renal colic, suffered from increasing weakness, and had lost 35 pounds in weight. During this time she was short of breath upon moderate exertion, and experienced frequent palpitation and irregularity of the heart. There was occasional swelling of the ankles.

Physical examination showed that the heart was normal in size. There was a systolic murmur at the apex. The rate varied from 106 to 140. There was an irregularity which was attributed to dropped beats. The blood pressure was 130/85. The radial and brachial arteries were thickened. The lungs were normal. The

abdomen was negative. There was no edema. The isthmus of the thyroid contained a small adenoma.

Roentgenologic examination showed no abnormalities of the heart or lungs, but did reveal a renal calculus on the left side.

The electrocardiogram showed an auricular rate of 167. Partial A-V block, with frequent dropped beats, was present, and the ventricular rate was 134 (Fig. 5, *A*). Carotid sinus pressure increased the degree of block and slowed the ventricles, but did not alter the auricular mechanism (Fig. 5, *B*). After digitalis in full doses, normal rhythm returned (Fig. 5, *C*). The patient was sent back to her home physician for nephrectomy.

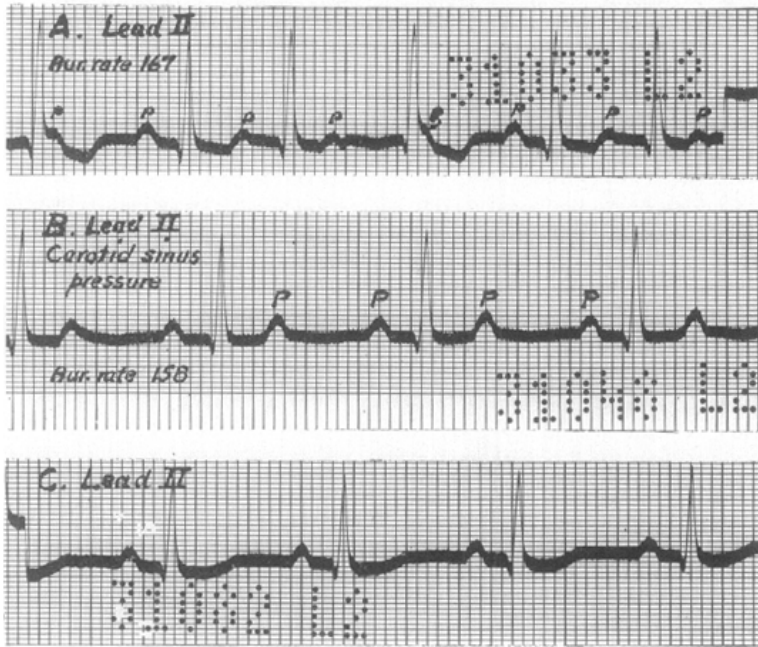


Fig. 5.—Case 5. *A*, July 18, 1938. Lead II. Auricular paroxysmal tachycardia with partial A-V block and frequent dropped ventricular beats. Auricular rate 167. *B*, July 19, 1938. Lead II. Carotid sinus pressure produces 2:1 A-V block. Auricular rate 158. *C*, July 22, 1938. Lead II. Normal rhythm. Rate 93. Had had digitalis.

CASE 6.—A white man, 19 years of age, was admitted to the hospital July 18, 1938. In 1930, the patient had had epigastric pain, nausea, and vomiting; these were attributed by his physician to heart disease, and were relieved in a few days by rest and digitalis. After that he took digitalis almost continuously and restricted his activities. Similar symptoms returned in 1933, and again in January, 1938. In each instance they followed strenuous exertion and were relieved by rest in bed. In January, 1938, he had a brief, acute respiratory infection. After that he had dyspnea and pronounced tachycardia upon moderate exertion. The heart was slow during rest. He improved under larger doses of digitalis and a month of rest in bed. The tachycardia upon exertion persisted, however, and he was referred to the hospital. There was no history of rheumatic fever.

The physical examination was entirely negative with the exception of the heart. It was markedly enlarged, with dullness extending to the left anterior axillary line. There were systolic murmurs at the apex and base. The rate and rhythm varied. At times the heart was regular at a rate of 60, at other times regular at a rate

of 170. Occasionally the rhythm was irregular and the rate intermediate between the two extremes. The blood pressure varied within normal limits. There were no signs of congestive cardiac failure.

Roentgenologic examination showed marked cardiac enlargement.

The electrocardiograms showed tachycardia of auricular origin, with a rate of 162 and 2:1 A-V block (Fig. 6, *A*). After mild exercise there was transient 1:1 ventricular response with no change in auricular rate. Carotid sinus pressure in-

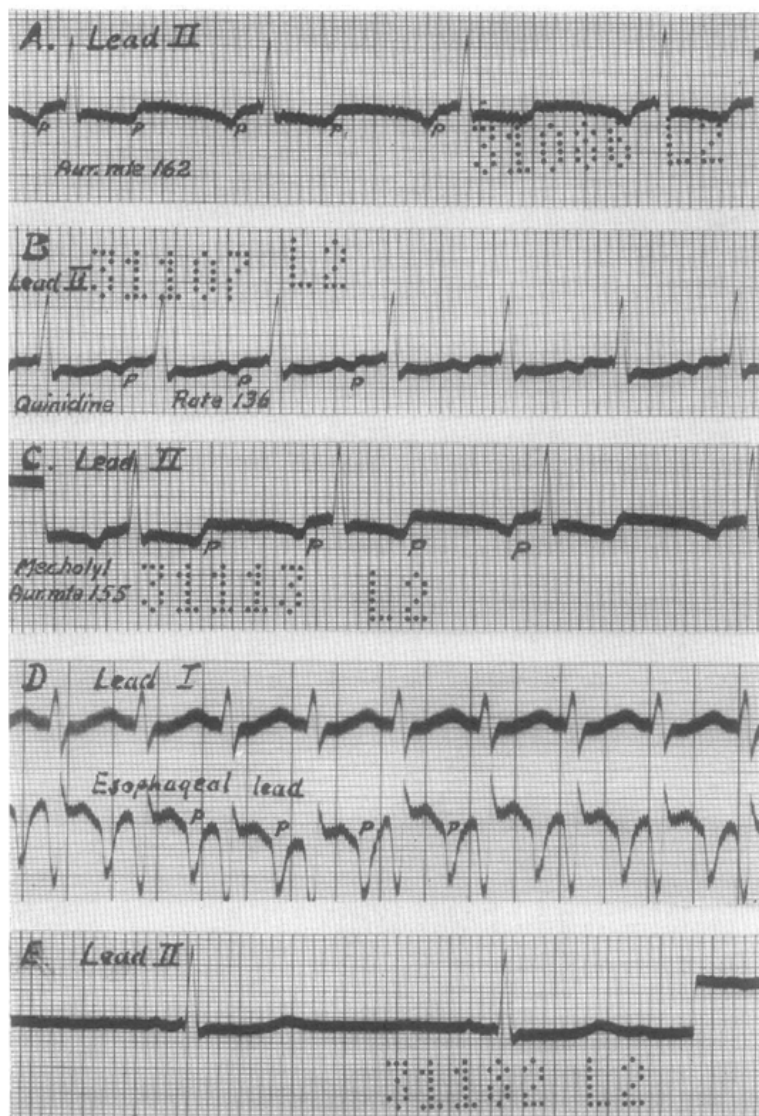


Fig. 6.—Case 6. *A*, July 22, 1938. Lead II. Auricular paroxysmal tachycardia with 2:1 A-V block. Auricular rate 162. Had had digitalis. *B*, July 25, 1938. Lead II. Auricular paroxysmal tachycardia with 1:1 ventricular response. Rate 136. Had had digitalis and quinidine. *C*, July 26, 1938. Lead II, taken 33 minutes after 10 mg. of mechohyl subcutaneously. Auricular paroxysmal tachycardia with 2:1 A-V block. Auricular rate 155. *D*, Aug. 8, 1938. Lead I above, esophageal lead below. Auricular paroxysmal tachycardia with 1:1 ventricular response. Rate 155. The auricular waves are very large in the esophageal lead. *E*, Aug. 3, 1938. Lead II. Normal rhythm. Rate 50. Had had digitalis and quinidine. Intraventricular block is present, but not readily apparent in this lead.

creased the degree of block temporarily, but did not affect the auricular mechanism or rate. Quinidine slowed the auricles to 136, usually with 2:1 ventricular response, but sometimes with 1:1 response (Fig. 6, *B*). Mecholyl, in a dose of 10 mg. subcutaneously, increased the degree of block slightly, but did not alter the auricular rate (Fig. 6, *C*). Normal rhythm returned on July 31, after large doses of quinidine sulfate (Fig. 6, *E*). On August 7 auricular paroxysmal tachycardia returned (Fig. 6, *D*). Normal rhythm was resumed after 0.9 Gm. of quinidine on August 8, and persisted thereafter. The patient was given quinidine sulfate in a dose of 0.3 Gm. three times daily. He felt quite well and there was no evidence of quinidine intoxication. He died unexpectedly in his sleep on Aug. 13, 1938.

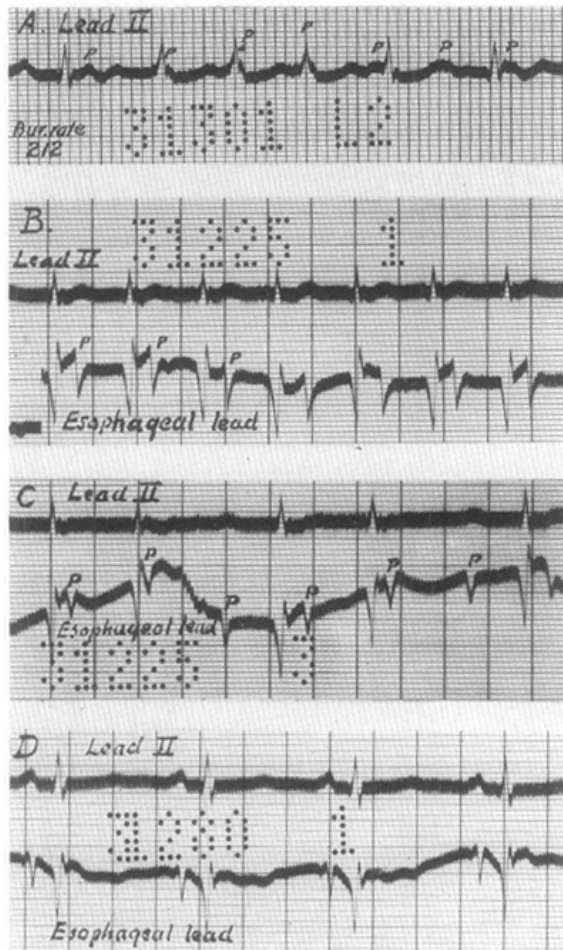


Fig. 7.—Case 7. *A*, Aug. 17, 1938. Lead II. Auricular paroxysmal tachycardia with partial A-V block and many dropped ventricular beats. Auricular rate, 212. Had had digitalis and quinidine. *B*, Aug. 6, 1938. Lead II above, esophageal lead below. There is 1:1 ventricular response. *C*, Same as *B*, but showing partial A-V block. *D*, Aug. 13, 1938. Lead II above, esophageal lead below. Normal rhythm. The auricular deflections are very large in the esophageal leads.

Autopsy showed hypertrophy of the left ventricle, the lateral wall of which measured 28 mm. in thickness. There was an old mitral valvulitis, with minimal deformity of the valve. The right side of the heart was dilated. The lungs showed congestion and edema, patchy emphysema, and atelectasis. There were acute puru-

lent bronchitis and microscopic bronchiectasis. The persistent hyperplastic thymus, generalized lymphoid hyperplasia, and hypoplasia of the aorta and adrenals suggested thymicolymphatic constitution. There was slight chronic cholecystitis, and the liver contained foci of leucocytes. The brain was not examined.

CASE 7.—A white man, aged 67 years, entered the hospital Aug. 1, 1938. He had been in good health until seven years previously, when he had a sudden attack of dyspnea which was relieved by adrenalin. Thereafter he had dyspnea when excited, and then upon moderate exertion; this increased in severity until finally he was short of breath at rest, and for the preceding few weeks he had been orthopneic. He spent the ten days before admission in a chair because of dyspnea, swelling of the legs, and sleeplessness. In four years he lost 65 pounds. There was no cough, wheezing, or chest pain.

Physical examination showed that the chest was emphysematous, with hyperresonance more pronounced on the right side. The breath sounds were absent over the right side of the chest, except in the interseapular region, where they seemed normal. There were râles at the base of the left lung. The heart was not definitely enlarged; the rate and rhythm were normal. There were no murmurs. The blood pressure was 180/106. The peripheral arteries were sclerotic. There was marked edema of the ankles.

Roentgenologic examination showed emphysema of the lungs, pneumothorax on the right, an old fibrotic scar at the left apex, and probably an inflammatory lesion at the right base. There was no abnormality of the heart or aorta.

The electrocardiogram on August 1 showed occasional auricular extrasystoles, but was normal in other respects. Digitalis was given in full doses. The patient had several attacks of auricular paroxysmal tachycardia, with partial A-V block (Fig. 7). Esophageal leads were employed to show the auricular deflections more clearly. The tachycardia was controlled only by fairly large doses of quinidine. The pneumothorax and edema cleared up satisfactorily, and the paroxysmal tachycardia did not return. The dyspnea upon slight exertion persisted. Upon one occasion tracings showed what was probably A-V nodal rhythm, with a rate of 88 per minute; the rhythm was regular, but no auricular waves could be identified.

CASE 8.—A white man, 53 years of age, entered the hospital Aug. 25, 1939. For the preceding eighteen months he had suffered from fatigue, shortness of breath, and swelling of the legs. For many years he had had a cough productive of yellowish sputum.

Physical examination showed emaciation, dyspnea, cyanosis, and pronounced edema of the feet, legs, and thighs. The lungs were resonant, but contained numerous crepitant and coarse râles throughout, and there were small areas of bronchovesicular breath sounds over the upper lobes. The heart was considerably enlarged, and there was a loud systolic murmur over the lower end of the sternum. The rhythm was regular except for occasional extrasystoles. The blood pressure was 110/78. The peripheral arteries were thickened. The liver was slightly enlarged.

Roentgenologic examination showed marked enlargement of the heart. In the lungs there were increased vascular shadows and also areas of inflammatory infiltration.

The electrocardiogram on August 26 showed normal rhythm, with occasional ventricular extrasystoles. There was right axis deviation, with inverted T waves in Leads II and III (Fig. 8, A). The patient was given digitalis in moderate amounts and improved temporarily, but there was no striking change at any time. On August 30 the electrocardiogram (Fig. 8, B) showed auricular paroxysmal tachycardia with an auricular rate of 188, and partial A-V block with a ventricular rate of 112. Later the rhythm became regular at a slower rate, and the curve of Sep-

tember 1 showed what was probably A-V nodal rhythm (Fig. 8, *C*), without any deflections which could be identified as P waves. The patient then grew gradually worse and died Sept. 5, 1939.

Autopsy showed bilateral saccular and tubular bronchiectasis and bronchiectatic abscesses. There were mucopurulent bronchitis and an old fibrous tuberculosis of the lungs and bronchial lymph nodes. The heart weighed 400 grams and showed right-sided dilatation. There were myocardial hypertrophy and brown atrophy. There were extensive subendocardial fibrosis and subepicardial fatty infiltration. There was minimal sclerosis of the coronary arteries and of the mitral and tricuspid valve leaflets.

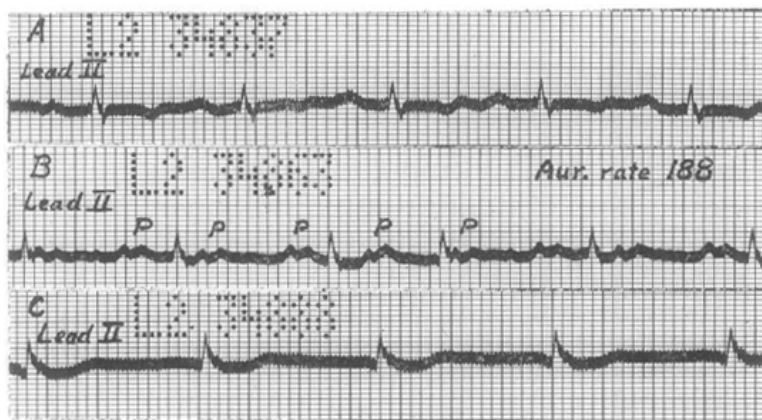


Fig. 8.—Case 8. *A*, Aug. 26, 1939. Lead II. Normal rhythm. Rate 107. *B*, Aug. 30, 1939. Lead II. Auricular paroxysmal tachycardia with partial A-V block, usually 2:1. Auricular rate 188. Had had digitalis. *C*, Sept. 1, 1939. Probably A-V nodal rhythm. Rate 88. No auricular deflections visible.

CASE 9.—A white woman, 23 years of age, was followed closely throughout the winter of 1939-1940, during a pregnancy. She gave a history of rheumatic fever in childhood, but tolerated exertion fairly well. Examination showed very slight cardiac enlargement, a blowing systolic murmur at the base, a high-pitched diastolic murmur at the left sternal margin, and a low-pitched diastolic murmur at the apex. The rate and rhythm were normal. The blood pressure was usually about 100/60. There were no signs of congestive failure.

The patient did well until March 7, 1940, when she developed acute edema of the lungs, from which she made a good recovery. On April 30, 1940, when almost at term, she was delivered of a normal infant by low Caesarean section, from which she recovered satisfactorily. Digitalis was continued in a dose of 0.1 Gm. daily. The cardiac rhythm remained normal throughout.

On July 18, 1940, she had a short attack of palpitation. On July 20 she developed shortness of breath and rapid, violent beating of the heart upon very slight exertion. Physical examination showed nothing new except slight cardiac irregularity and rather pronounced pulsation of the neck veins. The cardiac rate was 100. Upon rather mild exertion the rate rose to 210 and the rhythm was regular. The rate gradually fell to the previous level and slight irregularity returned. Pronounced but transient slowing was produced by carotid sinus pressure.

The electrocardiograms, which had previously shown normal rhythm, with broad, notched P waves (Fig. 9, *A*), now showed auricular paroxysmal tachycardia with an auricular rate of 195 (Fig. 9, *B*). There was high-grade partial A-V block, with a ventricular rate of 100. After exercise the auricular rate was 219. The

ventricles responded to each auricular beat for a short time (Fig. 9, *C*), then became slower and irregular, and finally displayed a long period of near standstill, interrupted by idioventricular beats (Fig. 9, *D* and *E*), at the end of which they resumed their previous rate of 100 per minute.

The dose of digitalis was increased for a few days, but the shortness of breath and palpitation continued, although they were less easily brought on. Quinidine was given and the patient tolerated moderate exertion without symptoms. The quinidine was stopped for a few days and the palpitation and shortness of breath returned. When quinidine was resumed the symptoms ceased. Since then quinidine has been taken irregularly. Tachycardia occurs every few days, often when quinidine has not been taken. Small amounts of quinidine are followed by normal rhythm in one or two hours.

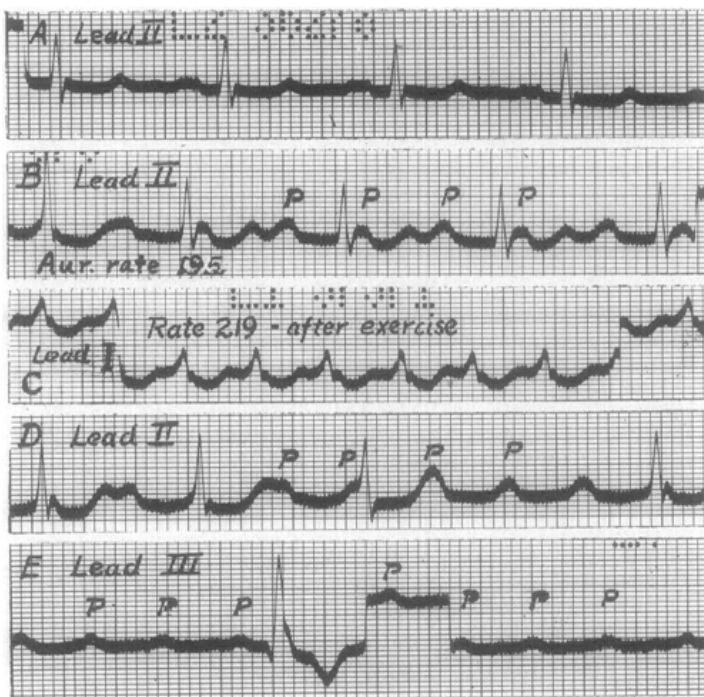


Fig. 9.—Case 9. *A*, March 12, 1940. Lead II. Normal rhythm, rate 90. *B*, July 20, 1940. Lead II. Auricular paroxysmal tachycardia, with partial A-V block. Auricular rate 195. Ventricular rate 100. Patient had had digitalis. *C*, *D*, and *E*, Leads I, II, and III, resp., July 20, 1940. After exercise, 1:1 ventricular response is followed by slowing and irregularity of the ventricles, with a period of ventricular near-standstill interrupted by idioventricular beats.

CASE 10.—A white man, aged 54 years, was first seen Feb. 14, 1940. His blood pressure had been somewhat elevated for about six years, but there had been no symptoms associated with his hypertension except nocturia. The patient considered himself in good health until Feb. 12, 1940, when he had an attack characterized by a feeling of numbness in the precordium, nausea, and profound weakness. There was no pain or shortness of breath. Examination showed that the patient was overweight. There was slight enlargement of the heart, but no murmurs. The rate was about 70, and there were frequent premature beats. The blood pressure was 150/125. The remainder of the examination was negative. The electrocardiogram (Fig. 10, *A*) showed frequent auricular extrasystoles and slight left axis deviation, with inverted T waves in Lead I. The precordial leads were normal

with the exception of inversion of the T waves in the lead taken in the left anterior axillary line. There were no further attacks of this type. He was given theophylline and digitalis. After digitalization the dosage of this drug was reduced to 0.1 Gm. daily, but in September he took 0.2 Gm. daily.

During the night of Sept. 21, 1940, he began having vague precordial discomfort, described as a sense of pressure or numbness or shakiness, and nausea and vomiting. There was no pain, shortness of breath, or edema. He was given digitalis (0.4 Gm.) on September 23. Physical examination on September 24 showed that the heart was slightly enlarged. The rate varied between 44 and 52 per minute. There were periods of bigeminy. At times there were numerous premature beats. At other times the rhythm was regular. The heart sounds varied in intensity when the ventricles were beating slowly and regularly. Pulsations in the neck veins were counted at approximately 200 per minute. The blood pressure was 164/120. The

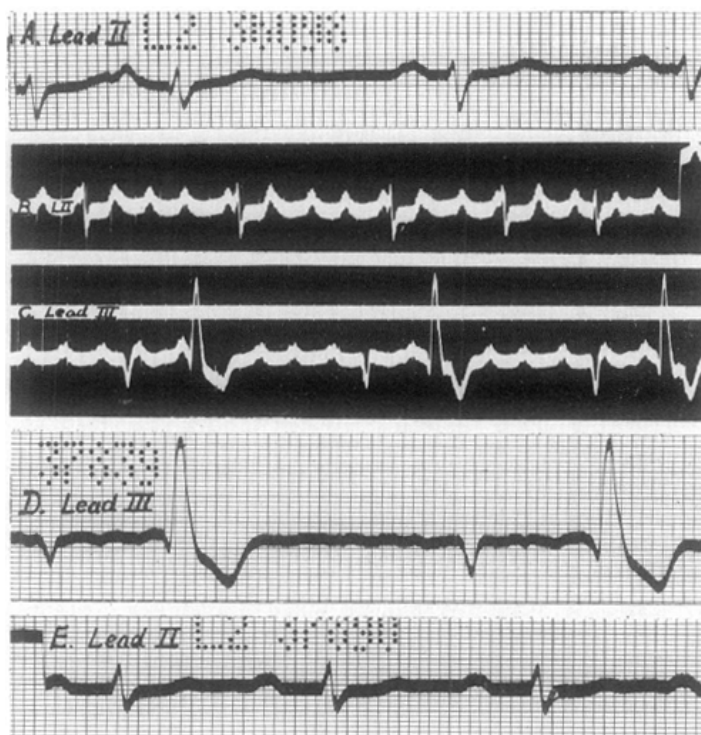


Fig. 10.—Case 10. *A*, Feb. 14, 1940. Lead II. Normal rhythm with auricular extrasystoles. P-R 0.20 sec. *B*, Sept. 24, 1940. Lead II. Auricular paroxysmal tachycardia with partial A-V block. Auricular rate 200. Ventricular rate 56. *C*, Sept. 24, 1940. Lead III. Auricular paroxysmal tachycardia with partial A-V block and extrasystolic bigeminy. Ventricular rate 58. In *B* and *C* the auricles are slightly irregular. Patient had been overdigitalized. *D*, Sept. 26, 1940. Lead III. Auricular fibrillation. Bigeminy. *E*, Oct. 2, 1940. Lead II. Normal rhythm. Prolonged P-R interval (0.28 sec.).

remainder of the examination was negative. The electrocardiograms showed auricular paroxysmal tachycardia with high-grade A-V block (Fig. 10, *B*). The auricular rate was 200, the ventricular rate, 56. There were ventricular extrasystoles and extrasystolic bigeminy (Fig. 10, *C*). Digitalis was stopped. Subsequent electrocardiograms showed auricular fibrillation (Fig. 10, *D*), and a few days later normal rhythm (Fig. 10, *E*). The patient dropped dead in December, 1941.

CASE 11.—A white man, 52 years of age, was admitted March 15, 1939, complaining of shortness of breath and swelling of the legs. These symptoms followed an acute respiratory infection which had occurred three weeks previously, and they became increasingly severe; the edema extended upward to include the abdomen. Examination showed that the heart was markedly enlarged; the rhythm was regular and the rate was 85. There were no murmurs. The blood pressure was 144/110. The arteries were not tortuous. There were dullness, diminished breath sounds, and râles at the bases of the lungs. The liver was enlarged and there was a little ascites. There was marked edema of the lower extremities, genitalia, and abdominal wall.

Roentgenologic examination showed marked enlargement of the heart.

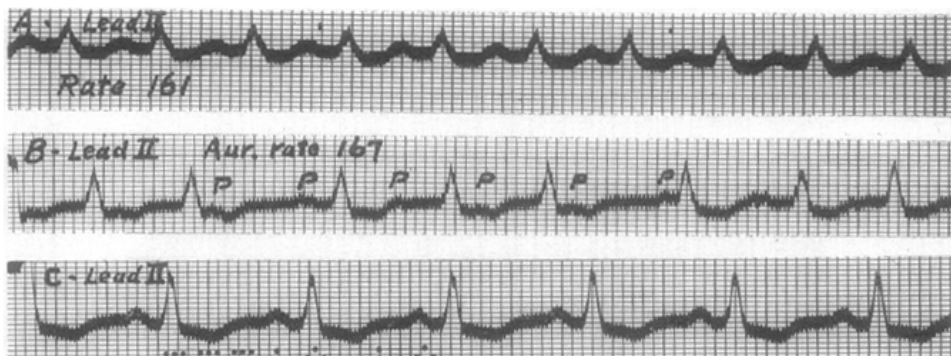


Fig. 11.—Case 11. *A*, March 18, 1939. Lead II. Paroxysmal tachycardia of supra-ventricular origin. Rate, 161. *B*, March 20, 1939. Lead II. After 2.4 grams of digitalis in 5 days. Auricular paroxysmal tachycardia with partial A-V block. Auricular rate 167, ventricular rate 131. *C*, March 21, 1939. Lead II. Normal rhythm, rate 107.

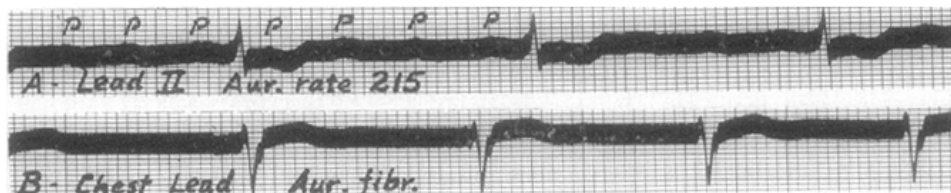


Fig. 12.—Case 12. *A*, Nov. 10, 1941. Lead II. Auricular paroxysmal tachycardia with 4:1 A-V block. Auricular rate, 215. *B*, Nov. 11, 1941. Precordial lead. Auricular fibrillation, ventricular rate 69.

On March 18 there occurred an attack of tachycardia which was shown by the electrocardiogram (Fig. 11, *A*) to be of supra-ventricular origin. The patient developed acute edema of the lungs, and the blood pressure rose to 170/120. He was almost moribund. By March 20 he had received 2.4 Gm. of digitalis in five days, and the tracing (Fig. 11, *B*) showed auricular paroxysmal tachycardia with partial A-V block. The auricular rate was 167, and the ventricular rate, 131, per minute. On the following day normal rhythm was present (Fig. 11, *C*). After this the patient improved remarkably; the blood pressure fell to 120/80 and the size of the heart returned almost to normal.

CASE 12.—A white man, aged 80 years, entered the hospital Nov. 8, 1941, because of urinary obstruction of three weeks' duration caused by benign enlargement of the prostate. He had suffered from shortness of breath for four years, and had been taking digitalis for three years. Examination showed evidence of senility

and emaciation. The heart was slightly enlarged and was irregular; the rate was 68. There were no murmurs. The blood pressure was 110/80. The peripheral arteries were thickened. The lungs were normal. The liver was not enlarged. There was edema of the left ankle which was attributed to varicose veins.

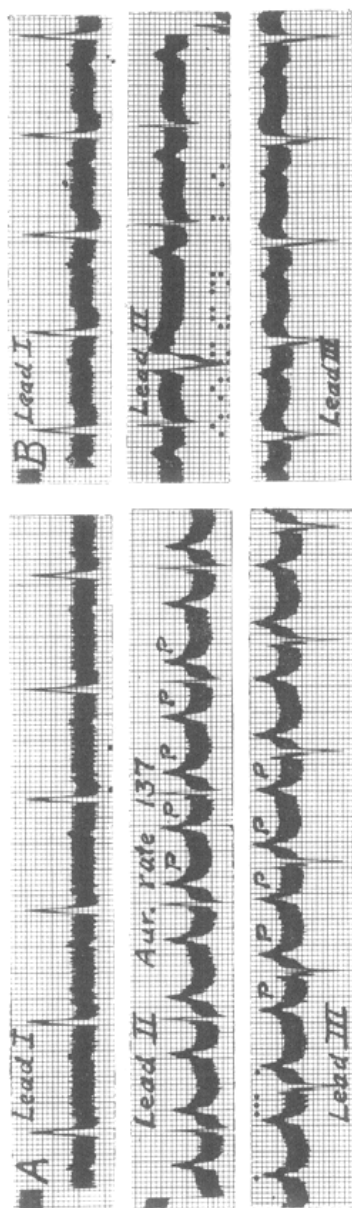


Fig. 13.—Case 13. *A*, May 25, 1935. Auricular paroxysmal tachycardia with 2:1 A-V block. Auricular rate 137. *B*, May 27, 1935. Normal rhythm with ventricular extrasystoles and prolonged P-R interval (0.24 sec.).

Digitalis, in a dose of 0.5 Gm., was given November 9. On the following day the electrocardiogram (Fig. 12, *A*) showed auricular paroxysmal tachycardia with partial A-V block, usually 4:1, with an auricular rate of 215 and a ventricular rate of 55 per minute. On November 11 the tracing (Fig. 12, *B*) showed auricular fibrillation with a ventricular rate of 60. There were many idioventricular beats, indicating overdigitalization. Subsequently the patient had a transurethral resection of the prostate, from which he made a good recovery.

CASE 13.—A white man, 68 years of age, was examined May 24, 1935. He had been troubled with attacks of nausea and vomiting. Examination showed that the heart was of normal size, but irregular, with a rate of 68 per minute. The lungs were normal, and the abdomen was negative. There was no edema. An electrocardiogram on the following day (Fig. 13, *A*) showed auricular paroxysmal tachycardia with 2:1 A-V block. The auricular rate was 137, and the ventricular rate, 68, per minute. There were a few ventricular extrasystoles. On May 27 the rhythm was normal except for ventricular extrasystoles (Fig. 13, *B*). A few months later the patient developed cardiac failure, but the cardiac rhythm remained normal.

CASE 14.—A white woman, 17 years of age, was admitted Nov. 1, 1932. She gave a history of nervousness, weakness, fatigue, palpitation, and irregularity of the heart. These symptoms began in August, 1931, and improved temporarily under iodine therapy in January, 1932. Enlargement of the thyroid gland appeared at that time. The palpitation was described as forceful beating of the heart, and the irregularity as a skipping of beats. No attacks or paroxysms of tachycardia or irregularity were noticed.

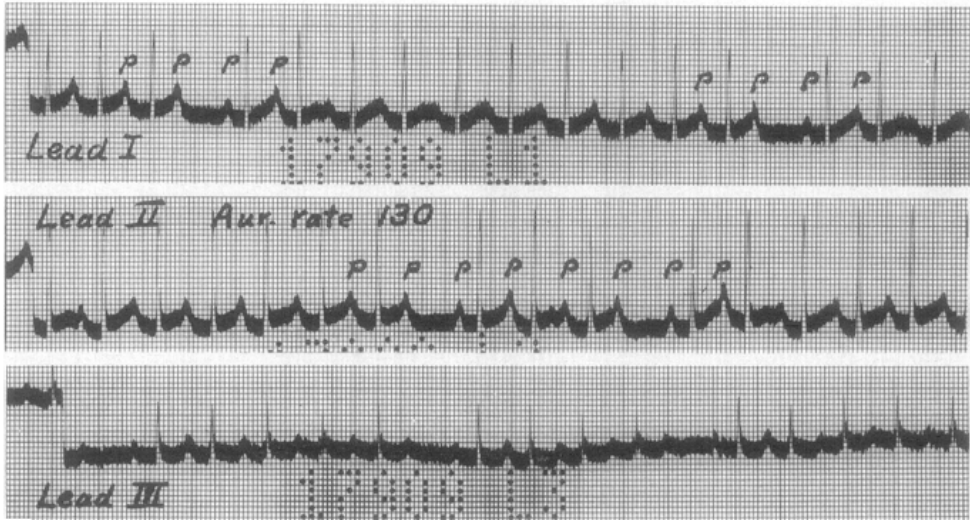

Fig. 14.—Case 14. Leads I, II, and III. Probably auricular paroxysmal tachycardia and partial A-V block with dropped beats. Auricular rate, 130.

Examination showed moderate enlargement of the thyroid, with a bruit over the gland. There were exophthalmos and a fine tremor of the fingers. The heart was normal in size, and there seemed to be numerous dropped beats. The rate was 108. There were no murmurs. The blood pressure was 135/78. There were no signs of congestive failure. The basal metabolic rate was plus 45 per cent. Roentgenologic examination showed no abnormality of the heart. The electrocardiogram (Fig. 14) showed an auricular rate of 130 and partial A-V block, with frequent dropped beats. Subsequently the rhythm seemed normal clinically, but no other electrocardiograms were taken. A subtotal thyroidectomy was followed by a good recovery. It is possible that this patient had auricular paroxysmal tachycardia with partial A-V block, but this is not certain.

CASE 15.—A white man, 64 years of age, was admitted Jan. 18, 1933. For four months he had suffered from attacks of rapid beating of the heart and shortness of breath; these lasted a few minutes and occurred several times a day. Exami-

nation showed that the patient was overweight. The heart was moderately enlarged, and there were faint systolic murmurs at the apex and base. The rhythm was irregular, and the rate was approximately 200 per minute. The blood pressure was 120, systolic. There were no signs of congestive cardiac failure. There were abrupt changes from tachycardia to normal rate, and from normal rate to tachycardia. The tachycardia was stopped by pressure upon the right carotid sinus, but soon returned. Many electrocardiograms were obtained, and showed a complicated arrhythmia. There were many brief attacks of tachycardia, apparently arising from two or more foci in the auricles, which had an abrupt onset and termination. There was also variation in the form of the ventricular deflections. In addition, there were brief periods of partial A-V block, as shown in Fig. 15. There were also premature ventricular deflections of abnormal outline, some of which probably were ventricular extrasystoles. Quinidine was given irregularly from January 21 to 24 without apparent benefit. Digitalization was begun on January 25 and completed on January 27, and then maintained by 0.1 Gm. daily. After this there were occasional auricular extrasystoles (Fig. 15, D), but no further attacks of tachycardia or dyspnea.

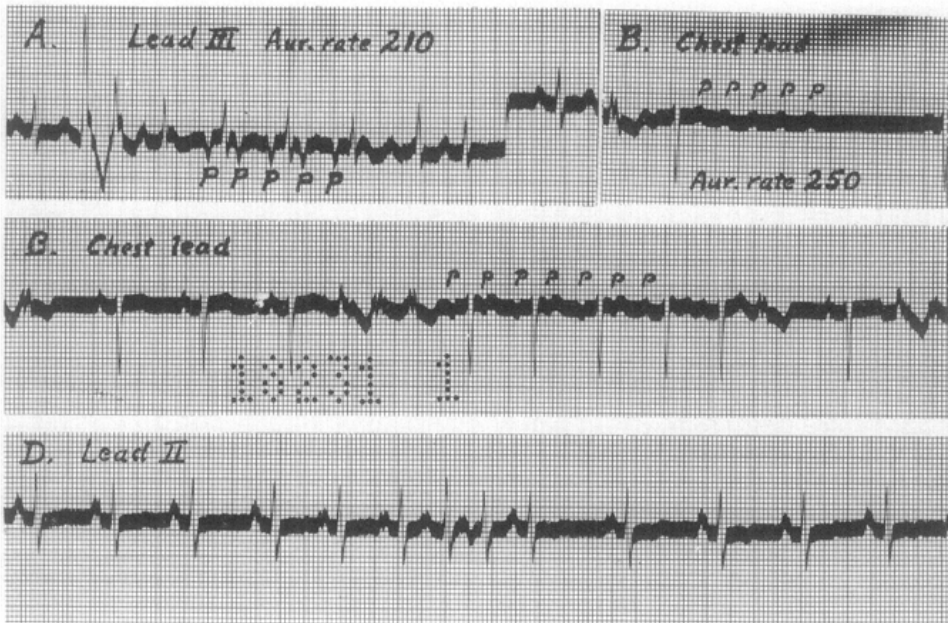


Fig. 15.—Case 15. A, Jan. 19, 1933. Lead III. A short paroxysm of tachycardia arising in at least two different foci in the auricles, and showing partial A-V block. Auricular rate 210. B, Jan. 21, 1933. Precordial lead. Unusual mode of termination of an attack; there is A-V block. Auricular rate 250. C, Jan. 21, 1933. Precordial lead. A short attack showing partial A-V block. Auricular rate approximately 200. D, Jan. 24, 1933. Lead II. Normal rhythm with auricular extrasystoles.

CASE 16.—A 26-year-old white woman entered the hospital March 13, 1929. For nearly a year she had suffered from shortness of breath, palpitation, swelling of the ankles, and nocturia. For the preceding month the swelling had been more extensive, involving the legs, thighs, and abdomen. There was no history of rheumatic fever.

Physical examination showed that the patient was dyspneic, orthopneic, and cyanotic. There was pronounced edema of both lower extremities, the right upper extremity, and the right breast. The heart was markedly enlarged. A systolic

murmur and gallop rhythm were present at the apex. No diastolic murmur was heard. The rhythm was regular, and the rate was 132 per minute. The blood pressure was 170/128. There were râles at the bases of the lungs. The liver and spleen were enlarged.

Röntgenologic examination showed marked cardiac enlargement and congestion of the lungs.

The electrocardiogram (Fig. 16, *A*) was taken March 16, 1929, after 1.8 Gm. of digitalis had been given. There was complete atrioventricular dissociation. The auricles and the ventricles were beating regularly and independently, the former at a rate of 160 and the latter at 84 per minute. No other electrocardiograms were obtained during this admission. The patient improved rapidly. Diuresis was accompanied by a loss of weight from 297 to 137 pounds. The blood pressure fell to 140/100, and the heart rate to 85.

The patient returned to the hospital July 31, 1931. Her symptoms and physical signs were essentially the same as on the previous admission. The blood pressure was 200/150. The heart rate varied from 90 to 75 per minute, and the electrocardiogram (Fig. 16, *B*) showed normal rhythm. In this curve the P waves are of different outline, as compared with the previous curve. The patient again improved.

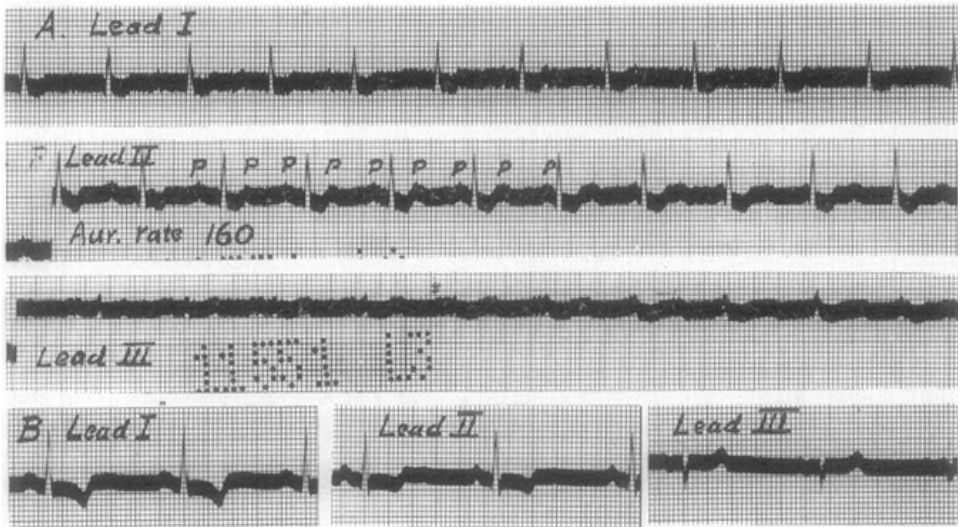


Fig. 16.—Case 16. *A*, March 16, 1929. Leads I, II, and III. Auricular paroxysmal tachycardia with complete dissociation. Auricular rate 160, ventricular rate, 84. *B*, Aug. 11, 1931. Leads I, II, and III. Normal rhythm.

CASE 17.—A 48-year-old white man entered the hospital May 12, 1942. He had felt well until one year previously. At that time he developed severe dyspnea during moderate exertion. It was relieved by morphine. His blood pressure was found to be 220. After that his pressure remained high, and he had headaches, blurred vision, and attacks of paroxysmal nocturnal dyspnea. Two months prior to admission his blood pressure was 240. A diagnosis of myocardial infarction was made by his physician. Since then he had been at rest in bed, and had taken digitalis regularly. There was no history of pain in the chest or edema of the extremities.

Physical examination showed an obese man who was dyspneic, orthopneic, and slightly cyanotic. The eye grounds showed evidence of retinal arteriosclerosis and

angiospasm. The heart was enlarged and was beating regularly at a rate of 120. The heart sounds were scarcely audible because of many coarse bubbling râles in the lungs. The blood pressure was 230/150. The peripheral vessels were not appreciably thickened. The liver was not enlarged. There was no edema of the extremities.

Shortly after admission, while being examined, the patient had an attack of acute pulmonary edema, from which he recovered after the administration of theophylline intravenously, and morphine, and phlebotomy, with the removal of 500 c.c. of blood, and the use of the oxygen tent. He was given 1.6 Gm. of digitalis in twelve hours, which caused nausea and vomiting. On the following day the patient was still somewhat dyspneic, and the blood pressure was 180/120. There was no pain in the chest. During the next few days the temperature rose to 99.6° F., the leucocyte count rose from 10,000 to 14,000 per c. mm., and the patient gradually improved. He was discharged May 26, 1942.

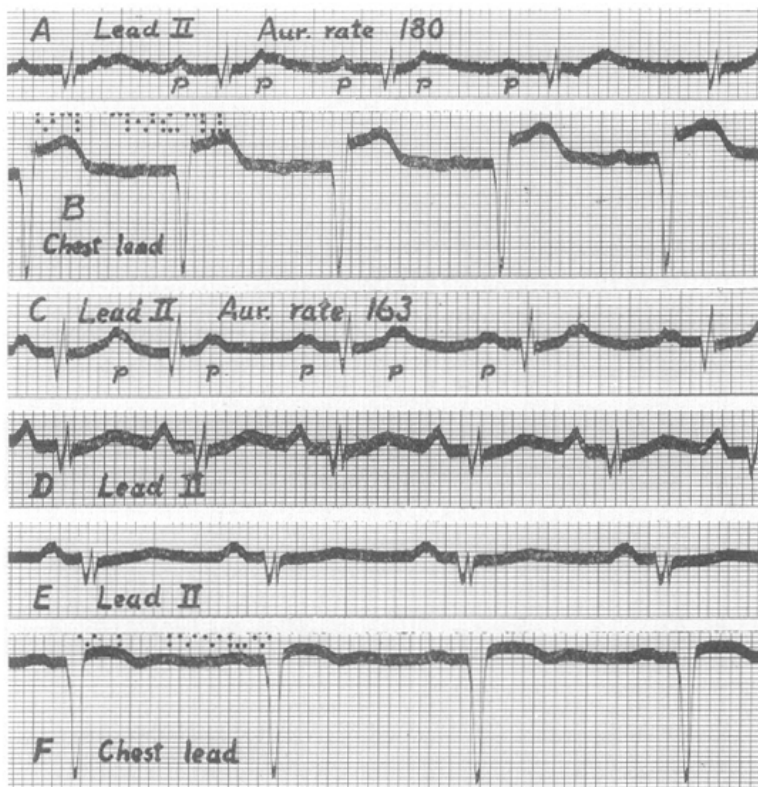


Fig. 17.—Case 17. *A*, May 13, 1942. Lead II. Auricular paroxysmal tachycardia with 2:1 A-V block. Auricular rate, 180. *B*, May 13, 1942. Precordial lead showing the changes of recent myocardial infarction. *C*, May 15, 1942, 2:15 P.M. Lead II. Auricular paroxysmal tachycardia with partial A-V block, usually 2:1. Auricular rate 163. Note the change in the form of the P waves. *D*, May 15, 1942, 4:50 P.M. Lead II. Normal rhythm. *E*, May 20, 1942. Lead II. Normal rhythm. Note the change in the form of the P waves. *F*, May 20, 1942. Precordial lead showing the expected progression of the changes accompanying myocardial infarction.

The first electrocardiogram (Fig. 17, *A*) was obtained May 13, 1942, the day after admission. It showed auricular paroxysmal tachycardia with 2:1 A-V block; the auricular rate was 180. Precordial leads showed changes suggesting very recent myocardial infarction (Fig. 17, *B*). On May 15, at 2:15 P.M. (Fig. 17, *C*), the auricular paroxysmal tachycardia was still present, with 2:1 A-V block most of the

time, and an auricular rate of 163. The auricular deflections were somewhat different in form from those of the previous curve. At 4:50 P.M. of the same day, normal rhythm was present, and the rate was 107 (Fig. 17, *D*). On May 20, 1942 (Fig. 17, *E*), normal rhythm was still present; the auricular deflections were different in form from those of the previous curve, and the rate was slower. Pre-cordial leads showed the expected progression of the changes of myocardial infarction (Fig. 17, *F*).

CASE 18.—A white man, 45 years of age, was a patient in the hospital from July 5 to 15, 1940. Four years previously he had experienced sudden, severe pain beneath the sternum which persisted for four hours and was relieved by morphine. After that he was subject to substernal pain upon slight effort. For about nine months he had been dyspneic upon mild exertion and sometimes at rest. The breathing was often noisy. Cough had been present for four months. He was found to be allergic to house dust and several other substances, and was given epinephrine by nebulizer and ephedrine by mouth. There had been no edema of the extremities. Examination showed slight cardiac enlargement, presystolic gallop rhythm, and many wheezing, musical, and crackling râles in the lungs. The blood pressure was 130/94. He was given rest and digitalis, and improved remarkably.

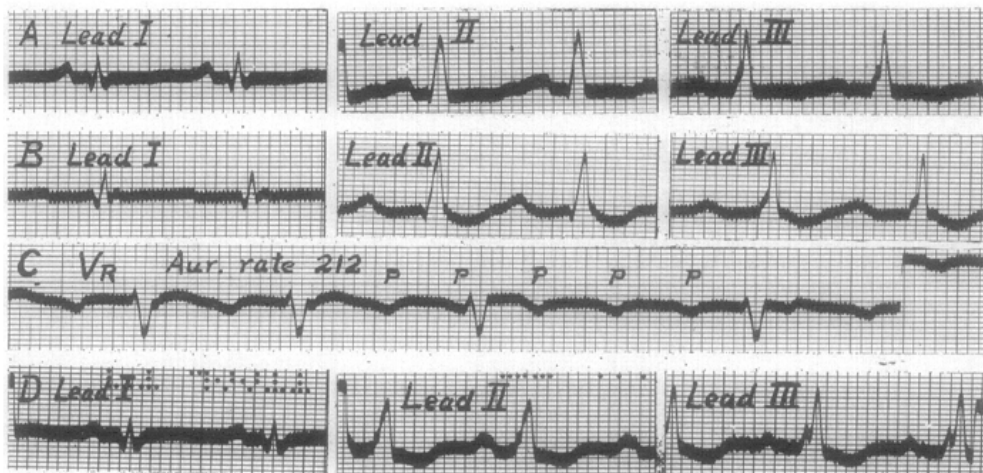


Fig. 18.—Case 18. *A*, July 6, 1940. Leads I, II and III. Normal rhythm. *B*, June 2, 1942. Leads I, II, and III. Auricular paroxysmal tachycardia with 2:1 A-V block. The auricular tachycardia is not readily apparent in these leads. *C*, June 2, 1942. Right arm potential (right arm electrode paired with the central terminal) taken a few seconds after *B*. The auricular tachycardia is clearly revealed during the short periods of 3:1 A-V block. *D*, June 9, 1942. Leads I, II, and III. Normal rhythm.

After being free from symptoms for six months, he began having shortness of breath again. In October, 1941, the substernal pain recurred, and thereafter orthopnea and edema of the ankles developed. He continued taking digitalis regularly. On May 25, 1942, he had an attack of tachycardia which was abrupt in onset and termination, lasted one hour, and was accompanied by substernal pain. He returned to the hospital June 1, 1942. Examination showed a dyspneic, apprehensive man with a severe, nonproductive cough. There were many musical and crepitant râles in the lungs. The heart was slightly enlarged, and gallop rhythm was present. The blood pressure was 152/118. There was slight edema of the ankles.

On the second hospital day (June 2, 1942), he developed tachycardia, accompanied by substernal pain. The heart rate was 160; it was slowed temporarily by pressure upon the left carotid sinus, but the tachycardia returned promptly upon cessation of the pressure. On June 4 the pulse was slower and the tachycardia had ceased after persisting for two days. There was, however, no other change in the patient's condition. He gradually improved.

The electrocardiograms on the first admission showed changes suggestive of old myocardial infarction (Fig. 18, *A*). On June 2, 1942, the curve showed auricular paroxysmal tachycardia with an auricular rate of 212 and partial A-V block, usually 2:1, sometimes 3:1 (Fig. 18, *B* and *C*). Normal rhythm was present on June 4 and persisted (Fig. 18, *D*).

COMMENT

Clinical Features.—Our interest in auricular paroxysmal tachycardia with A-V block was aroused by seeing 7 patients with this disturbance in the brief period of ten months, from October, 1937, to August, 1938. A review of 100 unselected cases of auricular paroxysmal tachycardia revealed 8 additional cases in which there was A-V block. The essential data in one additional case were supplied by Dr. John Parkinson (Case 1). The last 2 cases are of interest because of the associated myocardial infarction. In 8 of these 18 cases the tachycardia was the outstanding symptom, and in 5 it caused moderate to marked disability. In 4 other cases the tachycardia, although not the chief difficulty, was of importance in that it contributed to the disability of the patients. In the remaining 6 cases there was no disability, or the abnormal rhythm was merely an incident in the course of other more important conditions.

The degree of disability experienced by these patients is often greater than that which occurs with the common type of auricular paroxysmal tachycardia. In 29 cases it was possible to estimate the degree of disability. It was marked in 10, moderate in 7, and slight in 6. There was no apparent disability in 2, and in 4 others the abnormal rhythm was merely an incident of relatively minor importance in the course of some other illness. In general, the patients with organic heart disease and those with attacks of longer duration suffered more pronounced disability than the others (see Table I). Two patients developed acute edema of the lungs; both of these had organic heart disease. Another patient without organic heart disease died of cardiac failure caused by paroxysmal tachycardia which had been present almost continuously for three months.

In auricular paroxysmal tachycardia with A-V block, the duration of the attacks is often longer than in the common type of auricular paroxysmal tachycardia. Of the 17 previously reported cases, in 8 the attacks lasted several days; the longest was ninety-four days. Of our 18 patients, 13 had attacks lasting two days or longer. Three of these are known to have had attacks lasting twenty-six, sixty, and thirteen days, respectively. On the other hand, in 3 of the previous cases and in 3 of our own there were brief attacks which lasted only a few minutes.

The auricular rate is usually between 165 and 200 per minute.

Faster and slower rates sometimes occur. Four patients showed, at times, rates of 121, 120, 120, and 129 per minute, respectively. In one of these (Case 15) the slowing was caused by digitalis, and in another (Case 17) by assuming the recumbent posture, whereas in our Case 4 it was attributed to quinidine. Three of our other patients showed auricular rates of 136, 137, and 130 per minute, respectively, and in one of these the slowing was caused by quinidine (Case 6). Very rapid auricular rates are sometimes encountered. Lewis' patient¹ had a rate of 290 per minute. The first of the patients of Sprague and White⁶ showed a rate of 270 upon one occasion. Two of our patients had, at times, rates of 235 and 250 per minute, respectively. In some cases the auricular rate shows rather pronounced variations, usually in response to drugs.

The onset and termination of the abnormal auricular activity have been recorded graphically in several instances. They were abrupt, just as in paroxysmal tachycardia without A-V block. The case reported by Maddox¹¹ is exceptional in that the attack of tachycardia terminated by gradual slowing of the rate over a period of several days. In this and in many other respects it resembled that reported by Field, Barker, and Alexander.¹⁵

As a rule there is an abrupt transition from normal rhythm to paroxysmal tachycardia at the onset, and from paroxysmal tachycardia to normal rhythm at the termination of the attacks. In Dock's case,⁸ after 5 Gm. of digitalis in sixteen days, the mechanism changed to atrioventricular bradycardia with reciprocating rhythm. In Brown's patient,¹⁰ after large amounts of digitalis, the mechanism changed from auricular paroxysmal tachycardia to auricular fibrillation, and then to normal rhythm. One of our patients (Case 10) had auricular paroxysmal tachycardia with A-V block at a time when he was overdigitalized. Shortly after the digitalis was stopped the mechanism changed to auricular fibrillation, and then to normal rhythm (Fig. 10). Another patient (Case 12) was likewise overdigitalized when the paroxysmal tachycardia was present. On the following day the rhythm changed to auricular fibrillation, which persisted (Fig. 12). Although the transitions were not recorded, it seems highly probable that in these 3 cases the auricular paroxysmal tachycardia changed directly to auricular fibrillation without intervening normal rhythm. Spontaneous transitions from paroxysmal tachycardia to auricular flutter or fibrillation have been recorded, as have changes from flutter or fibrillation to paroxysmal tachycardia. Parkinson and Mathias¹⁶ observed a patient with auricular paroxysmal tachycardia whose rate increased progressively until there was a gradual transition to auricular flutter. Records were obtained by Carr¹⁷ on a patient with many short paroxysms of tachycardia arising in the A-V node who showed auricular flutter for a few seconds at the onset and termination of the attacks. This patient had received moderate amounts of digitalis. Lewis¹⁸ has reported a case

in which auricular fibrillation apparently changed to auricular paroxysmal tachycardia; the record of the transition was not published. It is possible that digitalis was responsible for the change to auricular fibrillation in the cases mentioned above, although in other cases of auricular paroxysmal tachycardia digitalis has restored normal rhythm without intervening auricular flutter or fibrillation.

In our Case 2 auricular flutter and auricular fibrillation were observed at different times, but it is not known whether there were transitions from either of these abnormal rhythms to paroxysmal tachycardia or vice versa. It is of interest that, of 100 unselected cases of auricular paroxysmal tachycardia, in only 5 was the patient known to have had auricular flutter or fibrillation, and that 3 of these had partial A-V block.

In some of the cases in which the onset or termination of an attack was recorded there was 1:1 ventricular response; the A-V block appeared during the course of the paroxysm. In other instances the block was present at the very beginning of the attack or continued to its very end.

In most cases the A-V block was fairly persistent or was maintained by digitalis, but 1:1 response could be brought on by exertion or occurred when digitalis was not taken. In some instances the patient was aware of the abnormal cardiac mechanism only during the periods of 1:1 ventricular response, which began and ended suddenly. The occurrence of 1:1 response increased the severity of the symptoms and accounted for the disability of some of the patients. Others, however, were incapacitated even with ventricular rates of about 100 per minute. In a few cases the block was transient and of short duration.

Patients with auricular paroxysmal tachycardia and partial A-V block are often very resistant to treatment. This is reflected in the long duration of some of the attacks. Pressure upon the carotid sinus restored normal rhythm only in Case 12 (Mackinnon). In many other cases it failed to do so. It commonly increased the degree of block and slowed the ventricles temporarily.

Digitalis was beneficial in 7 of the 17 previously reported cases: normal rhythm returned soon after the administration of full doses. In Cases 11 and 15 it was given without benefit, and, in the other 8 cases, it was apparently not used. Digitalis was given in 16 of our 18 cases, and in only 7 did it appear beneficial. In only 4 of these did normal rhythm return soon after the administration of the drug. In the other 3 it increased the degree of A-V block and prevented, in part, the occurrence of 1:1 response, so that the patients were improved symptomatically, but normal rhythm returned several days or weeks after full digitalization, and could not be attributed definitely to the drug. In some of the other cases digitalis may have been at least partly responsible for the partial A-V block, but did not appear to be beneficial in other respects. Digitalis sometimes causes considerable slowing of the auricular rate (Cases 4 and 14).

Quinidine was given in 5 of the previously reported cases. It prevented the attacks of paroxysmal tachycardia in Case 17 (Fine and Miller), but was without value in Cases 5, 6, 7, and 15. Quinine likewise was given in 5 of the previously reported cases. It restored normal rhythm in 3 (Cases 2, 8, and 10), but was without benefit in Cases 4 and 15. Quinidine was given to 8 of our patients. It restored normal rhythm in Cases 6, 7, and 9. In Cases 6 and 7, its continued use definitely prevented the return of the tachycardia, and in Case 9 it was probably of some benefit in preventing recurrences. In Cases 1, 2, 3, 4, and 15, quinidine was given without apparent benefit, although it slowed the auricular rate in Cases 3 and 4. There was no adequate explanation for death in Case 6; the patient had been taking quinidine sulfate in a dose of 0.3 Gm. 3 times daily for several days, but it is scarcely possible that this could have been responsible. Quinine was used in Case 2 without apparent benefit. Both quinidine and quinine sometimes cause conspicuous slowing of the auricular rate (Case 4 and our Cases 3, 4, and 6).

Mecholyl was given to 3 of our patients. It caused transient slowing of the ventricles by increasing the degree of block, but did not restore normal rhythm.

Electrocardiograms.—In the common type of auricular paroxysmal tachycardia the P waves are often almost indistinguishable because they are very small or flat, or because, in addition to being small, they fall upon some part of the ventricular complex. In about one-sixth of the cases the P waves are inverted. In only about 30 per cent are they upright and approximately similar in form to the P waves of normal rhythm. In auricular paroxysmal tachycardia with A-V block, about 60 per cent of the patients have P waves which are upright or largely so, and resemble, perhaps not exactly, but at least fairly closely, the P waves of normal rhythm. When P is diphasic or notched, it often shows a similar configuration during normal rhythm. The similarity of the P waves during the tachycardia and during normal rhythm is shown in 6 of the previously reported cases (Cases 3, 6, 7, 8, 9, and 15), and is well illustrated in ten cases of the present series (Cases 1, 2, 3, 5, 7, 10, 11, 13, 16, and 18). This indicates that in these cases the paroxysmal tachycardia had its origin near the sinoauricular node. It is possible that A-V block is more likely to occur in such cases, as compared with cases in which the form of P suggests an origin near the auriculoventricular node. In Cases 12 and 14 the P waves were upright during the tachycardia, but no tracings of normal rhythm were obtained for comparison. In 6 of the previously reported cases (Cases 2, 4, 5, 11, 14, and 17) and in 6 cases of our series (Cases 4, 6, 8, 9, 15, and 17) the P waves during the tachycardia were quite different from the P waves of normal rhythm. In Cases 4 and 8, P was very small during the tachycardia, whereas, in Cases 6 and 15, it was inverted. In Cases 9 and 17, the P waves were upright during the tachycardia but quite different in form from those of normal rhythm.

When the P waves are small or indistinct in the standard leads, it may not be possible to identify them with certainty, or to ascertain what type of arrhythmia is present. Under such circumstances it may be helpful to employ chest leads. By leading from two precordial contacts, one over the upper part of the sternum and the other over the ensiform, it is usually possible to record large auricular waves which are readily identified. This is well illustrated in Case 4 (Fig. 4). Esophageal leads may be even more helpful, for they invariably yield very large auricular deflections when employed as described by Brown.¹⁰ They may be especially helpful in distinguishing auricular paroxysmal tachycardia from flutter. In the former the auricular deflections are separated, during A-V block, by periods of electrical quiescence, in which the curve is at rest on the base line, whereas, in the latter, the curve is never at rest, but shows continuous changes in electrical potential (Figs. 2 and 7). These observations confirm those of Brown. The use of esophageal leads, however, imposes some hardship upon the patient.

The partial A-V block seems to be caused by the abnormally high auricular rate, at least to a considerable degree. In some of the patients, digitalis was a contributing factor. In none of the previously reported cases was there abnormal prolongation of the P-R interval during normal rhythm, although in several it was 0.20 second. In Case 2 (Singer and Winterberg), complete block persisted after the termination of the paroxysmal tachycardia. In the present series, likewise, the P-R interval was nearly always normal during normal rhythm, but there were a few exceptions. In Case 4 it was 0.22 second at times, but large amounts of digitalis had been given. In Case 10 the P-R interval was 0.20 second several months before the tachycardia occurred and before digitalis was given; when normal rhythm returned after the paroxysmal tachycardia it was 0.28 second, but the patient had been overdigitalized. One patient (Case 13) had a P-R interval of 0.24 second on the day when normal rhythm returned, and he had received no drugs; four months later it was 0.19 second.

The occurrence of auricular flutter and auricular fibrillation in Cases 2, 10, and 12 has been mentioned. Two other patients (Cases 7 and 8) showed abnormal auricular mechanism after cessation of the paroxysmal tachycardia; they yielded curves in which no auricular waves could be identified. It was thought that they might represent A-V nodal rhythm, but no special leads were employed and no large venous pulsations were observed, and it is possible that there was auricular standstill. The ventricles were beating regularly at normal rates. In several cases normal rhythm was disturbed by occasional auricular extrasystoles. One patient (Case 17) showed changes in the form of the P waves, both during the paroxysm of tachycardia and during normal rhythm shortly after the cessation of the attack.

The Mechanism of Auricular Paroxysmal Tachycardia.—Auricular paroxysmal tachycardia with partial A-V block resembles auricular flutter in many respects. It resembles flutter much more closely than does the common type of auricular paroxysmal tachycardia. The similarities extend beyond the presence of the partial block and the relatively long duration of some of the attacks. Quinidine and quinine often slow the auricular rate in auricular paroxysmal tachycardia and always do so in auricular flutter. In a few cases, digitalis in large amounts apparently converted auricular paroxysmal tachycardia into auricular fibrillation, a common occurrence in auricular flutter. In these cases, as in flutter, pressure upon the carotid sinus temporarily increases the degree of block and slows the ventricles, but almost never stops the attacks of abnormal rhythm. With respect to A-V block, the differences between auricular paroxysmal tachycardia and auricular flutter may be caused chiefly by the differences in the auricular rates in the two conditions.

In spite of the resemblances between auricular paroxysmal tachycardia with partial A-V block and auricular flutter, the two conditions differ from each other in several important respects. Digitalis sometimes slows the auricular rate in the former, whereas, in the latter, it has little effect, or induces auricular fibrillation. Pressure upon the carotid sinus restored normal rhythm in Case 13 (Mackinnon); it never does so in auricular flutter. In the common type of paroxysmal tachycardia, normal rhythm is often restored by pressure upon the carotid sinus. An important difference between auricular paroxysmal tachycardia with partial A-V block and auricular flutter is that in the former the auricular deflections are separated by periods of electrical quiescence, during which the curve is at rest on the base line, whereas, in the latter, the curve is never at rest, but shows continuous changes in electrical potential. This is apparent quite commonly in standard leads, usually in precordial leads, and always in esophageal leads.

If auricular paroxysmal tachycardia is caused by re-entry of the impulse, it must be a special kind of circus rhythm, differing from that of auricular fibrillation. Circus rhythm involving as part of the path of the circulating excitation wave either the sinoauricular node or the auriculoventricular node could account for most, if not all, of the features of auricular paroxysmal tachycardia. This possibility has been discussed briefly by Ashman and Hull.¹⁹ In our opinion, circus rhythm can account for auricular paroxysmal tachycardia only if it involves one of the nodes, or if the amount of muscle in some part of the main circus path is so small that its action potential cannot be recorded by ordinary methods. In a subsequent communication we hope to present additional evidence bearing upon this problem, and to discuss it at greater length.

SUMMARY

1. Seventeen previously reported cases of auricular paroxysmal tachycardia with auriculoventricular block are reviewed, and eighteen additional cases are reported.

2. This arrhythmia may occur at almost any age, and in persons with otherwise normal hearts or with organic heart disease.

3. The attacks are often of long duration, i.e., they commonly last several days or longer.

4. High-grade disability is common in patients with organic heart disease, but sometimes occurs in those with otherwise normal hearts. One patient without significant organic heart disease died of cardiac exhaustion and failure attributable entirely to the long continued tachycardia.

5. In some cases the auricular deflections of the electrocardiogram are small or not readily apparent in limb leads. In such instances precordial or esophageal leads are especially valuable because they yield prominent auricular waves and thus permit the identification of the arrhythmia. Such curves are quite different from those of auricular flutter, in that the auricular deflections are separated by periods of electrical quiescence, with the curve at rest on the base line.

6. Digitalis in large amounts often restores normal rhythm. Quinidine and quinine are somewhat less effective, but sometimes restore normal rhythm, occasionally even when digitalis has failed to do so. Pressure upon the carotid sinus rarely terminates the paroxysms; it was successful in only one case (Mackinnon⁹). Mecholyl and acetylcholine have been ineffectual. Some patients may not respond to any of these measures; in one such instance normal rhythm returned spontaneously after a period of rest in bed, whereas, in another, death resulted from cardiac exhaustion caused by the prolonged tachycardia.

7. Auricular paroxysmal tachycardia with partial A-V block resembles auricular flutter in many respects, but differs from it in some important particulars. Most of the features of auricular paroxysmal tachycardia can be accounted for by circus rhythm involving either the sinoauricular node or the auriculoventricular node.

REFERENCES

1. Lewis, T.: *The Mechanism and Graphic Registration of the Heart Beat*, ed. 3, London, 1925, Shaw and Sons, Ltd.
2. Koplik, H.: Paroxysmal Tachycardia in Children, *Am. J. M. Sc.* **154**: 834, 1917.
3. Singer, R., and Winterberg, H.: Chinin als Herz- und Gefäßmittel, *Wien. Arch. f. inn. Med.* **3**: 329, 1922.
4. Gallavardin, L.: Tachycardia Paroxystique a Forme Arythmique par Trouble de la Conductibilité Auriculo-Ventriculaire. Simulation d'un Rhythme Atrio-Ventriculaire, *Arch. d. mal. du coeur* **16**: 117, 1923.
5. Lenhartz, H., and Samet, B.: Beitrag zur Kenntnis der Tachykardie, *Wien. Arch. f. inn. Med.* **9**: 71, 1924.
6. Sprague, H. B., and White, P. D.: Heart-Block During Auricular Paroxysmal Tachycardia (Clinical Observations on Three Cases), *M. Clin. North America* **8**: 1855, 1925.

7. Wenekebach, K. F., and Winterberg, H.: Die unregelmässige Herzthätigkeit, Leipzig, 1927, Wilhelm Engelmann.
8. Dock, W.: The Reciprocal Rhythm. Report of a Case in Which Auricular Tachycardia With Partial A-V Dissociation and Atrioventricular Bradycardia, With Reciprocating Rhythm, Were Present, Arch. Int. Med. 41: 745, 1928.
9. Mackinnon, A. V.: The Rhythm of Paroxysmal Tachycardia. An Electrocardiographic Study, Quart. J. Med. 27: 1, 1934.
10. Brown, W. H.: A Study of the Esophageal Lead in Clinical Electrocardiography, AM. HEART J. 12: 307, 1936.
11. Maddox, K.: Auricular Paroxysmal Tachycardia (Possibly Nomotopic) With Variable Auriculo-Ventricular Conduction Time, AM. HEART J. 14: 183, 1937.
12. Maarssø, C.: Et tilfælde af paroxysmatisk tachycardi med partielt atrioventrikulært blok hos et 8 aars barn, Hospitalstid. 8: 1140, 1937.
13. Fine, M. J., and Miller, R.: Orthostatic Paroxysmal Auricular Tachycardia With Unusual Response to Change of Posture, AM. HEART J. 20: 366, 1940.
14. Katz, L. N.: Electrocardiography, Philadelphia, 1941, Lea and Febiger.
15. Field, H., Jr., Barker, P. S., and Alexander, J.: Unusual Sinus Tachycardia With Observations on Vagal Activity, AM. HEART J. 9: 298, 1934.
16. Parkinson, John, and Mathias, H. H.: Tachycardia of Auricular Origin and Flutter With Phasic Variation in Auricular Rate and in Conduction, Heart 6: 27, 1915.
17. Carr, F. B.: Auriculoventricular Nodal Paroxysmal Tachycardia and Auricular Flutter. Case Report, AM. HEART J. 7: 668, 1932.
18. Lewis, T.: Auricular Fibrillation and Its Relationship to Clinical Irregularity of the Heart, Heart 1: 306, 1910.
19. Ashman, R., and Hull, E.: Essentials of Electrocardiography, ed. 2, New York, 1941, The Macmillan Co.