

Role of endoscopic ultrasonography in screening and treatment of pancreatic endocrine tumours in asymptomatic patients with multiple endocrine neoplasia type 1

P. G. Gauger¹, J. M. Scheiman¹, E.-J. Wamsteker¹, M. L. Richards², G. M. Doherty¹ and N. W. Thompson¹

¹Division of Endocrine Surgery and Section of Gastroenterology, University of Michigan, Ann Arbor, Michigan, USA and ²Department of Surgery, University of Texas, San Antonio, Texas, USA

Correspondence to: Dr P. G. Gauger, Department of Surgery, University of Michigan, 1500 East Medical Center Drive, TC2920H, Ann Arbor, Michigan 48109-0331, USA (e-mail: pgauger@umich.edu)

Background: Patients with multiple endocrine neoplasia (MEN) type 1 risk premature death from pancreatic endocrine tumours (PETs). Endoscopic ultrasonography (EUS) is the most sensitive imaging modality for small PETs. A screening and therapeutic approach for asymptomatic patients is delineated in which EUS plays a pivotal role.

Methods: This was a retrospective study of 15 patients with MEN-1 but with no symptoms of a PET. All patients underwent serum hormone measurement, including gastrin, and EUS. The findings were used to facilitate operative treatment.

Results: Six of 15 patients had a normal basal gastrin level and nine had a raised level. EUS demonstrated PETs in 14 patients and identified multiple lesions in 12. There was no predictive relationship between age or gastrin level and the number or size of PETs discovered. Thirteen patients have undergone enucleation or resection of PETs and two remain under observation. Nine of the 13 patients underwent transduodenal exploration to excise gastrinoma(s). One patient had lymph node metastases found at operation. There was no death. Self-limiting pancreatic fistula in five patients and biliary fistula in one.

Conclusion: Early and aggressive screening using EUS identifies PETs in asymptomatic patients with MEN-1. Detection of tumours at an early stage, before the development of symptoms, lymph node metastases or liver metastases, may facilitate prompt surgical intervention and improve prognosis.

Presented to a Meeting of the British Association of Endocrine Surgeons, Pisa, Italy, May 2002

Paper accepted 11 January 2003

Published online 29 April 2003 in Wiley InterScience (www.bjs.co.uk). DOI: 10.1002/bjs.4142

Introduction

In 1954, Wermer described the autosomal dominant mode of inheritance of a syndrome now known commonly as multiple endocrine neoplasia (MEN) type 1¹. The *MEN-1* gene, discovered in 1997, is a tumour suppressor gene on the long arm of chromosome 11 (11q13). Little is known about the tumour suppressor action of Menin, the protein product of this 9-kilobase gene. A large number of germline mutations can inactivate the *MEN-1* gene, any one of which may be responsible for the individual clinical expression of the syndrome. The syndrome may be well characterized but it is phenotypically variable. It is commonly believed that most patients (95 per cent

by age 35 years) with the genomic mutation will have hyperparathyroidism and far fewer (20 per cent) will have a pituitary lesion². Pancreaticoduodenal disease such as gastrinoma, non-functioning pancreatic endocrine tumour (PET) and insulinoma occur in 60, 50 and 10 per cent of affected patients respectively². However, these profiles of clinical expression are influenced by age, geography and the specific kindred studied. Several investigators have defined completely different prevalences of clinical expression^{3,4}. Malignant thymic carcinoid tumours are a common cause of death in some large kindreds, but pancreatic tumours are associated with substantial morbidity and mortality rates overall. Doherty *et al.*⁵ analysed over 30 distinct MEN-1

kindreds for cause and age of death and found that 46 per cent died from causes related to endocrine tumours at a median age of 47 years. PETs were the most common cause of death in these patients.

The appreciation of MEN-1 as a life-threatening syndrome has led to the screening of potentially affected patients, even before the disease is evident clinically. Such patients are commonly screened for hyperparathyroidism by measurement of serum calcium and parathyroid hormone levels, or for pituitary lesions by measurement of serum hormones such as prolactin. The philosophy of early screening for PETs is based on the knowledge that the prognosis of MEN-1 pancreaticoduodenal disease is directly related to the stage at the time of diagnosis. Early diagnosis and definitive surgical treatment should improve prognosis, although this is still a matter for debate.

Currently, screening for PETs can be divided broadly into two categories: screening for hormonal evidence of functional or non-functional PETs (those producing human pancreatic polypeptide (PPomas) without a resultant syndrome or those producing no known hormone); and imaging for anatomical evidence of tumour presence, irrespective of hormonal status. Clearly, these two types of screening are complementary and are often used in combination. Biochemical screening for PETs traditionally includes measurement of glucose, insulin, proinsulin, glucagon, gastrin, pancreatic polypeptide and chromogranin A (if available). In an asymptomatic population, these tests have sensitivities ranging from 37 to 67 per cent⁶. Another less commonly used option is application of a standardized carbohydrate-rich meal test to elicit an increase in serum pancreatic polypeptide and/or gastrin levels⁷. However, the latter test is time consuming and expensive, and was shown to be of negligible benefit in a recent prospective study⁸.

Various imaging modalities for localizing PETs in patients with MEN-1 have been used. Studies analysing the sensitivity of imaging tests have often included symptomatic patients in whom the presence of tumour was already heralded by a hormonal syndrome. However, many patients with MEN-1 have non-functional pancreatic tumours (often PPomas), which also have malignant potential. Techniques such as computed tomography (CT) and magnetic resonance imaging are relatively insensitive for detecting pancreatic tumours in MEN-1 unless the lesion is large. Somatostatin receptor scintigraphy (SRS) is a complementary test that images approximately 80 per cent of tumours seen on CT but may also reveal unsuspected metastatic disease⁹. The sensitivity of SRS for large tumours (more than 3 cm) is up to 91 per cent in MEN-1-associated Zollinger–Ellison syndrome¹⁰.

However, SRS is generally limited in its ability to detect small gastrinomas, although a gastrinoma measuring just 3 mm has been imaged¹¹.

Endoscopic ultrasonography is one of the most sensitive and specific tests for detecting neuroendocrine tumours¹². Recent studies have reported sensitivities as high as 93 per cent or even higher for EUS combined with SRS^{12,13}. As a screening tool EUS is capable of detecting tumours smaller than those identified by helical CT, angiography or with SRS. Only EUS has the ability to image small PETs reliably, especially lesions in the head, uncinate and body regions of the pancreas¹⁴. This is especially relevant to non-functional PETs but may also apply to small functional tumours detected at a preclinical stage.

The authors have reported previously on 46 EUS examinations performed in 30 patients who were suspected or known to have MEN-1, all of whom had clinical, biochemical or radiological evidence of a neuroendocrine tumour¹². Only three patients, with multiple lesions, had tumours identified on operative palpation that were not visualized on EUS. All of the missed lesions were smaller than 2 mm and presumably of low malignant potential. This report describes the central role of EUS in the screening and overall management of PETs in patients with suspected MEN-1.

Patients and methods

This was a retrospective review of all patients evaluated for known or suspected MEN-1 at a single institution from May 1994 to August 2002. During this interval, 66 patients with MEN-1 were evaluated; they underwent a total of 135 EUS examinations. Patients with symptoms of a functional PET were excluded from the present series as were those who had had previous pancreatic surgery. The study group comprised 15 (23 per cent) of these 66 patients who were suspected of having MEN-1 but who had no symptoms referable to a PET (for example hypoglycaemia, peptic ulcer disease, diarrhoea). The group comprised eight females and seven males, all of whom had primary hyperparathyroidism as the initial manifestation of the syndrome. The median age at evaluation was 29 (range 15–63) years. Nine of the 15 patients had a clear family history of MEN-1 in a first-degree relative or had confirmatory mutational analysis. Of the six patients with no antecedent family history, the diagnosis of MEN-1 was suspected in three owing to coincident pituitary lesions such as prolactinoma. A diagnosis of MEN-1 was considered in the remaining three patients on the basis of mild dyspepsia or gastro-oesophageal reflux symptoms which, in the context of their hyperparathyroidism

caused by multiglandular disease, prompted measurement of the serum gastrin level. The symptoms in these three patients were notably mild and quite different from those typically seen in patients with MEN-1 and clinical evidence of Zollinger–Ellison syndrome. Analysis of the relationship between the presence of dyspepsia and/or gastro-oesophageal reflux and the serum gastrin level revealed no significant relationship in this group of 15 patients (Pearson correlation coefficient 0.234). Serum human pancreatic polypeptide was measured only intermittently and serum chromogranin A measurement was not routinely available during the study period.

EUS was used to screen for PETs in all 15 patients, irrespective of the serum gastrin level, and was performed by a single and highly experienced gastrointestinal endosonographer (J.M.S.). The findings were used for initial surgical planning. Complementary methods of imaging such as abdominal spiral CT and SRS were also used in some patients further to delineate EUS findings and to identify any liver metastases. Postoperative follow-up included abdominal CT for surveillance for metastases and serum studies such as gastrin measurement. EUS was also used after primary operative therapy to monitor for metachronous PET development (typically within the remaining head and uncinate regions). The specific findings of the examinations were analysed with respect to selected preoperative factors, and operative and pathological findings. Linear regression was used for statistical comparisons. The project was reviewed by the Institutional Review Board and was approved as exempt from further oversight.

Results

Screening procedures

Six of 15 patients had a normal basal serum gastrin level (mean(s.e.m.) 71(7) pg/ml; normal range 25–111 pg/ml). The remaining nine had a raised level of gastrin (215(42) pg/ml); of these nine patients, only two had levels greater than twice normal (318 and 512 pg/ml). Secretin was not available consistently during the study period and so stimulated gastrin levels could not be analysed.

Preoperative EUS demonstrated PETs in 14 of the 15 patients, 12 of whom had multiple lesions identified (median 3, range 1–5; excluding one patient with innumerable lesions). A total of 43 PETs were demonstrated in these 15 patients. Considering the pancreatic head, neck and uncinate process as separate pancreatic regions, the anatomical distribution of the identified lesions appeared to favour the distal pancreas (*Fig. 1*). However, considering the head, neck and uncinate

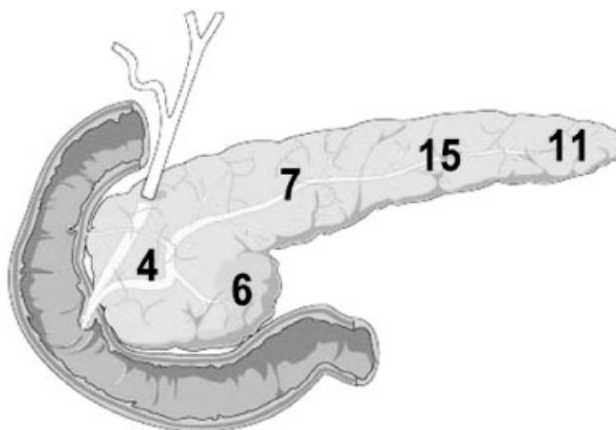


Fig. 1 Diagrammatic representation of the anatomical distribution of 43 pancreatic endocrine tumours demonstrated on initial endoscopic ultrasonography in 15 asymptomatic patients with multiple endocrine neoplasia type 1

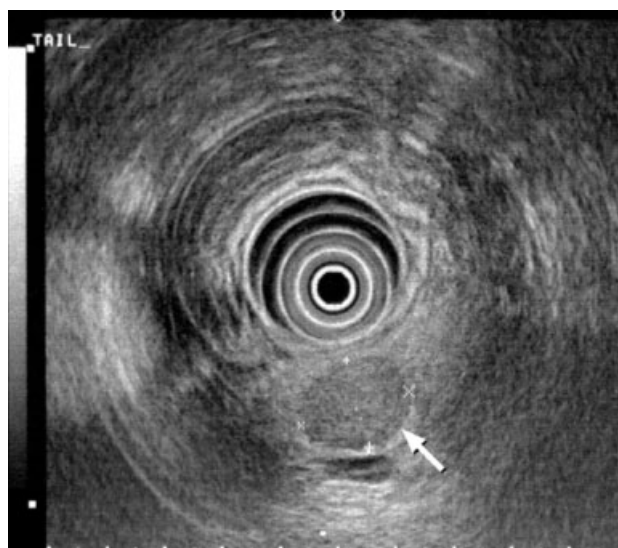

Fig. 2 A 1.4 × 2.8-cm pancreatic endocrine tumour of the pancreatic tail (arrow) demonstrated on endoscopic ultrasonography in a 28-year-old patient with hyperparathyroidism and a serum gastrin level of 118 pg/ml

as a single region, the distribution was predicted by the approximate parenchymal mass of the three pancreatic regions. *Fig. 2* illustrates the typical EUS appearance of a PET within the pancreatic tail. For the group of 15 patients, the mean(s.e.m.) size of the smallest tumour identified in each patient at the initial EUS screen was 0.7(0.1) (median 0.7, range 0.3–2.0) cm and that of the largest tumour was 2.1(0.4) (median 1.5, range 0.6–6.5) cm. *Fig. 3* shows the typical appearance of a small PET, which was of a size

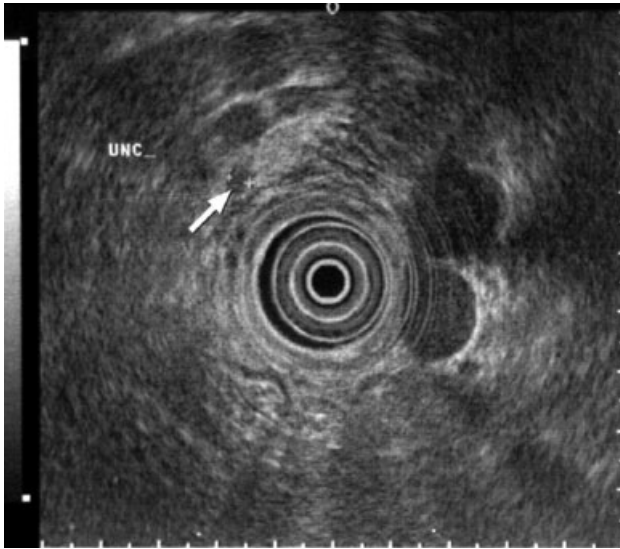


Fig. 3 Small 4-mm pancreatic endocrine tumour (arrow) imaged by endoscopic ultrasonography in the uncinus process of a 35-year-old woman with hyperparathyroidism and a serum gastrin level of 141 pg/ml

smaller than the detection limit of most other imaging techniques.

Linear regression analysis found no correlation between age and the total number of PETs found during screening EUS ($R^2 = 0.169$), or between age and the size of the largest PET imaged ($R^2 = 0.030$). Similar analysis indicated that the serum gastrin level was not correlated with the total number of PETs found during screening EUS ($R^2 = 0.112$) or with the size of the largest PET imaged by EUS ($R^2 = 0.065$).

Surgical management

Thirteen of the 15 patients underwent operative procedures to excise PETs on the basis of preoperative EUS findings. The mean (s.e.m.) time between screening EUS and operation was 2.5 (0.8) months. Distal pancreatectomy and splenectomy was performed in 12 of the 13 patients, nine of whom required enucleation of one or more tumours from the head or uncinus regions of the pancreas in addition to the distal pancreatectomy. Examples of this operative procedure are reproduced from the surgeon's notebook (*Fig. 4*). One of 13 patients required a pancreaticoduodenectomy for a 6.5-cm PET located in the uncinus process; a limited distal pancreatectomy for two additional large lesions in the tail was required at the same operation. One patient underwent concomitant hysterectomy for uterine leiomyomas, lesions frequently associated with the MEN-1 syndrome.

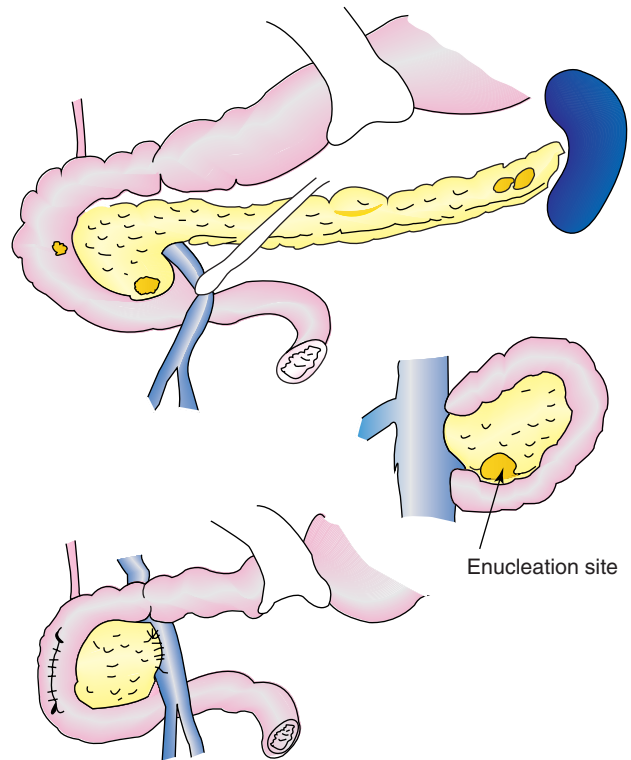


Fig. 4 The patient referred to in *Fig. 2* underwent distal pancreatectomy and splenectomy, enucleation of a pancreatic head endocrine tumour from the posterior surface of the uncinus process, and duodenotomy with excision of duodenal gastrinoma

A raised serum gastrin level was considered an indication for an intraluminal duodenal exploration regardless of the pancreatic findings. Nine patients underwent duodenotomy during the initial operation. A total of 12 submucosal tumours were excised from these nine patients (median 1, range 0–3) during duodenotomy. Nine of 12 tumours were confirmed to be gastrinomas.

Of the 13 patients who underwent operation, preoperative EUS identified PETs in 12. In ten of these patients, the number of PETs identified on final histology exceeded the number predicted by EUS, whereas the numbers corresponded exactly in the remaining two patients. In all patients, the additional multiple tumours were less than 1 cm in size and located in the resected pancreatic tail. None of the PETs stained positively for gastrin during immunohistochemical analysis. One of 13 patients had evidence of metastatic PET in a single peripancreatic lymph node near the distal pancreas, which was not predicted by EUS. No patient had preoperative or intraoperative evidence of liver metastases.

There was no operative mortality. One patient developed a postoperative wound infection. In five of 13

patients morbidity included pancreatic fistula, which was controlled by an initial operative drain, or peripancreatic fluid collection that required placement of an additional percutaneous drain. Leakage was defined as a drain output exceeding 30 ml per 24 h for longer than 5 days after operation. One patient developed a high-output biliary fistula from ischaemic necrosis of the common bile duct. This, in turn, was caused by resection of a large malignant pancreatic tumour invading the proper hepatic artery. This fistula was treated successfully with a Roux-en-Y choledochojejunostomy 3 months after the initial operation.

All patients were alive at a median of 50 (range 2–95) months after operation. The present median age of the study group is 35 (range 17–64) years. One of the 13 patients was lost to follow-up. The remaining 12 have no evidence of metachronous metastatic disease. None of the six patients with initial eugastrinaemia had later evidence of hypergastrinaemia. Of the nine patients with an increased gastrin level initially, eight underwent operation. Although a decrease in gastrin level was seen after gastrinoma excision, the response was not durable and these patients had a mean gastrin level of 206(139) pg/ml at a mean follow-up of 28 months. Patients were continued on proton pump inhibitors. Two of the 15 patients did not undergo early operation and continue to be monitored with serial EUS. Both patients are adolescent and have small asymptomatic tumours (1 cm or smaller), but will almost certainly require pancreatic operation at a later date.

Discussion

PETs are responsible for a large proportion of the deaths attributable to MEN-1^{5,15}. This is true irrespective of whether the PET is functional, because even non-functioning tumours (often those producing human pancreatic polypeptide) can behave in a malignant fashion. Theoretically, diagnosis at an earlier stage or smaller tumour size should have a positive impact on prognosis but the behaviour of PETs is difficult to predict based on size alone. A French multicentre study¹⁶ suggested that primary tumour size (larger and smaller than 3 cm) at the time of original operation may predict a higher risk of liver metastases (36 *versus* 6 per cent). However, Lowney *et al.*¹⁷ included lymph nodes in the definition of metastases and found that the primary tumour size did not reliably predict the presence of metastatic disease at the time of surgery in patients with MEN-1. The subgroup of patients in the latter study who had liver metastases accounted for only two of 23 patients with a primary tumour larger than 2 cm and no patient with a primary tumour smaller

than 2 cm. Skögseid *et al.*¹⁸ compared operative findings in patients with MEN-1 who had either solely biochemical evidence of PETs or radiological evidence of a PET without demonstrable metastases; the imaging modalities used included CT, ultrasonography, angiography and SRS, but not EUS. No patient with a biochemical diagnosis alone had metastatic disease whereas 26 per cent of patients with radiological evidence of the primary tumour had metastatic disease discovered at operation.

EUS has some recognized limitations. The anatomical and technical aspects of EUS indicate that it is most beneficial in identifying lesions in the pancreatic head, body or uncinata process. The evaluation of the distal pancreas is perceived to be limited because of the increasing distance between the sonographic interface and the target organ, but the authors have not found this to be a significant limitation. Furthermore, it would be of minor significance in this patient group because patients with MEN-1 are most often treated with a distal pancreatectomy and enucleation of tumours in the proximal pancreas.

EUS rarely detects duodenal gastrinomas and a negative study does not rule out their presence. In this series, none of the duodenal gastrinomas was imaged by EUS although one 1-cm tumour was seen during esophagogastroduodenoscopy performed in preparation for insertion of the echoendoscope. At operation, this tumour was confirmed to be a gastrinoma. None of the common preoperative imaging studies is useful or reliable in detecting these small submucosal tumours routinely. The presence of one or more duodenal gastrinomas in patients with MEN-1 must be assumed on the basis of a raised gastrin level and positive secretin stimulation test (if available).

Of the 13 patients who underwent operation, EUS failed to demonstrate a PET in one. Because of hypergastrinaemia, the patient underwent operation during which three pancreatic head tumours between 5 and 10 mm in size were located by intraoperative palpation and enucleated. A total of 18 PETs (4 mm or smaller) were confirmed histologically in the resected pancreatic tail. It unclear why EUS failed to demonstrate tumours in this patient, but the pancreas was noted to be markedly heterogeneous and irregular during EUS, and the tumours were apparently isoechoic instead of hypoechoic in nature. In contrast, EUS occasionally may suggest a small PET that is difficult to palpate at operation (see *Fig. 3*). Intraoperative ultrasonography may be of significant value in this situation.

As is often the case with the pancreatic lesions of MEN-1, the number of PETs demonstrated histologically in the excised pancreas exceeded the number predicted by EUS. It is not possible to enumerate the multiple

microscopic tumours exactly. In all cases, the additional multiple tumours were smaller than 1 cm and were located within the resected pancreatic tail. For this reason, the 'undersensitivity' of EUS for tumours smaller than 0.5 cm in this region is of little concern.

The value of early and aggressive screening was illustrated by two of the patients in this series who had locally advanced tumours. The first was a 28-year-old man with hyperparathyroidism who was the son of a known patient with MEN-1. In the absence of symptoms, he was still counselled to undergo EUS, but declined for 5 years. When EUS was eventually performed, a 4.5-cm pancreatic tumour was found in the head-neck junction that was also clearly demonstrated on CT. At operation, this was found to be encasing the common hepatic artery and the patient developed a biliary fistula related to an ischaemic bile duct owing to arterial resection. The second patient was a 42-year-old woman with hyperparathyroidism whose father had MEN-1. She had no symptoms of a PET, but screening EUS revealed three PETs of significant size, the largest of which was a 6.5-cm uncinata mass. The woman required a pancreaticoduodenectomy and limited distal pancreatectomy for resection of these.

Early screening for PETs supports the authors' policy of early and aggressive operative therapy for pancreatic and duodenal neoplasms associated with MEN-1. The recommended surgical strategy is as follows. Complete, low-morbidity resection of pancreatic tumours with preservation of normal pancreas is typically accomplished by distal pancreatectomy to the level of the superior mesenteric vein, and enucleation of PETs in the pancreatic head or uncinata process. PETs are identified during operation by bidigital palpation or intraoperative ultrasonography. The spleen is preserved if feasible, but a splenectomy accompanies the distal pancreatectomy if there are pancreatic tumours larger than 1 cm in the body or tail. If the preoperative serum gastrin level is raised, a duodenotomy is performed to excise duodenal tumours locally. An extensive Kocher manoeuvre is required. Tumours from the first to fourth portion of the duodenum can be approached through a lateral duodenotomy confined to the C loop by utilizing retrograde intussusception of the distal duodenum. Lymph nodes in the regions of the duodenum, porta hepatis, hepatic artery, coeliac axis and splenic hilum are removed routinely if there are tumours in the areas draining to these basins. Finally, a cholecystectomy is performed to address the possible need for future treatment with octreotide acetate for irresectable neuroendocrine tumour metastases that may occur in some patients with MEN-1.

This strategy is suitable for most patients but alternative surgical procedures may be required, as in the present patient who required a pancreaticoduodenectomy for a large pancreatic head mass that could not be enucleated safely. Some surgeons prefer to use a more aggressive resection routinely, such as pylorus-sparing pancreaticoduodenectomy, particularly in patients with MEN-1 and Zollinger-Ellison syndrome who are thought to have multiple gastrinomas¹⁹. This approach may be more likely to result in long-term eugastrinaemia because of a more extensive lymph node dissection and complete removal of even the smallest duodenal primaries²⁰.

The authors' surgical strategy may be criticized for several reasons. First, the restoration of eugastrinaemia was not durable in all patients. Second, the morbidity rate (pancreatic fistula) was high considering that most of these patients were healthy, asymptomatic and had small tumours. However, the leaks were resolved easily with observation or conservative treatment, and represented minor complications compared with those that might accompany untreated disease or alternative major procedures such as pancreaticoduodenectomy.

Neither the total number of tumours nor the size of the largest tumour demonstrated by EUS was related to preoperative factors such as basal gastrin level or patient age. While the basal serum gastrin level was raised in nine of the 15 asymptomatic patients, none of the PETs was positive by immunohistochemical staining for gastrin. This was not unexpected as it is almost always the submucosal duodenal gastrinoma that is detected by biochemical screening, and is the reason why duodenotomy figures prominently in the authors' surgical strategy for patients with a raised level of gastrin. In this series of patients, all of the small duodenal neuroendocrine tumours excised stained positively for gastrin, whereas the PETs removed all appeared to be 'non-functioning' tumours (usually PPomas) and not pancreatic gastrinomas.

After distal pancreatectomy patients are monitored by EUS at 2-year intervals for PET development in the residual pancreas. If one or more tumours become evident, enucleation is offered. This has occurred in only one patient in the present series. As with the initial operation, a raised serum gastrin level is used to determine the role of duodenotomy at any subsequent operation.

Based on the findings of the initial EUS examination, it is recommended that EUS be repeated after 1 year if a PET of 1 cm or smaller is identified, whereas neuroendocrine tumour(s) larger than 1 cm should be removed surgically as described above. If no tumour is noted, EUS should be repeated in 3 years. The complementary use of abdominal CT is also recommended to assess other abdominal organs,

both for unsuspected hepatic metastases from PETs and for other organ involvement by associated lesions such as renal cell carcinoma, adrenal tumours or leiomyomas. An interval of every other year is appropriate if the previous study was normal, but annual screening is preferred if an abnormality is being followed. SRS should be used both in assessment of the primary tumour before resection and to follow patients for potential metachronous metastatic disease.

EUS is a highly effective imaging procedure that has a pivotal position in the screening of asymptomatic patients with MEN-1 who are at risk of developing PETs. Prompt application of this technique may facilitate early detection of such tumours before the development of symptoms, lymph node metastases or liver metastases, allowing early and specific surgical intervention. EUS may also be used to image residual pancreatic tissue during late follow-up to monitor the development or progression of additional tumours. This image-based management policy may facilitate favourable long-term outcomes.

References

- 1 Wermer P. Genetic aspects of adenomatosis of endocrine glands. *Am J Med* 1954; **16**: 363–371.
- 2 Burgess JR, Greenaway TM, Shepherd JJ. Expression of the MEN-1 gene in a large kindred with multiple endocrine neoplasia type 1. *J Int Med* 1998; **243**: 465–470.
- 3 Carty SE, Helm AK, Amico JA, Clarke MR, Foley TP, Watson CG *et al.* The variable penetrance and spectrum of manifestations of multiple endocrine neoplasia type 1. *Surgery* 1998; **124**: 1106–1113.
- 4 Marx SJ, Vinik AI, Santen RJ, Floyd JC Jr, Mills JL, Green J III. Multiple endocrine neoplasia type I: assessment of laboratory tests to screen for the gene in a large kindred. *Medicine* 1986; **65**: 226–241.
- 5 Doherty GM, Olson JA, Frisella MM, Lairmore TC, Wells SA Jr, Norton JA. Lethality of multiple endocrine neoplasia type I. *World J Surg* 1998; **22**: 581–586.
- 6 Sköglseid B, Rastad J, Akerström G. Pancreatic endocrine tumors in multiple endocrine neoplasia type 1. In *Surgical Endocrinology*, Doherty G, Sköglseid B (eds). Lippincott Williams & Wilkins: Philadelphia, 2001; 511–524.
- 7 Sköglseid B, Oberg K, Benson L, Lindgren PG, Lorelius LE, Lundquist G *et al.* A standardized meal stimulation test of the endocrine pancreas for early detection of pancreatic endocrine tumors in multiple endocrine neoplasia type 1 syndrome: five years experience. *J Clin Endocrinol Metab* 1987; **64**: 1233–1240.
- 8 Langer P, Wild A, Celik I, Kopp I, Bergenfels A, Bartsch DK. Prospective controlled trial of a standardized meal stimulation test in the detection of pancreaticoduodenal endocrine tumours in patients with multiple endocrine neoplasia type 1. *Br J Surg* 2001; **88**: 1403–1407.
- 9 Yim JH, Siegel BA, DeBenedetti MK, Norton JA, Lairmore TC, Doherty GM. Prospective study of the utility of somatostatin-receptor scintigraphy in the evaluation of patients with multiple endocrine neoplasia type 1. *Surgery* 1998; **124**: 1037–1042.
- 10 Norton JA, Fraker DL, Alexander HR, Venzon DJ, Doppman JL, Serrano J *et al.* Surgery to cure the Zollinger–Ellison syndrome. *N Engl J Med* 1999; **341**: 635–644.
- 11 Cadiot G, Lebtahi R, Sarda L, Bonnaud G, Marmuse JP, Vissuzaine C *et al.* Preoperative detection of duodenal gastrinomas and peripancreatic lymph nodes by somatostatin receptor scintigraphy. Groupe d'Etude du Syndrome de Zollinger–Ellison. *Gastroenterology* 1996; **111**: 845–854.
- 12 Anderson MA, Carpenter S, Thompson NW, Nostrant TT, Elta GH, Scheiman JM. Endoscopic ultrasound is highly accurate and directs management in patients with neuroendocrine tumors of the pancreas. *Am J Gastroenterol* 2000; **95**: 2271–2277.
- 13 Proye C, Malvaux P, Pattou F, Filoche B, Godchaux JM, Maunoury V *et al.* Noninvasive imaging of insulinomas and gastrinomas with endoscopic ultrasonography and somatostatin receptor scintigraphy. *Surgery* 1998; **124**: 1134–1143.
- 14 Gauger PG, Thompson NW. Early surgical intervention and strategy in patients with multiple endocrine neoplasia type 1. *Best Pract Res Clin Endocrinol Metab* 2001; **15**: 213–223.
- 15 Dean PG, van Heerden JA, Farley DR, Thompson GB, Grant CS, Harmsen WS *et al.* Are patients with multiple endocrine neoplasia type 1 prone to premature death? *World J Surg* 2000; **24**: 1437–1441.
- 16 Cadiot G, Vuagnat A, Doukhan I, Murat A, Bonnaud G, Delemer B *et al.* Prognostic factors in patients with Zollinger–Ellison syndrome and multiple endocrine neoplasia type 1. Groupe d'Etude des Neoplasies Endocriniennes Multiples (GENEM) and Groupe de Recherche et d'Etude du Syndrome de Zollinger–Ellison (GRESZE). *Gastroenterology* 1999; **116**: 286–293.
- 17 Lowney JK, Frisella MM, Lairmore TC, Doherty GM. Pancreatic islet cell tumor metastasis in multiple endocrine neoplasia type 1: correlation with primary tumor size. *Surgery* 1999; **125**: 1043–1049.
- 18 Sköglseid B, Oberg K, Akerström G, Eriksson B, Westlin JE, Janson ET *et al.* Limited tumor involvement found at multiple endocrine neoplasia type I pancreatic exploration: can it be predicted by preoperative tumor localization? *World J Surg* 1998; **22**: 673–677.
- 19 Bartsch DK, Langer P, Wild A, Schilling T, Celik I, Rothmund M *et al.* Pancreaticoduodenal endocrine tumors in multiple endocrine neoplasia type 1: surgery or surveillance? *Surgery* 2000; **128**: 958–966.
- 20 Delcore R, Friesen SR. Role of pancreatoduodenectomy in the management of primary duodenal wall gastrinomas in patients with Zollinger–Ellison syndrome. *Surgery* 1992; **112**: 1016–1022.