

ECCHYMOSIS OF THE LOWER LEG

A SIGN OF HEMARTHROSIS WITH SYNOVIAL RUPTURE

ARMIN E. GOOD and RODNEY V. POZDERAC

Four patients with hemarthrosis of the knee, synovial rupture, and ecchymoses are reported. The patients presented with calf pain and swelling and large ecchymoses, which eventually extended to the ankle as a crescent about one or both malleoli. Appreciation of this physical sign, which appears to be characteristic for the hemorrhagic subset of synovial rupture, should alert the physician to the correct diagnosis and steer him away from contraindicated anticoagulant therapy.

Acute synovial rupture of the knee is a dramatic and characteristic syndrome almost always misdiagnosed as thrombophlebitis (1). The patient presents with widespread swelling, edema, and tenderness distal to the knee; redness and warmth maximal in the upper medial calf; and a positive Homans' sign. The keys to the diagnosis are a current history of pain or swelling in the knee joint and physical signs of knee involvement. An effusion in the knee is a prerequisite, and abrupt diminution or disappearance of the effusion coincides

with the onset of the calf swelling. However patients presenting after the fact may neither provide a history of synovial swelling nor volunteer other knee symptoms.

This is a report of 4 patients with gross blood in the knee and an acute synovial rupture syndrome. Each demonstrated an ecchymosis that eventually reached the ankle, forming a crescent about one or both malleoli. The ecchymosis can prove most helpful as a physical sign of synovial rupture with hemarthrosis, because little or no pain need accompany hemarthrosis per se, and swelling of the knee may disappear permanently as soon as the bloody effusion drains into the calf.

CASE REPORTS

Case 1

A 67-year-old man was seen in 1975 with a history of podagra starting at age 30, and pain and swelling in the right knee since age 51. A week earlier, he had injured the right knee in a fall. Later that day he noted swelling and tenderness of the calf. On admission there were swelling, increased heat, tenderness, and pitting edema of the right calf, as well as an ecchymosis extending to the foot (Figure 1). At the right knee, synovial swelling and tenderness were noted and aspiration yielded 80 ml of grossly bloody fluid containing 6,570 leukocytes/mm³ and 148,000 erythrocytes/mm³ as well as numerous urate crystals. With colchicine and leg elevation, calf swelling and tenderness disappeared.

Comment. Both the hemarthrosis and synovial rupture probably stemmed from minor trauma incurred by this patient with chronic gouty synovitis.

From the Veterans Administration Hospital and the Departments of Internal Medicine and Nuclear Medicine, University of Michigan Medical School, Ann Arbor, Michigan.

Armin E. Good, M.D.: Associate Professor of Internal Medicine, University of Michigan Medical School; Rodney V. Pozderac, M.D.: Assistant Professor of Internal Medicine, University of Michigan Medical School.

Address reprint requests to Armin E. Good, M.D., VA Hospital, 2215 Fuller Road, Ann Arbor, Michigan 48105.

Submitted for publication November 23, 1976; accepted January 21, 1977.

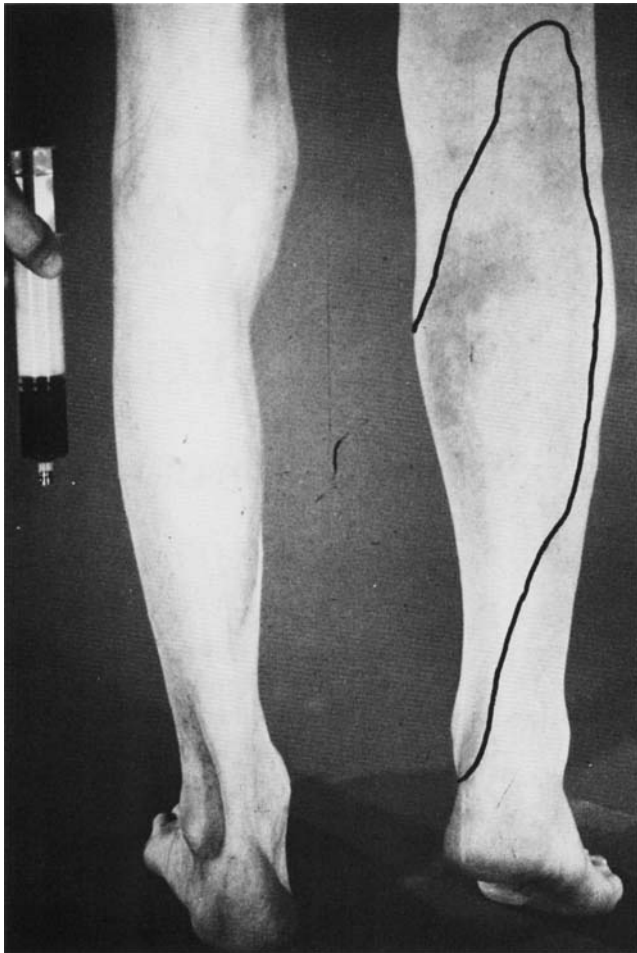


Fig 1. Case 1. Posterior aspect of lower legs and syringe containing grossly bloody fluid aspirated from right knee on estimated ninth day after synovial rupture. The print is adapted from a color slide. Lines show the boundary of the ecchymotic zone, which begins proximal to the popliteal crease and envelopes the medial malleolus. Swelling of the right calf and ankle is also visible.

Case 2

A 65-year-old man was seen in 1975 because of massive swelling of the right lower leg. He had a long history of pain and swelling in the knees, mainly the right. Two days before admission he fell on the ice, and swelling of the lower leg appeared within 24 hours. Physical examination showed a moderate synovial effusion of the right knee, as well as pitting edema, swelling, tenderness, and increased heat over the right calf. On the following day, ecchymoses appeared on the calf, extending as far as the medial malleolus. Arthroscintigraphy, utilizing intraarticular ^{99m}Tc -pertechnetate, demonstrated extension of the radionuclide into the calf for a distance of 7.5 cm from the knee joint. Aspiration of the knee yielded 30 ml of frankly bloody fluid that contained 43,000 leukocytes/mm³ with 92% polymorphonuclear cells; an erythrocyte count was not done. In serial aspirates the amount of blood diminished

progressively. In the final aspirate, on hospital day 10, the synovial fluid leukocyte count was 45,800/mm³ with 92% polymorphonuclear cells; the erythrocyte count was 44,800/mm³. The ecchymotic areas on the calf evolved from dark red to lemon yellow, and the calf swelling, tenderness, and pain diminished progressively. Follow-up studies including a synovial biopsy demonstrated nonspecific chronic synovitis and no recurrence of hemarthrosis.

Comment. It is presumed that this patient with chronic synovitis probably suffered a traumatic hemarthrosis and synovial rupture nearly simultaneously. Arthroscintigraphy was compatible with either synovial rupture or a popliteal cyst. However the ecchymosis supplied graphic evidence of the escape of bloody synovial fluid into the subcutaneum of the lower leg.

Case 3

In 1976 a 21-year-old man noted painless swelling of the left knee 2 days after lifting a disabled motorcycle. On day 4 he had sudden left popliteal pain followed within 24 hours by dull midcalf pain and disappearance of the swelling in the knee. Because swelling and pain of the left leg progressed, he presented to the hospital on day 14 and was admitted with a diagnosis of thrombophlebitis. The left lower leg showed heat, pitting edema, swelling and tenderness, and a positive Homans' sign. Dark red ecchymoses were present behind the left medial malleolus. At first the history of swelling of the left knee was not reported, nor was synovial effusion detected. A venogram was normal. On day 17, the third hospital day, a small effusion and increased heat were detected at the left knee, as well as a tender, ill-defined mass in the proximal medial calf belly. Twenty-eight milliliters of bloody fluid, with an erythrocyte count of 321,000/mm³ and a leukocyte count of 9,900/mm³, were aspirated from the knee. An arthrogram demonstrated a popliteal cyst with extravasation of contrast material at its lower pole. On the following day 58 ml of similar bloody fluid were aspirated. During convalescence at home, the ecchymosis and other calf signs disappeared by day 30. Later an orthopedist diagnosed a posterior meniscal tear.

Comment. Hemarthrosis probably accompanied an acute meniscal tear. Surprisingly the patient was free from pain until synovial rupture 4 days later. On admission at the peak of the calf swelling, several examiners failed to detect synovial swelling at the knee, and heparin therapy was narrowly averted.

Case 4

A 45-year-old man receiving sodium warfarin because of an aortic valve prosthesis twisted his left knee on day 1 in 1976. When seen on day 4 an effusion was palpable at the left knee, but there was no motion pain or tenderness. The prothrombin time was 22.5 seconds (control 11.5). A blood count revealed 5,340,000 erythrocytes/mm³, 6,400 leukocytes/mm³, and 15.1 g hemoglobin/dl. Thirty milliliters of grossly bloody synovial fluid showed an erythrocyte count of 3,580,000/mm³, a leukocyte count of 4,300/mm³, and hemoglobin 10.6 g/dl. At his next outpatient visit on day 11, he was free of pain, though a moderate effusion persisted. Later the same day while walking

vigorously, the patient experienced sudden popliteal pain, and, several hours later, marked swelling and pain in the belly of the calf. On the following day he observed a tender red ecchymosis on the medial third of the anterior tibial surface which felt crepitant to the touch. On day 14 he presented with swelling and tenderness in the right calf. An ill-defined, sausage-shaped mass was palpable in the medial aspect of the gastrocnemius belly. A tender, dark red ecchymosis covered much of the midcalf (Figure 2A). The knee itself was normal. After several days the ecchymosis faded proximally but extended as a crescent around both malleoli as far as the midfoot (Figure 2B), where it was also accompanied by edema and tenderness. The calf pain and swelling resolved in 2 weeks, and effusion in the knee did not recur. At follow-up on day 36, residual ecchymosis was visible only at the medial malleolus as a faint yellow crescent.

Comment. In this case we observed the sequence from the very beginning, starting with a painless hemarthrosis

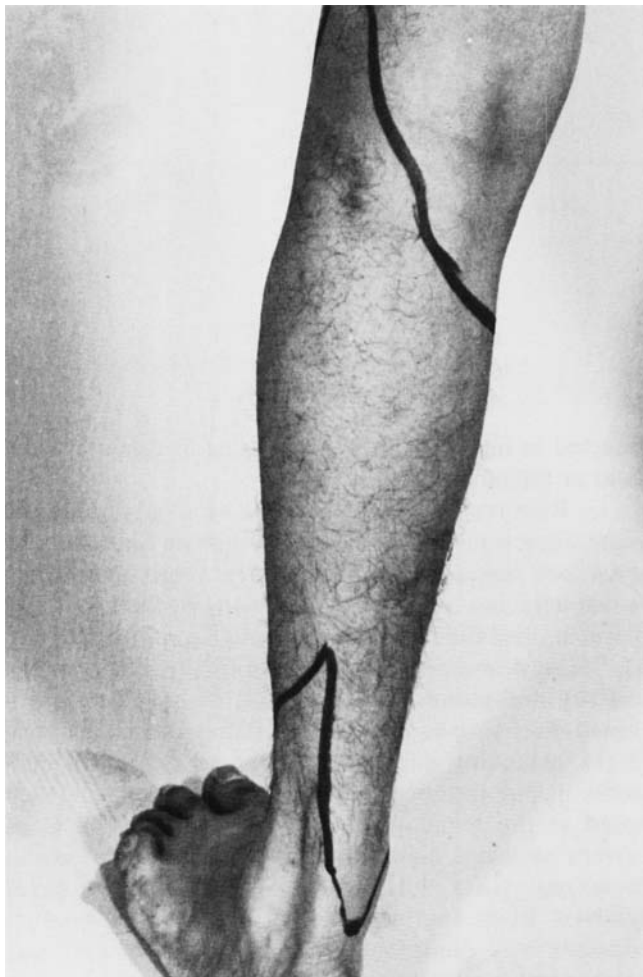

Fig 2A. Case 4. Posterior aspect of the left lower leg 4 days after synovial rupture. Superior and inferior boundaries of the ecchymotic zone are outlined by skin pencil. The ecchymosis includes most of the calf and has not yet extended to the ankle.

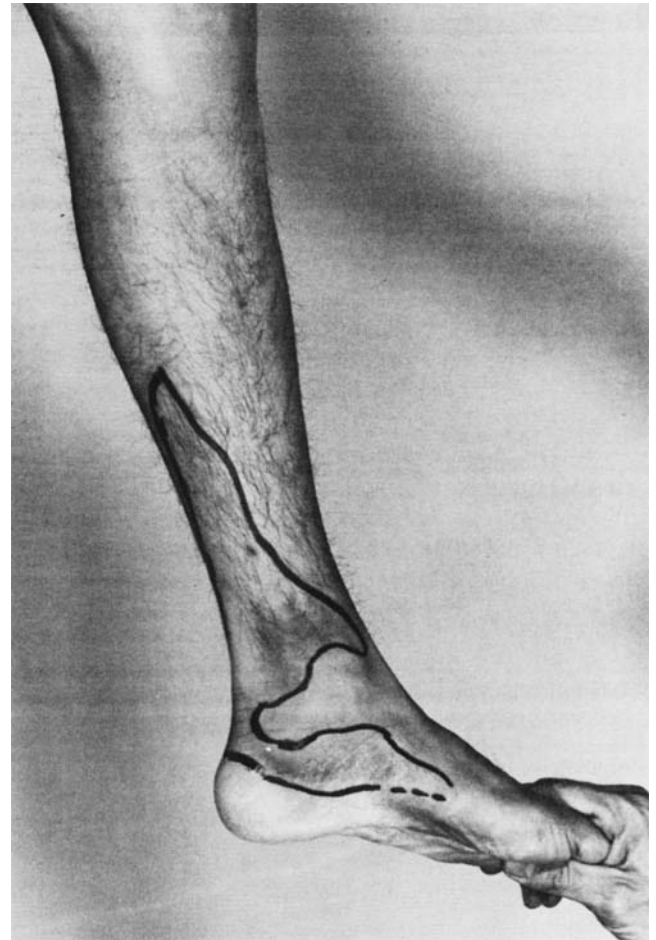


Fig 2B. Case 4, 19 days after synovial rupture. The skin is pencilled to show the ecchymone zone now located in the distal calf encircling the malleolus. By day 36, ecchymosis remained only as a small crescent at the malleolus.

stemming from an anticoagulant plus minor trauma. The knee was normal to examination when the patient returned later with pain and swelling in the calf and an ecchymosis migrating from midcalf to the ankle.

Clinical data for all 4 cases are summarized in Table 1.

DISCUSSION

Common causes for ecchymoses on the legs are trauma, venous stasis, sclerotic superficial vessels, and coagulopathy. In most instances the bleeding is painless, limited to the subcutaneum, and not associated with swelling of the calf. A tender ecchymosis may also follow rupture of the plantaris muscle of the calf (2). Tibbutt and Gunning (3) have reported 4 patients with painful swelling of the calf and ecchymoses extending to the ankle as a crescent around a malleolus. Two of their

Table 1. Clinical Data of 4 Patients with Calf Swelling and Ecchymoses

Case	Age	Trauma	Antecedent Knee Joint Disease	Appearance of "New" Effusion in Knee	Presumed Time of Synovial Rupture*	Period Observed	Initial SA† Demonstrating Hemarthrosis and Highest EC‡/mm ³	Ecchymosis Discovered	Arthrogram Demonstrating Rupture
1	67	Day 1, fall at home	Chronic gout		Day 1	Days 7-17	Day 7, 148,000	Day 7	
2	65	Day 1, fall on ice	Chronic nonspecific synovitis		Day 1	Days 3-12	Day 4, grossly bloody§ Day 10, 44,800	Day 4	Day 4
3	21	Day 1, exertion producing acute posterior meniscal tear	None	Day 3	Day 4	Days 14-19	Day 17, 321,000	Day 14	Day 17
4	45	Day 1, twisted knee while receiving sodium warfarin	None	Day 2	Day 11	Days 4, 11,¶ 14-19, 36	Day 4, 3,580,000	Day 12**	

* Onset of calf swelling and pain.

† SA: synovial aspiration.

‡ EC: erythrocyte count.

§ Erythrocyte count not done on day 10.

¶ Seen before rupture occurred that day.

** Observed by patient at home.

patients had suffered direct trauma to the calf, and the authors proposed the crescent sign as an indicator for intramuscular hemorrhage. In the remaining 2 patients, who had no history of trauma, the origin of the bleeding was unexplained and the authors did not discuss the status of the knee joints; the present experience with a similar crescent sign establishes blood from the knee as an alternative cause of the crescent sign. Hemarthrosis has been associated with a variety of arthropathies (4) and can be painless, as in sodium warfarin overdosage with little or no intrinsic disease of the knee joint (4).

The large ecchymoses in the present patients apparently stemmed from gross intraarticular bleeding that either preceded or coincided with synovial rupture. Minor ecchymoses probably occasionally follow synovial rupture in patients without hemarthroses. The origin of the ecchymoses in such cases could be hemorrhage at the site of the capsular tear or synovial rupture, tracking distally into the calf. During 1976 the authors treated 5 other patients with synovial rupture whose knee aspirates were free of blood. An ecchymosis was

detected in only 1 of these, appearing as a faint yellow stain at the lateral malleolus.

Reports dealing with either synovial rupture or acute dissection of popliteal cysts include scattered observations pertaining to hemorrhage. Deep hematomas in patients not receiving anticoagulant therapy (5,6), blood-stained fluid aspirated directly from the calf (1,7,8), "peau d'orange" discoloration of the skin over the calf (9), and redness of the calf (1,10) have been mentioned. Ecchymoses over the calves have been described (5,11), extending distally as a crescent around a malleolus in one instance (11). Ecchymotic crescents were noted at the malleoli in two recent cases (12). Concurrent synovial fluid findings were not described in these reports (5,11,12). Few authors have included synovial fluid analyses (8,9,13,14), perhaps because effusions may diminish temporarily or even disappear permanently, as in our case 4, following synovial rupture. In one series nonbloody synovial fluid was obtainable from the knee in 7 of 12 patients, amounting to less than 3 ml in 2 cases (8). Bloody knee effusions have been

reported twice (9,14). Bleeding into the calf following synovial rupture may produce a false positive ¹²⁵I-radiofibrinogen test for thrombophlebitis. Misguided anticoagulation in such a case (15) and in other patients (1, 11) with synovial rupture has resulted in large hematomas.

REFERENCES

1. Gerber NJ, Dixon AS: Synovial cysts and juxta-articular bone cysts (geodes). *Semin Arthritis Rheum* 3:323-348, 1974
2. Good AE: Unpublished observation
3. Tibbutt DA, Gunning AJ: Calf haematoma: a new sign in differential diagnosis from deep vein thrombosis. *Br Med J* 4:204, 1974
4. Wild JH, Zvaifler NJ: Hemarthrosis associated with sodium warfarin therapy. *Arthritis Rheum* 19:98-102, 1976
5. Good AE: Rheumatoid arthritis, Baker's cyst, and "thrombophlebitis." *Arthritis Rheum* 7:56-64, 1964
6. Solomon L, Berman L: Synovial rupture of the knee joint. *J Bone Joint Surg* 54B:460-467, 1972
7. Bacon PA, Gerber NJ: Popliteal cysts and synovial rupture in osteoarthritis. *Rheumatol Rehab* 13:98-100, 1974
8. Hall AP, Scott JT: Synovial cysts and rupture of the knee joint in rheumatoid arthritis: an arthrographic study. *Ann Rheum Dis* 25:32-40, 1966.
9. Tait GB, Bach F, Dixon AS: Acute synovial rupture: further observations. *Ann Rheum Dis* 25:273-277, 1965.
10. Schmidt MC, Workman JB, Barth WF: Dissection or rupture of a popliteal cyst. *Arch Intern Med* 134:694-698, 1974
11. Bryan RS, DiMichele JD, Ford GL Jr: Popliteal cysts and "thrombophlebitis." *Clin Orthop* 50:209-213, 1967
12. Kraeg GT, Thevathsan EM, Gordon DA, et al: The hemorrhagic crescent sign of acute synovial rupture. *Ann Intern Med* 85:477-478, 1976
13. Dixon AS, Grant C: Acute synovial rupture in rheumatoid arthritis. Clinical and experimental observations. *Lancet* 1:742-745, 1964
14. Levin MH, Nordyke RA, Ball JJ: Demonstration of dissecting popliteal cysts by joint scans after intra-articular isotope injections. *Arthritis Rheum* 14:591-598, 1971
15. Gibbons D, Phillips M, Prossor IM: Ruptured popliteal cyst simulating deep vein thrombosis with false positive radiofibrinogen uptake. *Postgrad Med J* 51:735-739, 1975