
BRIEF REPORT**SCLEROMYXEDEMA WITH SYSTEMIC INVOLVEMENT MIMICS RHEUMATIC DISEASES**

EDWARD J. FUDMAN, JOSEPH GOLBUS, and ROBERT W. IKE

Scleromyxedema is an infiltrative skin disease produced by hyaluronic acid deposition in the dermis. A benign monoclonal gammopathy is usually present. We report 2 patients with scleromyxedema and systemic illnesses. Both patients had muscle weakness, dysphagia, and weight loss in addition to the skin changes. One also had sclerodactyly, telangiectasias, and Raynaud's phenomenon. Scleromyxedema with systemic involvement may mimic rheumatic diseases.

Scleromyxedema, also known as papular mucinosis or lichen myxedematosus, is an unusual connective tissue disease which is characterized by infiltrative skin lesions and a monoclonal paraprotein. Patients with this disorder rarely have systemic manifestations (1-4). We report 2 cases of scleromyxedema with systemic features which mimicked rheumatic diseases.

Case reports. *Patient 1.* Patient 1, a 45-year-old white man, was in excellent health until 1976, when he developed dyspnea on exertion. Shortly thereafter, he noted the appearance of small white papules over his forearms and the extensor surfaces of his fingers, tightening of the skin around his hands and face, and Raynaud's phenomenon which was precipitated by cold and involved triphasic color changes. The skin

lesions were biopsied and interpreted as scleromyxedema.

Over the next 3 years, the patient was hospitalized twice with severe proximal muscle weakness, dysphagia, weight loss, pain and swelling of his fingers and wrists, facial and truncal telangiectasias, and progressive skin thickening. On both occasions, muscle enzyme levels were elevated and electromyography (EMG) findings were consistent with inflammatory myopathy. Pulmonary function studies revealed a mild decrease in diffusion capacity. Results of a barium swallow were normal. Manometric studies showed striated muscle dysfunction with low contraction amplitudes in the hypopharynx and upper esophagus. A persistent monoclonal IgG λ paraprotein was identified in his serum. Treatment consisted of prednisone, 60 mg/day and melphalan, 2 mg/day; on this regimen, his muscle strength returned and his skin improved.

In 1983, the melphalan dosage was reduced to 2 mg every other day, and the prednisone dosage was tapered as well. Since then he has noted a slow progression in his skin thickness, which severely limits motion about his mouth, fingers, elbows, and knees. The papules have spread and coalesced over the malar region, the glabella, and around his ears.

On examination, his skin revealed diffuse thickening over the upper arms, thighs, chest, and face, especially around the ears, mouth, and forehead. The skin was not "bound-down," but was freely movable over the subcutaneous tissues. There were extensive hard, white papules, 3-6 mm in diameter, over his hands, neck, and forehead, and multiple telangiectasias over his trunk and face (Figure 1). The head, eyes, ears, nose, and throat examination results were

From the Division of Rheumatology, Department of Internal Medicine, University of Michigan Medical Center, Ann Arbor. Edward J. Fudman, MD; Joseph Golbus, MD; Robert W. Ike, MD.

Address reprint requests to Edward J. Fudman, MD, Division of Rheumatology, 3918 Taubman Center, University of Michigan Medical Center, Ann Arbor, MI 48109-0358.

Submitted for publication October 29, 1985; accepted in revised form January 16, 1986.

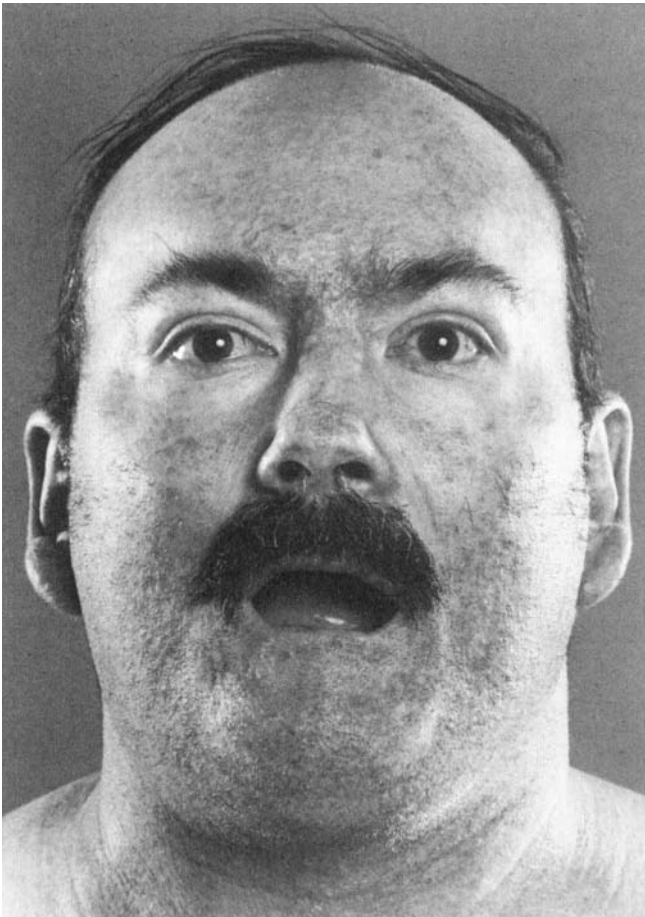


Figure 1. Patient 1, demonstrating telangiectasias, diminished oral aperture, and multiple papules over the bridge of the nose.

within normal limits, except for marked oral dryness and severe dental caries. The chest examination revealed decreased respiratory excursions and diffuse dry basilar crackles. Cardiovascular and abdominal examination results were normal. Examination of the extremities revealed sclerodactyly with flexion contractures of the fingers. Nailfold capillary microscopy showed dilated loops and avascular areas. There were no digital telangiectasias or digital pitting scars. The right elbow had a 15° flexion contracture. No peripheral joint had evidence of active synovitis. A neurologic examination, which included muscle strength testing, gave normal results.

Laboratory studies revealed normal values on complete blood count (CBC) and platelet count. Urinalysis showed 1+ protein. The value for blood urea nitrogen was 31 mg/dl and the creatinine value was 1.4 mg/dl. Creatinine clearance was 53 ml/minute.

The Westergren erythrocyte sedimentation rate (ESR) was 66 mm/hour. Serum protein electrophoresis showed an IgG λ monoclonal spike, though total serum IgG levels were normal. Values for creatine kinase, aldolase, serum glutamic oxaloacetic transaminase (SGOT), serum glutamic pyruvic transaminase (SGPT), and total protein were all within normal limits. Serum tests for rheumatoid factor, antinuclear antibodies (ANA) using rat liver and HEP-2 substrates, complement levels, cryoglobulins, and double-stranded DNA antibodies were all negative or normal. The chest radiograph result was normal. A barium swallow, which had given normal results 6 years earlier, showed diffuse esophageal dysmotility. A bone survey revealed no lytic lesions. A bone marrow biopsy revealed a slight increase in the number of plasma cells, but no other abnormalities. Evaluation for Sjögren's syndrome included a Schirmer's test and a minor salivary gland biopsy, both of which showed normal results. A skin biopsy from the left shoulder was diagnostic of scleromyxedema. There were focal subepidermal mucinous deposits and increased numbers of dermal fibroblasts. Skin appendages were preserved, and there was no increased deposition of collagen in the dermis.

Patient 2. This patient, a 27-year-old black man, first noted proximal muscle weakness when in 1982, during Marine training, he was unable to do pullups. While in Korea in the summer of 1983, he had difficulty stepping into trucks. Later that summer, he developed dysphagia and a diffuse, nonpruritic, papular rash over his arms. He was unable to rise from a squatting position due to progressive muscle weakness. In 1985, a facial rash developed, and he complained of being unable to move his tongue freely. He denied the presence of fevers, myalgias, arthralgias or arthritis, Raynaud's phenomenon, or dyspnea.

Physical examination findings were significant for diffuse facial edema, with erythema in a malar distribution and under the lower lip. There was a fine papular rash over the arms, trunk, back, and knees (Figure 2). He could not fully open his mouth or protrude his tongue. Results of the cardiopulmonary, abdominal, and joint examinations were normal. Muscle bulk was decreased, proximally more than distally. Muscle strength was mildly diminished in the shoulder and hip girdles with intact distal strength. There was no muscle tenderness.

CBC and urinalysis results were normal. The Westergren ESR was 3 mm/hour. Abnormal chemistry results included: SGOT, 137 units; SGPT, 162 units;

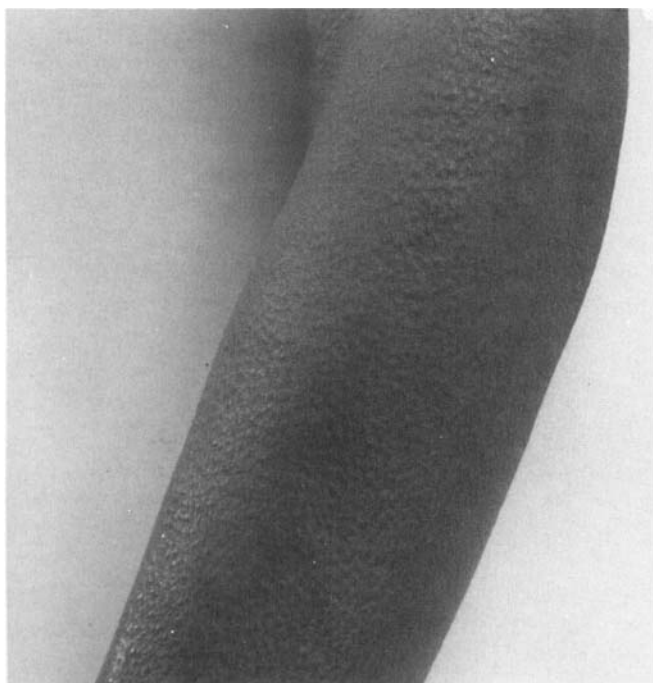


Figure 2. Arm of patient 2, showing multiple fine papules.

lactate dehydrogenase, 830 units; and creatine kinase, 8,400 IU/liter. Serum protein electrophoresis revealed a small monoclonal IgG κ spike. HEP-2, ANA, VDRL, and hepatitis B serologies were all negative. Thyroid function was normal. The chest radiographic results were normal. During a barium swallow, the patient aspirated a large amount of barium, and the study was terminated. The hypopharynx and esophagus were anatomically normal. Results of manometric studies were normal although pharyngeal pressures were borderline low. An EMG revealed a severe inflammatory myopathy with no evidence of neuropathy.

The skin biopsy showed increased fibroblasts in the mid- and deep reticular dermis with diffuse interstitial deposits of acid mucopolysaccharides; these led to a diagnosis of scleromyxedema. Muscle biopsy revealed numerous atrophic and hypertrophic fibers (types I and II), with muscle fiber splitting, internalization of nuclei, and vacuolated fibers. There were scattered necrotic fibers, some of which were undergoing myophagocytosis by macrophages. There was evidence of muscle fiber regeneration. No inflammatory infiltrates were seen (Figure 3). Alcian blue staining did not reveal increased hyaluronic acid deposition in the muscle. Biopsy specimens of liver, bone mar-

row, and sural nerve were all normal, without evidence of infiltrates or of mucin or amyloid deposits.

Discussion. Scleromyxedema is a rare disease of unknown etiology, in which there is deposition of hyaluronic acid within the dermis and, usually, a benign monoclonal gammopathy. The deposition of hyaluronic acid results in nodular, sclerotic skin changes, most commonly involving the face, hands, fingers, and extensor surfaces of the extremities. In addition, there may be generalized lichenoid eruptions, lichenoid plaques, or discrete papules. If the skin becomes diffusely thickened, the disease may resemble scleroderma (1-4).

A monoclonal paraprotein has been found in most patients who have scleromyxedema, including the 2 reported here. Almost always, it is an IgG with λ light chains, although κ light chains have been reported as well (5-8). While the paraprotein is antigenically homogenous in any given patient, there is no evidence for shared idiotypic determinants among

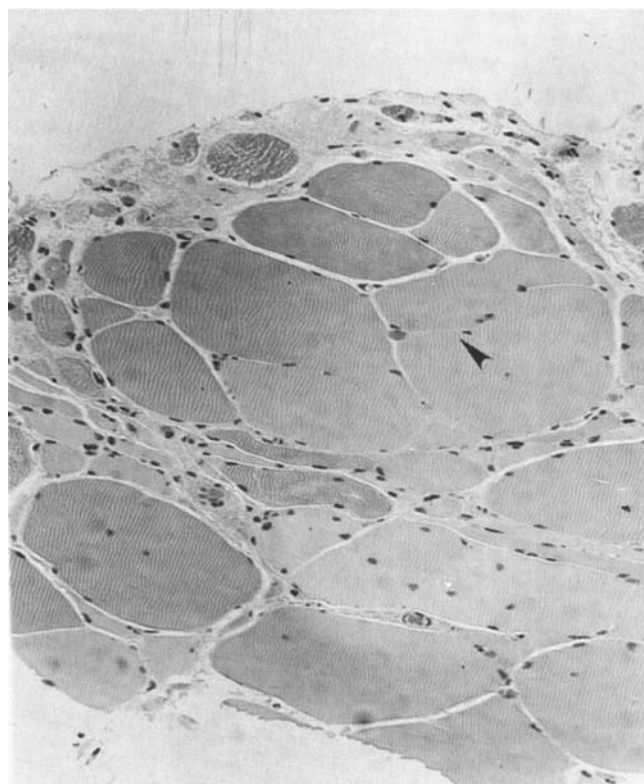


Figure 3. Muscle biopsy from patient 2. Atrophic and hypertrophic fibers are seen, with fiber splitting and central nuclei. **Arrowhead** indicates an example of muscle fiber splitting (hematoxylin and eosin stained, original magnification $\times 100$).

Table 1. Descriptions of myopathy in scleromyxedema*

Ref. no.	Age/sex	Muscle weakness	Muscle evaluation	Dysphagia	Esophageal studies
11	35/M	Proximal	CK elevated, EMG myopathy, biopsy (see text description)	Yes	BS normal M normal
12	58/F	Proximal	CK elevated, EMG inflammatory myopathy, biopsy (see text description)	Yes	Not reported
13	39/F	Unspecified	CK not reported, EMG inflammatory myopathy, biopsy inflammatory myopathy	Yes	BS aperistalsis
Present report	45/M	Proximal	CK elevated, EMG inflammatory myopathy	Yes	BS normal (1979), M striated muscle dysfunction (1979), BS diffuse dysmotility (1985)
Present report	27/M	Proximal	CK elevated, EMG inflammatory myopathy, biopsy (see text description)	Yes	BS aspiration, M borderline low pharyngeal pressures

* CK = creatine kinase; EMG = electromyography; BS = barium swallow; M = manometrics.

individuals (7). Whether the serum paraprotein plays a role in the pathogenesis of the disease is still unknown. Previous studies have reported that serum from patients with scleromyxedema stimulated human fibroblast production. This effect, however, persisted after removal of immunoglobulin (9). A more recent study by Yaron and coworkers (10) found an inhibitory or no effect of scleromyxedema serum on fibroblast proliferation, although the serum did induce a twofold increase in hyaluronic acid synthesis and a thirteenfold increase in prostaglandin E synthesis, as compared with that in controls. This stimulation was inhibited by both hydrocortisone and indomethacin (10). Based on these studies and previous work, the authors suggest that the factor stimulating hyaluronic acid production in patients with scleromyxedema could be mediated through prostaglandins. The component of serum responsible for these effects remains undetermined.

The diagnosis of scleromyxedema was made in both of our patients on the basis of the typical clinical appearance of the cutaneous lesions, skin biopsies that revealed increased deposition of acid mucopolysaccharide without increased collagen deposition, and the presence of IgG paraprotein. While scleromyxedema rarely involves organs other than the skin, the 2 patients presented here had systemic features resembling rheumatic diseases, in addition to cutaneous involvement. Patient 1 had scleroderma-like features of tight skin, sclerodactyly, and a decreased oral aperture, all of which are commonly seen in scleromyxedema. Also, he had systemic features which mimicked systemic sclerosis, including Raynaud's phenomenon, dysphagia, telangiectasias,

myopathy, weight loss, and decreased pulmonary diffusion capacity. Individually, many of these findings have been reported as rare complications of scleromyxedema; however, they have not been reported to occur together in the same patient. Patient 2 presented with cutaneous features of scleromyxedema and developed severe dysphagia, weight loss, and a proximal myopathy that was clinically similar to polymyositis.

Muscle weakness and dysphagia were seen in both our patients. Myopathy has been reported in 6 other patients who had scleromyxedema. The clinical manifestations have been described in only 3 of these patients (Table 1). Two had proximal muscle weakness and the third patient had weakness which was not further characterized. All 3 patients had dysphagia. Creatine kinase was elevated in 2 patients and not reported in the third. An EMG showed electrodiagnostic evidence of an inflammatory myopathy in 2 patients and of myopathy (details not reported) in the third (11-13). Muscle biopsy descriptions have been reported in detail for 2 patients. One biopsy demonstrated atrophic perifascicular fibers with multiple vacuoles and a chronic perivascular inflammatory infiltrate (11). Biopsy samples from the second patient also demonstrated perifascicular atrophy, involving type II fibers only, and a necrotizing myopathy. There were increased glycogen deposits seen in necrotic and vacuolated fibers. Rare inflammatory infiltrates were seen (12). It is also noteworthy that, in 1 patient studied at autopsy (14), pathologic findings showed degeneration and infiltration of lymphocytes in muscle tissues. However, hyaluronic acid deposition was not found in either the biopsy specimens or the autopsy material (11,12,14).

From our 2 patients and the descriptions of 3 others in the literature, it appears that scleromyxedema myopathy manifests primarily as painless proximal muscle weakness and dysphagia. Elevated serum muscle enzymes and inflammatory myopathic changes on EMG are present. No consistent findings on muscle biopsy have been identified thus far. In contrast with the marked hyaluronic acid deposition noted in the dermis, no deposits have been found in any of the muscle biopsy specimens studied.

Several authors have reported other rheumatic features in association with scleromyxedema. Frayha (15) has described a patient with scleromyxedema who developed an erosive seronegative rheumatoid-like arthropathy, carpal tunnel syndrome, sicca complex, and sclerodactyly with acrolysis. There have been 8 additional reports of seronegative rheumatoid arthritis in patients with scleromyxedema; 2 patients had erosive disease. Harris and colleagues (13) reported a patient who, like our first patient, had biopsy-proven scleromyxedema, sclerodactyly, dysphagia with esophageal aperistalsis, diminished diffusion capacity on pulmonary function testing, and an inflammatory myopathy. The pathogenesis of the systemic findings in scleromyxedema remains unknown, since histopathologic analyses of synovial biopsies and other tissue in all of these patients were repeatedly negative for mucin deposition.

As our case reports demonstrate, scleromyxedema, usually considered to be a disease confined to the skin, may have systemic features which mimic rheumatic diseases such as progressive systemic sclerosis and polymyositis. The diagnosis of scleromyxedema should be suspected in patients who have a scleroderma-like illness or myopathy in the presence of a papular eruption or a monoclonal paraprotein. Skin biopsy findings of increased dermal hyaluronic acid deposition without increased collagen deposition are diagnostic of the disease.

REFERENCES

1. Montgomery H, Underwood LJ: Lichen myxedematosus (differentiation from cutaneous myxedemas or mucoid states). *J Invest Dermatol* 20:213-233, 1953
2. Perry HO, Montgomery H, Stickney JM: Further observations on lichen myxedematosus. *Ann Intern Med* 53:955-969, 1960
3. Rudner EJ, Mehregan A, Pinkus H: Scleromyxedema. *Arch Dermatol* 93:3-12, 1966
4. Chanda JJ: Scleromyxedema. *Cutis* 24:549-552, 1979
5. McCarthy JT, Osserman E, Lombardo PC, Takatsuki K: An abnormal globulin in lichen myxedematosus. *Arch Dermatol* 89:446-450, 1964
6. James K, Fudenberg H, Epstein WL, Shuster J: Studies on a unique diagnostic serum globulin in papular mucinosis (lichen myxedematosus). *Clin Exp Immunol* 2:153-166, 1967
7. Wells JV, Fudenberg H, Epstein WL: Idiotypic determinants on the monoclonal immunoglobulins associated with papular mucinosis. *J Immunol* 108:977-983, 1972
8. Lai A Fat RFM, Suurmond D, Radl J, van Furth R: Scleromyxedema (lichen myxedematosus) associated with a paraprotein, IgG, of kappa type. *Br J Dermatol* 88:107-116, 1973
9. Harper RA, Rispler J: Lichen myxedematosus serum stimulates human skin fibroblast proliferation. *Science* 199:545-547, 1978
10. Yaron M, Yaron I, Yust I, Brenner S: Lichen myxedematosus (scleromyxedema) serum stimulates hyaluronic acid and prostaglandin E production by human fibroblasts. *J Rheumatol* 12:171-175, 1985
11. Johnson BL, Horowitz IR, Charles CR, Cooper DL: Dermatomyositis and lichen myxedematosus. *Dermatologica* 147:109-122, 1973
12. Verity MA, Toop J, McAdam LP, Pearson CM: Scleromyxedema myopathy. *Am J Clin Pathol* 69:446-451, 1978
13. Harris RB, Perry O, Kyle RA, Winkelman RK: Treatment of scleromyxedema with melphalan. *Arch Dermatol* 115:295-299, 1979
14. McCuiston CH, Schoch EP: Autopsy findings in lichen myxedematosus. *Arch Dermatol* 74:259-262, 1956
15. Frayha RA: Papular mucinosis, destructive arthropathy, median neuropathy, and sicca complex. *Clin Rheumatol* 2:277-284, 1983