

fibroblullous changes, chest wall restriction, and rare cricoarytenoid joint involvement (1,6). BOOP has been previously linked to many underlying connective tissue diseases (5). Although autopsy studies have suggested a common occurrence between AS and bronchiolitis (7), there have been only 2 reports in the literature that could support a causal relationship (3,4). We present a woman with progressive pulmonary impairment in association with AS and suggest that AS should be considered as a rheumatic disorder possibly associated with BOOP.

The opinions and assertions contained herein are those of the authors and are not to be construed as official policy of the Department of the Army or the Department of Defense.

J. F. Turner, MD
Raymond J. Enzenauer, MD
Fitzsimons Army Medical Center
Aurora, CO

1. Wiedemann HP, Matthay RA: Pulmonary manifestations of the collagen vascular diseases. *Clin Chest Med* 10:677-722, 1989
2. Hakala M, Paakko P, Sutinen S, Huhti E, Koivisto O, Tarkka M: Association of bronchiolitis with connective tissue disorders. *Ann Rheum Dis* 45:656-662, 1986
3. Epler GR: Bronchiolitis obliterans organizing pneumonia: definition and clinical features. *Chest* 102 (suppl):2S-6S, 1992
4. Henneghien C, Schreiber S, Remack P, Bruart J: Apical pulmonary fibrosis and rheumatoid polyarthritis. *Rev Mal Respir* 5:143-146, 1988
5. Cordier J-F: Cryptogenic organizing pneumonitis: bronchiolitis obliterans organizing pneumonia. *Clin Chest Med* 14:677-692, 1993
6. Rosenow EC, Strimlin CV, Muhm JR, Ferguson RH: Pleuropulmonary manifestations of ankylosing spondylitis. *Mayo Clin Proc* 52:641-649, 1977
7. Spencer H: *Pathology of the Lung*. Oxford, Pergamon, 1977

Methotrexate therapy for hearing loss in Cogan's syndrome

Cogan's syndrome is an uncommon disease characterized by nonsyphilitic interstitial keratitis and vestibulo-auditory dysfunction (1,2). Other manifestations include conjunctivitis, iritis, and, less commonly, a systemic necrotizing vasculitis (1-3). The disease can progress to deafness, but usually responds to corticosteroids provided therapy is begun early (4). However, some patients cannot tolerate the side effects of corticosteroid therapy, and this therapy is not always successful. Alternative forms of therapy for Cogan's syndrome are not well described in the literature, and the use of methotrexate (MTX) in the treatment of this disorder has not been reported. This report describes a patient with Cogan's syndrome in whom corticosteroid therapy was poorly tolerated, but who had a dramatic response to low-dose MTX.

The patient was an otherwise healthy man who developed fluctuating bilateral hearing loss in April 1986, when he was 29 years old. This was followed shortly thereafter by symptoms of eye irritation, intermittent tinnitus, and positional vertigo. Evaluation at an outside hospital revealed bilateral keratitis, conjunctivitis, and iritis, and

diminished hearing (60 dB speech recognition threshold [SRT] on the right with 72% word discrimination and 45 dB SRT on the left with 80% discrimination). Audiometry confirmed bilateral hearing loss, with identical decreases in air and bone conduction (Figure 1A). Results of a computed tomography scan of the head were normal. He was begun on a regimen of oral prednisone 60 mg daily and an ocular corticosteroid preparation for a presumed diagnosis of Cogan's syndrome, with subjective improvement in his hearing and ocular symptoms.

He was first seen at the University of Michigan in August 1986. At that time the prednisone dosage had been decreased to 20 mg daily, and eye drops were no longer required. The evaluation included repeat audiometry, which documented improvement (Figure 1B). Laboratory studies showed a normal hemoglobin level and platelet count, a mild leukocytosis (11,400/mm³), normal urinalysis and serum protein electrophoresis results, normal serum complement levels, a Westergren erythrocyte sedimentation rate of 2 mm/hour, and negative rheumatoid factor, antinuclear antibody, and VDRL. Chest radiography findings were normal. Evaluation by the rheumatology service revealed no clinical evidence of the vasculitis sometimes associated with Cogan's syndrome (2).

The patient continued to take 20 mg prednisone daily, but in December 1986 he again reported fluctuating hearing loss and eye irritation, necessitating an increase in the prednisone dosage to 40 mg daily and the use of corticosteroid eye drops. This hearing loss is documented in the audiogram shown in Figure 1C. Over the next several months his hearing continued to fluctuate despite therapy with antihistamines, diuretics, and increases of the prednisone dosage to 60 mg daily, which resulted in a cushingoid appearance, weight gain, and acne.

In June 1987, MTX (7.5-10 mg/week) was added to the treatment regimen as a steroid-sparing agent. This was followed promptly by a marked improvement in hearing. The prednisone dosage was tapered, and by September 1987 he was taking MTX only, with sustained improvement. The patient decreased his weekly MTX dosage to ≤ 2.5 mg on his own, but found that discontinuation always led to recurrence of hearing loss. He continued to take MTX at 2.5-10 mg/week through November 1992; repeated attempts to discontinue the medication always led to a recurrence of hearing loss. However, in May 1993, the patient reported that he had successfully discontinued MTX without loss of hearing. An audiogram performed in December 1993 documented near-normal hearing in his right ear, and a moderate decrease in his left (Figure 1D).

There is little doubt about the diagnosis in this patient. The combination of keratitis, conjunctivitis, sensorineural hearing loss, and a response to prednisone strongly supports the diagnosis of Cogan's syndrome. Other diseases often included in the differential diagnosis of Cogan's syndrome are congenital syphilis, sarcoidosis, other systemic autoimmune diseases and systemic infections, toxic conditions, and Meniere's disease with an unrelated eye disorder (2,5), but there was little evidence to support these diagnoses in this patient. Patients with Cogan's syndrome can develop cochlear hydrops (1), which may have contributed to some of the fluctuations in hearing acuity reported in this case.

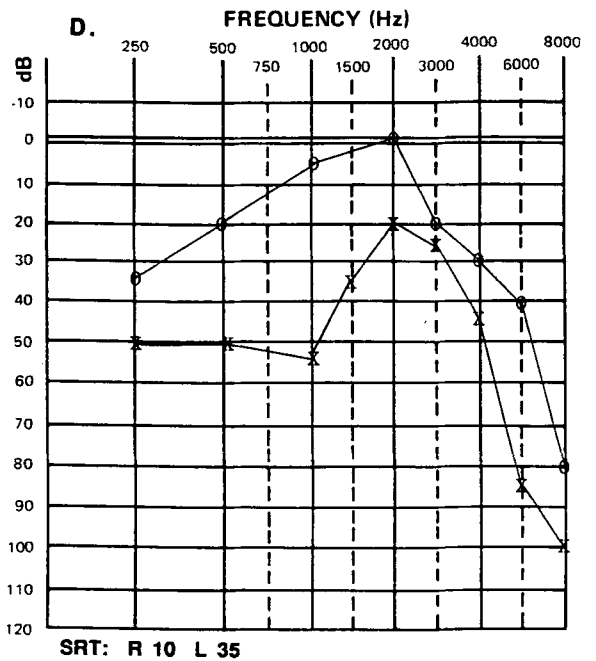
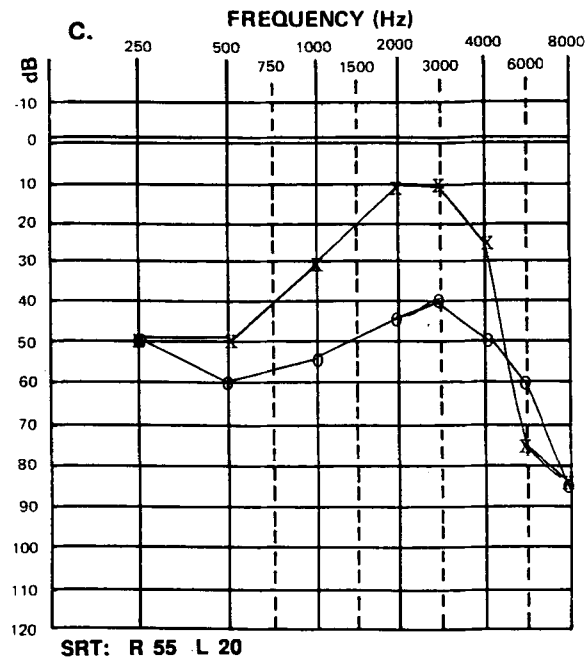
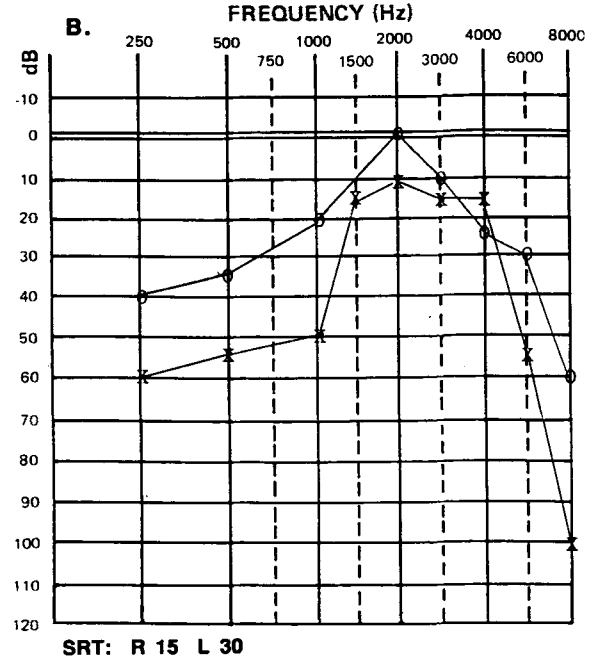
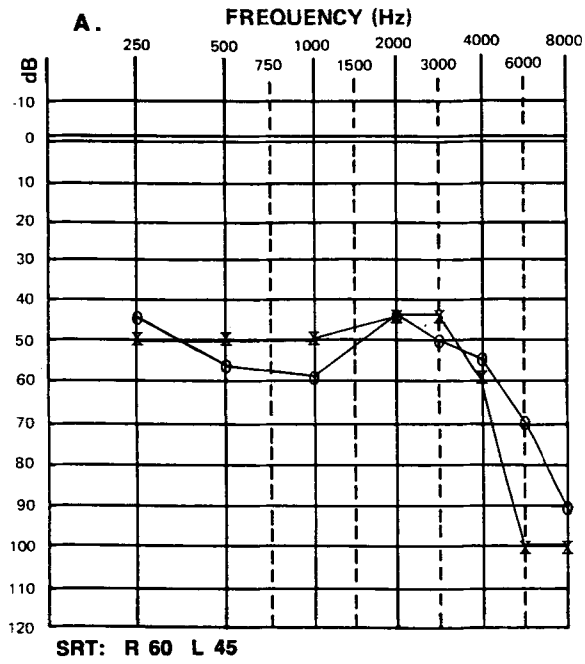


Figure 1. Serial audiograms of the patient with Cogan's syndrome, who began methotrexate treatment in 1987. A, May 1986. B, September 1986. C, December 1986. D, December 1993. × represents left ear; ○ represents right ear. Air and bone conduction were identical in all audiograms. SRT = speech reception threshold, measured in decibels.

This patient's illness demonstrated the usual good response to prednisone (4). However, cushingoid side effects limited the use of this drug. The addition of low-dose methotrexate allowed complete discontinuation of corticosteroid therapy within 3 months. It is unlikely that the prompt response represents a spontaneous remission in a normally fluctuating illness, because repeated attempts to discontinue MTX led to recurrence of the hearing loss. He was ultimately able to discontinue the MTX, but this could be due to either the therapy or a spontaneous remission.

Immunosuppressive therapy has been used in the treatment of Cogan's syndrome, but usually in patients with the associated vasculitis. Agents used include azathioprine (2), cyclophosphamide (2,6), leukapheresis (2), cyclosporin A (6), and FK 506 (7). There is one report of remission in a patient successfully treated with azathioprine and prednisone whose regimen was later switched to MTX and prednisone (8). However, this patient had already had a response to the initial therapy, and it is unclear whether MTX induced the remission.

Since Cogan's syndrome often requires prolonged use of corticosteroids, with predictable side effects, it is reasonable to investigate alternative forms of therapy. This report suggests that methotrexate may, with careful monitoring, be used as a steroid-sparing agent to reduce or prevent steroid side effects. Further testing of this agent in the treatment of Cogan's syndrome appears warranted.

Supported by PHS grants AR-42525, AR-20557, and AR-41703.

Bruce Richardson, MD, PhD
University of Michigan
Ann Arbor, MI

1. Haynes BF, Kaiser-Kupfer MI, Mason P, Fauci AS: Cogan syndrome: studies in thirteen patients, long-term follow-up, and a review of the literature. *Medicine (Baltimore)* 59:426-441, 1980
2. Vollertsen RS, McDonald TJ, Younge BR, Banks PM, Stanson AW, Ilstrup DM: Cogan's syndrome: 18 cases and a review of the literature. *Mayo Clin Proc* 61:344-361, 1986
3. Cogan's syndrome (editorial). *Lancet* 337:1011-1012, 1991
4. Haynes BF, Pikus A, Kaiser-Kupfer M, Fauci AS: Successful treatment of sudden hearing loss in Cogan's syndrome with corticosteroids. *Arthritis Rheum* 24:501-503, 1981
5. Bielory L, Conti J, Frohman L: Immunology grand rounds: Cogan's syndrome. *J Allergy Clin Immunol* 35:808-815, 1990
6. Allen NB, Cox CC, Cobo M, Kisslo J, Jacobs MR, McCallum RM, Haynes BF: Use of immunosuppressive agents in the treatment of severe ocular and vascular manifestations of Cogan's syndrome. *Am J Med* 88:296-301, 1990
7. Roat MI, Thoft RA, Thomson AW, Jain A, Fung JJ, Starzl TE: Treatment of Cogan's syndrome with FK 506: a case report. *Transplant Proc* 23:3347, 1991
8. Wilder-Smith E, Roelcke U: Cogan's syndrome. *J Clin Neurol Ophthalmol* 10:261-263, 1990

From the Editor's Desk

Submitters of manuscripts to be considered for publication in *Arthritis and Rheumatism* should be aware of the following policy: If there is a potential reviewer to whom the authors do not want the manuscript assigned, they may attach a letter to this effect, with a brief explanation of the reason. These requests will be honored in most cases.

Peter H. Schur, MD
Editor, *Arthritis and Rheumatism*