

## Pulmonary Sequestration: Ultrasonic Appearance

Mark H. Jaffe, MD, Estelle R. Bank, MD, Terry M. Silver, MD,  
and Richard A. Bowerman, MD

Pulmonary sequestration is a congenital anomaly in which aberrant, nonfunctioning lung tissue receives its entire blood supply from the systemic circulation. Early diagnosis may be difficult because the radiographic and clinical presentation may be mimicked by other lesions, such as cystic adenomatoid malformation, congenital bronchogenic cyst, pleural effusion, congenital diaphragmatic hernia, or large diaphragmatic eventration. The following case is presented to describe and illustrate the sonographic appearance of pulmonary sequestration. To our knowledge, a case in which sonography provided the correct preoperative diagnosis has not been reported.

### CASE REPORT

M.K. was the 3,950-gm product of a 39-wk uncomplicated pregnancy. The labor, delivery, and immediate postnatal course were unremarkable. At 26 hr of life, the infant developed duskiness, with tachypnea of up to 120 respirations per minute. At two days he was transferred to the University of Michigan Medical Center for evaluation and treatment. Physical examination revealed absent breath sounds over the left chest and no cardiac murmurs. A chest radiograph showed a large, homogeneous soft tissue mass in the left posterior hemithorax which displaced the heart and mediastinum to the right (Fig 1). A portable real-time ultrasound examination showed a large, hyperechoic, solid left intrathoracic mass which occupied the lower left thorax. The mass did not cross the diaphragm, and its shape suggested that its origin was pulmonary (Fig 2A, 2B). Tubular

branching structures representing blood vessels were identified within the mass. A pulmonary sequestration was diagnosed (Fig 2C). There was no pleural effusion or intra-abdominal abnormality. The attenuation coefficient of the mass on a computed tomography (CT) chest scan ranged between 10 and 30 HU, intermediate between fluid and solid (Fig 3). Echocardiography was normal and aortography was not performed.

On the fifth day of life, the infant underwent resection of an extralobar sequestration measuring  $10 \times 8 \times 4.5$  cm. The sequestered lobe was supplied by a vascular pedicle arising from the descending aorta at the level of the diaphragm. On microscopic evaluation, dilated bronchioles and alveolar ducts largely replaced lung parenchyma. Large, elastic-lined arteries were seen at the periphery of the mass. The left lung was somewhat small on inspection, but bronchoscopy was

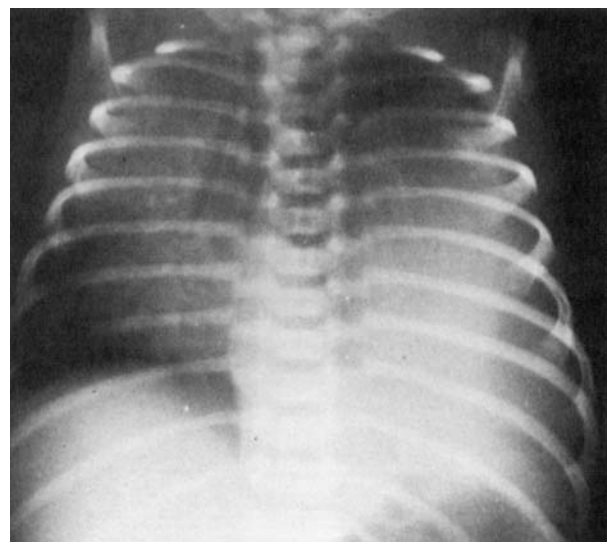
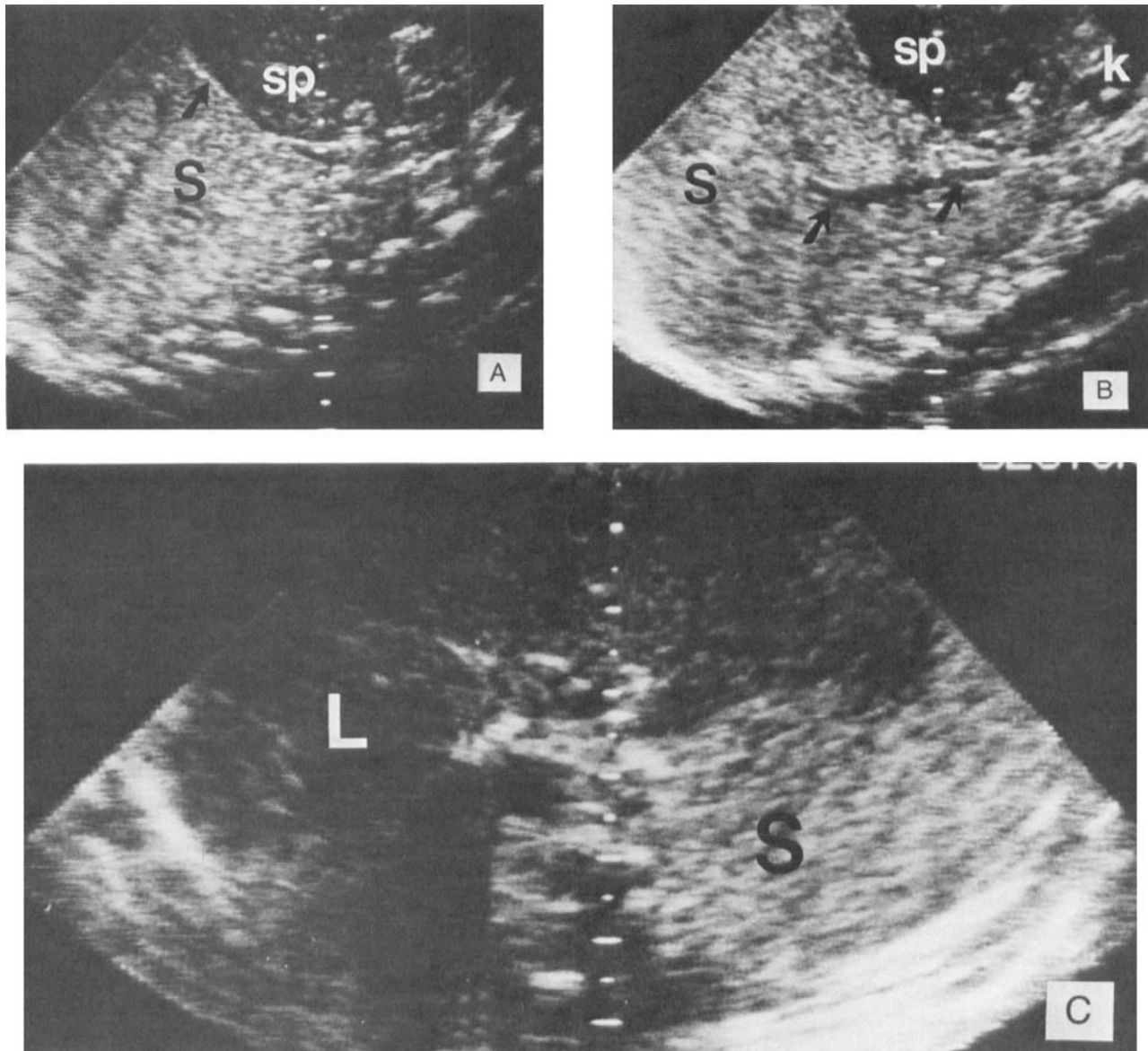


FIGURE 1. A chest radiograph demonstrating a large soft tissue mass in the left hemithorax displacing the heart and mediastinum to the right.

From the Department of Radiology, Ultrasound Division, University of Michigan Medical Center, Ann Arbor. Manuscript received August 10, 1981; manuscript accepted October 5, 1981. For reprints contact Mark H. Jaffe, MD, Department of Radiology, Ultrasound Division, Box 13, University Hospital, Ann Arbor, MI 48109.



**FIGURE 2.** Supine sagittal (A,B) and transverse (C) sonograms of the juxtadiaphragmatic region, performed with a mechanical sector scanner. **A:** Sagittal scan through the left chest and abdomen, demonstrating the pulmonary sequestration (S) separated by the diaphragm (arrow) from the spleen (sp). **B:** Sagittal scan more medial in the left chest and abdomen demonstrating the pulmonary sequestration (S) with its arterial supply (arrows), followed by a real-time scan from the aorta in the abdomen. sp: spleen. k: kidney. **C:** Transverse scan through the juxtadiaphragmatic region demonstrating the sequestration (S) low in the chest. It is more echogenic than the liver (L).

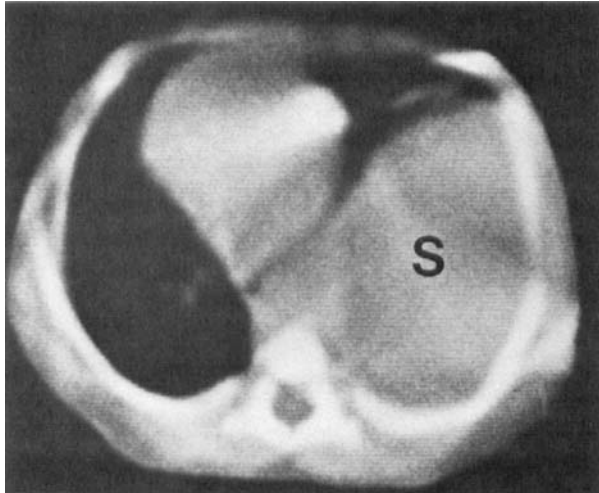
normal. Physical examination and chest radiograph were essentially normal at 4 weeks of age.

#### DISCUSSION

Pulmonary sequestration is one of several anomalies that have been recently grouped into a category known as bronchopulmonary foregut malformations.<sup>1</sup> Sequestrations which cause symptoms in infancy tend to be large and of the extralobar type, outside the pulmonary visceral pleura, and without communication with the bronchial tree. However, the majority of seques-

trations are intralobar, encased in the same visceral pleura as the normal lung. Respiratory distress is caused by mechanical factors: compression of normal lung and shifting of the mediastinum by the large mass.

The value of sonography in the evaluation of abdominal neonatal masses is established. Our case illustrates the usefulness of this technique in evaluating noncardiac thoracic lesions which border on the diaphragm or the pleural space. Such lesions are readily evaluated by sonography since there is no *interposed aerated lung*. Furthermore, sonography has the added advantage of



**FIGURE 3.** CT scan of the chest revealing a mediastinal shift and normal lung on the left, anterior to the pulmonary sequestration (S). The attenuation coefficient of the sequestration measures 10–30 HU.

portability, which is of benefit to infants with respiratory distress who cannot be transported.

The differential diagnosis of a neonatal space-occupying lesion involving one hemithorax producing a large opaque hemithorax includes pleural effusion, tumor, cyst, cystic adenomatoid malformation, sequestration, fluid-filled lung with lobar emphysema or bronchial atresia, congenital diaphragmatic hernia, or eventration.<sup>2</sup> Sonography can easily differentiate a large pleural effusion (whether due to chylothorax, hemothorax, or hydrothorax) from intraparenchymal pulmonary disease and nonpulmonary masses. Other intrathoracic lesions can be evaluated if adequate acoustic windows exist,<sup>3</sup> that is, if the lesion borders on the diaphragm or chest wall. Mediastinal cysts, whether bronchial or pericardial, can sometimes be differentiated from pulmonary lesions.<sup>3</sup>

Parenchymal lung lesions can be divided into solid and cystic groups. Cystic adenomatoid malformation is a condition in which there are numerous intercommunicating cysts of various sizes associated with an adenomatoid increase of terminal respiratory structures. Many of these cysts are macroscopic and can be easily seen on chest radiographs after they become filled with air. They should be identifiable ultrasonically at an earlier stage when they are fluid filled and have been detected in utero.<sup>4</sup> Cystic adenomatoid malformation can be confused radiographically with congenital diaphragmatic hernia because

air-filled cysts and air-filled bowel may look similar. Ultrasonically, these structures should be distinguishable by identifying peristalsis and the characteristic sonographic appearance of bowel. Communication of bowel above and below the diaphragm in patients with congenital diaphragmatic hernia can also be recognized. Eventration of the diaphragm has a characteristic sonographic appearance as well.<sup>3</sup> Congenital lobar emphysema is extremely rare as a lower lobe lesion and can therefore be discounted.<sup>1</sup>

Our case demonstrates typical sonographic features of pulmonary consolidation without obvious cystic change. The appearance of the sequestered lung is similar to that described previously in patients with pneumonia and atelectasis but is more echogenic.<sup>3</sup> Microscopic examination of the resected specimen revealed dilated bronchioles which were too small (less than 1 mm in diameter) to be resolved ultrasonically. The numerous interfaces from these "cysts" account for the hyperechoic appearance, analogous to the kidney in infantile polycystic kidney disease.<sup>5</sup> Although the attenuation number of 10–30 HU on CT was intermediate between fluid and solid, the solid nature of the mass was obvious sonographically. The anomalous arterial supply of the sequestered lung was seen and could be demonstrated on real time to emanate from the abdominal aorta. Mediastinal shift was also appreciated ultrasonically.

Sonography demonstrated the salient features of this congenital lesion. It showed that the mass was intrathoracic, nonpleural, parenchymal, and solid. It excluded congenital diaphragmatic hernia, congenital cystic adenomatoid malformation, and pleural processes, resulting in the correct preoperative diagnosis of sequestration.

#### REFERENCES

1. Swischuk LE: *Radiology of the Newborn and Young Infant*, ed 2. Baltimore, Williams & Wilkins, 1980, pp 143–149.
2. Swischuk LE: *Radiology of the Newborn and Young Infant*, ed 2. Baltimore, Williams & Wilkins, 1980, pp 187–188.
3. Haller JO, Schneider M, Kassner EG, et al: Sonographic evaluation of the chest in infants and children. *AJR* 134:1019, 1980.
4. Donn SM, Martin JN Jr, White SJ: Antenatal ultrasound findings in cystic adenomatoid malformation. *Pediatr Radiol* 10:180, 1981.
5. Boal DK, Teele RL: Sonography of infantile polycystic kidney disease. *AJR* 135:575, 1980.