

## Case Reports

# Superimposed Stents in the Management of Acute Recoil After Palmaz-Schatz Stenting

Robert J. Lederman, MD, and Mauro Moscucci,\* MD

We report a patient in whom aorto-ostial stenting with a Palmaz-Schatz coronary stent was complicated by significant acute elastic recoil, despite appropriate positioning of the stent and full expansion of a high-pressure, postdilatation balloon. Superimposing a Palmaz biliary stent overcame the inward radial force of this lesion and achieved an adequate lumen. *Cathet. Cardiovasc. Diagn.* 44:407–410, 1998. © 1998 Wiley-Liss, Inc.

**Key words:** aorto-ostial stenosis; percutaneous transluminal coronary angioplasty; mechanical stress; stents

### INTRODUCTION

Endoluminal coronary stenting is associated with reduced major adverse clinical events in patients with select lesion characteristics, when compared with percutaneous transluminal coronary angioplasty (PTCA) [1,2]. Although luminal scaffolding does not appear to reduce intimal hyperplasia, a reduction in adventitial contraction [3,4] and in elastic recoil [5,6] probably accounts for the observed reduction in angiographic restenosis.

Registry experience [7] suggests that these benefits may not be generalizable to patients with other lesion characteristics, including those with significant calcification, angulation, tortuosity, or involving aorto-coronary or branch ostia. Stenting these lesions may be limited by inadequate expansion or apposition of the stent against the vessel wall, by dissections at the stent margins, or by entrapment of significant branch vessels. We report a patient in whom aorto-ostial stenting was complicated by significant acute elastic recoil, despite appropriate positioning of the stent and full expansion of the high-pressure, postdilatation balloon.

### CASE REPORT

A 72-yr-old retired office manager had disabling effort angina and dyspnea. He had diabetes mellitus, hypercholesterolemia, and a remote anterior wall myocardial infarction. Left ventriculography revealed severe left ventricular systolic dysfunction with ejection fraction 0.30, anterolateral akinesis, and apical dyskinesis. The left anterior descending artery was occluded proximally. A large nondominant circumflex artery had calcified 90%

stenoses involving the origin of the first marginal branch. The dominant right coronary artery (RCA) had a mildly calcified 90% ostial and a 70% proximal stenosis. Low-dose dobutamine infusion improved function of the inferoposterior and lateral walls, but not of the LAD territory. In consultation with a cardiothoracic surgeon, the patient found the risk of aortocoronary bypass grafting to be excessive and opted to undergo percutaneous revascularization.

Revascularization was planned in two stages, first involving the right coronary artery. An 8 Fr Judkins Right 4 guiding catheter (Cordis Brite-Tip™, Johnson & Johnson Interventional Systems, Warren, NJ) with sideholes engaged the RCA ostium. The stenosis were crossed with a 0.014" High Torque Extra S'port™ wire (ACS, Santa Clara, CA) and predilated with a 3.5 mm NC Bandit™ balloon (Scimed, Maple Grove, MN). Balloon occlusion of the RCA promptly induced hypotension with elevation of the pulmonary artery diastolic pressure, limiting the duration of balloon inflations. The balloon required 12 atmospheres (atm) for full expansion (Fig. 1C), although the RCA ostium recoiled almost completely after balloon deflation (Fig. 1D). Two adjacent articulated coronary

Division of Cardiology, University of Michigan Medical Center, Ann Arbor, Michigan

\*Correspondence to: Mauro Moscucci, M.D., Division of Cardiology, B1 F245, University of Michigan Medical Center, 1500 East Medical Center Drive, Ann Arbor, MI 48109-0022.  
E-mail: Moscucci@umich.edu

Received 20 October 1997; Revision accepted 11 February 1998

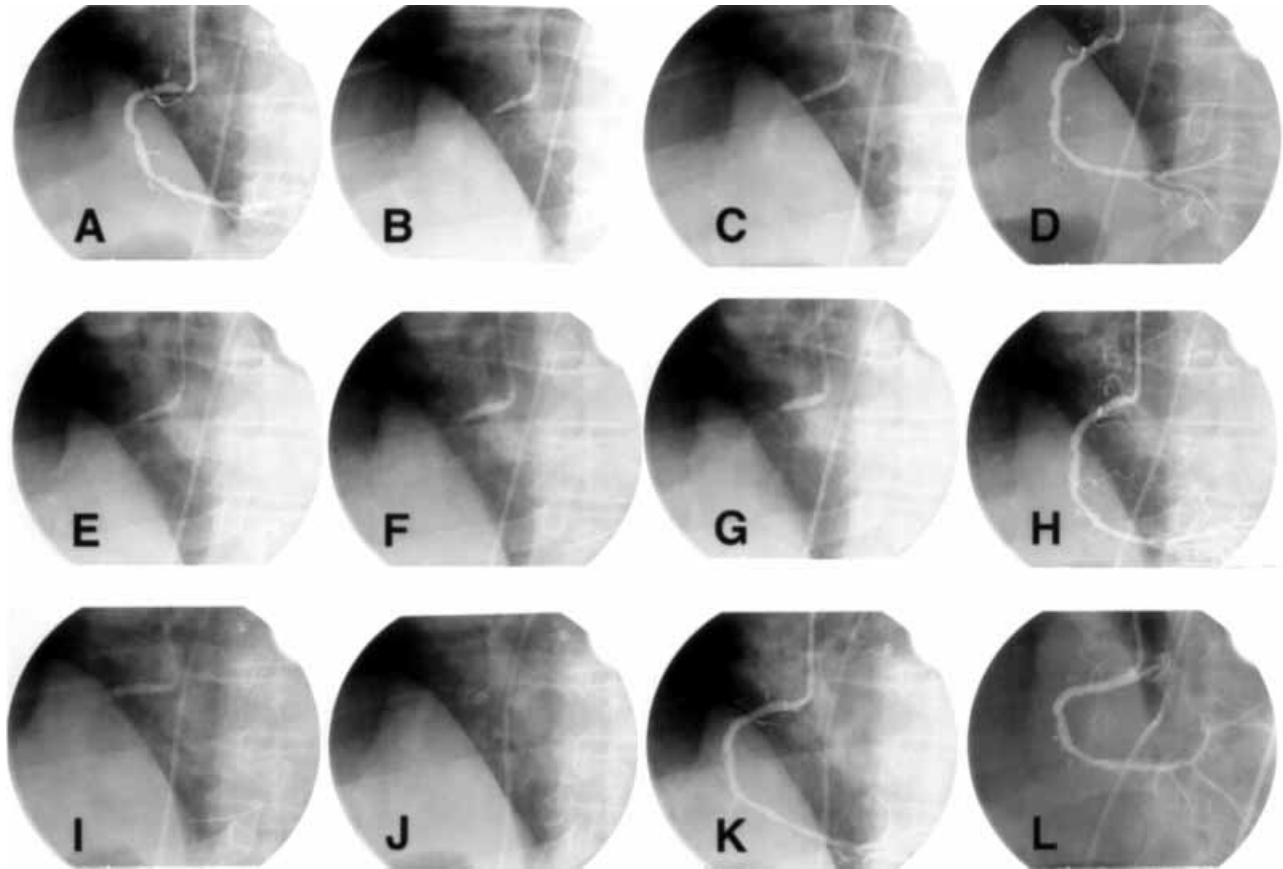


Fig. 1. A. Right coronary angiography in LAO view showing a critical stenosis at the origin of the RCA. B. Initial predilatation. A “waist” can be seen in the proximal end of the balloon. C. Full expansion of the predilatation balloon at 12 atm. D. Angiography after predilatation shows significant elastic recoil. E. Stent deployment at 8 atm. F, G. Postdilatation of the stent with full expansion of the postdilatation balloon. H. Angiography after

stent postdilatation, showing significant recoil with a 50% residual stenosis. I, J. Deployment of the Palmaz Biliary stent at 20 atm. K. Angiography immediately after deployment of the biliary stent. There is no evidence of stent recoil when compared with H. L. Final postdilatation angiography, showing a fully expanded stent and no residual stenosis.

stents (PS1540, Johnson & Johnson) were then deployed to cover both lesions and to extend slightly into the aorta. Both were postdilated with a Scimed  $4.0 \times 20$  mm NC Bandit at up to 20 atm (Scimed). There was full balloon expansion during inflation (Fig. 1F,G). The guiding catheter was manipulated during balloon inflation to “flare” the proximal end of the stent across the aortic ostium.

Immediately afterward, angiography showed that the ostial coronary stent recoiled and had a 50% residual diameter stenosis (Fig. 1H). Therefore, a 10 mm Palmaz biliary stent (P104, Johnson & Johnson) was hand-crimped on the NC Bandit balloon and deployed across the recoiled ostial segment at 20 atm. There was no residual stenosis (Fig. 1I–K). The proximal end of the stent was then flared by inflating the balloon to 24 atm (Fig. 1L). The patient was treated afterward with ticlopidine, aspirin, ACE inhibitors, pravastatin, and nitrates.

Two weeks later, he underwent uneventful rotational atherectomy of the marginal branch and stenting of the left circumflex artery. At 6 mos follow-up, he remained free of cardiac symptoms, and a dual isotope rest thallium-201 adenosine stress technetium-99m sestamibi SPECT study showed no inducible ischemia.

## DISCUSSION

Percutaneous revascularization of ostial right coronary artery stenosis can be technically challenging [8]. The aorto-coronary ostium is prone to recoil after balloon dilatation, presumably because of elastic tissue surrounding the coronary artery as it penetrates the aortic wall. The presence of ostial calcification also may contribute to lesion rigidity. Guiding catheters may occlude the treated vessel and cause ischemia, may undermine ostial plaque leading to coronary dissection and acute vessel closure,

**TABLE I. Mechanical Properties of Coronary and Biliary Johnson & Johnson Stents\***

	Coronary PS1530	Biliary P104
Stent thickness (in)	0.0025	0.0055
Expansion range (mm)	3–6	4–9
Radial compressive force at 4 mm (atm)	0.45	1.71

\*Adapted from Sklar and Schatz [10].

and must be withdrawn from the treated ostium in order to deliver the angioplasty device. Therefore, interventions on ostial right coronary artery stenosis are associated with increased procedural complications as well as with higher angiographic and clinical restenosis [9]. Newer percutaneous revascularization techniques including directional [11–13], laser [14], and rotational atherectomy [15,16] as well as endoluminal stenting [17,18] may be more successful [10]. In particular, coronary stents achieve a larger postprocedure minimal lumen diameter and can prevent acute recoil and geometric remodeling of the vessel by applying a significant outward radial force.

Self-expanding stents (*e.g.*, Wallstent™, or Radius™ stent) are considered *elastic* at clinically relevant pressures. That is, they deform linearly with increasing pressure and then return to their previous shape after that pressure is withdrawn. Balloon-expandable stents (*e.g.*, Palmaz-Schatz™ stent, or Gianturco-Roubin™ stent) also exhibit elastic properties at low pressures, but become *plastic*, or deformable, at pressures beyond a *yield point*. With balloon inflation to pressures greater than the yield point, as during stent deployment, these stents do not return to their previous shape and thereafter generate sufficient outward radial force to resist vessel recoil [19,20].

Coronary arteries are generally compliant and, when distended, rarely generate pressures exceeding the yield point of available endoluminal stents. We hypothesize that in this patient, the fibrocalcific right coronary ostium was sufficiently stiff to exceed the yield point of the Palmaz-Schatz stent, yet not stiff enough to prevent full expansion of the noncompliant balloon used for predilatation. The second overlapping stent probably increased the effective yield point beyond that of the treated lesion, thereby maintaining an adequate postprocedure lumen. Indeed, using an *in vitro* model, Lossef *et al.* [19] report that overlapping 10 mm Palmaz stents nearly doubled the yield point. Moreover, the “biliary” Palmaz stent exerts a greater radial compressive force than does the “coronary” Palmaz-Schatz stent (see Table I).

Only three other cases of acute stent recoil have been reported. Itoh *et al.* [21] stented a calcified vessel after rotational atherectomy. Despite high-pressure postdilatation, the stented lumen was suboptimal by intravascular

ultrasound; the patient subsequently suffered subacute stent thrombosis. An adequate lumen was restored only after placing a disarticulated PS1530 within the first stent. In another patient, a PS1530 was inadequately expanded at a site of deep and superficial calcification, but fully expanded after a second P084 stent was deployed within the first. Kereiakes [8] describes a lesion similar to the one reported here, which also required overlapping stents to overcome acute stent recoil. We cannot exclude the possibility that in our case rotational atherectomy could have prevented stent recoil. We routinely perform rotational atherectomy before stenting if there is any fluoroscopic evidence of lesion calcification. In this case, rotational atherectomy was considered but not performed because the lesion was felt not to be significantly calcified and because of the underlying left ventricular systolic dysfunction. Had we been unable to adequately expand the predilatation balloon, we would have switched to rotational atherectomy with hemodynamic support.

In conclusion, our experience suggests that acute recoil of an endoluminal stent in the aortocoronary ostium can occur and that revascularization strategies should include consideration of debulking, or the selection of a stent with adequate radial strength. Once recoil has occurred, it may be treated satisfactorily by superimposing a second endoluminal stent.

## REFERENCES

1. Serruys PW, de Jaegere P, Kiemeneij F, et al.: A comparison of balloon-expandable-stent implantation with balloon angioplasty in patients with coronary artery disease. Benestent Study Group. *N Engl J Med* 331:489–495, 1994.
2. Fischman DL, Leon MB, Baim DS, et al.: A randomized comparison of coronary-stent placement and balloon angioplasty in the treatment of coronary artery disease. Stent Restenosis Study Investigators. *N Engl J Med* 331:496–501, 1994.
3. Hoffmann R, Mintz GS, Dussaillant GR, et al.: Patterns and mechanisms of in-stent restenosis. A serial intravascular ultrasound study. *Circulation* 94:1247–1254, 1996.
4. Mintz GS, Popma JJ, Pichard AD, et al.: Arterial remodeling after coronary angioplasty: A serial intravascular ultrasound study. *Circulation* 94:35–43, 1996.
5. Haude M, Erbel R, Issa H, Meyer J: Quantitative analysis of elastic recoil after balloon angioplasty and after intracoronary implantation of balloon-expandable Palmaz-Schatz stents. *J Am Coll Cardiol* 21:26–34, 1993.
6. Somitsu Y, Ikari Y, Ui K, et al.: Elastic recoil following percutaneous transluminal coronary angioplasty and Palmaz-Schatz stent implantation. *J Invasive Cardiol* 7:165–172, 1995.
7. George C, Kennard E, Holubkov R, Detre K: Are STRESS results generalizable? The NACI-PSS experience [Abs]. *J Am Coll Cardiol* 29:495A, 1997.
8. Kereiakes DJ: Percutaneous transcatheter therapy of aorto-ostial stenoses. *Cathet Cardiovasc Diagn* 38:292–300, 1996.
9. Topol E, Ellis S, Fishman J, et al.: Multicenter study of percutaneous transluminal angioplasty for right coronary artery ostial stenosis. *J Am Coll Cardiol* 9:1214–1218, 1987.

10. Safian RD, Freed M, Reddy V, et al.: Do excimer laser angioplasty and rotational atherectomy facilitate balloon angioplasty? Implications for lesion-specific coronary intervention. *J Am Coll Cardiol* 27:552–559, 1996.
11. Popma J, Dick R, Haudenschild C, Topol E: Atherectomy of right coronary artery ostial stenoses: Initial and long-term results, technical features, and histologic findings. *Am J Cardiol* 67:431–433, 1991.
12. Stephan WJ, Bates ER, Garratt KN, et al.: Directional atherectomy of coronary and saphenous vein graft ostial stenoses. *Am J Cardiol* 75:1015–1018, 1995.
13. Kerwin PM, McKeever LS, Marek JC, et al.: Directional atherectomy of aorto-ostial stenoses. *Cathet Cardiovasc Diagn Suppl* 1:17–25, 1993.
14. Eigler NL, Weinstock B, Douglas JS, Jr, et al.: Excimer laser coronary angioplasty of aorto-ostial stenoses. Results of the excimer laser coronary angioplasty (ELCA) registry in the first 200 patients. *Circulation* 88:2049–2057, 1993.
15. Koller PT, Freed M, Grines CL, WW ON: Success, complications, and restenosis following rotational and transluminal extraction atherectomy of ostial stenoses. *Cathet Cardiovasc Diagn* 31:255–260, 1994.
16. Zimarino M, Corcos T, Favereau X, et al.: Rotational coronary atherectomy with adjunctive balloon angioplasty for the treatment of ostial lesions. *Cathet Cardiovasc Diagn* 33:22–27, 1994.
17. Rocha-Singh K, Morris N, Wong SC, et al.: Coronary stenting for treatment of ostial stenoses of native coronary arteries or aortocoronary saphenous venous grafts. *Am J Cardiol* 75:26–29, 1995.
18. Zampieri P, Colombo A, Almagor Y, et al.: Results of coronary stenting of ostial lesions. *Am J Cardiol* 73:901–903, 1994.
19. Lossef SV, Lutz RJ, Mundorf J, Barth KH: Comparison of mechanical deformation properties of metallic stents with use of stress-strain analysis. *J Vasc Interv Radiol* 5:341–349, 1994.
20. Berry J, Newman V, Ferrario C, et al.: A method to evaluate the elastic behavior of vascular stents. *J Vasc Interv Radiol* 7:381–385, 1996.
21. Itoh A, Hall P, Maiello L, et al.: Acute recoil of Palmaz-Schatz stent: A rare cause of suboptimal stent implantation-report of two cases with intravascular ultrasound findings. *Cathet Cardiovasc Diagn* 37:334–338, 1996.