

# Feasibility of MR Diffusion Studies in the Kidney

Cary Lynn Siegel, MD • Alex M. Aisen, MD • James H. Ellis, MD • Frank Londy • Thomas L. Chenevert, PhD

**Renal apparent diffusion coefficients (ADCs) were anisotropic within and significantly different between cortex and medulla using a relatively motion-insensitive one-dimensional technique in 20 volunteers. ADC values ranged from  $1.79 \pm .39$  to  $2.95 \pm .58$  ( $\times 10^{-3} \text{mm}^2/\text{sec}$ ), relatively high but similar to other reports. Further investigation may help clarify this data, and determine whether the findings result from diffusion properties (and/or radially oriented parenchymal architecture), or artifacts due to factors such as bulk motion.**

**Index terms:** MR imaging, diffusion • Kidneys key

**Abbreviations:** ADC = apparent diffusion coefficient.

**JMRI 1995; 5:617-620**

From the Department of Radiology, University of Michigan Medical Center, Ann Arbor, MI 48109-0030. Present address for C.L.S., Mallinckrodt Institute of Radiology, Washington University School of Medicine, St. Louis, MO. Present address for A.M.A., Department of Radiology, Indiana University Medical Center, 550 N. University Blvd, Indianapolis, IN 46202. Presented at the annual meeting of the Association of University Radiologists, 1993. Received February 14, 1994; revision requested June 14; revision received January 18, 1995; accepted March 2. Address reprint requests to A.M.A.

© SMR, 1995

MOLECULAR DIFFUSION refers to the thermally driven, random motion of molecules within a medium. Nuclear MR techniques have been developed to quantify and characterize diffusion (1-4). LeBihan et al extended these concepts to the in vivo situation, and generalized the types of random motion that occur in tissues in the intravoxel-incoherent motion model (2,3). This model considers the effects of molecular diffusion and microcirculatory flow in the capillaries as diffusionlike processes. It is theoretically possible to quantify the combined effects of capillary perfusion and water diffusion in vivo via an apparent diffusion coefficient (ADC) and to isolate the perfusion fraction and diffusion components by specific assumptions and measurements.

A quantitative diffusion measurement made by using MR techniques can provide information on the normal or abnormal structure of tissues. Numerous factors influence water mobility in vivo, including possible restrictions by membranes and other structures, such as macromolecules. Some factors may have directionality or anisotropy, which can result in variation in the ADC with orientation. Unfortunately, in practice, there are limitations on accurate measurements of ADC values. Artifacts from bulk tissue motions related to muscular, respiratory, or cardiac pulsations are highly amplified in most pulse sequences designed for diffusion sensitivity (5-7). Results measured in vivo must be interpreted with these limitations in mind.

The purpose of this study was to investigate a custom, one-dimensional technique to study diffusion in the human kidney. This method offers substantial reduction of motion artifacts, and has been previously used to study the human brain (4). The goal was to assess the feasibility and reproducibility of quantitative, anisotropic diffusion measurements of the normal native kidney in vivo. If reliable diffusion measurements of the kidney can be made in vivo, then further investigations to determine if they are useful in diagnosing or grading disease states will be appropriate.

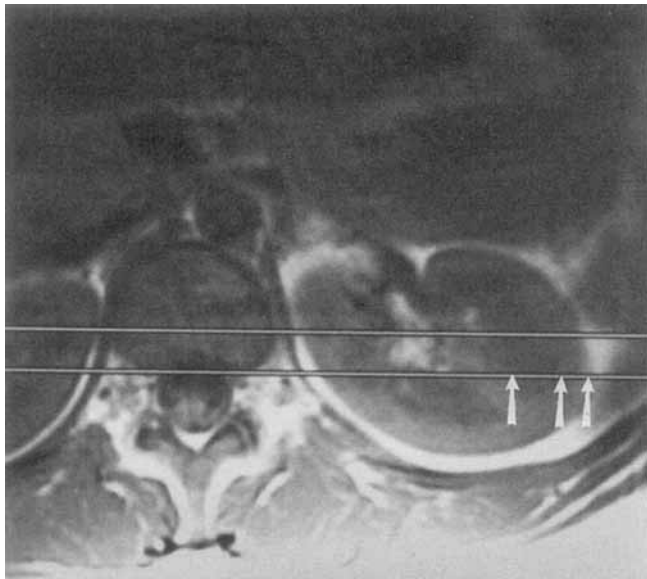
## ● MATERIALS AND METHODS

The study consisted of two parts. The first, to study diffusion in a series of

healthy persons, consisted of 20 healthy volunteers, each of whom was studied once. The second part was designed to assess intrapersonal variation; four healthy subjects were studied serially four or five times each. The volunteers were given no special preparation before their arrival at the MR imaging facility, and were scanned in a presumably normal state of hydration. No attempt was made to control for hydration state, a factor that may have influenced results (8). Subjects were studied with a General Electric 1.5-T Signa instrument (GE Medical Systems, Milwaukee, WI) in the supine position, with an optical pulse sensor placed on an index finger. The initial study of 20 subjects was made using 4.x scanner software and hardware; the study of intrapersonal variations was made using version 5.x. All scans were performed during quiet respiration. Initial coronal locator images were obtained to identify the left kidney. A 5.5-inch general purpose surface coil was then placed beneath the left kidney. Contiguous 10-mm-thick T1-weighted spin-echo (TR/TE = 500/11) axial images were then obtained.

These axial locator images were reviewed and a slice in the midzone of the left kidney was chosen where there was good corticomedullary distinction and the cortical medullary boundaries were constant, both in the anteroposterior (AP) and superoinferior (SI) direction. Thus, as the kidney moved with respiration, the relative position of the cortex and the medulla within the diffusion column would remain relatively steady. Image location was further selected to avoid columns of Bertin.

Our technique included orthogonal 90° and 180° slice selective pulses, which yielded a spin echo from tissue within a 10 × 10 mm transversely oriented column through the retroperitoneum (4). Frequency encoding was performed along the right/left (R/L) column axis, providing a one-dimensional dataset at 10 × 10 × 2-3 mm (adjusted for patient size and field of view) resolution. Bulk tissue motion artifacts were reduced by Fourier transformation of individual echoes. Echo signal magnitude was determined, and the results of 20 measurements were averaged as described below. Phase encoding was not applied. This phase-insensitive processing scheme prevented interecho phase cancellation artifacts. In addition, intrae-



**Figure 1.** Axial T1-weighted locator image from a representative patient shows the diffusion column.

cho phase cancellation from bulk motion was reduced by pulse gating, with an acquisition delay of 500 msec. Respiratory compensation was not used. Preliminary tests indicated highest ADC values were in the R/L direction, possibly because the greatest cardiac pulsation waves would propagate along R/L lines as transmitted by the renal artery and its branches. These pulsation waves can result in signal loss and an artifactually elevated ADC measurement. Intravoxel phase cancellation from the R/L bulk tissue motion was believed to be minimized by orienting the short dimension of the voxels along this direction.

Trapezoidal, 35-msec duration, diffusion-sensitization gradient pulses were separated by 64 msec and straddled the 180° pulse of the TE = 120 msec sequence. Two gradient strengths (4 and 9 mT/m) were iteratively applied along the R/L, AP, and SI directions in an acquisition of 128 echoes. This scheme provided 20 echoes for each of the six gradient conditions (the initial eight echoes were ignored to establish the steady-state condition). An additional 128 phase-encoded echoes were interleaved with the ADC acquisition to yield a crude image confirming that the desired plane was sampled. The precise TR time for each subject varied with heart rate, and was approximately 1700 msec, resulting in an acquisition time of about 4 minutes. Nominal b factors of  $b_1 = 73$  and  $b_2 = 370$  sec/mm<sup>2</sup> associated with the 4 and 9 mT/m gradient amplitudes, respectively, were derived by numerical integration of each complete gradient waveform. Other gradient waveforms were designed to be temporally compact to minimize gradient cross-terms (slice-selective 90°, and frequency-encoded waveforms, including rephase pulses, produced no cross-terms) (9). ADC estimates were derived by the following equation:  $ADC = \ln(S_1/S_2)/(b_2 - b_1)$ , where S1 and S2 are the signal amplitudes acquired by b1 and b2 b factors,

respectively.  $ADC_{AP}$ ,  $ADC_{SI}$ ,  $ADC_{R/L}$ , and  $ADC_o$ , defined as  $(ADC_{R/L} + ADC_{AP} + ADC_{SI})/3$ , were calculated for each voxel along the transversely oriented diffusion column. Because cross terms are minimal,  $ADC_o$  is a scalar invariant of the diffusion tensor; that is, it is a property of tissue and does not depend on the orientation of the gradients (10,11).

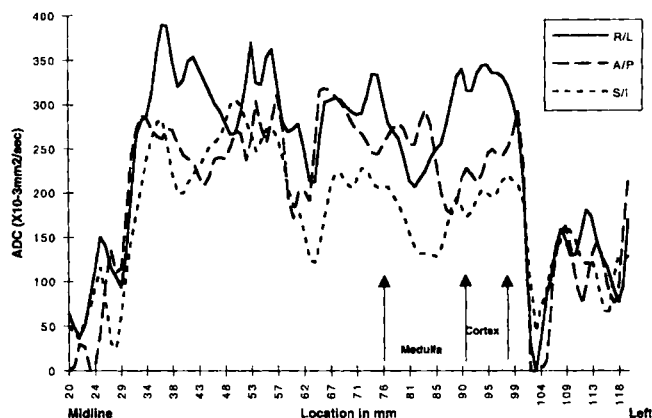
Time domain data were transferred to an off-line workstation and processed with custom modules programmed using Advanced Visual Systems software (Waltham, MA), yielding three ADC data series for each case, corresponding to the three diffusion-sensitization directions. One-dimensional ROIs comprising renal medulla and cortex were defined on the basis of coordinates obtained from the two-dimensional axial images. The calculated ADC values for these voxels were averaged together for each subject. A Student's two-tailed paired t-test was used for statistical analysis of the data from all volunteers. The renal cortex ADC measurements in each direction were compared with their medullary counterparts. To determine possible tissue anisotropy, the ADC values in each direction were compared.

#### • RESULTS

Figure 1 is a representative T1-weighted axial image through the midzone of the left kidney at the level that data were acquired. The prescribed location of the column is indicated on the image with the cortical and medullary boundaries marked. Figure 2 shows ADC measurements in the same subject as a function of position from the midline of the abdomen to the left lateral abdominal wall.

Table 1 shows the mean ADC values for the 20 healthy volunteers, and the P values for the statistical comparisons. Figure 3 shows the range of ADC values in the three directions for cortex and me-

#### ADC By Location



**Figure 2.** Graph from a representative study shows the measured ADC values in a column running from the midline to the left abdominal wall. The renal cortex and medulla are demarcated by vertical arrows.

dulla. Figure 4 shows the same for the four subjects in the intrapersonal analysis. The large spread in the data in Figure 4 indicates that there is substantial measurement error inherent in the technique as now implemented. Nevertheless, most of the findings seen in the 20-patient study are borne out in this dataset as well.

For the 20 volunteers, the cortical ADC values in the R/L and SI directions were somewhat higher than the medullary values ( $P < .001$  in both directions); there was no statistically significant difference in the AP direction. Note that there is substantial anisotropy: the cortical and medullary ADC values were greatest in the R/L orientation whereas the ADCs in the SI direction were the lowest. The differences shown in the means in Table 1 are confirmed by comparing the values in individual subjects.  $ADC_{R/L}$  was greater than  $ADC_{AP}$  in 15 subjects in the medulla and in 19 subjects in the cortex. Similarly,  $ADC_{R/L}$  was greater than  $ADC_{SI}$  in 19 volunteers in the medulla and in all 20 volunteers in the cortex. In addition,  $ADC_{AP}$  was greater than  $ADC_{SI}$  in 18 subjects for the medulla and in 17 subjects for the cortex. Finally, the  $ADC_o$  was greater in the cortex than the medulla in 18 subjects.

Similar trends were noted for the intrapersonal data for all comparisons except  $ADC_{AP}$  versus  $ADC_{SI}$ .

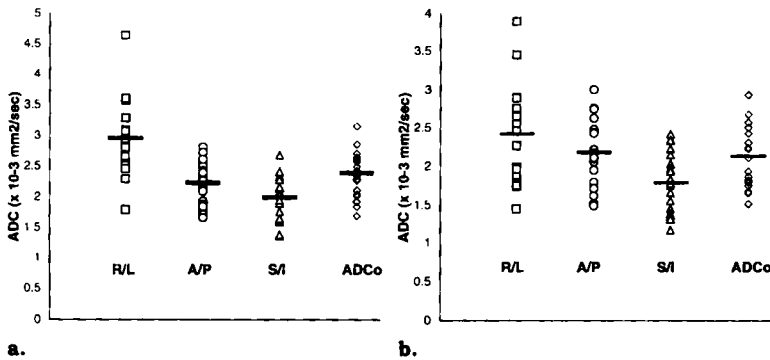
#### • DISCUSSION

Diffusion-sensitive MR imaging has been applied in a variety of forms to animal and human studies. One notable success has been in the study of stroke in animal models using diffusion-weighting imaging, where pixel intensity is inversely related by the relative diffusion rates in each voxel. Increased signal intensity resulting from a relative drop in diffusion-like motion is observed in ischemic brain before abnormalities become visible on conventional MR images (12).

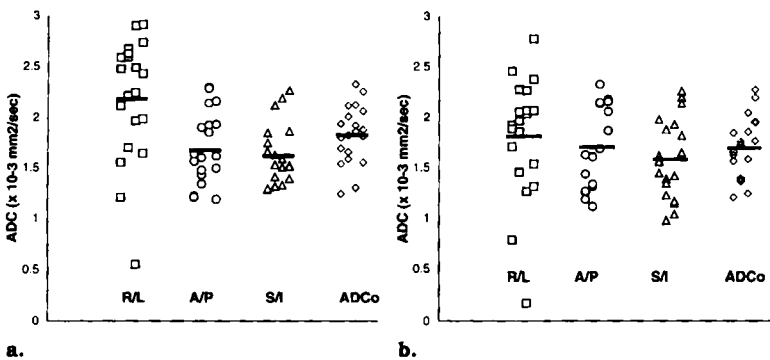
In addition to imaging, it is also possible to make quantitative measurements of the diffusion properties of tissue using

**Table 1**  
**Summary of Apparent Diffusion Coefficient (ADC) Values Expressed as Mean  $\pm$  SD ( $10^{-3}\text{mm}^2/\text{sec}$ );  $n = 20$ . (The  $P$  values [paired, two-tailed, Student's  $t$ -test] for the group comparisons are also shown)**

	Direction			ADC <sub>0</sub>	Statistical Comparison		
	Right/Left (R/L)	Anteroposterior (AP)	Superoinferior (SI)		P value, SI versus AP	P value, SI versus R/L	P value, AP versus R/L
ADC cortex	2.95 $\pm$ 0.58	2.22 $\pm$ 0.34	2.00 $\pm$ 0.37	2.39 $\pm$ 0.38	< .003	< $4 \times 10^{-9}$	< $1.5 \times 10^{-6}$
ADC medulla	2.43 $\pm$ 0.60	2.20 $\pm$ 0.43	1.79 $\pm$ 0.39	2.14 $\pm$ 0.38	< .0005	< $3 \times 10^{-5}$	< .086
P value (cortex versus medulla)	< .00015	< .74	< .0004	< .0002			



**Figure 3.** Plot shows the ADC values for renal cortex (a) and medulla (b) in the three spatial directions for the 20 kidneys. The horizontal bars show the means.



**Figure 4.** Plot shows the ADC values for renal cortex (a) and medulla (b) in the three spatial directions for the four kidneys. Each volunteer was scanned four or five times, and the data points for each subject appear in single vertical columns, in each of the four groups: R/L, AP, SI, and ADC<sub>0</sub>. The horizontal bars show the means.

MR imaging (1-3,13). The numerical values obtained are referred to as ADCs. These values may be anisotropic, that is, they may vary with the spatial orientation of the diffusion-sensitizing gradients used to make the measurements. It is hoped that diffusion measurements may help characterize tissues, thereby aiding in diagnosis. This has been clearly demonstrated in the brain (14,15), and at least one preliminary report suggests that it may apply in the abdomen as well (16).

Diffusion is a property of a tissue related to molecular mobility. The diffusion of molecules in a tissue, being limited by obstacles such as macromolecules, fibers, and cellular membranes, should be less than pure water, which has an ADC of about  $3 \times 10^{-3} \text{mm}^2/\text{sec}$  at body temperature (2,3). Bulk tissue motion, such as from respiration, peristalsis, or vascular pulsations, often interferes with quantitative diffusion measurements. Such

motion will attenuate MR signal in the presence of gradients, which tends to produce an artifactually elevated ADC measurement. This effect has placed practical limits on the application of quantitative diffusion measurements to many in vivo situations. Thus, most clinical and animal diffusion studies have concentrated on relatively immobile tissues, such as brain and extremities or excised organs (4,12,14-24). Our data confirm that bulk motion is a serious problem in making diffusion measurements in the abdomen.

Cardiac gating techniques and/or immobilization techniques can be used to reduce the artifacts due to motion. Echoplanar imaging can be used for diffusion studies in vivo as an effective means of reducing the undesirable effects of bulk tissue motion. However, echoplanar imaging requires special scanning equipment presently available at only a few institutions. Thus far, there have been few pub-

lished reports of diffusion studies involving intraabdominal organs in vivo (8,16,21,24).

We used an alternative approach to reduce measurement artifacts related to bulk tissue motion. Specifically, we used a technique in which one-dimensional datasets through the tissue of interest were acquired. Our results in the kidney show a wide range of ADC values for the renal cortex and medulla with some overlap. We found considerable variability within the cortex and medulla of individual subjects as well (Fig 2). The variation in the graph over relatively homogeneous tissues reflects noise and measurement error in the small voxels used, as well as possible partial volume effects. The latter are probably inevitable in an organ with internal structure on a size scale similar to the kidney. As shown in Table 1, our data showed ADC values in the SI and AP directions almost as high as the diffusion coefficient of pure water. In the R/L direction, ADC values above that of water were found. There is substantial spread even in the intrapersonal data. Thus, in spite of our relatively motion-insensitive technique, an initial consideration is whether the numbers we report reflect the diffusion properties of water in the in vivo kidney. Possible causes of artifactual elevation include cardiac pulsatility forces on the kidney and bulk motion from respiration and blood flow. Though our data show considerable scatter, trends over the total volunteer population are evident. The relative ordering of the ADC values by direction was relatively constant, with the highest values in the R/L direction. This strongly suggests that something other than only random noise is present. This might be either true anisotropic diffusion effects or anatomically oriented motion, such as transmitted arterial pulsations.

Elevation of ADC in the R/L direction, that is, along the radial axis of the kidney, might be understood by considering the image location that was chosen for diffusion analysis. The renal lateral cortex and medulla were studied at the level of the renal hilus. At this level, the renal arterial pulsation waves would be expected to propagate along the R/L axis from the renal hilus outward. The venous and lymphatic flow also move along this axis in this imaging plane; little AP or SI directionality would be attributed to arterial, venous, or lymphatic flow. Transmitted pulsations may have raised the ADC values, particularly in the R/L direction; this may also explain the larger measurement standard deviations in this direction. In

addition, tubular reabsorption, secretion, and urine flow would follow a similar path at this level. Alternatively, the differential ADC values may represent anisotropic diffusion. Like myelinated white matter tracts in the brain (4), the kidney has a substantial directionality to its architecture. We were unable to separate the contributions of motion artifact and true structural differences to the spatial variation in our ADC measurements, and we consider this an area appropriate for future study.

Several other investigators have reported ADC measurements in the kidney. There are at least two reports of *ex vivo* measurements. Lorenz et al estimated the diffusion coefficient in an isolated dog kidney preserved in formalin to be  $1.90 \pm 0.02 \times 10^{-3} \text{ mm}^2/\text{sec}$  (13,17). Powers et al estimated the diffusion coefficient in an excised dog kidney to be  $2.10 \times 10^{-3} \text{ mm}^2/\text{sec}$  (18). We are encouraged by the similarity of our results to those of other investigators in the *in vivo* kidney. Using echoplanar techniques to measure renal diffusion *in vivo* in normal volunteers, Müller et al found renal ADC values of  $3.54 \times 10^{-3} \text{ mm}^2/\text{sec} \pm 0.47$  (16,24). These results were acquired within a single breath-hold to avoid respiratory motion, but they still found ADC values above pure water. In a second study, Müller et al investigated renal diffusion with subjects initially dehydrated and subsequently hydrated. The mean ADC value for dehydrated subjects was  $2.88 \pm 0.65 \times 10^{-3} \text{ mm}^2/\text{sec}$  and for rehydrated subjects the mean was  $3.56 \pm 0.32 \times 10^{-3} \text{ mm}^2/\text{sec}$  (8). In the same work (16,24), Müller et al report ADC values for liver, spleen, and muscle that were substantially below those of the kidney.

Our study was performed without specific instructions on hydration, and this may explain the wide range of values from subject to subject, as Müller et al found hydrated patients to have ADC values 25% higher than some patients when dehydrated. Also of note in Müller's study was no statistically significant differences between cortex and medulla.

In conclusion, our feasibility studies of diffusion in *in vivo* kidneys were met with mixed success. Though the scatter in our data is higher than desirable, reasonably consistent anisotropy was observed, and our results are similar to those of other investigators. Our diffusion coefficient values are only slightly higher than those for *ex vivo* excised dog kidneys, which is encouraging. The ADC values comparable to pure water suggest that solid tissue/cellular elements in the kidneys do not restrict water diffusion to the extent observed in other tissues, such as brain and muscle (4,19,24). However, observed

values that reach or, for some subjects, exceed pure water ADC values may be a consequence of bulk flow and bulk tissue motion, which may have influenced our measurements. Further investigation and refinement of technique is warranted to help clarify these matters and to determine if diffusion measurements are diagnostically useful for detecting or grading renal disease.

**Acknowledgments:** We wish to acknowledge and thank Dr. James Pipe, who wrote many of the software tools used for this project. We also wish to express our gratitude to our colleagues at General Electric Medical Systems for their support of our research efforts, and for the pulse sequence development tools that made this work possible.

#### References

1. Stejskal EO, Tanner JE. Spin diffusion measurements: spin-echoes in the presence of a time dependent field gradient. *J Chem Phys* 1965; 42:288-292.
2. LeBihan D, Breton E, Lallemand D, Grenier P, Cabanis E, Laval-Jeantet M. MR imaging of intravoxel incoherent motions: applications to diffusion and perfusion in neurologic disorders. *Radiology* 1986; 151:401-407.
3. LeBihan D, Breton E, Lallemand D, Aubin ML, Vignaud J, Laval-Jeantet M. Separation of diffusion and perfusion in intravoxel incoherent motion MR imaging. *Radiology* 1988; 168:497-505.
4. Chenevert TL, Brunberg JA, Pipe JG. Anisotropic diffusion in human white matter: demonstration with MR techniques *in vivo*. *Radiology* 1990; 177:401-405.
5. Chenevert TL, Pipe JG. Effect of bulk tissue motion on quantitative perfusion and diffusion magnetic resonance imaging. *Magn Reson Med* 1991; 19:261-265.
6. Merboldt KD, Hancicke ML, Gyngell J, Frahm J, Bruhn H. The influence of flow and motion in MRI of diffusion using a modified CE-FAST sequence. *Magn Reson Med* 1989; 12:198-208.
7. Prasad PV, Nalcioğlu O. A modified pulse sequence for *in vivo* diffusion imaging with reduced motion artifacts. *Magn Reson Med* 1991; 18:116-131.
8. Müller MF, Prasad PV, Pearlman JD, Braun R, Edelman RR. Echo planar diffusion mapping of the human kidney in states of dehydration and hydration (abstr). In: Proceedings of the Society of Magnetic Resonance in Medicine 1993; 1:49.
9. LeBihan D, Turner R, Moonen CTW, Pekar J. Imaging of diffusion and microcirculation with gradient sensitization: design, strategy, and significance. *J Magn Reson Imaging* 1991; 1:7-28.
10. Basser PJ, Mattiello J, LeBihan D. Diagonal and off-diagonal components of the self-diffusion tensor: their relation to and estimation from the NMR spin-echo signal (abstr). In: Proceedings of the Society of Magnetic Resonance in Medicine 1992; 1:1222.
11. Basser PJ, LeBihan D. Fiber orientation mapping in an anisotropic medium with NMR diffusion spectroscopy (abstr). In: Proceedings of the Society of Magnetic Resonance in Medicine 1992; 1:1221.
12. Moseley ME, Kucharczyk J, Mintorovitch J, et al. Diffusion-weighted MR imaging of acute stroke: correlation with T2-weighted and magnetic susceptibility-enhanced MR imaging in cats. *AJNR* 1990; 11:423-429.
13. Lorenz CH, Pickens DR III, Puffer DB, Price RR. Magnetic resonance diffusion/perfusion phantom experiments. *Magn Reson Med* 1991; 19:254-260.
14. Tsuruda JS, Chew WM, Moseley ME, Norman D. Diffusion-weighted MR imaging of the brain: value of differentiating between extraaxial cysts and epidermoid tumors. *AJNR* 1990; 11:925-931.
15. Chenevert TL, Brunberg JA, Pipe JG. Quantitative diffusion and anisotropy of human CNS lesions (abstr). In: Proceedings of the Society of Magnetic Resonance in Medicine 1992; 1:1008.
16. Müller MF, Prasad PV, Siewert B, Raptopoulos V, Nussenbaum MA, Lewis WD, Edelman RR. Abdominal diffusion mapping using a whole body echo planar system (abstr). In: Proceedings of the Society of Magnetic Resonance in Medicine 1993; 1:45.
17. Lorenz CH, Pickens DR, Puffer DB, Price RR. Society of Magnetic Resonance in Medicine Workshop on Diffusion and Microcirculation. Berkeley, CA: Society of Magnetic Resonance in Medicine 1990; 123-130.
18. Powers TA, Lorenz CH, Holburn GE, Price RR. Renal artery stenosis: *in vivo* perfusion MRI imaging. *Radiology* 1991; 178:543-548.
19. Cleveland GG, Chang DC, Hazlewood CF. Nuclear magnetic resonance measurement of skeletal muscle: anisotropy of the diffusion coefficient of the intracellular water. *Biophys J* 1976; 16:1043-1053.
20. Moonen CTW, de Vleeschouwer MHM, DesPres D, van Zijl PCM, Pekar J. Restricted and anisotropic displacement of water in healthy cat brain and in stroke by NMR diffusion imaging (abstr). In: Book of abstracts: Society of Magnetic Resonance in Medicine 1990; 1:121.
21. Pickens DR III, Jølgren DL, Lorenz CH, Creasy JL, Price RR. Magnetic resonance perfusion/diffusion imaging of the excised dog kidney. *Radiology* 1992; 27:287-292.
22. Merboldt KD, Bruhn H, Frahm J, Gyngell ML, Hancicke W, Deimling M. MRI of "diffusion" in the human brain: new results using a modified CE-FAST sequence. *Magn Reson Med* 1989; 9:423-429.
23. Moseley ME, Cohen Y, Kucharczyk J, et al. Diffusion-weighted MR imaging of anisotropic water diffusion in cat central nervous system. *Radiology* 1990; 176:439-446.
24. Müller MF, Prasad PV, Stewart B, Nissenbaum MA, Raptopoulos V, Edelman RR. Abdominal diffusion mapping with use of a whole-body echo-planar system. *Radiology* 1994; 190:475-478.