

A NOTE ON THE STRUCTURE OF THE ELASTICA INTERNA OF ARTERIES

G. CARL HUBER

Department of Anatomy, University of Michigan

ONE FIGURE

A comparison of a number of texts, descriptive of the structure of the elastic intima—the fenestrated membrane of Henle—of arteries, reveals the fact that the views concerning the structure of this layer are by no means unanimous. Schäfer¹ speaks of the elastic intima as follows: “The elastic tissue is represented by one distinct lamina, which is separated from the endothelium by the subendothelial layer. It is, on its outside, in direct contact with the non-striped muscle of the middle layer.” The ‘internal elastic lamina’ is spoken of as membranous in character, the membrane is not, however, a continuous one, but is perforated by apertures. In figure 517, of Schäfer’s text, is shown a portion of the fenestrated membrane from the femoral artery as figured by Henle. Mall² in his study of connective tissue fibrils states that “elastic fibers are composed of two distinct substances—the interior, which stains intensely with magenta, and the membrane, which does not.” A study of the membrane of Henle, isolated by boiling in acetic acid or KOH and then stained with magenta or picrocarmine leads him to conclude that “The Henle’s fenestrated membrane is therefore composed of three layers—an upper and a lower transparent membrane in which there are no openings, and which is identical with the membrane of elastic fibers; and a middle layer which stains with magenta, and is identical with the interior of elastic

¹ Schäfer, E. A. Text book of microscopic anatomy. Longmans, Green, and Co., 1912, p. 332.

² Mall, F. P. Reticulated tissue, and its relation to connective fibrils. Johns Hopkins Hospital Reports, vol. 1.

fibers. This central portion contains the openings." V. Ebner's³ description of the elastic intima concludes as follows, "Uebrigens erscheint dieselbe fast immer als eine sogenannte gefensterte Haut mit verschiedenen deutlich ausgeprägten, netzförmigen Fasern und meist kleinen länglichen Oeffnungen, seltener als ein wirkliches, aber sehr dichtes Netz vorzüglich langsverlaufender elastischer Fasern mit engen, länglichen Spalten, und stimmt in ihrem chemisches Verhalten vollkommen mit den elastischen Häuten der Media grosser Arterien überein." Triepel⁴ in his account of the elastic tissue in the walls of intracranial arteries considers the elastic intima as a fenestrated membrane, stating that in the smaller arteries the fenestra are so near together that only a felt-work of elastic fibers remains, so that in cross sections a row of adjacent points is observed instead of a membrane. His figure 4 shows this clearly. Schoppler,⁵ who studied the finer structure of the brain arteries of several mammals, gives especial consideration to the internal elastic membrane, and gives emphasis to closely arranged longitudinal ledges, which have a course parallel to the long axis of the vessels. He recognizes a fibrillar structure in the elastic intima as expressed in these words, "Vielfach zeigt sich auch, dass die Membrana flava interna keine homogene Platte ist, sondern wie die Betrachtung von Schrägschnitten bei 1000facher Vergrösserung lehrt, aus, sehr feinen elastischen Fäserchen besteht. Die erwähnten Leistchen werden durch Ausbildung stärkerer nach dem Lumen vorspringender Fasern bedingt." His figure 6, which shows an oblique longitudinal section of a basilar artery presents the fibrillar character of the elastic intima clearly. Dürck⁶ records observations made on connective tissues studied by means of Weigert's iron-hematoxylin myelin sheath staining method. In tissues fixed in formalin and Müller's fluid or in formalin,

³ v. Ebner, Victor, Kölliker's Handbuch der Gewebelehre des Menschen, Dritter Band, Zweite Hälfte. Engelmann, Leipzig, 1902, p. 643.

⁴ Triepel, H. Das elastische Gewebe in der Wand der Arterien der Schädelhöhle. Anat. Hefte, vol. 7, 1897.

⁵ Schöppler, H. Ueber die feinere Structure der Hirnarterien einiger Säugtiere. Anat. Hefte, vol. 15, 1900.

⁶ Dürck, H. Ueber eine neue Art von Fasern im Bindegewebe und in der Blutgefässwand. Virchow's Archiv, vol. 189, 1907.

mordanted in a copper salt and stained in iron-hematoxylin, following the Weigert method for staining myelin sheaths, certain connective tissue fibrils were stained blue-black. Certain of these differentially stained fibrils were regarded by Dürck as a special type of connective tissue fibrils, others, as yellow elastic fibers. This method as used by this observer, gave, in successful preparations, unusually distinct staining of the elastic intima of vessels. His words read as follows, "Untersucht man zunächst kleine Arterien auf dem Längsschnitt oder auf Schrägschnitten, welche das Rohr in langer Ausdehnung treffen, so erkennt man an den durch die Intima fallenden Schnitten, dass die *Elastica interna* hier nicht durch zirkuläre Fasern, Faserbündel oder Lamellen dargestellt wird, wie man dies gewöhnlich abgebildet und beschrieben findet, sondern unmittelbar über dem Endothelrohr liegt wie eine Basthülle unter einer Baumrinde eine einfache Schicht von straffen Längsfasern, welche unter sich allerdings durch kurze quere Zwiechenstücke verbunden sind und so ein Netz mit sehr langgestreckten und längs verlaufenden Maschen darstellen." In cross-sections such fibers appear as points.

The method used in staining the sections on which this study was based and from one of which the figure accompanying this note was drawn, was presented by Dr. De Witt⁷ at the Wisconsin meeting of the American Association of Anatomists in 1907. This differential elastic tissue staining method consists of a modification of Weigert's⁸ iron-hematoxylin van Gieson method. According to Weigert's method two stock solutions are prepared.

Solution I

Hematoxylin crystals.....	1 gram
Alcohol, 96 per cent.....	100 cc.

Solution II

Liquor ferri sesquichlorati (U. S. P.).....	cc. 40
Hydrochloric acid (sp. gr. 1.20).....	7
Aqua dist.....	959

⁷ DeWitt, Lydia M. Abstracts of papers presented at the 22nd Session Amer. Ass. Anat. Anat. Record, vol. 1, p. 74.

⁸ Weigert, K. Eine kleine Verbesserung der Hämatoxylin-van Gieson-Methode. Zeitsch. f. wissensch. Mik., vol. 21, 1904.

Solutions I and II are mixed in equal proportions just before using. Differentiation is obtained by means of van Gieson's picric acid fuchsin solution, prepared after Weigert as follows:

Picric acid, saturated aqueous solution.....	<i>cc.</i> 100
Acid Fuchsin (Weigert), 1 per cent aq. sol.....	10

In the method as used for elastic tissue staining, stock solutions I and II are mixed in proportion of 3 to 4 parts of solution I to one part of solution II. The sections are stained several hours and after rinsing in distilled water differentiated in van Gieson's picric acid, acid fuchsin solution, prepared as above indicated. The differentiation is controlled from time to time under the microscope. The method is simple and can be used on celloidin sections or paraffin sections fixed to the slide. The yellow elastic fibers are stained blue-black, the collagenous tissue is stained brick-red to pink, depending on the degree of differentiation and the thickness of the sections. The method is not unlike that used by Dürck, although the differentiation by means of the van Gieson picric acid, acid fuchsin solution has the advantage of counterstaining the collagenous tissue. This differential elastic tissue staining method has been extensively used in the preparation of sections for classes and is recommended as simpler than other differential elastic tissue stains.

Numerous sections of arteries varying in size from arterioles with two or three layers of muscle cells to arteries of about 2.5 mm. in diameter, cut in pieces of tissue fixed in formalin, formalin and Müller's fluid, and picro-nitric solution, embedded in paraffin, and sections fixed to slides, were stained after the above mentioned iron-hematoxylin and picric acid, acid fuchsin method. The differentiation in picric acid, acid fuchsin was carried in most sections to an extreme degree, so that only the yellow elastic tissue retained any of the blue-black coloring. Usually four to six sections were fixed to one slide, the sections approximating 5μ in thickness. They were cut on the sliding microtome, thus varied a little in thickness and gave slightly varying degrees of differentiation. The larger and largest arteries were, owing to want of suitable material, not included in this special

study, though previous incidental study of such vessels leads me to believe that the elastic intima, where present as such, is in general character like that of the smaller vessels. In no instance were the arteries especially studied removed from the surrounding connective tissue, so that the staining of the elastic tissue in the perivascular areolar tissue served as a control for the staining of the elastic tissue in the arterial walls.

In all of the successfully stained preparations and in arteries varying in size from the smaller to the larger ones studied, the elastic intima appears, when successfully differentiated, as a

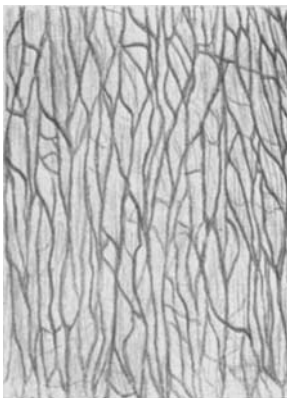


Fig. 1 Elastic intima of deep plantar artery, human. Stained in iron-hematoxylin and van Gieson's acid fuchsin, picric acid solution. $\times 600$.

network of elastic fibers, the larger fibers of the network having in the main a direction which is parallel to the long axis of the respective vessel. A well stained and well differentiated longitudinal or longitudinal oblique section of an artery including the elastic intima, appears not unlike a successfully teased preparation of yellow elastic tissue from the ligamentum nuchae.

In figure 1 is presented a drawing of a portion of the elastic intima of one of the larger deep plantar arteries of a human foot. During fixation the artery had collapsed in such a way that on one side, for a distance, its wall was nearly in a plane. Several sections of a series thus included long stretches of the elastic intima. In this figure only the elastic tissue, which is

stained deeply blue-black, is reproduced as drawn with the aid of the camera lucida, using a $\frac{1}{12}$ inch oil immersion objective and a No. 4 Zeiss compensation ocular with paper at table level. The network character of the coarser elastic fibers with frequent anastomoses and numerous cross-bridges is faithfully reproduced. It was not possible to draw accurately all of the finest fibrils throughout their entire extent. However, the figure as a whole gives a correct impression of the appearance presented by the section. At both ends (above and below the figure), the intima leaves the plane of section and the elastic fibers, shown as a network in the figure, appear as cross cut or obliquely cut fibers. In numerous other sections of vessels of varying sizes, longitudinally or obliquely cut, including the elastic intima, similar appearances are found. The character of the network varies but slightly, dependent on the degree of extension or distension of the respective vessel. Oblique sections approaching cross sections of vessels are especially instructive. In such sections a side view of the elastic network of the elastic intima with end view of the fibers as seen in cross-cut, is obtained by moving the micrometer screw of the microscope. In cross sections of vessels, in place of the usual line representing the elastic intima as seen after the usual staining, there is observed a row of deeply stained blue-black dots, varying in size with the size of the vessel, with here and there a longer or shorter blue-black dash where a cross anastomosis between fibers is included in the section.

Sections of areolar connective tissue, differentially stained for elastic tissue by means of the iron hematoxylin picric acid, acid fuchsin method, present no evidence of an 'outer membrane' for elastic fibers as described by Mall. However, the existence of such a membrane is in no sense denied, since a slight tinging with picric acid would not be evident against the deep blue-black stain of what is probably the 'inner substance,' stained readily in magenta. In certain of the longitudinal sections of vessels including the elastic intima, as for instance in the section from which the figure here presented was drawn, a delicate grey-blue color overlies the elastic network. This is represented in the figure by a light wash of neutral tint. If

this be expressive of structure it reveals a homogeneous structure and may possibly indicate the presence of a homogeneous membrane. Such a membrane, however, I have not detected in cross sections of vessels.

From this study of the elastic intima of arteries the conclusion seems warranted that the stainable substance of this layer consists of a network of yellow elastic fibers, with coarser fibers having in the main a course which is parallel to the long axis of the respective vessel, these fibers presenting frequent anastomoses and cross bridges, and with numerous finer fibrils which pervade the network. Here and there certain of the fibers of the elastic intima may in cross or oblique sections be traced in anastomosis with elastic fibers of the media. It would thus appear desirable to discard the term 'fenestrated membrane,' since this term does not express the structure of this layer. Of previous descriptions, that given by Dürck appears to me the most nearly conforming with observed facts.