

THE NERVUS TERMINALIS IN THE ADULT DOG AND CAT

ROLLO E. McCOTTER

The Anatomical Laboratory, University of Michigan, Ann Arbor

FOUR FIGURES

In a previous communication the writer ('12) has shown the presence in mammals of two distinct groups of nerve fibers in the olfactory region which terminate in separate ganglionic masses on the surface of the olfactory bulb. These are the common olfactory fibers arising from the olfactory mucosa, and the vomeronasal nerves arising in the vomeronasal organ (Jacobson's organ). The former ramify in the glomeruli of the olfactory formation and the latter terminate in similar structures in the accessory olfactory bulb, or, as we might better designate it, the vomeronasal formation. In the same paper it was suggested that we might have to add to these a third group, the nervus terminalis which apparently differs essentially from the previous two groups. It was also mentioned that, judging from the dissections of adult dogs, it might be possible to demonstrate all three of these nerve groups in that animal. Since that time, as will be reported in the present paper, the writer has succeeded in clearly demonstrating in both the adult dog and cat the existence of a slender ganglionated nerve which in its position and character corresponds completely with the nervus terminalis as described by previous authors in lower forms. In other mammals it is either extremely small or is absent. The writer made a careful search for it in the opossum, rat, rabbit, guinea-pig and sheep and did not succeed in finding it.

Before describing the details of the connections of these nerves it may be well to remind the reader that the nervus terminalis was first described in 1894 by Pinkus who found it in Protop-

terus. Since that time it has attracted the attention of a large number of observers, among whom may be mentioned Locy ('05), Brookover ('08 '10), Sheldon ('09) and Brookover and Jackson ('11) with the result that the nerve has been described for nearly all groups of fishes. The presence of the *nervus terminalis* in Amphibia was studied by Herrick ('09) for the frog and by McKibben ('11) for Urodela. At the last meeting of the American Association of Anatomists at Cleveland, Johnston ('13) demonstrated reconstructions of pig embryos showing the presence there of a *nervus terminalis* which is connected peripherally with the vomeronasal nerves. He also reported having seen the same nerve in human and turtle embryos. For a complete history of the *nervus terminalis* the above references should be consulted.

My own observations are based in the first place upon six gross dissections of the adult dog and three of the cat; in the second place on the microscopical studies of these fibers after their removal; and thirdly on serial sections prepared to show the median wall of this part of the brain together with the coverings and the contained nerves.

In the preparation of the specimens for the purposes of dissection the same methods were used as previously described by the author ('12) for the identification of the vomeronasal apparatus. This method consists of dividing the head to one side of the mid-sagittal plane and immersing the larger part from twenty-four to forty-eight hours in Müller's fluid to which has been added 5 per cent glacial acetic acid. The nerves are then found to be toughened and differentiated in color, thereby facilitating their identification. The dissection was done under water with the aid of a binocular microscope. The first step in the procedure consists in the careful removal of the *falx cerebri* and the identification of the vomeronasal nerves which are then followed to the caudal border of the olfactory bulb where the *nervus terminalis* may be seen associated with it. Then the course of this nerve can be easily traced caudalward. The microscopical study of the dissected nerves was made by dividing the vomeronasal nerves at the dorsal border of the vomeronasal organ and at their entrance to the vomeronasal formation of the olfactory

bulb. The nervus terminalis was likewise divided where it entered the brain wall. These nerves were then removed from the specimen in one mass and stained in Van Gieson's hematoxylin-picro-fuchsin stain. Figures 3 and 4 represent drawings made from favorable portions of such a preparation. The serial sections used for this study consisted of a transverse series made from the medial half of the olfactory bulb and peduncle of the dog. The sections were stained in hematoxylin and congo red.

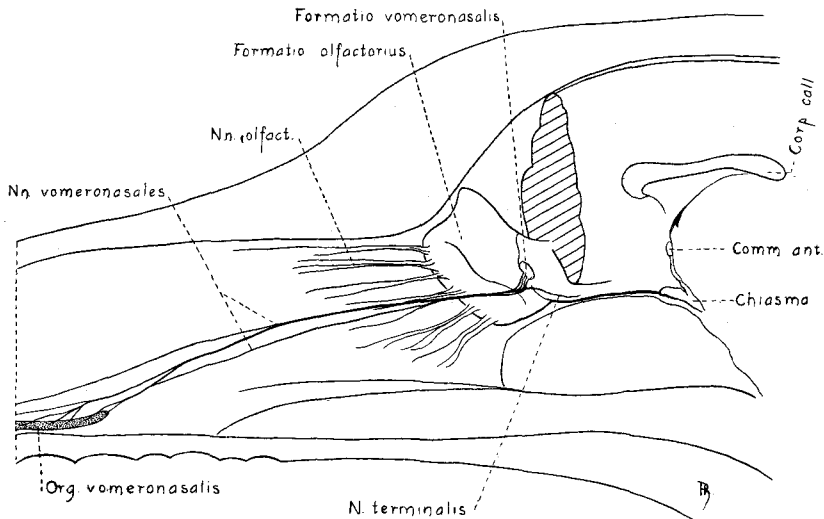


Fig. 1 A median section of the head of a dog with the frontal lobe of the brain, the nasal septum and the mandible removed, showing the course and termination of the nervus terminalis and its connection with the vomeronasal nerves. Natural size.

The relation of these structures as seen in the dissections of the dog are shown in figure 1. The vomeronasal nerves upon passing through the cribriform plate course almost horizontally across the narrow medial aspect of the olfactory bulb to its caudal border where they break up in a fine plexus and turn lateralward upon the dorsal aspect of the olfactory bulb. Connected with this plexus are several small bundles that usually unite into a single trunk which extends caudoventralward on the

medial surface of the olfactory peduncle where it appears to enter the brain substance some distance from the olfactory bulb. In one specimen, however, instead of entering the brain wall on the medial surface of the olfactory peduncle the nerve passed across this surface and apparently entered on the ventral surface of the peduncle. A few small filaments which seem to be connected with the olfactory nerves join the *nervus terminalis* just after its separation from the vomeronasal nerves.

Upon microscopical examination of the specimen of the vomeronasal nerves and the *nervus terminalis*, stained in mass, there were observed large oval, fusiform and cone-shaped nerve cells with granular cytoplasm and large spherical nuclei with prominent nucleoli. These cells were present in considerable numbers and were found either grouped around the nerve or embedded between its fibers causing a fusiform enlargement of the *nervus terminalis* immediately after its fibers have separated from the vomeronasal nerves.

The examination of the transverse sections of the olfactory bulb of the dog confirmed the above mentioned observations. The vomeronasal nerves were easily recognized and followed to the vomeronasal formation. The filaments of the *nervus terminalis* can be seen separating from the vomeronasal nerves. A group of ganglion cells enclosed in a capsule and attached to the combined filaments was followed through eight consecutive sections. In this particular series, the filaments having been slightly torn in the preparation of the block, the nerve could not be traced into the brain substance.

The vomeronasal nerves of the cat (fig. 2) course upward and backward in three separate bundles on the medial surface of the olfactory bulb to the caudal border of this surface where they unite into a loose plexus and turn outward to end in the vomeronasal formation. Several small filaments separate from the above mentioned plexus and unite into a single strand which courses caudalward on the medial surface of the olfactory peduncle where it apparently enters the brain substance in the region of the arcuate fissure. The *nervus terminalis* gradually decreases in size from its connection with the vomeronasal nerves to its termination

in the brain cortex. This is due to three or four small filaments that leave the nerve at intervals and apparently enter the brain substance at different points along the course of the nerve.

Upon microscopical examination of the vomeronasal nerves and the nervus terminalis, which were dissected off and stained in mass, there can be seen a small spindle-shaped ganglion composed of about 200 cells causing an enlargement of the nerve shortly after its fibers have separated from the vomeronasal nerves.

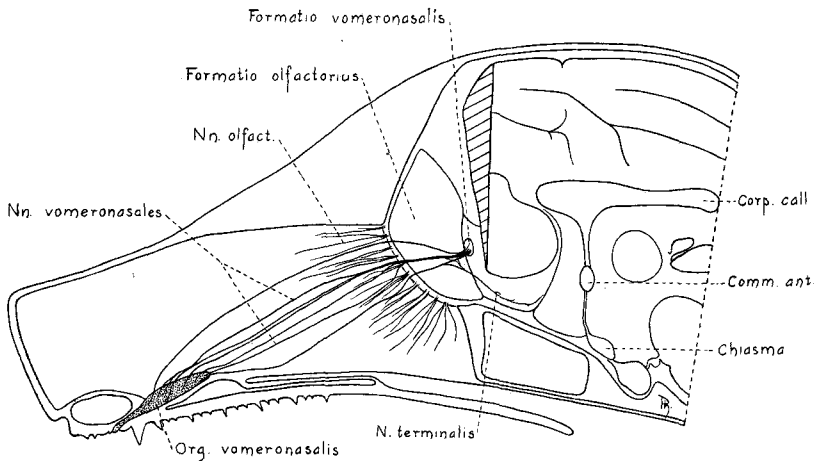


Fig. 2 Represents the median section of the head of a cat with the frontal lobe of the brain, the nasal septum and mandible removed, showing the course and termination of the nervus terminalis and its connection with the vomeronasal nerves. $\times 1\frac{1}{2}$.

Ganglion cells are scattered around the nerve and between its fibers throughout the greater part of its course. Figure 3 represents a camera lucida drawing of a part of the nervus terminalis proximal to the ganglion showing the distribution of these cells. On a careful examination of the septal portion of the vomeronasal nerves within the nasal cavity a clump of nerve cells was found on each of two of its seven filaments. They lie at the side of the nerve and attached to it just dorsal to the vomeronasal organ. These ganglion cells cannot be the cell bodies of the vomeronasal nerve filaments because it has long been known

that the vomeronasal nerves are the axis cylinder processes of the sense cells of the mucosa of the vomeronasal organ and arise in the same manner as the olfactory nerve filaments from the sense cells of the olfactory mucosa. It is quite evident, therefore, that these clumps of ganglion cells belong to the nervus

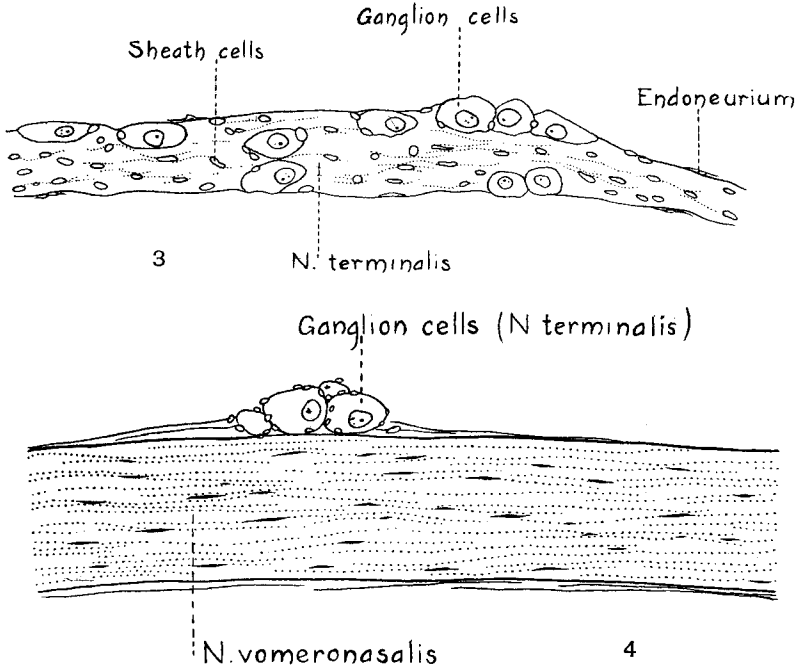


Fig. 3 A camera lucida drawing of a favorable portion of the nervus terminalis of the cat proximal to its ganglion to show the characteristic distribution of the nerve cells. $\times 200$.

Fig. 4 A camera lucida drawing of one of the filaments of the vomeronasal nerves of the cat, taken not far from its origin from the vomeronasal organ. The clump of ganglion cells attached to it indicates that fibers of the nervus terminalis extend into this region. $\times 200$.

terminalis, the filaments of which extend into the nasal cavity along with several filaments of the vomeronasal nerves and apparently terminate within or very close to the vomeronasal organ.

From the foregoing description it is evident that there is normally present in the adult dog and cat a ganglionated nerve

connected with the vomeronasal nerves on the one hand and apparently with the forebrain on the other, having thereby the same morphological relations in these mammals as is described for the nervus terminalis of lower forms. Therefore we believe that we are justified in considering this nerve the nervus terminalis.

In conclusion it may not be out of place to add a word regarding the terminology of this region. One source of confusion in terminology is the use of terms applicable to surface appearances but not applicable to the same structures as they appear in sections made through them. It is still worse when the term used applies to the appearances in some animals but not in others. Manifestly the ideal terminology should express, as far as possible, the function and connections of the parts concerned. Unfortunately, however, in some cases we have to apply a terminology before the function and even the connections are known. In the region we have been considering the terms olfactory bulb and olfactory stalk are widely accepted and have been found very convenient in the description of the surface anatomy of these parts. In a previous paper it was suggested in a tentative way that we call the accessory olfactory bulb the 'vomeronasal tubercle.' It is true that it forms an elevation on the olfactory bulb of mammals, but in many of the lower forms (reptiles), however, it is described as a pit or fossa. It therefore seems feasible to substitute the term 'formatio vomeronasalis.' This term is consistent with 'formatio olfactoria,' the receptive ganglion of the ordinary olfactory nerves, which is in common use. Then if we apply the term 'olfactory bulb' in its true sense to include the entire bulbous enlargement of the olfactory evagination, it will be found composed of four separate and distinct parts: (1) the formatio olfactoria where the ordinary olfactory fibers terminate; (2) the formatio vomeronasalis which is the receptive center for the vomeronasal nerves; (3) the pars bulbaris of the lateral olfactory cortex which is to a greater or less extent covered in and attenuated by divisions 1 and 2, and which includes also, the over-lying layer of olfactory tract fibers as well as the deeply placed layer of the pars olfactoria of the anterior commissure;

(4) the ventricle of the bulb with its lining ependyma. Based upon the classification given by Kölliker, each of the subdivisions of the olfactory bulb is then composed of the following laminae:

Bulbus olfactorius	}	(1) <i>Formatio olfactoria</i>
		(A) <i>Fila olfactoria</i>
		(B) <i>Stratum glomerulorum</i>
		(C) <i>Stratum griseum</i>
		(a) <i>Stratum moleculare</i>
		(b) <i>Stratum mitrale</i>
		(D) <i>Stratum granulare</i>
		(2) <i>Formatio vomeronasalis</i>
		(A) <i>Fila vomeronasales</i>
		(B) <i>Stratum glomerulorum</i>
		(C) <i>Stratum griseum</i>
		(a) <i>Stratum moleculare (including mitral cells)</i>
		(3) <i>Cortex olfactorius lateralis, pars bulbaris</i>
		(A) <i>Stratum plexiforme (including tract. olf. lat.)</i>
		(B) <i>Stratum pyramidale</i>
		(C) <i>Stratum fibrosum (including comm. ant., pars olfact.)</i>
(4) <i>Ependyma and Ventriculus bulbi</i>		

LITERATURE CITED

- BROOKOVER, C. 1908 Pinkus' nerve in *Amia* and *Lepidosteus*. *Science, N. S.*, vol. 27, p. 913.
 1910 The olfactory nerve, the nervus terminalis and the preoptic sympathetic system in *Amia calva* L. *Jour. Comp. Neur.*, vol. 20, pp. 49-118.
- BROOKOVER, C., AND JACKSON, T. S. 1911 The olfactory nerve and the nervus terminalis of *Ameiurus*. *Jour. Comp. Neur.*, vol. 21, pp. 237-259.
- HERRICK, C. JUDSON 1909 The nervus terminalis (nerve of Pinkus) in the frog. *Jour. Comp. Neur.*, vol. 19, pp. 175-190.
- JOHNSTON, J. B. 1913 Nervus terminalis in reptiles and mammals. *Jour. Comp. Neur.*, vol. 23, No. 2.
- KÖLLIKER, A. *Gewebelehre*, 6 Auf., Bd. 2, p. 693.
- LOCY, W. A. 1905 On a newly recognized nerve connected with the forebrain of selachians. *Anat. Anz.*, Bd. 26, pp. 111-123.
- McCOTTER, ROLLO E. 1912 The connection of the vomeronasal nerves with the accessory olfactory bulb in the opossum and other mammals. *Anat. Rec.*, vol. 6, pp. 299-328.
- McKIBBEN, PAUL S. 1911 The nervus terminalis in urodele Amphibia. *Jour. Comp. Neur.*, vol. 21, pp. 262-309.
- PINKUS, FELIX 1894 Ueber einen noch nicht beschriebenen Hirnnerven des *Protopterus annectens*. *Anat. Anz.*, Bd. 9, S. 562-566.