

# THE DEVELOPMENT OF THE ALBINO RAT, MUS NORVEGICUS ALBINUS

## II. ABNORMAL OVA; END OF THE FIRST TO THE END OF THE NINTH DAY

G. CARL HUBER

*From the Department of Anatomy, University of Michigan, and the Division of  
Embryology, Wistar Institute of Anatomy and Biology, Philadelphia*

TEN FIGURES

### CONTENTS

Introduction.....	359
Half embryos in Mammalia.....	361
Degeneration of ova at the end of segmentation.....	364
Incomplete or retarded segmentation.....	365
Abnormal segmentation cavity formation.....	370
Degeneration of ova as a result of pathologic mucosa.....	373
Imperfect development of ectodermal vesicle.....	376
Two egg-cylinders in one decidual crypt.....	382
Conclusions.....	384
Literature cited.....	386

### INTRODUCTION

In the course of my study of the normal development of the albino rat, from the end of the first to the end of the ninth day after insemination, as recorded in Part I of this series of contributions, there were encountered from time to time ova which appeared to deviate both in rate and type of development from what, as a result of extended study, came to be regarded as the normal developmental cycle of the albino rat. When taken collectively, the number of these abnormal ova is not large, although they embrace nearly all of the developmental stages studied. When taken singly, it may be stated that while it is comparatively easy to record the points of deviation from the normal, it must be admitted that the probable fate of the respective stages can only be conjectured. Nevertheless, a record of

the abnormal stages met with seems warranted, especially in view of the fact that the literature is very meager in its account of early stages of mammalian ova presenting abnormal development.

The excellent and comprehensive studies of Mall on pathologic human ova, extending over many years, may be interpreted as leading to the general conclusion that pathologic ova and monsters "are produced from normal eggs by conditions which either interfere with their nutrition or poison them." There is evidence to show that defective implantation, using the term in its broadest sense so as to include relation to the embryotroph or pabulum, is directly associated with abnormal development. Comparative experimental teratology so successfully followed by a number of European and American experimental embryologists warrants the conclusion that all of the abnormalities or malformations observed in the human embryo may be brought forth by the application of suitable mechanical interference or chemical solutions. Experimental teratology possesses the very great advantage of enabling the observer to follow the pathologic process from step to step, admitting more readily of their interpretation, than when single stages are obtained from nature. The evidence appears to be accumulating that the primary causes which produce pathologic ova lie not in the germ cells, but are rather to be sought in the environs of the germ cells in the course of their development.

I am cognizant of the fact that the interpretation of the chance findings of abnormal stages of mammalian ova is much more difficult than of abnormal ova produced experimentally. The fact, however, that nearly all of the abnormal ova observed by me in my albino rat material were found in tubes and uteri containing normal ova also, tubes and uteri which so far as observable appear in most instances to be normal, and the further fact that certain of the abnormal ova are of stages prior to what may be regarded as showing implantation, stages concerning which we possess no data as far as human ova are concerned, has led to the tentative conclusion that certain of the abnormal ova may be the resultant of abnormal germ cells, perhaps of an abnormality which may not show a structural expression.

It is my primary purpose to make records of the abnormal ova observed in the material at hand; and to follow these records with a brief consideration of the observations made. There is no literature dealing with the problem immediately at hand—abnormal rat ova. It is not my purpose at this time to enter into the extensive literature of comparative experimental teratology. This has been critically summarized relatively recently by O. and R. Hertwig, and by Mall, in his several contributions dealing with human pathologic ova.

#### HALF EMBRYOS IN MAMMALIA

The first preparation to which attention is called is one taken from the oviduct of rat No. 60, 1 day, 18 hours, after insemination. The two oviducts of this rat contained seven ova in the 2-cell stage, to one of which especial attention was drawn in Part I (page 271). As there recorded, in one of the 2-cell stages, the first two blastomeres were separated by an appreciable distance. There is loss of oolemma. The possibility of half embryos in Mammalia was suggested. The preparation under consideration is figured in figure 1, A and B. In A of this figure there is presented a portion of the wall of the oviduct, its epithelial lining and the immediately adjacent mucosa, including the fourth of a series of six sections ( $10\ \mu$ ) passing through the two blastomeres. In this region, the cilia of the epithelium are clearly observable, as may be seen from the figure. In B of this figure there are sketched in approximately relative position the several sections of the series passing through the two blastomeres, the relative position of which, with reference to the walls of the tube, is shown in A of the figure. The six drawings were made from a well ribboned series; the slide was moved from section to section by means of a mechanical stage, and the perpendicular indicated on each drawing as made. The relative position of the several drawings, therefore, is quite correct. It may be observed that throughout the series the two blastomeres are separated by an appreciable space, and that one of the cells has rotated slightly on its axis. If these two blastomeres had remained in close apposition, they would present the appearance of a normal 2-cell stage

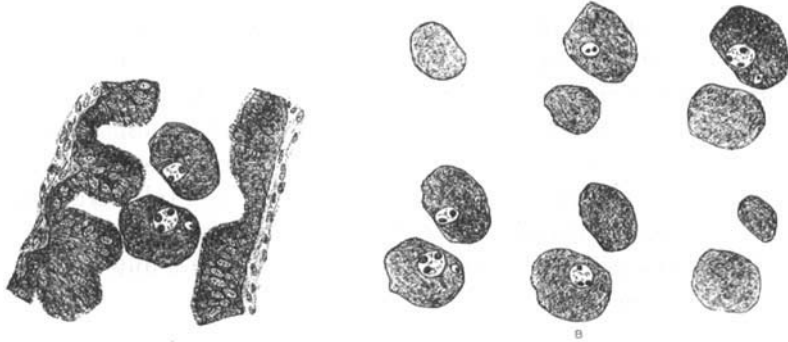


Fig 1 Oviduct and ovum of albino rat, in 2-cell stage, with first two blastomeres separated. Rat No. 60, 1 day, 18 hours, after the beginning of insemination.  $\times 200$ . A, epithelial wall of oviduct with adjacent mucosa, and the fourth of a series of six sections of the 2-cell stage with separated blastomeres, showing them in their relation to the epithelium. B, the series of six sections which pass through the separated blastomeres, the fourth of which is shown in A. The series reads from right to left.

as shown in B and C of figure 1, Part I. There is here clearly a separation of the first two blastomeres and not a close approximation of two unfertilized ova. In all of the unfertilized ova met with in the oviducts in the series at my disposal, these present the second maturation spindle and oolemma and are not to be confused with the blastomeres of the 2-cell stage, either as to size or structure. Both of the blastomeres in the preparation under consideration present normal protoplasmic structure, having a finely granular protoplasm. Their nuclei, as may be seen from the figures, are of normal size and structure. They present regular form, are distinctly membranated, have large chromatoid nucleoli, and chromatin scattered in fine granules and threads. However, attention needs to be drawn to the presence of two micro-nuclei, one in each of the two blastomeres, showing in the third and fourth section of the series respectively (B, fig. 1). These micro-nuclei are nearly free from chromatin, each presenting a small chromatoid nucleolus. They are not to be regarded as cell inclusions, as perhaps representing phagocytic leucocytes. It may be conjectured that they were formed by amitotic division, by budding and constriction from the parent

nuclei, perhaps indicating altered metabolism in the two blastomeres. I am inclined to think that both of these cells would have degenerated in the course of further development; however, their fate can only be guessed and not predicted. The possibility of their developing into half embryos is suggested. Half embryos developing as a result of a separation of the first two blastomeres has not been observed in the Mammalia, and an experimental test of the question is for the present not a probability.

As a result of experimental embryology it has been clearly shown that through mechanical interference polysomatous monsters may be produced from normal ova. The first two blastomeres are totipotent as expressed by Driesch. Driesch was able to produce polysomatous forms by mechanical separation of the first two blastomeres in sea urchin eggs; Wilson, by separating through shaking of 2- and 4-cell stages in *Amphioxus*; O. Hertwig, Herlitzka and Spemann, by separating the first two cells in amphibian eggs; O. Schultze and others, by use of gravity and compression; and Loeb and others by use of chemical agents. By various means, then, when suitably applied and at the right time, hemiembrs have been produced by separating or potentially separating the first two blastomeres in certain forms. O. Hertwig states:

Bei den kleinen, mit geringen Mengen von Dotter ausgestatteten Eiern der Wirbeltiere sind spontan entstandene, das heisst, ohne experimentelle Eingriffe veranlasste Mehrfachbildungen ausserordentlich selten, bei manchen Klassen überhaupt noch nie beobachtet worden, dagegen sind sie relativ häufige Befunde bei manchen untersuchten Arten von Knochenfischen und Vögeln, besonders bei der Forelle und beim Hühnchen.

So far as I am aware, the possibility of hemiembrs in Mammalia has not been shown. In the albino rat, the oolemma may be lost as early as the 2-cell stage. In forms with early loss of oolemma, the separation of the two first blastomeres does not appear to me as an impossibility. The probable fate of separated mammalian blastomeres can only be conjectured, since it is manifestly impossible, for the present, to follow them in further development.

DEGENERATION AND DEATH OF OVA AT THE END OF  
THE SEGMENTATION STAGES

In figure 2, A and B, are presented drawings of typical sections of two morula masses showing complete degeneration and death. The degenerated ovum shown in A, of this figure was obtained from rat No. 52, 4 days, 15 hours, after insemination. In all, eight normal ova were found in the uterus of this rat,



Fig 2 Ova of the albino rat in late segmentation stages, showing death and dissolution of the constituent cells.  $\times 200$ . A, rat No. 52, 4 days, 15 hours, after the beginning of insemination. B, rat No. 68, 4 days, 16 hours, after the beginning of the insemination. This figure shows an imperfectly developed morula with probable retention of oolemma.

these showing late morula stages and stages of early blastodermic vesicle formation, three of which were sketched and are shown in A, B, and C of figure 20, Part I. The degenerated ovum here under consideration lies in very close proximity to the normal blastodermic vesicle shown in C of figure 20, Part I. The shallow mucosal pits harboring the two ova are in contiguity. The two contiguous pits resemble each other very much; the mucosa underlying them is in every respect the same, indicating, it would seem, that to a certain stage in development—to the end of segmentation—the development of the degenerated ovum proceeded normally. The degenerated egg-mass measured approximately  $80 \mu$  by  $50 \mu$  by  $40 \mu$ . In reaction to stains, it differs markedly from the adjacent normal vesicle. The staining is very pale; cell boundaries are indistinct or lost, and the nuclei scarcely retain any coloring matter. Scattered through the protoplasm are found small globular masses, perhaps of lipoid character. Protoplasm and nuclei present evidences of cytolysis and chromatolysis, and have the appearance presented by necrotic tissue. Had normal development supervened, both ova

(the pathologic and the adjacent normal one) would in all probability have been enclosed within the same decidual crypt, a condition exceedingly rare, judging from the material at hand. Whether the very close proximity of these two ova bears causal relation to the death of one, by reason of the consequent lessening of the available pabulum or embryotroph, can only be conjectured. There is at this stage no question of faulty implantation, the ova, though presumably permanently lodged, lie free in the lumen of the uterus. Whether on the other hand, the death of this ovum was the result of some inherent nutritional deficit must also remain unanswered. However, this preparation may serve to show that ova of the albino rat, after reaching the uterine tube, and after apparently normal segmentation, may undergo death and dissolution, for reasons which are not structurally discernable.

B of figure 2, rat No. 68, 4 days, 16 hours, after insemination, is from the uterus of a rat containing four ova in early stages of blastodermic vesicle formation, three of which were sketched under D and E of figure 20, and the series of figure 21, Part I. The preparation here described lies free in the lumen of the uterus, and appears to represent an uncompleted segmentation, with cells and nuclei showing cytolysis and chromatolysis. The mass is surrounded by a thin membrane regarded as an oolemma. Normally the oolemma of the segmenting ova of the albino rat is lost in the 4-cell stage, now and again in the 2-cell stage. Whether the retention of the oolemma may be brought in causal relation to the death and dissolution of the enclosed cells is problematic. That such causal relation may exist for the ova of the albino rat, appears to me as not impossible. This degenerated egg-mass presents the only instance of the late retention of the oolemma in the albino rat material at my disposal.

#### INCOMPLETE OR RETARDED SEGMENTATION

The blastodermic vesicles presented in figures 3 and 4 have been interpreted as showing incomplete or retarded division of certain of the cells of early stage morula masses. The probable fate of such blastodermic vesicles in further development cannot

be projected with any degree of certainty. The most characteristic vesicle showing this phenomenon is presented in figure 3, and is taken from rat No 53, 5 days after insemination, the uterus of which contained seven blastodermic vesicles showing early stages of development, four of which are reproduced in figure 22, Part I. In A and B of figure 3 are reproduced two consecutive sections of a series of five sections of  $10\ \mu$  thickness, including this ovum. In the lower part of this ovum there is found a small segmentation cavity, bounded by cells which present normal appearances. The roof of this vesicle is slightly

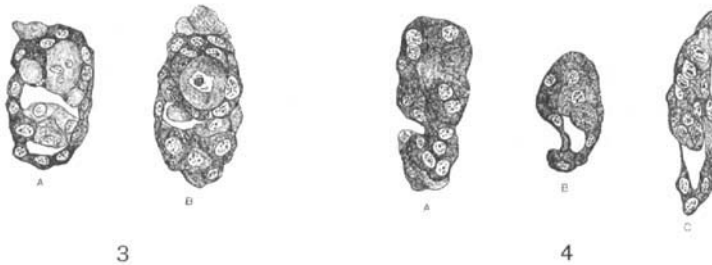


Fig. 3 Early stages of the blastodermic vesicle of the albino rat, presenting evidence of irregular or retarded segmentation.  $\times 200$ . Rat No. 53, 5 days after the beginning of insemination.

Fig. 4 Three ova of the albino rat, showing early blastodermic vesicle stages, in each of which certain of the cells suggest irregular or retarded segmentation.  $\times 200$ . A, rat No. 64, 4 days, 14 hours, after the beginning of insemination. B, rat No. 68, 4 days, 15 hours, after the beginning of insemination. C, rat No. 54, 6 days, 16 hours, after the beginning of insemination.

folded and compressed, as a consequence of which the roof wall in the sections figured is presented in part as seen in surface view. In the floor of this vesicle there is to be observed, surrounded by other smaller cells, one large cell, of nearly spherical shape, having a diameter which is three or four times as great as that of the majority of the surrounding cells. The protoplasm of this large cell stains less deeply than does that of the majority of the other cells constituting the floor of the vesicle. Its nucleus is relatively large and slightly lobulated, so much so that in the section of it shown in A of this figure, in the optical section sketched, the nucleus appears as three separate nuclei, in reality,



lobules of the same nucleus. In A of this figure there is shown to the lower left of the large cell another relatively large cell, enclosing a globular inclusion, which stained faintly, and the nature of which was not fully determined. In the upper part of each of the two figures are seen cells which show cytolysis and loss of nuclei; regarded as degenerating cells. When compared with the normal blastodermic vesicles obtained from the same uterus, the ovum here described presents a unique appearance, and was readily recognized as showing development and structure which deviated from the normal. At this stage of development, the blastodermic vesicles of the albino rat are still found lying free in the lumen of the uterus, showing no structural relation to the uterine mucosa. This vesicle has been interpreted as showing irregular or retarded segmentation. It is conjectured that one of the cells, perhaps of the 8-cell stage, did not undergo further cleavage. The large cell presents an appearance evidencing beginning stages of degeneration, and in further development, would probably have undergone dissolution. The majority of the smaller cells of the roof appear as if normal, as do also the cells of the floor, certain of the smaller cells of the floor presenting mitoses as evidence of further proliferation.

In figure 4, A, B, and C, there are presented typical sections of three ova of the albino rat showing what has been regarded as irregular segmentation. A of this figure represents an ovum taken from rat No. 64, 4 days, 14 hours, after insemination, in the uterus of which there were found five normal ova showing early stages of blastodermic vesicle formation, four of which are cut longitudinally, one in a series of cross-sections. In each of the four longitudinally cut series the floor of the respective vesicles is markedly folded, owing to fixation contractions; therefore, none were sketched as normal stages. In appearance, they resemble closely the vesicles sketched under C, D, and E of figure 20, Part I. In the pathologic ovum, shown in A of figure 4, there is no evidence of segmentation cavity formation. However, the ovum cannot be regarded as presenting a late morula stage such as is figured in A of figure 20, Part I, since it shows distinct departure from the normal. The marked constriction

seen to the lower left of the figure passes through the series of four  $10\ \mu$  sections including this ovum, and in part separates a portion composed of relatively small cells from a larger portion composed of larger cells. The rate of segmentation of certain of the cells composing the upper larger portion of this cell mass appears to have been retarded, thus retarding the development of the whole mass. This pathologic ovum rests normally in a shallow pit of the mucosa, very similar in form and structure to the shallow pit lodging the five normal vesicles found in this uterus.

The ovum shown in B of figure 4 was obtained from the uterus of rat No. 68, 4 days, 16 hours, after insemination. with four normal vesicles showing early stages of blastodermic vesicle formation. From this uterus was also taken the completely degenerated cell mass with persistent oolemma shown in B of figure 2. This vesicle on superficial observation does not appear to depart markedly from the normal appearance for this stage. In form and size it corresponds closely to the normal ova taken from this uterus. The segmentation cavity seems to have developed normally. The slight folding of the roof seen to the left of the figure is accidental, due to fixation shrinkage, and is very similar to folding of the roof to be observed in many of the normal preparations of the series. In the floor of the vesicle there may be observed three relatively large cells, partly enclosed by smaller cells of a size comparable to that of the cells forming the floor of the normal blastodermic vesicles of this stage of development. The three relatively large cells, clearly distinguished in the figure, are interpreted as showing a retarded segmentation. So far as may be determined, their protoplasm and nuclei present normal structure, the lowest of the three cells showing an early mitotic phase. I am inclined to the opinion that this ovum would have continued in development, perhaps in later stages showing distinct arrest in development. This hypothesis seems warranted on the basis of the study of a vesicle shown in C of figure 4, taken from rat No. 54, 6 days, 16 hours, after insemination. Normal stages for the albino rat, taken about the middle of the seventh day after insemination, are shown in figure

24, Part I. Reference to this figure may serve to show that during the early hours of the seventh day after insemination, the phenomenon of inversion or entypy of the germ layers is initiated in the albino rat. The ova are, on reaching this stage of development, enclosed within a well differentiated decidual crypt which communicates as yet freely with the lumen of the uterus. These crypts present a continuous lining of uterine epithelium; the contained ova are thus not as yet in direct relation with the maternal decidua. In the normal blastodermic vesicle of this stage, the ectoplacental cone is in anlage, and in the cell mass which extends into the cavity of the vesicle—the egg-plug or egg-cylinder—there is evident a clearly circumscribed nodule of cells, which has been designated the ectodermal node and recognized as the anlage of the primary embryonic ectoderm; this node is in part surrounded by the yolk entoderm. In the uterus of rat No. 54, there are contained nine blastodermic vesicles, one of which is sketched in C of figure 24, Part I. Not nearly all of these vesicles are so favorably cut as that shown in this figure, the majority being cut in a plane which is oblique to the long axis of the vesicle. However, in all of them the ectoplacental cone and the ectodermal node may be determined except in the one shown in C of figure 4. This vesicle was obtained from a series of sections passing at right angles to the plane of the mesometrium. It lies free in a deep decidual crypt and passes through six sections of 10  $\mu$  thickness; thus is compressed from side to side. This vesicle is distinctly smaller than the normal ones taken from this series, especially so as concerns its cavity. An ectoplacental cone is not clearly differentiated, and it is not possible to determine an ectodermal node, nor is it clear that the yolk entoderm has differentiated. In the cell mass from which ectoplacental cone and ectodermal node should have developed, the upper portion of this figure, there are evident, in the sections figured, four relatively large cells with relatively large nuclei, cells which have been interpreted as evidencing retarded segmentation with consequent retardation in the normal differentiation of the vesicle. On tracing this vesicle through the series of six sections it would seem that the direction of section is favor-

able. The uterine mucosa appears to have reacted normally; the decidual crypt in which this vesicle is lodged presenting normal size and form, and the surrounding decidua normal structure. The vesicle itself is retracted from the uterine epithelium, intact throughout the crypt, thus, does not appear to have attained the normal adhesions observed in normal vesicles of this stage. The four ova depicted in figures 3 and 4, appear to present a distinctive type of abnormal development, a type which is interpreted as showing retarded segmentation in certain of the cells of the 8-cell and perhaps 16-cell stage. All are found in

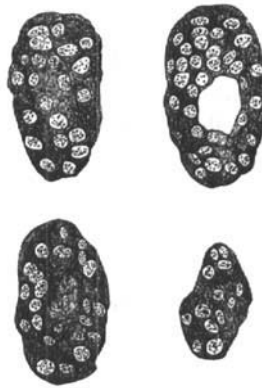

Fig. 5 Four consecutive sections of the ovum of the albino rat showing abnormal development of the segmentation cavity  $\times 200$ . Rat No. 46, 6 days, 14 hours, after insemination.

uteri containing normal stages. The appearances presented, if correctly interpreted, speak in favor of a structural or metabolic defect inherent in the cells themselves and not primarily dependent on environment, pabulum, or embryotroph.

#### ABNORMAL SEGMENTATION CAVITY FORMATION

The following three ova have been grouped as showing irregularity in the formation of the segmentation cavity.

In figure 5 are reproduced four consecutive sections passing through an abnormal ovum obtained from rat No. 46, 6 days, 14 hours, after insemination. There were obtained from the uterus

of this rat ten blastodermic vesicles, two of which are reproduced in A and B of figure 24, Part I, as showing typically early stages of the anlage of the ectoplacental cone and entypy of the germ layers. The ovum shown in figure 5 is found in a decidual crypt which is in very close proximity to the one containing the vesicle figured under B of figure 24, Part I, the two crypts being separated by a distance of approximately 1.3 mm., while the distance between decidual crypts is normally 1 cm. to 1.5 cm. The decidual crypt lodging the abnormal ovum presents a normal appearance, resembling very closely in form, depth and structure

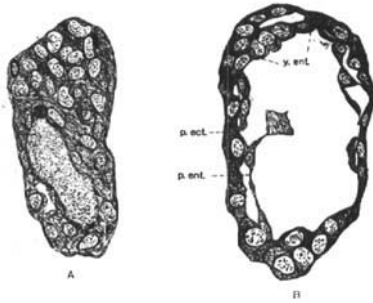


Fig. 6 Two ova of the albino rat, interpreted as evidencing retarded or irregular formation of the segmentation cavity.  $\times 200$ . A, rat No. 90, 6 days, 17 hours, after the beginning of insemination. B, rat No. 90, 6 days, 17 hours, after the beginning of insemination. *p.ect.*, parietal or transitory ectoderm; *y.ent.*, yolk entoderm; *p.ent.*, parietal entoderm.

of the surrounding decidua, the crypt and decidua enclosing the adjacent normal vesicle figured in B of figure 24, Part I. The abnormal ovum in question appeared to have proceeded normally in segmentation, its constituent cells being of about the size and structure of the cells of normal vesicles taken the early part of the seventh day after insemination. The cell-mass encloses a relatively small cavity which may be regarded as an abnormally placed segmentation cavity, in that its position is not eccentric, and that it is surrounded on all sides by more than one layer of cells. There is thus no differentiation of floor and roof as in normal blastodermic vesicles, and no development of ectoplacental cone and egg-cylinder as in the other ova obtained from

this uterus. I am for the present unable to offer any plausible explanation or give reasons for such abnormal development of the segmentation cavity. The fate of such a structure may perhaps be conjectured from a study of the abnormal ovum shown in A of figure 6, interpreted as showing a similar abnormality, but obtained in early stages of degeneration. This ovum and that shown in B of the same figure was obtained from the uterus of rat No. 90, 6 days, 17 hours, after insemination. In the uterus of this rat there are found six ova, only one of which was developed to a stage comparable to that shown in figure 24 (Part I) of about the same age. Three other vesicles present a slightly younger stage and may be compared with vesicles shown in D and E of figure 23, Part I. None of these four vesicles is favorably cut, but so far as may be determined, are of normal structure for the respective stages represented. A of figure 6 is also cut slightly obliquely, not sufficiently so, however, to make difficult its interpretation. The figure drawn is that of the third of a series of seven sections having  $10\ \mu$  thickness, and depicts what is regarded as representing an ovum with abnormal segmentation cavity formation. In this ovum, the segmentation cavity is slightly more eccentric than is that shown in figure 5, and contains a granular detritus which in the preparations is distinctly stained with Congo red. The roof of this vesicle is composed almost throughout of more than one layer of cells. There is no differentiation of ectoplacental cone and ectodermal node, nor of yolk entoderm. Two cells regarded as phagocytic leucocytes, staining much more deeply in Congo red than do the cells of the ovum, have, in the section figured, penetrated the egg-mass, indicating early degenerative changes.

The vesicle shown in B of figure 6, obtained from the same rat, is favorably cut, and is readily followed through the series. The structural appearance presented by this vesicle is not explained by supposing it due to very oblique plane of section of a normal vesicle, a plane of section which might include the roof of the vesicle while avoiding its floor. The vesicle is abnormal in that it presents a want of development of the thickened germ disc, and a hyperdevelopment of the yolk entoderm. In none of the

sections of the series which includes this vesicle, which is cut in very favorable longitudinal direction, and is thus readily oriented with reference to mesometrial and antimesometrial portion, is there seen any thickening of the outer layer of cells, to form the part known as the floor of the vesicle, which at this stage of development is uniformly directed toward the mesometrial border. In A and B of figure 23, Part I, are shown vesicles with which the ovum here discussed may be compared. In the preparation under discussion, the yolk and parietal entoderm form almost a continuous layer, one of the detached cells showing a mitotic phase. In the normal vesicles of this stage of development the parietal entoderm is represented by a few scattered cells, as may be observed by a study of the figures to which reference is above made. Whether this vesicle is to be regarded as showing a later stage of an ovum in which there was irregularity in the formation of the segmentation cavity, I must for the present, leave as problematic. It has occurred to me that by enlargement of the segmentation cavity of an ovum such as shown in figure 5, with centrally placed segmentation cavity, there might result in further development the formation of a vesicle such as shown in B of figure 6.

It is freely admitted that the deductions here made, relative to irregularity in the formation of segmentation cavity, are not supported by conclusive evidence. It has seemed to me, however, that the interpretations given to the appearances presented are less open to criticism than others that might be suggested. These abnormal ova also suggest an inherent defect in the ova, leading to abnormal development, rather than abnormal development resulting from defective environment.

#### DEGENERATION OF OVA AS RESULT OF PATHOLOGIC UTERINE MUCOSA

In figure 7 are reproduced two ova which seem to me to show the primary stages of degeneration owing to pathologic condition of the uterine mucosa. Vesicle A was taken from the uterus of rat No. 91, 5 days, 16 hours, after insemination. In the uterus of this rat there were found only two ova. Vesicle B was taken

from rat No. 104, 6 days after insemination. In the uterus of this rat there were found six ova. In both of these rats, the ova present essentially the same stage of development, comparable to that shown in A and B of figure 23, Part I. As may be observed from the text of Part I (page 301) the stages obtained at the end of the sixth day and early hours of the seventh day, were found very difficult to fix. At this stage the ovum consists of a relatively large, thin walled vesicle, very prone to fixation shrinkage. All of the ova or vesicles obtained from rats Nos. 91 and 104, are very badly folded in their roof portion. Those shown

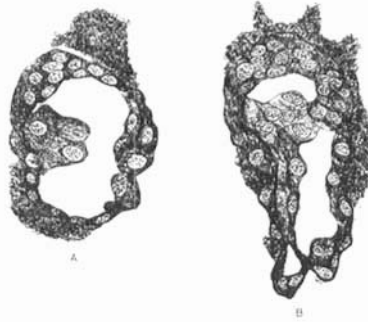


Fig. 7 Two ova of the albino rat partly surrounded by maternal blood with many phagocytic leucocytes. The folding of the roof of the vesicles is due to fixation shrinkage.  $\times 200$ . A, rat No. 91, 5 days, 16 hours, after the beginning of insemination. B, rat No. 104, 6 days after the beginning of insemination.

in A and B, figure 7, are representative. This folding, a result of imperfect fixation, is present in all of the vesicles of this stage, even though the respective vesicles present normal structure. The ova here figured may be regarded as having fairly normal structure, both as to rate of development and as to arrangement, form, and structure of constituent cells. All of the eight vesicles obtained from these two rats (No. 91, 2 ova; No. 104, 6 ova) are in part surrounded by exudated maternal blood, containing numerous leucocytes. Small masses of blood with leucocytes are found here and there in different parts of the uterine lumen of both rats, lodged in mucosal folds other than the characteristic decidual crypts enclosing the respective ova. These



decidual crypts are relatively shallow when compared with those of normal uteri of similar stages with normal ova. The uterine mucosa of the two rats under discussion does not appear to have reacted in a normal manner. In these preparations, attention is especially drawn to the presence of maternal blood with numerous phagocytic leucocytes found in relation with the ova, a condition never observed in normal development of ova and uterine mucosa. In A and B, figure 7, the red and white blood cells with granular detritus may be observed as found in relation with the respective vesicles, these presenting essentially the same appearances as do the other six ova obtained from these two rats; the one figured having been more favorably cut than any of the others. The appearances presented in these two rats are interpreted as showing a probable degeneration of the eight ova, and probably complete dissolution and removal. The vesicles appear to have developed normally to the stage at which they were obtained. As a result, however, of pathologic condition of the uterine mucosa, maternal blood, especially leucocytes, have entered the lumen of the uterus, the leucocytes being destined to play the rôle of phagocytes. In normal development of the albino rat, maternal blood does not enter the lumen of the uterus—decidual crypts—until after the uterine epithelium has become detached from the mucosa of the wall of the decidual crypt, in the region of lodgment of the enclosed ovum. Normally, very few leucocytes are met with in the lumen of the uterus, even in later stages of development, stages in which maternal red blood cells are met with in the decidual crypts. After experience had accumulated, uterine tubes supposed to contain developmental stages aging from the fourth to the sixth day, which on examination revealed blood and especially leucocytes in the lumen of the uterus, were regarded as not favorable specimens for finding ova. In a number of such uteri, cut completely in serial sections, no ova were found. It is possible that, owing to phagocytic action of the leucocytes present, the ova may have been completely removed prior to killing and fixing the tissues. In such condition, it would seem to me as pertinent to speak of faulty implantation, due to abnormal uterine mucosa. It seems to me signifi-

cant that in the two rats in which the pathologic condition affects primarily the maternal tissue, the uterine mucosa, all of the contained ova are prone to degeneration. In the abnormal ova previously described, for which it was suggested that the causes for the abnormality were to be sought in the ova themselves, in the great majority of instances, only one abnormal ovum was found in each uterus along with a variable number of ova which are to be regarded as normal for the respective stage.

#### IMPERFECT DEVELOPMENT OF THE ECTODERMAL VESICLE

The series contains two ova, very favorably cut, ova in which the ectodermal vesicle with the antimesometrial portion of the proamniotic cavity does not seem to have developed normally. Stages showing the differentiation of the egg-cylinder, the formation of the ectodermal vesicle with the antimesometrial portion of the proamniotic cavity, the formation of the mesometrial portion of the proamniotic cavity in the extraembryonic ectoderm, the union of the two primary proamniotic cavities to form a single space, are clearly shown in figures 26 and 27, Part I, in the series of closely approximated stages there portrayed. From a study of these figures, it will be observed that the antimesometrial portion of the proamniotic cavity develops within the ectodermal node before the mesometrial portion of this cavity develops in the extraembryonic ectodermal portion of the egg-cylinder. In the egg-cylinder shown in figure 8, rat No. 94, 8 days after the beginning of insemination, such is not the case. In the uterus of this rat there were found seven egg-cylinders, one of which, very favorably cut, is shown in C, figure 27, Part I. The other egg-cylinders obtained from this uterus, except the abnormally developed one to be discussed, though not favorably cut, present essentially the same form and structure as that figured under C of the figure above referred to. The egg-cylinder portrayed in figure 8 compares in size and form with those regarded as normal and taken from the same uterus. For the greater part it presents normal structure and normal relations of cells. The ectoplacental cone, only in part included in the figure, and the parietal

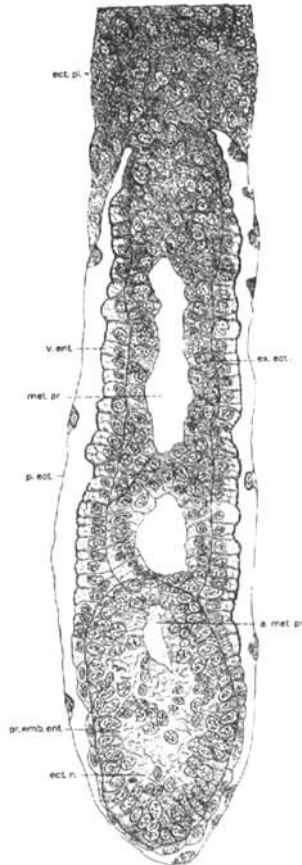
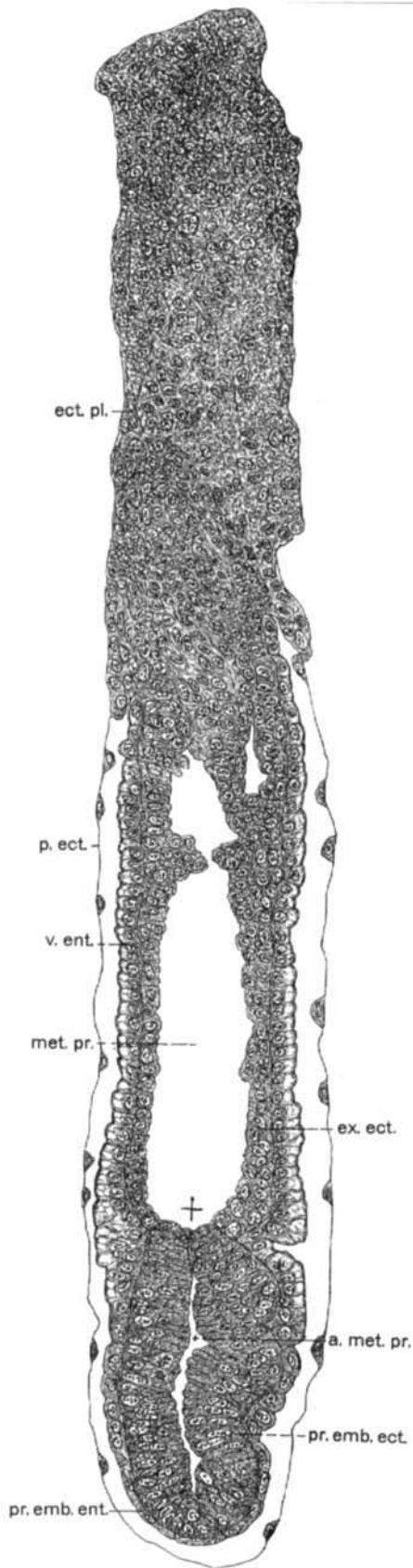


Fig. 8 Egg-cylinder of albino rat showing retarded development of ectodermal node and of the formation of the antimesometrial portion of the proamniotic cavity.  $\times 200$ . Rat No. 94, 8 days after the beginning of insemination. *ect.pl.*, ectoplacental cone or Träger; *v.ent.*, visceral entoderm; *met.pr.*, mesometrial portion of the proamniotic cavity; *p.ect.*, parietal or transitory ectoderm; *pr.emb.ent.*, primary embryonic entoderm; *ect.n.*, ectodermal node; *a.met.pr.*, imperfectly developed antimesometrial portion of proamniotic cavity; *ex.ect.*, extraembryonic ectoderm.

ectoderm, in structure and relation to decidual crypt, are to be regarded as of normal development. The visceral entoderm, surrounding the extraembryonic ectodermal portion of the egg-cylinder, is of normal structure, showing the three zones evidenc-

ing its absorptive function. The extraembryonic ectoderm, enclosing the mesometrial portion of the proamniotic cavity, presents normal structure and relations of cells. The only abnormality observed is in the region of the ectodermal node, the anlage of the ectodermal vesicle with the enclosed antimesometrial portion of the proamniotic cavity. With this stage of development of the egg-cylinder (see figs. 26 and 27, Part I) the ectodermal node presents a well formed cavity, surrounded by the cells of the primary embryonic ectoderm, radially arranged. In the egg-cylinder under discussion (fig. 8) there is distinctly a retardation in the development of the ectodermal vesicle with full differentiation of the primary embryonic ectoderm. An imperfectly developed antimesometrial portion of the proamniotic cavity is evident. This small cavity, indistinctly bounded, extends obliquely through several sections of the ectodermal node, and contains amorphous granular detritus, which in the preparations is stained by Congo red. The cells destined to form the primary embryonic ectoderm show no definite arrangement, especially as concerns the more centrally placed cells of the node. Since the primary embryonic ectoderm is the anlage for the ectoderm of the embryo, an arrest in its differentiation would of necessity profoundly affect further development of the embryo. Antimesometrial to the ectodermal node (just above it in the figure) there is found a small vesicle the walls of which are not distinctly delimited and composed of extraembryonic ectodermal cells, surrounding a small, completely bounded cavity. I am not prepared to say whether this small vesicle is to be regarded as developing from cells of the extraembryonic ectoderm, or from a displaced, accessory ectodermal node, in which a discrete portion of the proamniotic cavity has developed. If the latter, the possibility of a double anlage for the embryonic ectoderm is to be considered. My interpretation of this egg-cylinder as showing a retardation of the development of the ectodermal node and differentiation of the primary embryonic ectoderm, is confirmed from a study of a slightly older stage showing essentially the same condition. This ovum is presented in figure 9, and is taken from rat No. 41, 8 days, 16 hours, after the

Fig. 9 Egg-cylinder of albino rat, in which the antimesometrial and mesometrial portions of the proamniotic cavity have failed to unite to form a single or definite proamniotic cavity.  $\times 200$ . Rat No. 41, 8 days, 16 hours, after the beginning of insemination. *ect.pl.*, ectoplacental cone or Träger; *p.ect.*, parietal or transitory ectoderm; *v.ent.*, visceral entoderm; *met.pr.*, mesometrial portion of the proamniotic cavity; *ex.ect.*, extraembryonic ectoderm; *a.met.pr.*, antimesometrial portion of the proamniotic cavity; *pr.emb.ect.*, primary embryonic ectoderm; +, region at which, in normal development, by the end of the eighth and beginning of the ninth day, the two portions of the proamniotic cavity would have united to form a single space, the definite proamniotic cavity.



beginning of insemination. The uterus of this rat contains eight egg-cylinders, all of which, except the one here figured, show normal structure, though presenting quite different stages of development. One of these, cut serially in cross-section, is figured in C, figure 32, Part I, as showing anlage of mesoderm with primitive streak and groove. Two of the other egg-cylinders show the anlage of the mesoderm, two others show late pre-mesoderm stages of the egg-cylinder, the remaining egg-cylinders are less fully developed, one showing a development which may be compared to B of figure 26, Part I, thus a much younger stage. By the end of the eighth day and with the early hours of the ninth day after the beginning of insemination in the albino rat, the two parts of the proamniotic cavity, which develop discretely, have joined to form a single space (C, fig. 27, Part I). The egg-cylinder shown in figure 9, presents normal development in all parts, except that there is as yet no union of the two parts of the proamniotic cavity. This egg-cylinder is most favorably cut, in longitudinal direction; the plane of section being almost parallel to the mid-sagittal plane. This egg-cylinder, therefore, is easily followed through the several sections of the series into which it was cut. The irregularity of outline of the ectodermal vesicle, lower right of figure, it is believed, is not due to fixation shrinkage. Judging from size and structural differentiation of this egg-cylinder, union of the antimesometrial and mesometrial portions of the proamniotic cavity should have been completed before this stage of development was reached, with the primary embryonic ectoderm and the extraembryonic ectoderm forming a continuous layer, as shown in figure 29, Part I. The folding of the wall of the antimesometrial portion of the egg-cylinder, lower right of figure, evident in nearly all of the sections of the series, is regarded as indicating an abnormal growth of the primary embryonic ectodermal cells composing the wall of the ectodermal vesicle, as a result of retarded extension of the antimesometrial portion of the proamniotic cavity, perhaps an adjustment to meet the altered mechanical stress resulting from abnormal development. The condition here seen, it would seem, is foreshadowed in the egg-cylinder shown in figure 8.

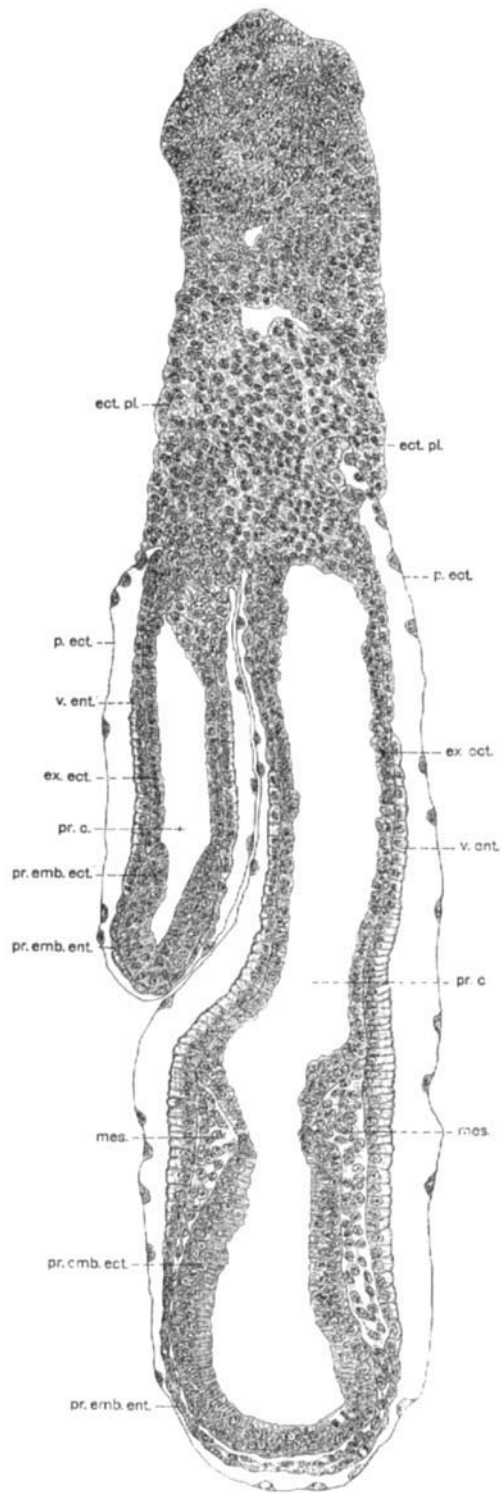


Fig. 10 Two egg cylinders of the albino rat found within the same decidual crypt, with in part common ectoplacental cone.  $\times 150$ . Rat No. 87, 9 days after the beginning of insemination. *ect.pl.*, ectoplacental cone or Träger; *p.ect.*, parietal or transitory ectoderm; *v.ent.*, visceral entoderm; *ex.ect.*, extra-embryonic ectoderm; *pr.c.*, proamniotic cavity; *pr.emb.ect.*, primary embryonic ectoderm; *pr.emb.ent.*, primary embryonic entoderm; *mes.*, mesoderm.

The causes operative in this retardation of development and differentiation of the ectodermal vesicle and primary embryonic ectoderm, I have been unable to determine. They would appear to be inherent in the egg-cylinder, since ectoplacental cone and visceral entoderm, so far as may be determined from a study of sections, appear to have functioned normally, in furnishing the necessary embryotroph in the form of maternal hemoglobin, as is normal for egg-cylinders of the albino rat of this stage of development.

#### TWO EGG-CYLINDERS IN ONE DECIDUAL CRYPT

The ova portrayed in figure 10 present a condition which must be regarded as exceedingly rare, since it represents the only instance of this condition observed in the extended series of preparations of the various stages of the development of the albino rat from the end of the first to the end of the ninth day after insemination, in my possession. This preparation is from rat No. 87, 9 days after the beginning of insemination. The uterus of this rat contained, other than the preparation here considered, six egg-cylinders of normal development, all showing a stage which is slightly older than that shown in figure 31, Part I, in that the mesoderm shows further development than is shown in that figure. In the preparation here figured there are found two egg-cylinders enclosed within the same decidual crypt. This figure, which is drawn by combining the drawings made from two sections, is reproduced at a magnification of 150 diameters, while all of the other figures portraying sections of ova, both in Part I and in Part II of this communication, are reproduced at a magnification of 200 diameters. This should be borne in mind when comparing this figure with the others. In figure 10, the lower portion of the large egg-cylinder to the level of the lower end of the smaller one was drawn from one section, while the remainder of the figure was drawn from the fourth following one. The adjustment was made by overlapping in the camera lucida drawing ( $\times 600$ ) the sharp mesometrial border of the primary embryonic ectoderm of the larger egg-cylinder. Scarcely any



adjustment was found necessary, none of the right wall of the larger egg-cylinder, and only very slightly so of its left wall. The slight deviation from the longitudinal axis of the larger egg-cylinder made the procedure desirable. It is thought that the figure as presented gives correctly the size of the respective egg-cylinders, and in all essentials, their relations; the greater part of the figure having been drawn from one section. Both of the egg-cylinders reveal normal structure for the stages of development attained. The larger one is cut in the coronal plane, as is readily determined by the distribution of the mesoderm, one side representing a mirror picture of the other. The direction of section in the smaller egg-cylinder, except that it is longitudinal, is not to be determined, since before the anlage of the mesoderm, a bilateral symmetry cannot be recognized in sections. Since these two egg-cylinders are in all essentials of normal form and structure, and since their structure is clearly brought out in the figure, an extended description of them at this place seems uncalled for. For respective stages the reader is referred to Part I. Attention may be drawn, however, to the fact that the visceral endoderm on the contiguous surfaces of the two egg-cylinders is less fully differentiated, and shows less absorption of the maternal hemoglobin than is seen on the exposed or free surfaces, this, no doubt, for mechanical reasons. Further, that in the region where the two egg-cylinders are in contact, the parietal ectoderm of each can be traced as a distinct layer to the bases of the respective ectoplacental cones, showing that each developed from a separate ovum. The ectoplacental cones are for a short distance distinct. In tracing the sections through the series the impression is gained that the ectoplacental cone of one of the egg-cylinders overlaps that of the other in such a way that in the plane of the sections obtained, one seems continuous with the other, as represented in the figure. The boundary between the two is not distinct, and it would seem that as a result of pressure, partial fusion of the two had taken place. The presence of two egg-cylinders, enclosed within a single decidual crypt, as shown in this figure, with one of them having much smaller size and representing a younger stage of development, I believe is

not to be explained on the supposition of superfecundation or superfoetation. The record for this rat does not show insemination on successive days. At The Wistar Institute, after all of the supposedly successful matings of albino rats, the females rats are caged apart from the males. The smaller egg-cylinder, though appreciably smaller, is in stage of development separated from the other by a time interval of perhaps less than 24 hours. It presents a stage of development which is comparable to C of figure 27 (8 days) and except for size, to the one figured in figure 29 (8 days, 17 hours) of Part I. It is believed that in this case both ova were seminated at about the same time, and proceeded through normal segmentation and that on reaching the lumen of the uterus during the fifth day they became lodged in close proximity in the same mucosal fold. With the development of the decidual crypts, both became enclosed within the same crypt, at perhaps slightly different levels. In further development one blastodermic vesicle dominated the other and from about the seventh day on, one developed and differentiated more rapidly than the other. Had development continued, two distinct embryos, with separate amniotic cavities, attached to the same placenta, would have been formed, with one embryo large and more fully developed than the other. From mere difference in size and of development of embryos in the same litter it is not warranted to postulate superfecundation nor superfoetation. I am of the opinion that usually when two morula masses are lodged in close proximity in the same mucosal fold, one or the other degenerates (fig. 2, A) and that the normal development of both, as in the preparation shown in figure 10, is of very rare occurrence.

#### CONCLUSIONS

A study of the abnormal or pathologic ova met with in the extended series of preparations covering the first ten days of the development of the albino rat, enables grouping them in two main classes:

a. Such in which all of the ova of a given rat show, or are associated with, abnormal development.

b. Such in which a single abnormal or pathologic ovum is found in the same uterus along with an average number of normally developed ova.

When all the ova in a given uterus show abnormality, the presumption seems warranted that the underlying cause of the abnormality is to be sought in an altered or pathologic condition of the uterine mucosa. In the instances observed, the presence of maternal blood with many phagocytic leucocytes was noted in the lumen of the uterus, adhering to and surrounding the ova. From the study of sections of the uteri of an appreciable number of albino rats, in which insemination and supposedly semination seemed normal, but in which on complete serial sectioning of the uterine tubes no ova were found, but in the lumen of the uterine tubes of which the presence of maternal blood and phagocytic leucocytes was noted, the conclusion seems warranted that death and complete absorption of ova, after a given stage of normal development has been reached, may occur. In such cases, one may with propriety speak of faulty implantation, due to altered or pathologic condition of the uterine mucosa, even in cases where no actual implantation would have occurred in corresponding normal stages. In the two rats (Nos. 91 and 104) in which this condition was observed, the decidual crypts were shallow and not developed to the extent normal for the respective stages, evidencing the abnormal condition of the mucosa.

In cases in which a single abnormal or pathologic ovum is found in the uterus along with several normal ova, the presumption seems justified that the underlying cause responsible for the abnormal development is to be sought in the ovum itself, and not in its environs.

Abnormal developmental stages, interpreted as due to irregular or retarded segmentation, irregular or abnormal segmentation cavity formation, and retarded development of the ectodermal node and primary embryonic ectoderm, where only a single ovum shows abnormal development in a uterus containing the average number of ova presenting normal development, are difficult to explain on the assumption that extraneous influences affecting a single ovum are operative. Practically all

of the abnormal ova of the class described, and especially is this true for older stages, present normal relations to the uterine mucosa and the walls of the decidual crypt after implantation, and so far as may be determined by structure, give evidence of normal absorption of maternal hemoglobin in stages in which such absorption is pertinent. It may be argued that a single ovum may be less favorably placed in relation to embryotroph or pabulum, and as a result of unfavorable nutrition, develop abnormally. This is difficult to conceive for stages in which the ova lie free in the lumen of the uterus, namely, to about the beginning of the seventh day after the beginning of insemination, when embryotroph or pabulum must be relatively evenly distributed. The presumption, it would seem to me, in such cases is in favor of regarding the primary cause of the abnormal development as inherent in the ovum.

Separation of the first two blastomeres and the presence of two egg-cylinders in a single decidual crypt are regarded as chance findings and as of rare occurrence, since each was met with only once in the material at hand.

#### LITERATURE CITED

Literature on pathologic ova of the albino rat is lacking. For the literature of all but the more recent work, dealing with comparative experimental teratology, the bibliographies accompanying the chapters of O. and R. Hertwig may be consulted; for that dealing with the pathology of human ova, the bibliographies accompanying the contributions of F. P. Mall may be consulted.

HERTWIG, O. 1906 Missbildung und Mehrfachbildung, die durch Störung des ersten Entwicklungsprozesse hervorgerufen werden. Hertwig's Handbuch der vergleichenden und experimentellen Entwicklungslehre der Wirbeltiere, Bd. 1, Part 1; Fischer, Jena.

HERTWIG, R. 1906 Der Furchungsprozess. Hertwig's Handbuch, Bd. 1, Part 1.

MALL, F. P. 1900 Welch Festschrift, Johns Hopkins Hospital Reports, vol. 9.  
1903 Vaughan Festschrift, Contributions to medical science, G. Wahr, Ann Arbor.

1908 A study of the causes underlying the origin of human monsters. Jour. Morph., vol. 19.

1910 The pathology of the human ovum. Keibel and Mall, "Manual of Human Embryology." Lippincott Company, Philadelphia.