

cerebellum. These findings correlate remarkably well with the abnormalities seen on MRI. In one previous autopsy study of a chronic solvent abuser, there was prominent degeneration and gliosis of ascending and descending long tracts with cerebral and cerebellar atrophy [4]. In addition, diffuse demyelination in the subcortical white matter and giant axonopathy of both peripheral and central nervous systems were seen. The conclusions were that the pathological changes were due to primary neuronal and axonal loss with secondary demyelination. Unlike our patients, however, this patient abused several solvents, including glue, which usually contains *n*-hexane or other solvents known to cause both central and distal axonal degeneration [13, 14]. In our autopsied patient, there is a possibility that alcohol abuse contributed to his neurological syndrome, particularly in view of recent data suggesting that brain atrophy in chronic alcoholism may be due to primary effects on white matter [15]. Although we cannot totally exclude such a contribution, the absence of medical complications of alcoholism, peripheral neuropathy, and alcoholic cerebellar degeneration strongly suggests that toluene was the primary toxin.

The MRI and neuropathological evidence from this study supports prior clinical studies that suggested that abuse of toluene can cause permanent CNS injury. The mechanism of injury is not known, and other solvents in the abused mixtures (e.g., methylene chloride) may enhance the toxicity of toluene. Further studies currently in progress are attempting to characterize the effects of toluene in minimally affected or neurologically normal toluene abusers. Data obtained from these studies may help establish a dose-response relationship between toluene abuse and permanent CNS injury and yield useful methods for evaluating those individuals who are chronically exposed to toluene at low levels in the workplace.

The authors wish to thank Dr Herbert H. Schaumburg for helpful suggestions and Karen Kaplan for her excellent secretarial assistance in the preparation of this manuscript.

Dr Rosenberg is the recipient of a Research Associate Career Development Award of the Veteran's Administration.

References

- Hormes JT, Filley CM, Rosenberg NL. Neurologic sequelae of chronic solvent vapor abuse. *Neurology* 1986;36:698-702
- Katzman R, Brown T, Fuld P, et al. Validation of a short orientation-memory-concentration test of cognitive impairment. *Am J Psychiatry* 1983;140:734-739
- Grabski DA. Toluene sniffing producing cerebellar degeneration. *Am J Psychiatry* 1961;118:461-462
- Escobar A, Aruffo C. Chronic thinner intoxication: clinicopathologic report of a human case. *J Neurol Neurosurg Psychiatry* 1980;43:986-994
- Metrick SA, Brenner RP. Abnormal brainstem auditory evoked potentials in chronic paint sniffers. *Ann Neurol* 1982;12:553-556
- Fornazzari L, Wilkinson DA, Kapur BM, Carlen PL. Cerebellar,

cortical and functional impairment in toluene abusers. *Acta Neurol Scand* 1983;67:319-329

- Lazar RB, Ho SU, Melen O, Daghestani AN. Multifocal central nervous system damage caused by toluene abuse. *Neurology* 1983;33:1337-1340
- Ehyai A, Freemon FR. Progressive optic neuropathy and sensorineural hearing loss due to chronic glue sniffing. *J Neurol Neurosurg Psychiatry* 1983;46:349-351
- Keane JR. Toluene optic neuropathy. *Ann Neurol* 1978;4:390
- Malm G, Lying-Tunell U. Cerebellar dysfunction related to toluene sniffing. *Acta Neurol Scand* 1980;62:188-190
- Boor JW, Hurtig HI. Persistent cerebellar ataxia after exposure to toluene. *Ann Neurol* 1977;2:440-442
- Lukes SA, Crooks LE, Aminoff MJ, et al. Nuclear magnetic resonance imaging in multiple sclerosis. *Ann Neurol* 1983;13:592-601
- Schaumburg HH, Spencer PS. Degeneration in central and peripheral nervous systems produced by pure *n*-hexane: an experimental study. *Brain* 1976;99:183-192
- Griffin JW. Hexacarbon neurotoxicity. *Neurobehav Toxicol Teratol* 1981;3:437-444
- Harper CG, Kril JJ, Holloway RL. Brain shrinkage in chronic alcoholics; a pathological study. *Br Med J* 1985;290:501-504

Stroke Associated with Obstructive Sleep Apnea in a Child with Sickle Cell Anemia

Patricia L. Robertson, MD,*† Michael S. Aldrich, MD,†
Samir M. Hanash, MD, PhD,* and Gary W. Goldstein, MD*†

We describe a child with sickle cell anemia and multiple ischemic infarctions who was found to have severe obstructive sleep apnea and hypoxemia, secondary to adenotonsillar enlargement. The apnea-associated hypoxemia likely contributed to the development of the strokes in this child. Moreover, because stroke in patients with sickle cell anemia, and maximal tonsillar enlargement (the most common cause of obstructive apnea in children) both have peak incidence at the same age (6-7 years), obstructive sleep apnea may be an important factor in the development of stroke in other children with sickle cell anemia.

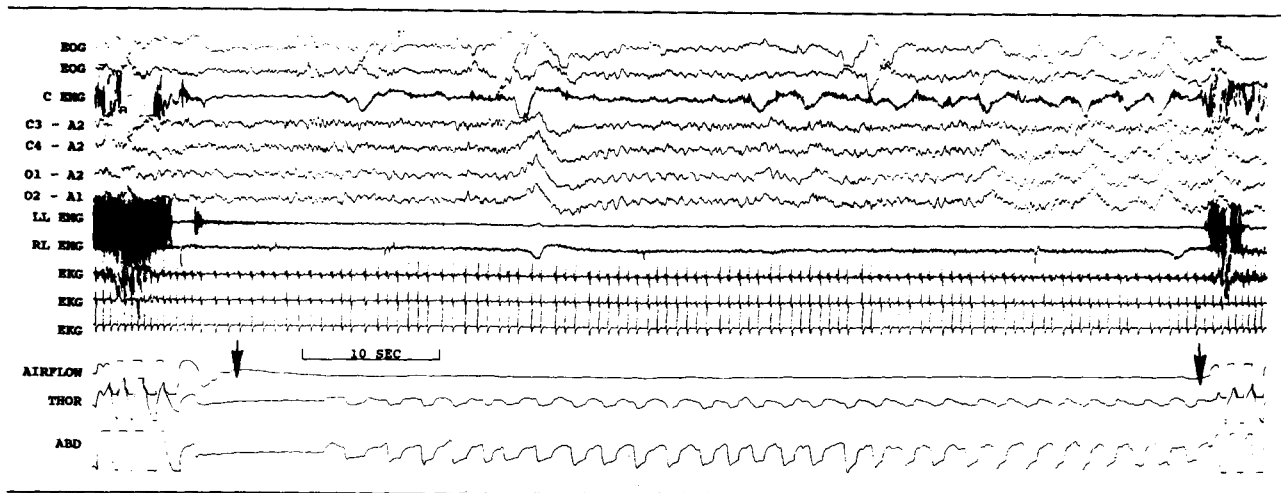
Robertson PL, Aldrich MS, Hanash SM, Goldstein GW. Stroke associated with obstructive sleep apnea in a child with sickle cell anemia. *Ann Neurol* 1988;23:614-616

Stroke is one of the most catastrophic complications of sickle cell anemia. Cerebral infarctions occur in 7 to

From the Departments of *Pediatrics and †Neurology, University of Michigan, Ann Arbor, MI 48109.

Received Sep 9, 1987, and in revised form Dec 15. Accepted for publication Dec 16, 1987.

Address correspondence to Dr Robertson, Pediatric Neurology, University of Michigan, Kresge II-R6060, Ann Arbor, MI 48109-0570.



Seventy-second obstructive apnea during REM sleep (indicated by arrows). (EOG = electrooculogram; CEMG = chin electromyogram; C3, C4, O1, O2 = electroencephalogram; LL EMG = left leg EMG; RL EMG = right leg EMG; EKG = electrocardiogram; THOR = thoracic wall motion; ABD = abdominal wall motion.)

10% of children with the disease and, without therapy, recur in two-thirds of the patients [1, 2]. The specific factors that predispose patients with sickle cell anemia to stroke, however, are unknown. We present a case in which obstructive sleep apnea and associated hypoxemia may have played a major role.

Case Report

A 6½-year-old right-handed girl with sickle cell anemia was admitted for evaluation of weakness of her right arm and leg. Her initial diagnosis was made at 17 months of age after several episodes of dactylitis, with a hemoglobin of 8.3 gm/dl and a characteristic hemoglobin electrophoresis with more than 80% hemoglobin S. Her mother reported that 3 to 4 weeks before admission, the child had several episodes, each lasting a few days, of being transiently clumsy while walking or running. One week before admission she awoke unable to walk because of right leg weakness. She had been previously hospitalized six times for febrile illnesses associated with sickle cell pain episodes.

Her general examination was remarkable for markedly enlarged tonsils and adenoids. Neurological examination revealed a mild right hemiparesis with greater involvement of

leg than arm. Sensory and language examinations were normal. Deep tendon reflexes were increased at the right biceps and quadriceps, and a Babinski response was present on the right side. The patient walked with a right foot drop and circumducted her right leg.

On admission, hemoglobin was 8.0 gm/dl and reticulocyte count was 20%. Cerebral computed tomography demonstrated attenuation in the region of the left temporooccipital junction, consistent with infarction. Following several partial exchange transfusions that resulted in a hemoglobin of 13.2 gm/dl and a hemoglobin S fraction of 26.8%, a cerebral angiogram demonstrated multiple areas of abnormal luxury perfusion associated with early venous drainage in the distributions of the left posterior cerebral artery, left anterior cerebral artery, right posterior cerebral artery, and in the watershed region between the right middle and anterior cerebral arteries. These were consistent with multiple areas of ischemic brain injury. Irregularities with narrowing of the supraclinoid right internal carotid artery and proximal A1 segment of the anterior cerebral artery were also noted.

During hospitalization, snoring and irregular nocturnal respirations were observed. A nocturnal polysomnogram demonstrated 145 obstructive apneas (Table). During REM sleep, apnea frequently lasted more than 1 minute with oxygen saturation as low as 47% (Fig).

The patient underwent tonsillectomy and adenoidectomy. Postoperatively, she no longer snored. A nocturnal polysomnogram 3 weeks later showed resolution of sleep apnea and oxygen desaturation.

Results of Polysomnography

	Presurgical			Postsurgical		
	REM	NREM	Total	REM	NREM	Total
Minutes of sleep	90	361	451	99	337	436
Obstructive apneas	65	80	145	0	1	1
No. per hour (apnea index)	43	13	19	0	0.2	0.2
Average duration	45 sec	25 sec			12 sec	
Longest duration	110 sec	45 sec			12 sec	
Lowest oxygen saturation	47	78	47	94	94	94

REM = rapid-eye-movement sleep; NREM = sleep stages 1, 2, 3, and 4.

Discussion

Repeated cerebral ischemic injury occurs commonly after an initial stroke in children with sickle cell anemia and is a major cause of serious morbidity in this disease [1, 3]. Although repeated transfusions following an initial stroke can reduce the rate of recurrence, no factors identify children at risk before the first stroke, when a major neurological deficit may already be sustained [4, 5].

Pathological studies provide evidence that sludging of blood flow in small cerebral vessels may lead to the development of stroke just as occurs in other organs during sickle pain episodes [6, 7]. However, stenotic lesions in proximal cerebral vessels and strokes in a watershed distribution support the view that insufficient flow distal to large vessel obstruction plays a role in some cases [8–10]. Hypoxemia superimposed in either setting could increase the risk for infarction in these children. Recurrent hypoxemia from sleep apnea in a child with sickle cell anemia could also contribute to the production of the vessel abnormalities themselves, possibly by permitting intravascular sickling at an arterial level where it does not ordinarily occur, leading to more exposure and damage to the endothelium by sickled erythrocytes.

We believe that the obstructive apnea and associated hypoxemia in this child with sickle cell anemia contributed to the series of cerebral infarctions she suffered. Moreover, sleep apnea may be a more frequent occurrence in children with sickle cell anemia than is now recognized. The peak age for incidence of strokes due to cerebral infarctions in patients with sickle cell disease is 6 to 7 years [1, 5]. Adenotonsillar enlargement, the most common cause of obstructive sleep apnea in children, is also maximal at about this age [11].

Obstructive sleep apnea could be an important factor in the development of stroke in some children with sickle cell anemia. Further study to assess the incidence of nocturnal respiratory disturbance in children with sickle cell anemia appears justified. Because snoring is very common with obstructive sleep apnea, children with sickle cell anemia and a history of snoring should promptly be investigated for sleep apnea and hypoxemia.

References

1. Powars D, Wilson B, Imbus C, et al. The natural history of stroke in sickle cell disease. *Am J Med* 1978;65:461–471
2. Bridges W. Cerebral vascular disease accompanying sickle cell anemia. *Am J Pathol* 1939;15:353–360
3. Lusher J, Haghghat H, Khalifa A. A prophylactic transfusion program for children with sickle cell anemia complicated by CNS infarction. *Am J Hematol* 1976;1:265–273
4. Williams J, Goff JR, Anderson MA, et al. Efficacy of transfusion therapy for one to two years in patients with sickle cell disease and cerebrovascular accidents. *J Pediatr* 1980;90:205–208
5. Wood DH. Cerebrovascular complications of sickle cell anemia. *Stroke* 1978;9:73–75

6. Baird RL, Weiss DL, Ferguson AD, et al. Studies in sickle cell anemia. XXI. Clinico-pathological aspects of neurological manifestations. *Pediatr* 1964;34:92–100
7. Hughes JG, Diggs LW, Gillespie CE. The involvement of the nervous system in sickle cell anemia. *J Pediatr* 1940;17:166–184
8. Boros L, Thomas C, Weiner WJ. Large cerebral vessel disease in sickle cell anemia. *J Neurol Neurosurg Psychiatry* 1976;39:1236–1239
9. Stockman JA, Nigro MA, Mishkin MM, Oski FA. Occlusion of large cerebral vessels in sickle cell anemia. *N Engl J Med* 1972;287:846–849
10. Rothman SM, Fulling KH, Nelson JS. Sickle cell anemia and the central nervous system: a neuropathological study. *Ann Neurol* 1986;20:684–698
11. Fujioka M, Young LW, Girdany BR. Radiographic evaluation of adenoidal size in children: adenoidal nasopharyngeal ratio. *AJR* 1979;133:401–404

Possible Neurotransmitter Basis of Behavioral Changes in Alzheimer's Disease

Alan M. Palmer, PhD, Gary C. Stratmann, MA,
Andrew W. Procter, MRC Psych,
and David M. Bowen, PhD

Serotonin, 5-hydroxyindoleacetic acid, and homovanillic acid concentrations have been determined in 10 areas of the cerebral cortex from 17 subjects with Alzheimer's disease and 18 control subjects. The dopamine metabolite was not reduced in any area, whereas both indoleamines were reduced in the superior frontal, inferior temporal, and fusiform gyri, and the temporal pole. These areas and areas of the parietal cortex, where there were no changes in concentration, have not previously been reported on. We argue that the large loss of indoleamines from the frontal lobe (to 50–63% of control values) is rather unexpected based on other biochemical measurements and may relate to behavioral changes.

Palmer AM, Stratmann GC, Procter AW,
Bowen DM. Possible neurotransmitter basis of
behavioral changes in Alzheimer's disease.
Ann Neurol 1988;23:616–620

Evidence from biopsy samples now indicates that the density of cholinergic nerve endings and concentrations of somatostatin-like immunoreactivity (somato-

From the Miriam Marks Department of Neurochemistry, Institute of Neurology (Queen Square), University of London, 1 Wakefield Street, London, WC1N 1PJ, UK.

Received Nov 10, 1987, and in revised form Dec 22. Accepted for publication Dec 22, 1987.

Address correspondence to Dr Palmer.