

Immune Thrombocytopenic Purpura Following Liver Transplantation: A Case Series and Review of the Literature

Ryan M. Taylor,¹ Paula Bockenstedt,² Grace L. Su,¹ Jorge A. Marrero,¹ Shawn M. Pellitier,³ and Robert J. Fontana¹

¹Division of Gastroenterology, ²Division of Hematology, Department of Internal Medicine, and ³Division of Transplant Surgery, Department of Surgery, University of Michigan, Ann Arbor, MI

Thrombocytopenia is common among liver transplant candidates and recipients. The aim of our study was to determine the incidence and outcome of new-onset immune-mediated thrombocytopenic purpura (ITP) following liver transplantation at a single center. Among the 256 liver transplant recipients with an International Classification of Diseases, Ninth Edition code for thrombocytopenia, 8 cases of new-onset ITP were identified, leading to an overall incidence of 0.7% in 1,105 consecutive liver transplant recipients over a 15-year period. All 8 patients were Caucasian, 5 (63%) were male, and the median age at ITP onset was 54 years (range, 15-63). The median platelet count at presentation was 3,500 cells/mL (range, 1,000-12,000) and liver disease was due to hepatitis C (38%), primary sclerosing cholangitis (38%), and cryptogenic cirrhosis (25%). The median time from transplant to ITP onset was 53.5 months (range, 1.9-173). Three of the 6 patients tested (50%) had cell-bound antiplatelet antibodies, 1 patient had an underlying hematological malignancy, and none of the organ donors had a history of ITP. Corticosteroids and/or immunoglobulin infusions were effective in 4 patients. However, serial rituximab infusions were required in 4 patients with persistent thrombocytopenia, and 3 of them eventually required splenectomy to induce disease remission. At a median follow-up of 19.7 months, 7 long-term survivors remain in remission with a median platelet count of 267,000 cells/mL. In conclusion, new-onset ITP is an infrequent but important cause of severe thrombocytopenia in liver transplant recipients. Corticosteroids and immunoglobulin infusions were effective in 50% while the remainder of patients required rituximab infusions or eventual splenectomy for long-term disease remission. *Liver Transpl* 12:781-791, 2006. © 2006 AASLD.

Received September 1, 2005; accepted December 21, 2005.

Autoimmune thrombocytopenic purpura is a disorder characterized by the premature removal of opsonized platelets from the circulation.¹ Autoimmune thrombocytopenic purpura has been further divided into 4 broad etiologic subgroups, including idiopathic immune-mediated thrombocytopenic purpura (ITP), secondary immune thrombocytopenia, immune drug-induced thrombocytopenia, and viral infection-related thrombocytopenia.² Clinical manifestations of ITP include mucocutaneous bleeding and bruising, while some patients may present with asymptomatic thrombocytopenia.^{3,4} Although antiplatelet antibodies are frequently detected in ITP patients, these alloantibodies are nonspecific and can be found in patients with

splenomegaly and autoimmune disorders, and in blood transfusion recipients.³ To make a diagnosis of ITP, one must first exclude other more common causes of thrombocytopenia, including infections, drugs, malignancy, and systemic diseases. A bone marrow biopsy demonstrating increased megakaryocytes is supportive of a diagnosis of ITP but not required.^{5,6} Furthermore, an improvement in platelet count with corticosteroids is suggestive but not diagnostic of ITP.

Thrombocytopenia is common among orthotopic liver transplant (OLT) candidates and recipients. The mechanism of thrombocytopenia in OLT candidates is complex and likely due, in part, to reduced hepatic thrombopoietin production, hypersplenism, chronic

Abbreviations: ITP, immune thrombocytopenic purpura; OLT, orthotopic liver transplant; IVIG, intravenous immunoglobulin; CBPAb, cell-bound platelet antibody; EBV, Epstein-Barr virus; HCV, hepatitis C virus; HD, hospital day; CMV, cytomegalovirus. Address reprint requests to Robert J. Fontana, MD, University of Michigan Medical Center, 3912 Taubman Center, Ann Arbor, MI 48109-0362. Telephone: 734-936-4780; FAX: 734-936-7392; E-mail: rfontana@umich.edu

DOI 10.1002/lt.20715

Published online in Wiley InterScience (www.interscience.wiley.com).

gastrointestinal bleeding, intravascular hemolysis, and drug effects. As many as 50% of patients develop transient worsening of thrombocytopenia within the first 2 weeks of OLT with subsequent platelet count increases by 1 month.⁷ However, persistent thrombocytopenia may be observed in some patients due to residual portal hypertension, hypersplenism, and/or drug effects. Recently, we encountered several OLT recipients with severe symptomatic thrombocytopenia (i.e., <15,000 cells/mL) and a clinical picture consistent with ITP requiring hospitalization and treatment. The aims of our study were to determine the incidence, clinical presentation and outcome of patients with new-onset ITP in a large liver transplant program. We also set out to determine the response of OLT recipients with new-onset ITP to corticosteroids, intravenous immunoglobulin (IVIG), immunosuppressants, and splenectomy as well as the anti-CD20 agent, rituximab.⁸⁻¹⁰ Finally, we reviewed the published literature on ITP following OLT to develop an algorithm for the diagnosis and treatment of OLT recipients with new-onset ITP.

PATIENTS AND METHODS

This is retrospective review of all adult and pediatric OLT recipients with ITP seen at the University of Michigan Medical Center in Ann Arbor, MI, between January 1990 to June 2005. During this period, 1,105 liver transplants (923 adult, 182 pediatric) were performed. Using ICD-9 codes for thrombocytopenia (287.3, 287.4), 256 OLT recipients were identified and reviewed. The project was approved by the IRB of the University of Michigan with a waiver of consent. Subjects were considered to have ITP if there was evidence of new-onset severe, isolated immune mediated thrombocytopenia (i.e., platelet count <15,000 cells/mL) in the absence of other identifiable causes of thrombocytopenia, including microangiopathic hemolytic anemia/thrombotic thrombocytopenic purpura, as excluded by peripheral blood smear review. Hematology consultation was obtained on all patients at the time of diagnosis. Additionally, bone marrow biopsy and cell-bound antiplatelet antibody (CBPAb) testing were obtained in most patients but not required to make a diagnosis of ITP. All cases of new-onset ITP were reviewed by one of the investigators (PB), an experienced clinical hematologist, to insure that diagnostic criteria for ITP were met.

To identify prior publications on ITP in OLT recipients, a Medline search using the terms *thrombocytopenia*, *liver transplantation*, *platelets*, *ITP*, and *rituximab* was conducted. One hundred and eighty-eight articles were identified, and 51 were incorporated into this review.

RESULTS

There were 256 OLT recipients with an ICD-9 code for thrombocytopenia, 25 of whom had no preliminary explanation for thrombocytopenia. Upon further evaluation, 17 patients were excluded for various reasons,

including 7 subjects with known ITP prior to transplant, leaving 8 OLT recipients with new-onset ITP following liver transplantation (see Table 1). Therefore, the overall incidence of new-onset ITP post-OLT was 0.7% among the 1,105 OLT recipients.

Case 1

A 55-year-old male underwent OLT in 1988 for secondary biliary cirrhosis and developed ductopenic rejection requiring retransplantation 4 months later. He also developed hypertension, diabetes, and renal failure requiring dialysis. At 122 months post-OLT, he was diagnosed with a large granular T-cell lymphocytic lymphoma, which was initially treated by decreasing his cyclosporine dose. At 125 months post-OLT, a liver biopsy showed Epstein-Barr virus (EBV)-related large cell lymphocytic leukemia. The patient was followed clinically with reduction in his immunosuppression. Four years later, in 2001, he was noted to have a platelet count slowly decreasing to 80,000 cells/mL. Cell-bound platelet antibody was negative. A bone marrow biopsy performed at 168 months post-OLT (5 months prior to ITP presentation), showed a persistent T-cell large granular lymphocytic leukemia with 50% bone marrow cellularity and trilineage hematopoietic maturation with an adequate number of megakaryocytes.

The patient was evaluated at 14.2 years post-OLT with a platelet count of 12,000 cells/mL, a hemoglobin count of 12.8 g/dL and a white blood cell count of 3,500 cells/mL. Medications at presentation included cyclosporine, lansoprazole, Zaroxolyn, allopurinol, folic acid, erythropoietin, calcium, sevelamer, and lorazepam. After receiving prednisone and IVig his platelet count increased to 67,000 cells/mL and has remained stable at last follow-up, 29 months since initial ITP presentation.

Case 2

A 46-year-old male underwent OLT for hepatitis C virus (HCV) cirrhosis in 1992 that was complicated by rejection requiring OKT3 as well as chronic renal insufficiency. He received antiviral therapy for 2 months in 1994 for recurrent HCV and had stable a platelet count of approximately 90,000 cells/mL thereafter off interferon.

In early 2002, the patient presented with flu-like symptoms, headache, and new-onset bruising. His daughter had experienced a recent, unspecified viral illness. Immediately prior to presentation and following the development of the aforementioned symptoms, the patient took colchicine and 1 dose of trimethoprim-sulfamethoxazole. Shortly thereafter at 117 months post-OLT, he was hospitalized with a platelet count of 6,000 cells/mL, WBC count of 2,900 cells/mL, and a hemoglobin count of 10.8 g/dL. Concomitant medications included cyclosporine, trandolapril, atenolol, allopurinol, ranitidine, fluoxetine, bupropion, and furosemide. A liver ultrasound showed a mildly enlarged spleen with a maximal diameter of 15.4 cm. Following a platelet infusion and a single dose of intravenous ste-

TABLE 1. Patients With New-Onset ITP Following Liver Transplantation

Case	Age (y), Gender, Ethnicity	Liver Disease, OLT Date	Immunosuppression at ITP Presentation	Days From OLT to ITP Onset	Initial/Nadir Platelet Count	CBPAb	ITP Treatment	Outcomes
1	55, M, Caucasian	Biliary strictures, HCV, 1988 × 2	Cyclosporine	5,186	12,000	Neg	Prednisone, IVIg	No recurrence at 29.2- mo follow-up.
2	46, M, Caucasian	HCV, 1992	Cyclosporine	3,506	6,000	ND	Prednisone, IVIg	No recurrence at 3.4- years follow- up; platelets 40,000- 50,000.
3	57, M, Caucasian	PSC, 1993	Tacrolimus	2,994	4,000	Neg × 2	Prednisone, plasmapheresis, IVIg, WinRho, rituximab	No recurrence at 3.9- y follow- up.
4	63, F, Caucasian	Cryptogenic cirrhosis, 1995	Prednisone, cyclosporine, azathioprine	57	3,000	Pos	Prednisone, IVIg	No recurrence 32- d follow- up. Patient died of sepsis POD 100.
5	53, M, Caucasian	PSC and cholangiocarcinoma, 1998	Tacrolimus	1,480	10,000	Pos	Prednisone, IVIg	Relapse × 3. No recurrence for 239 days since last relapse.
6	55, F, Caucasian	Cryptogenic cirrhosis, 1998	Prednisone, tacrolimus	1,768	3,000	Neg	Prednisone, IVIg, plasmapheresis, Rituximab, splenectomy	Relapse at 580 days, platelets 376,000 at 3.5- mo post- splenectomy.
7	15, F, Caucasian	PSC, 2002	Prednisone, tacrolimus	442	1,000	ND	Prednisone, IVIg, vincristine, rituximab, splenectomy	No recurrence at 20-mo follow- up.
8	49, M, Caucasian	HCV and HCC, 2003	Prednisone tacrolimus, MMF	244	3,000	Pos	Prednisone, Decadron, IVIg, Cytozan, Rituximab, splenectomy	No recurrence at 19.3-mo follow-up.

Abbreviations: CBPAb, cell bound platelet antibody; M, male; Neg, negative; ND, not done; PSC, primary sclerosing cholangitis; F, female; Pos, positive; POD, postoperative day; MMF, mycophenolate mofetil.

roids and IVIg, his platelet count improved to 28,000 cells/mL, and he was discharged home on hospital day (HD) 3.

Eight days later, he was rehospitalized for abdominal pain with a hemoglobin of 9.0 g/dL and a platelet count of 89,000 cells/mL. Diagnostic evaluation included negative polymerase chain reaction for cytomegalovirus (CMV) and EBV. The platelet count remained above 47,000 cells/mL throughout the hospitalization without further treatment. Although a bone marrow biopsy and antiplatelet antibodies were not obtained, it was felt that the patient's thrombocytopenia was most likely due to a viral infection precipitating ITP. Thrombocytopenia due to trimethoprim-sulfamethoxazole was felt to be less likely due to the timing of exposure after the onset of bruising and this patient's prior use of this agent without adverse sequelae. Subsequent platelet counts have remained at approximately 50,000 cells/mL without further treatment. The mild chronic thrombocytopenia detected both before and after ITP onset may, in part, be due to portal hypertension from recurrent HCV cirrhosis on liver biopsy.

Case 3

A 57-year-old male underwent OLT in 1993 for primary sclerosing cholangitis. His postoperative course was complicated by hepatic artery thrombosis requiring surgical repair, rejection treated with corticosteroids and OKT3, and recurrent cirrhosis demonstrated on liver biopsy in 1998. At month 98 post-OLT, his platelet count abruptly dropped from a stable baseline of 70,000-100,000 to 3,000 cells/mL without evidence of bleeding. He was followed as an outpatient by a hematologist since his platelet counts remained over 10,000 cells/mL without clinically significant bleeding. Two months later, he was hospitalized with epistaxis and diagnostic serologies including CPBAb, CMV and EBV studies were all negative. Bone marrow biopsy showed patchy marrow cellularity but adequate megakaryocytes. Medications at presentation included tacrolimus, ursodeoxycholic acid, ciclopirox, ranitidine, and diphenoxylate. Sirolimus was substituted for tacrolimus, and the patient was treated with 6 days of plasmapheresis with no improvement. After a prednisone pulse on HD 12 and IVIg on HD 16, his platelet counts improved from 2,000 to 17,000 cells/mL. He also received Win-Rho for 1 day. Weekly rituximab infusions were started on HD 21, and after the sixth infusion his platelet count improved to 139,000 cells/mL and has remained stable 47 months after initial diagnosis of ITP with no further therapy (Fig. 1).

Case 4

A 63-year-old female with cryptogenic cirrhosis underwent OLT in 1995. The patient had a history of diabetes mellitus, lupus, arthritis, and hypothyroidism. On postoperative day 57, she was noted to have increased serum aminotransferase levels and an asymptomatic platelet count of 20,000 cells/mL. Medications at the

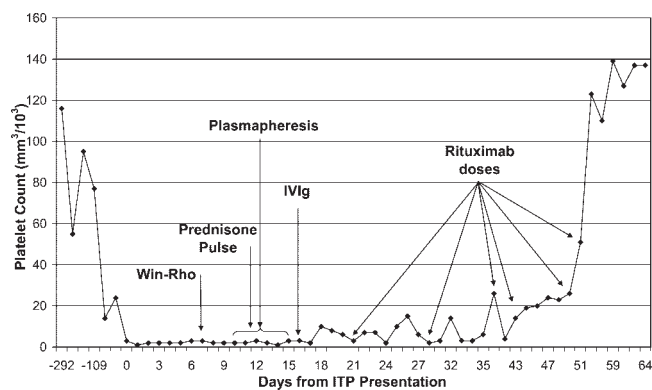


Figure 1. New-onset ITP responsive to rituximab following liver transplantation (Case 3). A 57-year-old man with primary sclerosing cholangitis had failed to respond to intensive medical treatment for new-onset ITP presenting 98 months post-OLT. However, after six doses of weekly rituximab his platelet count improved and has remained stable for 47 months with no further therapy.

time of admission included cyclosporine, prednisone, azathioprine (75 mg/d), as well as furosemide, levothyroxine, glyburide, vitamins, and ranitidine. The azathioprine and glyburide were discontinued, but her platelet count dropped to 3,000 cells/mL and she received platelet infusions. Diagnostic evaluation included mildly positive antiplatelet antibodies as well as a bone marrow biopsy revealing hypercellular marrow and increased megakaryocytes. There was no evidence of CMV or EBV reactivation.

On HD 2, the patient was started on IVIg, and her prednisone dose was increased to 50 mg twice a day. After 3 days of IVIg treatment, she developed non-oliguric renal failure with a peak creatinine of 3.9 mg/dL. Her platelet count began to rise after HD 6 and was 98,000 cells/mL at discharge. Thirteen days later her platelet count was 137,000 cells/mL. Unfortunately, the patient died approximately 1 month later, on postoperative day 100, with sepsis from *Clostridium perfringens* at an outside hospital. A limited autopsy revealed portal venous gas and massive bowel wall thickening but no evidence of malignancy.

Case 5

A 53-year-old male with primary sclerosing cholangitis and cholangiocarcinoma underwent OLT in 1998. The patient had previously undergone colectomy for ulcerative colitis as well as incidental splenectomy. His post-OLT course was complicated by neuropathy, leukoclastic vasculitis, and coronary artery disease. At 49 months post-OLT, he presented with bruises on his lower extremities and blood in his stool. Medications at presentation included tacrolimus, alendronate, omeprazole, losartan, metoprolol, aspirin, and vitamins. On admission, his platelet count was 12,000 cells/mL, which improved to 53,000 cells/mL following platelet infusion. A serum protein electrophoresis demonstrated a monoclonal gammopathy of uncertain significance, and serum cryoglobulins were undetectable,

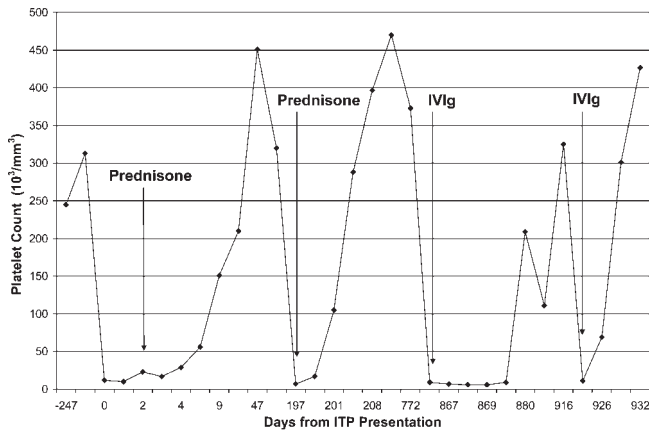


Figure 2. Relapsing new-onset ITP following liver transplantation (Case 5). A 53-year-old male presented with new-onset ITP 43 months after liver transplantation. The patient required 3 courses of corticosteroids and IVIg for relapsing ITP over 2 years.

but a positive CBPAb was noted with reactivity to IIb/ Glycoprotein IIIa and Ia/IIa. He responded to a 6-week course of steroids with a discharge platelet count of 300,000 cells/mL.

The patient was readmitted 6 months after initial ITP presentation with a platelet count of 7,000 cells/mL and treated again with intravenous and oral steroids. EBV serologies were consistent with prior infection. The patient did well off steroids until he had additional flares of symptomatic thrombocytopenia approximately 2 years later (Fig. 2). He responded to retreatment with IVIg, and his platelet counts have remained above 130,000 cells/mL since his last course of treatment. At 39 months following ITP presentation, his most recent platelet count was 495,000 cells/mL off steroids.

Case 6

A 55-year-old female with cryptogenic cirrhosis underwent OLT in 1998. Her course was complicated by biliary strictures, acute rejection treated with pulse steroids and OKT3, and chronic ductopenic rejection treated with tacrolimus and steroids. In 2003, she presented with bleeding gums and epistaxis and had an initial platelet count of 3,000 cells/mL. A CMV polymerase chain reaction and CBPAb were negative and a bone marrow biopsy demonstrated adequate megakaryocytes. At an outside hospital, the patient was initially treated with dexamethasone and IVIg for 3 days; however, the patient then developed fevers, raising concern for thrombotic thrombocytopenic purpura, and she received plasmapheresis for 2 days without improvement. Upon transfer to the University of Michigan, the patient was found to have positive blood cultures for *Staphylococcus aureus*. Due to persistent thrombocytopenia despite steroids, weekly rituximab infusions were started on HD 19 and the platelet count subsequently improved to 49,000 cells/mL. However, rituximab was discontinued after 3 doses when the patient developed

an acute hypersensitivity reaction, including severe rash and oral mucocutaneous blistering.

The patient did well until 19 months after initial ITP presentation, when she developed an asymptomatic decrease in her platelet count to 14,000 cells/mL with persistently negative CBPAb. She was retreated with high dose steroids and IVIg over a 6-week period and eventually rechallenged with rituximab for persistent thrombocytopenia. She eventually required splenectomy 580 days from initial ITP presentation due to a platelet count of 1,000 cells/mL. She has been treated with ongoing steroids due to concerns for post-OLT autoimmune liver disease. Her most recent platelet count was 376,000 cells/mL at 3.5 months post-splenectomy.

Case 7

A 15-year-old female with primary sclerosing cholangitis underwent OLT in 2002. At 15 months post-OLT, she presented with malaise and hematochezia and was found to have a platelet count of 1,000 cells/mL as well as a hemoglobin of 5.0 g/dL with a WBC of 2,200 cells/mm³. Two months prior to presentation, her WBC was 4,100 cells/mm³, hemoglobin count was 13.4 g/dL, and platelet count was 138,000 cells/mL. Medications at presentation included low-dose prednisone and tacrolimus. Bone marrow biopsy demonstrated 90% cellularity with trilineage hematopoietic maturation. Both CMV and EBV studies were negative. Ultrasound on presentation demonstrated splenomegaly with a maximal diameter of 16.3 cm. The patient responded to IVIg and prednisone with a discharge platelet count of 60,000 cells/mL. She was readmitted 18 days from initial presentation due to persistent menstrual bleeding and right retinal hemorrhage with a platelet count of 4,000 cells/mL. Additional treatment included rituximab as well as vincristine. She remained persistently thrombocytopenic with platelet count of 2,000 cells/mL leading to readmission 34 days from initial presentation. During this admission, another course of intravenous steroids, rituximab, and vincristine were given without improvement in platelet counts and she eventually required a splenectomy 40 days after initial presentation. Immediately postsplenectomy, her platelets were 101,000 cells/mL and her most recent platelet count was 543,000 cells/mL 20 months after initial presentation with ITP.

Case 8

A 49-year-old male with HCV cirrhosis and hepatocellular carcinoma underwent OLT in early 2003. Immunosuppression included prednisone, tacrolimus, and mycophenolate mofetil. Due to recurrent HCV with bridging fibrosis on biopsy, pegylated interferon- α 2a 90 μ g per week with ribavirin 400 mg daily was started on postoperative day #217 with a pretreatment platelet count of 186,000 cells/mL. Three weeks later, he developed spontaneous bruising with a platelet count of 55,000 and antiviral treatment was discontinued. The patient was hospitalized 10 days later with diarrhea,

TABLE 2. Patients With Known ITP Prior to Liver Transplantation

Age (y) at OLT, Gender, Ethnicity	Liver Disease, OLT Date	Current Immunosuppression	Time From ITP Presentation to OLT	Pre-OLT ITP Treatment	Recurrence of ITP Post transplant	Most Recent Platelet Count (cells/mm ³)	Years of ITP-Free Survival Since OLT
52, F, Caucasian	Fulminant liver failure, 1993	Cyclosporine, azathioprine, prednisone	5.6 y	Steroids, splenectomy	No	171,000	11.8
34, M, Caucasian	HBV, HCV, alcohol, 1993	Cyclosporine	7 mo	Unknown	No	117,000	10.7
64, M, Caucasian	Alcohol, alpha-1 antitrypsin deficiency, 1994	Cyclosporine	9 mo	Prednisone, IVIg	No	299,000	10.4
40, F, Caucasian	PSC, 1994	MMF, prednisone, cyclosporine	8.4 y	Steroids, IVIg, splenectomy (following OLT)	No*	255,000	11.1
14, M, Caucasian	Cystic fibrosis, 1999	MMF, prednisone, tacrolimus	11 mo	Unknown	No	133,000	5.6
53, F, Caucasian	Cryptogenic cirrhosis, 2003	Cyclosporine	2.3 y	Unknown	No	139,000	1.7
52, M, African American	HCV, alcohol, 2005	Cyclosporine	6mo	Prednisone	No	64,000	0.25

Abbreviations: F, female; HBV, hepatitis B virus; M, male; MMF, mycophenolate mofetil.
*Required splenectomy for recurrent autoimmune hemolytic anemia post-OLT.

malaise, and bruising and a platelet count of 3,000 cells/mL. Medications included tacrolimus, vitamins, citalopram, ursodeoxycholic acid, gabapentin, and temazepam. Diagnostic studies for CMV and EBV infection as well as heparin-induced thrombocytopenia antibody were negative. However, CBPAAb was positive. A bone marrow biopsy revealed normal megakaryocytes. His hospital course was complicated by mucosal bleeding and persistent thrombocytopenia despite treatment with high dose corticosteroids for 5 weeks, IVIg on HD 4-5, and pulse Cytoxan on HD 12. On HD 33, weekly infusions of rituximab were initiated without improvement in his platelet count. Fifty-five days after presentation, he developed a spontaneous subdural hemorrhage with a nadir platelet count of 1,000 cells/mL necessitating emergent splenectomy.

Postsplenectomy, the patient's platelet count increased to 45,000 cells/mL and he was discharged home. However, 72 days after presentation, he was re-hospitalized with extension of his subdural hematoma and a platelet count of 37,000 cells/mL. Without further intervention, his platelet counts improved and his most recent platelet count was 366,000 cells/mL at 27 months post-OLT.

Patients with ITP prior to liver transplantation

There were 7 OLT recipients with established ITP prior to liver transplantation (Table 2). Six of the patients

were Caucasian (85%) and 57% were men. The median age of these subjects (52 years; range, 14-64 years) was similar to that of the 8 patients with new-onset ITP post-OLT (54 years; range, 15-63 years). The diagnosis of ITP had been made at a median of 11 months prior to OLT, and 4 of the patients had required prior medical therapy or splenectomy. All of these patients are currently alive and well with a mean follow-up of 7.4 years post-OLT. Quite remarkably, none of the patients have had recurrent ITP post-OLT. However, 1 patient did undergo splenectomy due to refractory autoimmune hemolytic anemia post-OLT.

DISCUSSION

Aberrations in platelet level and function are common among OLT recipients particularly in the early postoperative period. A recent series of 541 OLT recipients showed a mean decrease in platelet count of 56% within 2 weeks of surgery and a mean platelet nadir of 44,638 cells/mL seen in the first 4 days post-OLT. However, the mean platelet count exceeded pretransplant levels in most subjects by week 4.⁷ The etiology of thrombocytopenia in OLT recipients is complex and likely multifactorial. Contributing factors include splenic sequestration, thrombopoietin deficiency, reperfusion injury, graft vs. host disease, bleeding, disseminated intravascular coagulation, sepsis, intrahepatic deposition of platelets, medications, and viral infections.¹¹⁻¹⁵ Medications in particular are a common cause of abnormal

platelet count and function in OLT recipients. For example, antimetabolites such as azathioprine and mycophenolate mofetil can lead to thrombocytopenia via direct effects on the bone marrow in a dose-dependent manner.^{16,17} The calcineurin inhibitors cyclosporine and tacrolimus have also been reported to cause thrombocytopenia, although the clinical presentation may be more similar to thrombotic thrombocytopenic purpura.¹⁸⁻²⁰ In addition, ganciclovir, valganciclovir, and trimethoprim sulfamethoxazole can lead to thrombocytopenia in transplant recipients. Heparin-induced thrombocytopenia is an increasingly recognized cause of thrombocytopenia and should also be considered in exposed patients.²¹ In all of our patients, there was evidence of severe thrombocytopenia at presentation and drugs known to be associated with thrombocytopenia were discontinued early on without improvement in the platelet count.

Acute or chronic viral infections may also be associated with new-onset thrombocytopenia. For example, human immunodeficiency virus infection has been associated with new-onset immune-mediated destruction of platelets.²² Other viral infections, including CMV, EBV, parvovirus B19, herpes zoster, and varicella also can induce secondary ITP.^{12,13,23-25} Therefore, excluding these opportunistic infections is important in the evaluation of unexplained thrombocytopenia among immunosuppressed OLT recipients. In the current series, only Case 2 had a history suggestive of exposure to an undefined viral pathogen but all diagnostic studies were negative. HCV infection is associated with a number of autoimmune extrahepatic manifestations including ITP.²⁶ In particular, an increased prevalence of HCV infection has been reported in patients with ITP as well as cryoglobulinemia.^{27,28} In addition, not only does interferon therapy for HCV leads to direct suppression of bone marrow progenitor cells, but also rare cases of interferon-induced ITP have been reported.²⁹ Interestingly, three of the patients with new-onset ITP from the current series had underlying HCV, and two of the patients with known ITP prior to OLT had HCV infection. We speculate that Case 8 in the present series may have had a component of interferon-induced ITP, since severe thrombocytopenia was noted 3 weeks after starting pegylated interferon.

Other noninfectious etiologies that can present with new-onset secondary immune-mediated thrombocytopenic purpura include autoimmune disorders such as systemic lupus erythematosus as well as hematologic malignancies and lymphoma.³⁰ In the OLT population, posttransplant lymphoproliferative disorder should also be considered in patients with unexplained changes in any blood cell line. Although Case 1 was diagnosed with a variant of leukemia, none of the other patients undergoing bone marrow biopsy in our series had evidence of a malignancy or posttransplant lymphoproliferative disorder at presentation or during follow-up.

The diagnostic value of antiplatelet autoantibody testing in patients with suspected ITP remains unclear due to frequent false-positive and false-negative test

results.³⁰ Interpretation of antiplatelet antibodies is even more challenging in patients with chronic liver disease and portal hypertension who frequently have low titer antiplatelet antibodies with or without associated thrombocytopenia.³¹ Consistent with prior reports of OLT recipients with new-onset ITP (Table 3), 3 of our patients had negative CBPAbs while 3 had positive titers. Alloimmune thrombocytopenia can also develop after transplantation of organs from donors with a history of ITP or antibodies to HPA-1a alloantigen.^{5,32,33} However, review of the donor medical history in our 8 OLT recipients demonstrated no evidence of preexisting ITP in any of the donors.

There have been additional reports of an increased risk of developing ITP in patients with primary biliary cirrhosis and primary sclerosing cholangitis both before and after liver transplantation.³⁴⁻⁴¹ Interestingly, there was no apparent overrepresentation of autoimmune liver disease in our 8 patients with new-onset ITP (Table 1). Similarly, the 7 patients with known ITP prior to OLT had a distribution of liver diseases typical of patients undergoing OLT in the United States without an overrepresentation of autoimmune etiologies, although the number of patients affected is limited (Table 2).

The incidence of ITP in the general population is estimated at 50-100 cases per 1 million with over half of the cases arising in children.^{6,42} In the current study, the incidence of new-onset ITP was noted to be higher at 0.7% over the 15-year period. However, the true incidence may be even higher in OLT recipients who are prospectively followed with frequent laboratory monitoring. Nineteen additional cases of new-onset ITP following OLT were identified in the literature (Table 3). Interestingly, 8 of these 19 patients were younger than 20 years of age, while all of our patients were older than 20 except for Case 7. Despite reports of "classic ITP" having a female-to-male ratio of 2:1 in the general population, the majority of patients in our series were male (63%) as were 47% in the published literature.

Review of the previously published cases indicates that new-onset ITP following OLT may occur either early (i.e., within the first 3 months) or later following OLT. The majority of our patients developed ITP more than 1 year post-OLT, with a mean of 5.4 years from OLT to ITP presentation. Some authors speculate that "early-onset" ITP post-OLT may occur due to passive transfer of antibody from the donor to recipient or other transfusion related phenomenon.^{5,33} In addition, reactivation of CMV, EBV, or varicella infection in the early post-transplant setting when patients are receiving high levels of immunosuppression may increase the risk of ITP. However, we only had 1 patient with early-onset ITP, and there was no evidence of viral infection in this patient (Table 1).

Standard medical treatment for ITP includes high-dose corticosteroids, immunosuppression, and IVIg, as well as plasmapheresis.^{2,6} The intent of these treatments is to reduce the level of circulating antiplatelet antibodies. Data from Stasi et al. suggests that up to 35% of ITP patients receiving prednisone alone will require additional therapy for persistent thrombocytopenia.

TABLE 3. Published Reports of New-Onset ITP Following Liver Transplantation

Reference No.	Age (y)/Sex, Liver Disease	Time to ITP Onset	Initial/Nadir Platelet Count	ITP Treatment	Comments
12	5/F, biliary atresia	1 day	18,000	IVIg	Known ITP pre-OLT treated with IVIG, suspected CMV induced; recurrence 4 and 8 mo later treated with IVig, then no recurrence for 77 months post-OLT.
33	52/M, HCV	1 day	2,000	IVIg	Donor died from hemorrhage from ITP; no recurrence at 24 mo.
32	43/F,PBC	2 days	12,000	Steroids and ATGAM for rejection	AlloAb from donor; recipients of kidneys also developed ITP; no recurrence at 1-y follow-up.
5	47/F, PBC	2 days	2000	Plasma exchange, IVIG, emergent re-OLT	Donor with ITP and prior splenectomy with recurrence.Donor death from ICH, plts 5,000; no recurrence at POD 20.
49	15/F, idiopathic acute liver failure	6 days	17,000	Splenectomy	Required re-OLT at 3 wk for severe rejection; no recurrence at 36-mo follow-up
49	52/M, cryptogenic cirrhosis	14 days	3,000	Methylprednisolone, IVIG, splenectomy	No recurrence at 32-mo. follow-up.
23	46/M, HCV	19 days	3,000	IVIg	VZV with acute zoster; no recurrence at 2 mo.
24	20/M, fulminant HBV	32 days	6,000	Steroids, ganciclovir × 4 weeks	Active CMV; no recurrence at 13-mo follow-up.
11	13/F, hepatoblastoma	2 mo	<10,000	Anti-D Ab IV	HHV-6B DNA+, required doxorubicin and cisplatin; no recurrence at 6-mo follow-up.
12	0.6/F, biliary atresia	3 mo	7,000	IVIg	Donor with prior ITP; no recurrence at 50-mo follow-up.
25	58/M, HBV, HCV, HCC	6 mo	3,000	Prednisolone, IVIG, splenectomy	Parvovirus B19+; no recurrence at 1- y follow-up.
40	56/M, PSC	9 mo	<10,000	Prednisone, splenectomy	On Bactrim at presentation; no recurrence at 9-mo follow-up.
12	2/M,biliary atresia	13 mo	5,000	IVIg	ITP relapse 7 mo later.
50	2/F, biliary atresia	14 mo	7,000	IVIg	3 mo prior to ITP had mumps meningitis, with concomitant neutropenia; no reported follow-up.
39	41/F,PBC	15 mo	65,000	Prednisone, IVIG	Platelets 142,000 at 4 mo.
13	12/M,Wilson's disease	24 mo	5,000	Prednisone, IVIG, lowered tacrolimus dose	Parvovirus B19+; no recurrence at 12 mo.
38	62/F,PBC	24 mo	15,000	Prednisone	No recurrence at 16-mo follow-up.
40	49/F,PBC	39 mo	15,000	Prednisone, splenectomy	No recurrence at 1-y follow-up.
51	74/M, HCV	4.5 y	8,000	Steroids, IVIG, splenectomy	Treated post-OLT with IFN and ribavirin; no recurrence at 44 mo.

Abbreviations: F, female; M, male; PBC, primary biliary cirrhosis; ATG, antithymocyte globulins; AlloAb, alloantibodies; ICH, intracerebral hemorrhage; plts, platelets; POD, postoperative day; VZV, varicella-zoster virus; anti-D Ab IV, red blood cell antigen D antibody; HHV-6B, human herpes virus 6B; HBV, hepatitis B virus; HCC, hepatocellular carcinoma; PSC, primary sclerosing cholangitis; IFN, interferon.

- **Initial evaluation of unexplained platelet count < 50,000 cells/ml**
 - Repeat complete blood count with peripheral smear to exclude platelet clumping or hemolysis/microangiopathic hemolytic anemia
 - Review all prescribed and over the counter medications
 - Hospitalize if signs of bleeding or platelet count <10,000 cells/ml for further evaluation and treatment
- **Diagnostic Testing**
 - Serologic evaluation
 - CMV PCR, EBV PCR, and HIV Ab if suspected
 - Additional viral serologies as clinically indicated (e.g. varicella titer, parvovirus B19 PCR, HSV PCR)
 - Cryoglobulins, serum and urine electrophoresis
 - Exclude DIC and sepsis
 - Anti-platelet antibody testing *
 - Heparin induced thrombocytopenia (HIT) antibody if recent heparin exposure.
 - Consider bone marrow biopsy to evaluate megakaryocyte reserves and exclude lymphoproliferative disorder/ malignancy **
 - Consider CT scan of chest/abdomen/pelvis for PTLD**
- **Initial Treatment**
 - Bed rest and hematology consult
 - Eliminate other myelotoxic medications (e.g. trimethoprim-sulfamethoxazole, ganciclovir, ranitidine, mycophenolate)
 - Consider changing immunosuppression if calcineurin related TTP/ITP variant suspected (e.g. switch from tacrolimus to sirolimus)
 - Oral prednisone 1mg/kg or dexamethasone 40 mg PO for 4 days or Intravenous solumedrol 250 mg q d if active mucocutaneous or GI/GU bleeding
 - Intravenous immunoglobulin 1 g/kg for 1 to 3 days (Monitor creatinine daily; platelet response may take up to 7 days)
 - Transfuse platelets only if active mucocutaneous bleeding, intracranial bleeding, or planned procedure.
 - If platelets remain < 10,000 cells/ml or persistent mucocutaneous bleeding consider salvage therapy per hematology consultant
 - Rituximab infusion (Response may range from 2 weeks to 4 months) 375 mg/m² weekly for 4 weeks
 - Cyclophosphamide (Response 6-8 weeks) 1 gm/m² at 4 week intervals
 - Vincristine (Response 1-3 weeks) 1-2 mg weekly for 4-6 weeks
 - Urgent splenectomy if critical bleeding (e.g. intracranial or intraocular hemorrhage), persistent bleeding with transfusion requirement, or refractory ITP ***
- *Up to 50% of patients with ITP have undetectable anti-platelet antibodies and anti-platelet antibodies may be detected in patients with hypersplenism.
- **If splenectomy is considered, preoperative bone marrow biopsy and CT scanning to evaluate for lymphoma/PTLD is recommended.
- *** Preoperative immunization against *Streptococcus pneumoniae*, *Hemophilus influenzae b*, and *Neisseria meningitidis* is recommended.
- Treatment of ITP should be individualized and provided in consultation with an experienced hematologist.

nia.⁴³ Rituximab has been proposed as a salvage therapy for refractory ITP patients who are poor candidates for splenectomy.⁸⁻¹⁰ Four of the patients in the current series were treated with rituximab for refractory ITP, but only 1 achieved a long-term remission. Although rituximab infusions are generally well tolerated, the most frequent complication of this treatment is a hypersensitivity infusion reaction as well as increased susceptibility to infection due to severe B-cell depletion.^{1,44} Caution must also be used when giving rituximab to patients with active or prior hepatitis B infection.^{45,46} Case 6 appeared to have an extreme reaction to rituximab with a severe rash and mucosal blistering, which has rarely been reported with rituximab use. The hazards of IVIg including infusion reactions and nephrotoxicity should also be borne in mind when using this agent in OLT recipients as was seen in Case 4.⁴⁷

Based upon our experience and that reported in the literature, an algorithm for the evaluation and management of OLT recipients with severe thrombocytopenia and suspected ITP is presented in Figure 3. The majority of OLT recipients with thrombocytopenia post-OLT will improve with medication changes and expectant management. However, patients with persistent and unexplained severe thrombocytopenia (i.e., platelet count <10,000 cells/mL) should be carefully monitored and hospitalized for further evaluation and treatment if they develop bleeding. Consultation with an experienced hematologist is recommended early on, due to the complexity of OLT recipients. In addition to discontinuing potentially myelotoxic drugs, viral and other diagnostic serologies should be ordered. A computed tomography scan of the abdomen and chest should be considered for possible posttransplant lymphoproliferative disorder, as well as a bone marrow biopsy to exclude underlying hematological malignancy. Medical therapy can be initiated in a stepwise manner as proposed in nontransplant ITP patients. Infusion of platelets should be guided by the presence of active bleeding or planned procedures rather than a specific platelet count. Although splenectomy is considered a definitive therapy for chronic refractory ITP, this procedure carries substantial risk, especially in immunosuppressed OLT recipients. A recent case series of 10 patients who underwent splenectomy following OLT revealed a 40% mortality during short-term follow-up.⁴⁸ In our study, 3 OLT recipients eventually required splenectomy for refractory ITP as well as 2 of the patients with ITP pre-OLT. Fortunately, all 5 of these patients have done well

Figure 3. Suggested algorithm for evaluation of thrombocytopenia in liver transplant recipients. Treatment of ITP should be individualized and provided in consultation with an experienced hematologist. PCR, polymerase chain reaction; HIV Ab, human immunodeficiency virus antibody; HSV, herpes simplex virus; DIC, disseminated intravascular coagulation; CT, computed tomography; PTLD, posttransplant lymphoproliferative disorder; TTP, thrombotic thrombocytopenic purpura; PO, per os, by mouth orally; q d, every day; GI/GU, gastrointestinal/genitourinary.

without significant bleeding or infectious complications and no recurrence of ITP during follow-up.

In conclusion, thrombocytopenia is common among OLT recipients. However, severe unexplained thrombocytopenia remote from OLT is less common and raises the possibility of new-onset ITP vs. sepsis, viral infection, drug effects, or malignancy. A complete battery of viral and diagnostic studies should be performed in patients with persistent unexplained thrombocytopenia. Our data and that of others demonstrate that approximately 50% of patients with new-onset ITP post-OLT may respond to conventional medical therapy and/or adjustments in immunosuppression. Although rituximab appears to be safe in selected OLT recipients with persistent ITP, long-term disease remission is uncommon. Splenectomy should be reserved for OLT recipients with refractory ITP or evidence of life-threatening bleeding. Although the mechanism of early- and late-onset ITP post-OLT remains unclear, a heightened awareness of this disease entity in OLT recipients with unexplained thrombocytopenia is advised.

REFERENCES

1. Stasi R, Provan D. Management of immune thrombocytopenic purpura in adults. *Mayo Clin Proc* 2004;79:504-522.
2. Chong BH, Ho SJ. Autoimmune thrombocytopenia. *J Thromb Haemost* 2005;3:1763-1772.
3. British Committee for Standards in Haematology General Haematology Task Force. Guidelines for the investigation and management of idiopathic thrombocytopenic purpura in adults, children, and in pregnancy. *Br J Haematol* 2003;120:574-596.
4. George JN, Woolf SH, Raskob GE, et al. Idiopathic thrombocytopenic purpura: A practice guideline developed by explicit methods for the American Society of Hematology. *Blood* 1996;88:3-40.
5. Friend PJ, McCarthy LJ, Filo RS, Leapman SB, Pescovitz MD, Lumeng L, et al. Transmission of idiopathic (autoimmune) thrombocytopenic purpura by liver transplantation. *N Engl J Med* 1990;323:807-811.
6. Cines DB, Blanchette VS. Immune thrombocytopenic purpura. *N Engl J Med* 2002;346:995-1008.
7. Chatzipetrou MA, Tsaroucha AK, Weppeler D, Pappas PA, Kenyon NS, Nery JR, et al. Thrombocytopenia after liver transplantation. *Transplantation* 1999;67:702-706.
8. Narang M, Penner JA, Williams D. Refractory autoimmune thrombocytopenic purpura: responses to treatment with a recombinant antibody to lymphocyte membrane antigen CD20 (rituximab). *Am J Hematol* 2003;74:263-267.
9. Koulova L, Alexandrescu D, Dutcher JP, O'Boyle KP, Eapen S, Wiernik PH. Rituximab for the treatment of refractory idiopathic thrombocytopenic purpura (ITP) and thrombotic thrombocytopenic purpura (TTP): report of three cases. *Am J Hematol* 2005;78:49-54.
10. Braendstrup P, Bjerrum OW, Nielsen OJ, Jensen BA, Clausen NT, Hansen PB, et al. Rituximab chimeric anti-CD20 monoclonal antibody treatment for adult refractory idiopathic thrombocytopenic purpura. *Am J Hematol* 2005;78:275-280.
11. Rosoff PM, Tuttle-Newhall E, Treem WR. Successful treatment of immune thrombocytopenic purpura with anti-D antibody following a cadaveric liver transplant for hepatoblastoma. *Med Pediatr Oncol* 2003;40:402-404.
12. Takatsuki M, Uemoto S, Kurokawa T, Koshihara T, Inomata Y, Tanaka K. Idiopathic thrombocytopenic purpura after a living-related liver transplantation. *Transplantation* 1999;67:479-481.
13. Assy N, Rosenthal E, Hazani A, Etzioni A, Baruch Y. Human parvovirus B19 infection associated with idiopathic thrombocytopenic purpura in a child following liver transplantation. *J Hepatol* 1997;27:934-936.
14. Randoux O, Gambiez L, Navarro F, Declercq N, Labalette M, Dessaint JP, Pruvot FR. Post-liver transplantation thrombocytopenia: a persistent immunologic sequestration? *Transplant Proc* 1995;27:1710-1711.
15. Plevak DJ, Halma GA, Forstrom LA, Dewanjee MK, O'Connor MK, Moore SB, et al. Thrombocytopenia after liver transplantation. *Transplant Proc* 1988;20:630-633.
16. Tredger JM, Brown NW, Adams J, Gonde CE, Dhawan A, Rela M, Heaton N. Monitoring mycophenolate in liver transplant recipients: toward a therapeutic range. *Liver Transpl* 2004;10:492-502.
17. Danesi R, Del Tacca M. Hematologic toxicity of immunosuppressive treatment. *Transplant Proc* 2004;36:703-704.
18. Rerolle JP, Akposso K, Lerolle N, Mougnot B, Ponnelle T, Rondeau E, Sraer JD. Tacrolimus-induced hemolytic uremic syndrome and end-stage renal failure after liver transplantation. *Clin Transplant* 2000;14:262-265.
19. Singh N, Gayowski T, Marino IR. Hemolytic uremic syndrome in solid-organ transplant recipients. *Transpl Int* 1996;9:68-75.
20. Abraham KA, Little MA, Dorman AM, Walshe JJ. Hemolytic-uremic syndrome in association with both cyclosporine and tacrolimus. *Transpl Int* 2000;13:443-447.
21. Warkentin TE, Greinacher A. Heparin-induced thrombocytopenia: recognition, treatment, and prevention: the Seventh ACCP Conference on Antithrombotic and Thrombolytic Therapy. *Chest* 2004;126(Suppl):311S-337S.
22. Scaradavou A. HIV-related thrombocytopenia. *Blood Rev* 2002;16:73-76.
23. Singh N, Gayowski T, Yu VL. Herpes zoster-associated idiopathic thrombocytopenic purpura in a liver transplant recipient: a case report and overview. *Transpl Int* 1995;8:58-60.
24. Arnold JC, Heilig B, Otto G, Kommerell B, Theilmann L. Cytomegalovirus-induced severe thrombocytopenia after liver transplantation. *Transplantation* 1993;56:1286-1288.
25. Kita Y, Harihara Y, Hirata M, Sano K, Kubota K, Takayama T, et al. Splenectomy for idiopathic thrombocytopenic purpura after living-related liver transplantation. *Transplantation* 2000;70:553-555.
26. Pockros PJ, Duchini A, McMillian R, Nyberg LM, McHutchison J, Viernes E. Immune thrombocytopenic purpura in patients with chronic hepatitis C virus infection. *Am J Gastroenterol* 2002;97:2040-2045.
27. Bauduer F, Marty F, Larrouy M, Ducout L. Immunologic thrombocytopenic purpura as presenting symptom of hepatitis C infection. *Am J Hematol* 1998;57:338-340.
28. Pawlotsky JM, Bouvier M, Fromont P, Deforges L, Duval J, Dhumeaux D, Bierling P. Hepatitis C virus infection and autoimmune thrombocytopenic purpura. *J Hepatol* 1995;23:635-639.
29. Sagir A, Wettstein M, Heintges T, Haussinger D. Autoimmune thrombocytopenia induced by PEG-IFN-alpha2b plus ribavirin in hepatitis C [letter]. *Dig Dis Sci* 2002;47:562-563.
30. Bussel JB. Overview of idiopathic thrombocytopenic purpura: new approach to refractory patients. *Semin Oncol* 2000;27(Suppl 12):91-98.
31. Kajihara M, Kato S, Okazaki Y, Kawakami Y, Ishii H, Ikeda Y, Kuwana M. A role of autoantibody-mediated platelet

- destruction in thrombocytopenia in patients with cirrhosis. *Hepatology* 2003;37:1267-1276.
32. West KA, Anderson DR, McAlister VC, Hewlett TJ, Belitsky P, Smith JW, Kelton JG. Alloimmune thrombocytopenia after organ transplantation. *N Engl J Med* 1999;341:1504-1507.
 33. de la Torre AN, Fisher A, Wilson DJ, Harrison J, Koneru B. A case report of donor to recipient transmission of severe thrombocytopenia purpura. *Transplantation* 2004;77:1473-1474.
 34. Chalmers EA, Chan Lam D, Holden RJ, Fitzimons EJ. Familial primary biliary cirrhosis and autoimmune thrombocytopenia. *Scott Med J* 1987;32:152.
 35. Mizukami Y, Ohhira M, Matsumoto A, Murazumi Y, Murazumi K, Ohta H, et al. Primary biliary cirrhosis associated with idiopathic thrombocytopenic purpura. *J Gastroenterol* 1996;31:284-288.
 36. Bassendine MF, Collins JD, Stephenson J, Saunders P, James OF. Platelet associated immunoglobulins in primary biliary cirrhosis: a cause of thrombocytopenia? *Gut* 1985;26:1074-1079.
 37. Feistauer SM, Penner E, Mayr WR, Panzer S. Target platelet antigens of autoantibodies in patients with primary biliary cirrhosis. *Hepatology* 1997;25:1343-1345.
 38. Fickert P, Trauner M, Sill H, Hinterleitner TA, Stauber RE. Successful steroid treatment of idiopathic thrombocytopenic purpura after orthotopic liver transplantation for primary biliary cirrhosis. *Am J Gastroenterol* 1998;93:1985-1986.
 39. Yoshida E, Mandl LA, Erb SR, Buckley AB, Scudamore CH, Buskard NA. Idiopathic thrombocytopenic purpura in a liver transplant recipient with previous primary biliary cirrhosis. *J Clin Gastroenterol* 1997;24:274-275.
 40. Kuo PC, Lewis WD, Dzik W, Jenkins RL. Immune thrombocytopenic purpura following orthotopic liver transplantation. *Clin Transplantation* 1993;7:43-46.
 41. Sakai M, Egawa N, Sakamaki H, Sanaka M, Yuyang T, Kamisawa T, et al. Primary sclerosing cholangitis complicated with idiopathic thrombocytopenic purpura. *Intern Med* 2001;40:1209-1214.
 42. McCarthy LJ, Dzik W. Immune thrombocytopenic purpura [author reply]. *N Engl J Med* 2002;347:450.
 43. Stasi R, Stipa E, Masi M, Cecconi M, Scimo MT, Oliva F, et al. Long term observation of 208 adults with chronic idiopathic thrombocytopenic purpura. *Am J Med* 1995;98:436-442.
 44. McLaughlin P, Grillo-Lopez AJ, Link BK, Levy R, Czuczman MS, Williams ME, et al. Rituximab chimeric anti-CD20 monoclonal antibody therapy for relapsed indolent lymphoma: half of patients respond to a four-dose treatment program. *J Clin Oncol* 1998;16:2825-2833.
 45. Dervite I, Hober D, Morel P. Acute hepatitis B in a patient with antibodies to hepatitis B surface antigen who was receiving rituximab. *N Engl J Med* 2001;344:68-69.
 46. Sarrecchia C, Cappelli A, Aiello P. HBV reactivation with fatal fulminating hepatitis during rituximab treatment in a subject negative for HBsAg and positive for HBsAb and HBcAb. *J Infect Chemother* 2005;11:189-191.
 47. Sati HI, Ahya R, Watson HG. Incidence and associations of acute renal failure complicating high-dose intravenous immunoglobulin therapy. *Br J Haematol* 2001;113:556-557.
 48. Troisi R, Hesse UJ, Decruyenaere J, Morelli MC, Palazzo U, Pattyn P, et al. Functional, life threatening disorders and splenectomy following liver transplantation. *Clin Transplant* 1999;13:380-388.
 49. Altaca G, Scigliano E, Guy SR, Sheiner PA, Reich DJ, Schwartz ME, et al. Persistent hypersplenism early after liver transplant: the role of splenectomy. *Transplantation* 1997;64:1481-1483.
 50. Arakawa Y, Matsui A, Sasaki N, Nakayama T. Agranulocytosis and thrombocytopenic purpura following measles infection in a living-related orthotopic liver transplantation recipient. *Acta Paediatr Jpn* 1997;39:226-229.
 51. Lauro A, Marino IR, Doria C, Panarello G, Gruttadauria S. Hepatitis C virus recurrence and idiopathic thrombocytopenic purpura after liver transplantation in adult patients: the role of splenectomy. *Transplantation* 2005;79:738.