

Utility of Extended Pattern Prostate Biopsies for Tumor Localization

Pathologic Correlations After Radical Prostatectomy

Ryan T. Schulte, MD¹
 David P. Wood, MD¹
 Stephanie Daignault, MS¹
 Rajal B. Shah, MD^{1,2}
 John T. Wei, MD, MS¹

¹ Department of Urology, University of Michigan Medical School, Ann Arbor, Michigan.

² Department of Pathology, University of Michigan Medical School, Ann Arbor, Michigan.

BACKGROUND. Focal targeted therapy has been proposed as a potential treatment for localized prostate cancer in an attempt to reduce morbidity. However, these modalities rely heavily on accurate tumor localization to achieve total tumor ablation. In the current study, we sought to examine the ability of contemporary extended pattern prostate biopsy to predict the location of tumors.

METHODS. A total of 281 men with prostate cancer detected via a standardized extended pattern biopsy template with at least 12 cores and who subsequently underwent radical prostatectomy were evaluated. Tumor location on biopsy, stratified by laterality and by site (apex vs mid-base prostate), was compared with corresponding locations on the prostatectomy specimen. Generalized estimating equation models were developed to assess the effects of clinical variables on pathologic agreement between biopsy and prostatectomy specimens.

RESULTS. Of the 281 prostate biopsies, the positive predictive value (PPV) of right and left needle biopsy was high at 97.3% and 96.7%, respectively. However, the negative predictive value (NPV) was low at 24.7% and 31.3%, respectively. When more specific locations were considered, the NPV improved at the apex. However, this came at a cost to the PPV. Tumor focality on prostatectomy specimen was the only clinical feature found to be significantly and consistently related to pathologic agreement.

CONCLUSIONS. Contemporary extended pattern prostate biopsy, although able to diagnose cancers, fails to provide reliable localization of tumors to specific areas of the prostate. Focal therapy, which relies heavily on localization, should only be performed with this caveat in mind. *Cancer* 2008;113:1559-65. © 2008 American Cancer Society.

KEYWORDS: prostate neoplasms, prostate biopsy, localization, focal therapy.

See editorial on pages 1500-1, this issue.

Supported by NIH EDRN 1U01CA113913; NIH SPORE CA069568.

John Wei is a funded research investigator and consultant for Envisioneering, Inc.

Address for reprints: John T. Wei, MD, MS, University of Michigan, Department of Urology, Rm 1013 Women's Trailer SPC 5759, 1500 E. Medical Center Drive, Ann Arbor, MI 48109-0330; Fax: 734-936-9536; E-mail: jtwei@umich.edu

Received February 1, 2008; revision received March 28, 2008; accepted April 15, 2008.

An estimated 218,890 men were newly diagnosed with prostate cancer in the United States in 2007, accounting for approximately 29% of all newly diagnosed cancer in American men.¹ Despite advances in standard treatments for localized prostate cancer, radical prostatectomy, external beam radiation, and brachytherapy are still associated with significant adverse effects on health-related quality of life.^{2,3} Because of this associated morbidity, several investigators have explored targeted focal therapy with cryoablation or high-intensity focused ultrasound as a potential treatment for localized prostate cancer.⁴⁻⁶ In theory, targeted focal therapy would treat only the specific site or side of the prostate with the cancer in an attempt to minimize tissue injury and subsequent morbidity. However, for these targeted focal therapies to be effective in total tumor

ablation, it is essential to accurately localize neoplastic lesions within the prostate with a high degree of reliability.

Transrectal ultrasound (TRUS)-guided biopsy of the prostate currently remains the standard of care for the initial diagnosis of prostate cancer. Over the years TRUS-guided prostate biopsy techniques have evolved from the traditional sextant pattern into a variety of extended pattern templates in which a greater number of cores are being obtained. Several studies have shown that the use of an extended pattern template increases the likelihood of detecting prostate cancer,^{7,8} but very few studies have investigated how well prostate biopsies predict tumor location to specific areas of the prostate. Despite this, a recent survey of French and Belgian urologists reported that 73% used prostate biopsies for tumor localization.⁹ Therefore, we examined the ability of contemporary extended pattern prostate biopsy technique to predict location of tumor based on radical prostatectomy specimens. Secondly, we sought to identify determinants of pathologic agreement between needle biopsy and radical prostatectomy findings.

MATERIALS AND METHODS

As part of an institutional review board-approved prospective cohort database study, 557 men were identified who underwent both prostate biopsy and radical prostatectomy at a tertiary care hospital. Of these 557 patients, 281 men underwent a standardized extended pattern prostate biopsy template in which at least 12 cores were obtained. All eligible biopsies were performed between 2002 and 2007. For each biopsy, a standardized 12-core extended pattern prostate biopsy template was used with laterally directed peripheral zone cores including the anterior horns in addition to the standard sextant technique.¹⁰ The total number of biopsies taken was determined clinically by the individual urologist. In some cases, additional cores were obtained because of abnormal lesions on ultrasound or palpable nodules. All men included in the analysis subsequently went on to have a radical prostatectomy. Several men had multiple biopsies such that there were a total of 330 prostate biopsies in the 281 patients. In men who had more than 1 biopsy performed, only the biopsy closest to the time of prostatectomy was used for analysis, and thus 281 biopsies were included for analysis.

Radical prostatectomy specimens were examined by a genitourinary pathologist using a standardized protocol. The specimens underwent a standardized

evaluation that includes tumor mapping by zones (right apex, left apex, right mid-base, left mid-base), evaluation of prostatectomy multifocality, maximal tumor dimensions, evaluation of capsular penetration, seminal vesicle involvement, surgical margins, and lymph node status. Each specimen was then given a pathologic TNM stage. This data was then entered into the prostate cancer database at our institution. Clinical data, including age, race, pre-biopsy prostate-specific antigen (PSA), digital rectal examination results, clinical stage, prostate size estimated by transrectal ultrasonography, total number of needle cores, and the number of positive needle cores were obtained from our prostate cancer database. Pathological findings, including gland weight, cancer status, Gleason score, location of tumors, and maximum diameter of the largest tumor foci were also obtained from our prostate cancer database.

For statistical analysis, tumor location on all biopsies was first stratified by laterality: right versus left. Tumor location was then further substratified by specific site: right apex, left apex, right mid-base, left mid-base. As there were an insufficient number of cases where needle cores were targeted at the transition zone, no attempt was made to evaluate transition zone tumors separately. Tumor locations on biopsy were then compared with the corresponding location from the prostatectomy specimens and were used to calculate with 95% confidence intervals (CI) the positive predictive value (PPV) and negative predictive value (NPV) of prostate biopsy for each side and specific site. Logistic regression models using general estimating equations were constructed to determine the effect of various clinicopathologic variables on the pathologic agreement of tumor location between prostate biopsy and radical prostatectomy specimens. These same analyses were then also performed on a subset of low-risk patients ($n = 64$) (clinical stage T1c, PSA <10 , Gleason score <6 , and unilateral positive biopsy) in whom targeted focal therapy may be more likely considered. To determine which clinical factors available for treatment planning are associated with pathologic agreement, we repeated our analyses and included only preoperative factors (PSA, clinical stage, biopsy Gleason score, ultrasound prostate volume, number of positive cores, total number of cores). All statistical analyses were performed using SAS (SAS Institute, Cary, NC) with a P -value of $<.05$ considered statistically significant.

RESULTS

Table 1 shows the population of the 281 men in the study and their preoperative demographic and clinical

TABLE 1
Preoperative Patient Demographics and Clinical Characteristics

Clinical Characteristic	No. (%)
Mean age, (SD)	59.2 (7.6)
Race	
Caucasian	225 (84.3)
African American	26 (9.7)
Other	16 (6.0)
Preoperative PSA, ng/mL	
0-4	50 (17.9)
4-10	185 (66.1)
>10	45 (16.1)
Clinical stage	
T1c	216 (77.1)
T2a	48 (17.1)
≥T2b	16 (5.7)
Biopsy Gleason score	
2-6	117 (42.2)
7	136 (49.1)
8-10	24 (8.7)

SD indicates standard deviation; PSA, prostate-specific antigen.

TABLE 2
Positive and Negative Predictive Values of Prostate Biopsies to Tumor Location

Biopsy Location	Entire Population (N=281)		Low-Risk Population* (n=64)	
	PPV (95% CI)	NPV (95% CI)	PPV (95% CI)	NPV (95% CI)
Right	97.3% (93.8-99.1)	24.7% (16.4-34.8)	100.0% (88.1-100)	25.7% (12.5-43.3)
Left	96.7% (93.3-98.7)	31.3% (20.6-43.8)	91.2% (76.3-98.1)	36.7% (19.9-56.1)
Right mid-base	93.8% (88.8-97.0)	28.6% (20.7-37.6)	90.9% (70.8-98.9)	28.6% (15.7-44.6)
Left mid-base	91.2% (86.1-94.9)	33.0% (23.8-43.3)	75.0% (53.3-90.2)	40.0% (24.9-56.7)
Right apex	47.4% (37.2-57.8)	65.4% (58.0-72.3)	53.3% (26.7-78.7)	69.4% (54.6-81.8)
Left apex	50.8% (41.9-59.6)	64.4% (56.2-72.1)	53.3% (26.6-78.7)	73.5% (58.9-85.1)

PPV indicates positive predictive value; CI, confidence interval; NPV, negative predictive value.
*Clinical stage T1c, prostate-specific antigen <10, Gleason score <6, unilateral positive biopsy.

cal characteristics. The mean age was 59.2 years old, with the majority of patients being Caucasian, and having nonpalpable disease and serum PSA <10 ng/mL.

The median number of total cores obtained with each biopsy was 12 with a range of 12 to 34. At the apex, a median of 4 cores were obtained with a range

TABLE 3
Relation of Clinicopathologic Variables and Pathological Agreement Between Prostate Biopsy and Prostatectomy Specimens

Clinical Variable	Right vs Left Biopsy		Specific Site of Biopsy	
	OR (95% CI)	P	OR (95% CI)	P
Age		.19		.61
Per year of age	1.0 (1.0-1.0)		1.0 (1.0-1.0)	
PSA (ng/mL)		.33		.47
0-4	0.7 (0.4-1.2)		1.0 (0.5-1.5)	
4.1-10	1.0 (1.0-1.0)		1.0 (1.0-1.0)	
>10	0.7 (0.4-1.3)		0.8 (0.5-1.2)	
Clinical stage		.31		.28
T1c	1.0 (1.0-1.0)		1.0 (1.0-1.0)	
≥T2a	1.3 (0.8-2.2)		1.2 (0.9-1.7)	
Biopsy Gleason score		.03		.06
2-6	1.0 (1.0-1.0)		1.0 (1.0-1.0)	
7	1.8 (1.2-2.8)		1.3 (1.0-1.8)	
8-10	1.8 (0.8-4.3)		1.7 (1.0-2.8)	
No. of cores		.10		.06
12	1.6 (0.9-2.6)		1.4 (1.0-2.0)	
>12	1.0 (1.0-1.0)		1.0 (1.0-1.0)	
Multifocality		<.01		.02
Absence	2.5 (1.3-4.7)		1.5 (1.0-2.1)	
Size of largest tumor		.04		.65
Per cm	1.3 (1.0-1.7)		1.0 (0.8-1.2)	
Gland weight		.98		.80
Per gram	1.0 (1.0-1.0)		1.0 (1.0-1.0)	

OR indicates odds ratio; CI, confidence interval; PSA, prostate-specific antigen.

of 2 to 10, and at the prostate mid-base, a median of 8 cores were obtained with a range of 4 to 23.

Table 2 displays the positive predictive value and negative predictive values of prostate needle biopsy to predict the location of cancer first by laterality (right vs left) and then further by specific site (right apex, left apex, right mid-base, left mid-base). Of the 281 prostate biopsies in the entire study population, the PPV of right and left needle biopsy was high at 97.3% and 96.7%, respectively. However, the NPV was low at 24.7% and 31.3%. When more specific locations were considered, the NPV improved at the right and left apex at 65.4% and 64.4%, respectively. However, this came at a cost to the PPV at the right and left apex, at 47.4% and 50.8%, respectively. Analysis of the subset of low-risk patients (clinical stage T1c, PSA <10, Gleason score <6, and unilateral positive biopsy) in whom targeted focal therapy would likely be more applicable demonstrated similar results (Table 2). Right and left needle biopsy as well as the right and left mid-base showed a high PPV and low NPV, but the right and left apex displayed a low PPV and high NPV.

Table 3 summarizes the odds ratios (ORs) and the 95% CIs in the entire 281-patient study popula-

TABLE 4
Relation of Clinicopathologic Variables and Pathological Agreement
Between Prostate Biopsy and Prostatectomy Specimens in Low-Risk*
Patient Population

Clinical Variable	Right vs Left Biopsy		Specific Site of Biopsy	
	OR (95% CI)	P	OR (95% CI)	P
Age		.10		.58
Per year of age	1.0 (0.9-1.0)		1.0 (1.0-1.1)	
No. of biopsies		.07		.17
12	1.8 (0.9-3.3)		1.7 (0.8-3.7)	
>12	1.0 (1.0-1.0)		1.0 (1.0-1.0)	
Multifocality		<.01		.01
Absence	7.8 (2.5-24.2)		2.8 (1.3-6.2)	
Size of largest tumor		.11		.49
Per cm	1.5 (0.9-2.3)		0.8 (0.5-1.3)	
Gland weight		.21		.68
Per gram	1.0 (1.0-1.0)		1.0 (1.0-1.0)	

OR indicates odds ratio; CI, confidence interval.

*Clinical stage T1c, prostate-specific antigen <10, Gleason score <6, unilateral positive biopsy.

tion of the effect of various clinicopathologic variables on the pathologic agreement of tumor location between radical prostatectomy specimens and prostate biopsy, first by right or left laterality of biopsy and then by specific site. When considering right versus left prostate biopsy, higher grade cancers ($P = .03$), larger tumor size ($P = .04$), and absence of multifocality on prostatectomy specimen ($P < .01$) significantly increased the agreement between biopsy and prostatectomy tumor location. When specific site of biopsy was considered, only tumor unifocality on prostatectomy ($P = .02$) significantly increased the agreement between tumor location on prostatectomy and needle biopsy.

Table 4 shows the ORs and 95% CIs in the subset population of low-risk patients of the effect of various clinicopathologic variables on the pathologic agreement between radical prostatectomy specimens and prostate biopsy, again first by right or left laterality of biopsy and then by specific site. Of all the variables evaluated, only the absence of multifocality significantly increased the agreement both in the model including right versus left biopsy ($P < .01$) as well as in the model including specific site of biopsy ($P = .01$).

The impact of using only preoperative needle biopsy information (ultrasound prostate volume, number of positive cores, total number of cores, biopsy Gleason score) to predict pathologic agreement between radical prostatectomy and prostate biopsy was also examined. When considering right versus left prostate biopsy in the overall population, having only 1 positive biopsy core for cancer was associated

with lower pathologic agreement (OR, 0.3; 95% CI, 0.2-0.5) ($P < .0001$) compared with having more than 1 positive core. A similar association was observed when specific sites of biopsy were considered (OR, 0.6; 95% CI, 0.4-0.8) ($P = .002$). However, in the subset population of low-risk patients, none of the preoperative clinical factors predicted pathologic agreement.

Tumor multifocality was present on radical prostatectomy specimen in 217 (77.7%) of the 281 total men. In addition, 158 (56.2%) of the 281 total men were identified with only unilateral disease on prostate biopsy; however, only 44 (40.4%) of these 158 were found to have true unilateral disease after examination of radical prostatectomy specimens.

DISCUSSION

Template-driven TRUS-guided prostate biopsy has undergone a significant evolution of techniques through the years. The traditional sextant pattern biopsy as first described in 1989¹¹ was the standard protocol for many years. However, several studies have recognized that the negative predictive value of sextant biopsy alone is relatively poor.¹²⁻¹⁵ This high number of false-negatives associated with sextant biopsy is likely because of its failure to adequately sample the prostate, as cancer detection has been shown to be a function of the number of needle cores taken and the direction of the needle cores. Multiple studies have demonstrated that contemporary biopsy methods with 10 to 12 cores and more laterally directed samples result in a higher yield of cancer detection when compared with the classic sextant biopsy template.^{7,8,16,17} These studies clearly illustrate our ever improving ability to detect cancer, but empirical data examining localization of prostate tumors with biopsy is sparse and has been limited to sextant biopsies.

Gregori et al¹⁸ evaluated the accuracy of sextant biopsy in predicting the site of tumor location in 289 patients with clinically localized prostate cancer treated by radical perineal prostatectomy. Overall, 66.7% of the men had a unilateral positive biopsy. However, of these men with a unilateral positive biopsy, only 33.1% had cancer actually confined to 1 side of the gland on radical prostatectomy specimen. Similarly, Scales et al¹⁹ evaluated 384 men with only 1 or 2 positive cores and unilateral disease on biopsy with a minimum of 6 cores and found that only 28.4% actually had unilateral disease based on final pathologic examination of the radical prostatectomy specimens. Our current study confirms these previous reports and extends prior observation to include contempo-

ary 12-core template-driven extended needle biopsy. Overall, 56.2% of our patients displayed only unilateral disease on prostate biopsy. However, after evaluation of the radical prostatectomy specimen, only 40.4% of those with unilateral disease on biopsy actually had true unilateral disease. In addition, the poor negative predictive value of right and left biopsy on tumor laterality of 24.7% and 31.3%, respectively, further supports the limited reliability of prostate biopsy to exclude the presence of bilateral disease. Our findings demonstrate that despite evolution of biopsy techniques, contemporary 12-core extended pattern prostate biopsy still does not provide reliable localization of tumors to specific areas of the prostate.

The well-documented multifocal, microscopic nature of prostate cancer²⁰ is the most likely reason for our findings of poor localization of cancer within the prostate. Considering this, another important finding in this study was that the absence of multifocality in the prostatectomy specimen was the only clinicopathologic variable that consistently and significantly increased the pathologic agreement between biopsy and prostatectomy specimens. The absence of multifocality increased the NPV at all sites, but this came at the cost of a decreased PPV at all sites. Unfortunately, multifocality is a pathologic characteristic that is not confirmed until after prostatectomy. Therefore, we repeated our analyses using only those factors that would be available for preoperative decision making (PSA, clinical stage, biopsy Gleason score, ultrasound prostate volume, number of positive cores, total number of cores). In these models, having only 1 positive needle core, which is conceptually related to tumor unifocality, was associated with pathologic agreement only for the total study population but not for the low-risk group. Indeed, it is noteworthy that no preoperative features were indicative of pathologic agreement for the low-risk population.

Alternative explanations for the poor tumor localization with contemporary prostate biopsy technique include the systematic misclassification of tumor locations as a result of taking needle cores at an angle oblique to the posterior surface of the prostate. Although the needle path often will pass from 1 area of the prostate into the adjacent area (Fig. 1), current labeling convention indicates only the site of entry into the prostate. Thus, as illustrated in the apical core in Figure 1, a mid-prostate cancer has the potential to be misclassified as an apex cancer. In addition, current imaging with 2-dimensional gray scale ultrasonography limits tumor localization. The majority of prostate cancers are poorly visualized on gray-scale ultrasonography.²¹ Although several

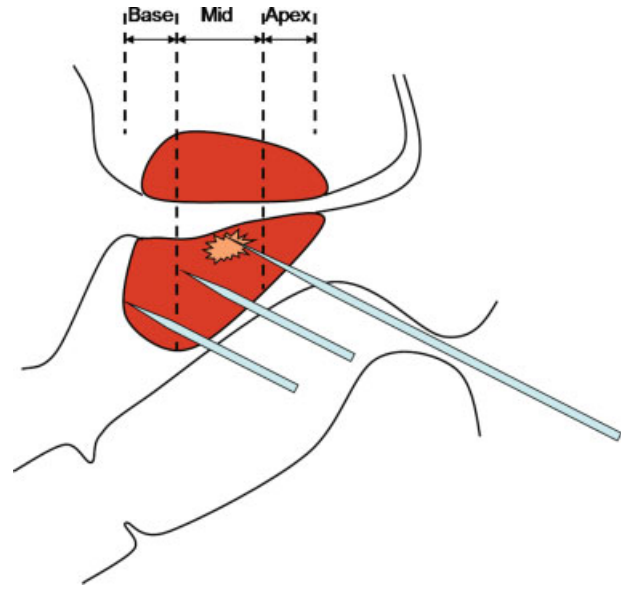


FIGURE 1. A typical transrectal ultrasound guided prostate biopsy takes needle cores at an angle oblique to the posterior surface of the prostate.

modifications to ultrasonography including color flow Doppler imaging, bio-impedance, and contrast enhancement with microbubbles have been investigated to improve localization of discrete tumor, they are still likely to miss small foci of disease.²¹⁻²³

In breast cancer, management has evolved from radical treatment to localized treatment in the form of lumpectomy in which strict criteria for operable lesions have been developed and validated. However, similar criteria currently do not exist for prostate cancer and would require that the cancer be located where the biopsy is positive (high positive predictive value) and not where the biopsy is negative (high negative predictive value). Considering these conceptual criteria, our findings demonstrated that contemporary extended pattern prostate biopsy has a high PPV for right and left prostate biopsies as well as in the prostate mid-base. However, the low NPV suggests a low reliability to exclude the presence of cancer at those sites. Even when the biopsy was negative at these sites, over 2 thirds of the time there was still cancer present at the corresponding sites on the prostatectomy specimen. At the apex, the NPV improved, likely representing smaller sampled size; however, this came at a cost to the PPV. When we limited the analyses to the subset of patients with low-risk disease, there continued to be very limited ability to localize tumor foci properly.

This poor localization of neoplastic lesions in the prostate by contemporary extended pattern prostate biopsy raises particular concern when considering

targeted focal therapy of localized prostate cancer, which attempts to treat only the affected side or specific site based on prostate biopsy. Focal targeted therapy with a curative intent of the prostate would require either reliable preoperative localization or use of a highly reproducible mapping of the tumor in 3-dimensional space, a goal that has yet to be achieved. Several studies have reported early results with targeted focal therapy of unilateral localized prostate cancer. Onik et al⁶ reported on their experience with focal cryohemablation in 9 men. Patients were only considered if their cancer was unilateral based on sextant biopsy. In addition, patients biopsied at other institutions underwent repeat biopsy with 7 to 8 additional cores from the peripheral zone on the side opposite of the previously demonstrated tumor before focal cryohemablation. More recently, Bahn et al⁴ reported their results with focal cryohemablation in 31 patients. After an initial 6- to 8-core diagnostic biopsy, patients underwent color Doppler ultrasound with targeted biopsy of all the suspect lesions. Although some of these early results for focal treatment are encouraging, the biopsy techniques used in these studies as well as the poor localization of tumor to specific areas of the prostate by contemporary extended pattern biopsy in our current study still raise concerns about the possibility of missing other cancers within the prostate using these modalities.

This study has several limitations. First, our results are based on a single-institution, albeit prospective, study; thereby limiting generalizability. Second, the standardized protocol of pathological tumor mapping of radical prostatectomy specimens currently performed at our institution includes and reports tumor location in only 4 zones: right apex, left apex, right mid-base, and left mid-base. Thus, in our current analysis, we are limited by the inability to differentiate between mid-prostate and prostate base. Although we are able to assess Gleason score, size of largest tumor foci, tumor multifocality, and presence/absence of tumor in specific regions of the prostate, our current standardized pathological evaluation of radical prostatectomy specimens does not allow us to determine Gleason score and size of each individual tumor foci within the prostate. In future studies, we hope to further evaluate the ability of prostate biopsy to predict the location of clinically significant disease to even more specific areas of the prostate, further differentiating between mid-prostate and prostate base and largest tumor foci.

So far as is known, this is the first study to evaluate the ability of contemporary extended pattern prostate biopsy to predict location of neoplastic

lesions to specific regions of the prostate. Whereas the extended prostate biopsy techniques improved cancer detection,⁸ there is no evidence that they provide reliable localization of tumor to specific areas of the prostate. In addition, there are no preoperative clinicopathologic features that significantly and consistently increase the predictability of prostate biopsies in specific locations. Thus, focal targeted therapy with a curative intent, which relies heavily on localization, should only be performed with these caveats in mind.

REFERENCES

1. Jemal A, Siegel R, Ward E, Murray T, Xu J, Thun MJ. Cancer statistics, 2007. *CA Cancer J Clin.* 2007;57:43-66.
2. Litwin MS, Gore JL, Kwan L, et al. Quality of life after surgery, external beam irradiation, or brachytherapy for early-stage prostate cancer. *Cancer.* 2007;109:2239-2247.
3. Miller DC, Sanda MG, Dunn RL, et al. Long-term outcomes among localized prostate cancer survivors: health-related quality-of-life changes after radical prostatectomy, external radiation, and brachytherapy. *J Clin Oncol.* 2005;23:2772-2780.
4. Bahn DK, Silverman P, Lee F Sr, Badalament R, Bahn ED, Rewcastle JC. Focal prostate cryoablation: initial results show cancer control and potency preservation. *J Endourol.* 2006;20:688-692.
5. Crawford ED, Barqawi A. Targeted focal therapy: a minimally invasive ablation technique for early prostate cancer. *Oncology (Williston Park).* 2007;21:27-32; discussion 33-24,39.
6. Onik G, Narayan P, Vaughan D, Dineen M, Brunelle R. Focal "nerve-sparing" cryosurgery for treatment of primary prostate cancer: a new approach to preserving potency. *Urology.* 2002;60:109-114.
7. Eichler K, Hempel S, Wilby J, Myers L, Bachmann LM, Kleijnen J. Diagnostic value of systematic biopsy methods in the investigation of prostate cancer: a systematic review. *J Urol.* 2006;175:1605-1612.
8. Siu W, Dunn RL, Shah RB, Wei JT. Use of extended pattern technique for initial prostate biopsy. *J Urol.* 2005;174:505-509.
9. Descazeaud A, Rubin MA, Allory Y, et al. What information are urologists extracting from prostate needle biopsy reports and what do they need for clinical management of prostate cancer? *Eur Urol.* 2005;48:911-915.
10. National Comprehensive Cancer Network Clinical Practice Guidelines in Oncology. Prostate Cancer Early Detection. Available at: <http://www.nccn.org> Accessed March 2008.
11. Hodge KK, McNeal JE, Terris MK, Stamey TA. Random systematic versus directed ultrasound guided transrectal core biopsies of the prostate. *J Urol.* 1989;142:71-74; discussion 74-75.
12. Babaian RJ, Toi A, Kamoi K, et al. A comparative analysis of sextant and an extended 11-core multisite directed biopsy strategy. *J Urol.* 2000;163:152-157.
13. Borboroglu PG, Comer SW, Riffenburgh RH, Amling CL. Extensive repeat transrectal ultrasound guided prostate biopsy in patients with previous benign sextant biopsies. *J Urol.* 2000;163:158-162.

14. Levine MA, Ittman M, Melamed J, Lepor H. Two consecutive sets of transrectal ultrasound guided sextant biopsies of the prostate for the detection of prostate cancer. *J Urol*. 1998;159:471-475; discussion 475-476.
15. Roehl KA, Antenor JA, Catalona WJ. Serial biopsy results in prostate cancer screening study. *J Urol*. 2002;167:2435-2439.
16. Emiliozzi P, Scarpone P, DePaula F, et al. The incidence of prostate cancer in men with prostate specific antigen greater than 4.0 ng/ml: a randomized study of 6 versus 12 core transperineal prostate biopsy. *J Urol*. 2004;171:197-199.
17. Naughton CK, Miller DC, Mager DE, Ornstein DK, Catalona WJ. A prospective randomized trial comparing 6 versus 12 prostate biopsy cores: impact on cancer detection. *J Urol*. 2000;164:388-392.
18. Gregori A, Vieweg J, Dahm P, Paulson DF. Comparison of ultrasound-guided biopsies and prostatectomy specimens: predictive accuracy of Gleason score and tumor site. *Urol Int*. 2001;66:66-71.
19. Scales CD, Amling CL, Kane CJ, et al. Can unilateral prostate cancer be reliably predicted based upon biopsy features? *J Urol*. 2006;175:373.
20. Boccon-Gibod LM, Dumonceau O, Toublanc M, Ravery V, Boccon-Gibod LA. Micro-focal prostate cancer: a comparison of biopsy and radical prostatectomy specimen features. *Eur Urol*. 2005;48:895-899.
21. Raja J, Ramachandran N, Munneke G, Patel U. Current status of transrectal ultrasound-guided prostate biopsy in the diagnosis of prostate cancer. *Clin Radiol*. 2006;61:142-153.
22. Kravchick S, Cytron S, Peled R, Altshuler A, Ben-Dor D. Using gray-scale and 2 different techniques of color Doppler sonography to detect prostate cancer. *Urology*. 2003;61:977-981.
23. Lee BR, Roberts WW, Smith DG, et al. Bioimpedance: novel use of a minimally invasive technique for cancer localization in the intact prostate. *Prostate*. 1999;39:213-218.