

MUTATION IN BRIEF

Mutational Spectrum of *FAM83H*: The C-Terminal Portion is Required for Tooth Enamel Calcification

Sook-Kyung Lee¹, Jan C-C. Hu², John D. Bartlett³, Kyung-Eun Lee¹, Brent P-J. Lin⁴, James P. Simmer², and Jung-Wook Kim^{1,5*}

¹Department of Cell and Developmental Biology & Dental Research Institute, School of Dentistry, Seoul National University, 275-1 Yongon-dong, Chongno-gu, Seoul 110-768, Korea; ²Department of Biologic and Materials Sciences, University of Michigan Dental Research Lab, 1210 Eisenhower Place, Ann Arbor, MI 48108; ³Harvard-Forsyth Department of Oral Biology, Department of Cytokine Biology, The Forsyth Institute, 140 The Fenway, Boston, MA 02115; ⁴Department of Growth and Development, University of California, San Francisco, School of Dentistry, San Francisco, CA 94143-0640; ⁵Department of Pediatric Dentistry & Dental Research Institute, School of Dentistry, Seoul National University, 275-1 Yongon-dong, Chongno-gu, Seoul 110-768, Korea.

*Correspondence to Jung-Wook Kim, Dental Genetics Laboratory, Department of Cell and Developmental Biology, Department of Pediatric Dentistry & Dental Research Institute, School of Dentistry, Seoul National University, 275-1 Yongon-dong, Chongno-gu, Seoul 110-768, Korea; Tel.: +82-220722639; Fax: +82-27443599; E-mail: pedoman@snu.ac.kr

Communicated by Mark H. Paalman

Dental enamel forms through the concerted activities of specialized extracellular matrix proteins, including amelogenin, enamelin, MMP20, and KLK4. Defects in the genes encoding these proteins cause non-syndromic inherited enamel malformations collectively designated as amelogenesis imperfecta (AI). These genes, however, account for only about a quarter of all AI cases. Recently we identified mutations in *FAM83H* that caused autosomal dominant hypocalcified amelogenesis imperfecta (ADHCAI). Unlike other genes that cause AI, *FAM83H* does not encode an extracellular matrix protein. Its location inside the cell is completely unknown, as is its function. We here report novel *FAM83H* mutations in four kindreds with ADHCAI. All are nonsense mutations in the last exon (c.1243G>T, p.E415X; c.891T>A, p.Y297X; c.1380G>A, p.W460X; and c.2029C>T, p.Q677X). These mutations delete between 503 and 883 amino acids from the C-terminus of a protein normally comprised of 1179 residues. The reason these mutations cause such extreme defects in the enamel layer without affecting other parts of the body is not known yet. However it seems evident that the large C-terminal part of the protein is essential for proper enamel calcification. © 2008 Wiley-Liss, Inc.

KEY WORDS: amelogenesis imperfecta; hypocalcification; enamel; matrix; FAM83H

INTRODUCTION

Dental enamel is the hardest tissue in the human body. It consists of a highly organized layer of calcium hydroxyapatite crystals that covers dentin to form the crown of a tooth. Dental enamel contains less than 1%

Received 29 January 2008; accepted revised manuscript 20 February 2008.

organic material, whereas other mineralized tissues contain about 20% organics (Nanci, 2008). Amelogenesis imperfecta (AI) is a collection of inherited conditions exhibiting malformations in tooth enamel, usually in the absence of other symptoms (Hu, et al., 2007; Wright, 2006). The enamel phenotype in AI varies, but can be broadly categorized as hypoplastic (abnormally thin), hypomaturation (normal thickness, but soft), and hypocalcified (irregular thickness and soft) (Witkop, 1988).

Dental enamel forms in an extracellular space by matrix-mediated biomineralization (Simmer and Fincham, 1995). Defects in the genes encoding four secreted enamel matrix proteins are known to cause non-syndromic hereditary enamel defects. Mutations in the amelogenin gene (*AMELX*; MIM# 300391) cause X-linked hypoplastic and hypomaturation AI. Mutations in the enamelin gene (*ENAM*; MIM# 606585) cause autosomal dominant or recessive hypoplastic AI, while mutations in the genes encoding the enamel proteases enamelysin (*MMP20*; MIM# 604629) and kallikrein 4 (*KLK4*; MIM# 603767), cause autosomal recessive hypomaturation AI. These genes, however, were found to cause the disease in only 6 out of 24 AI families screened by mutational analyses using the known candidate genes (Kim, et al., 2006).

Recently, a form of autosomal dominant AI was linked to a 2.1 MB region of chromosome 8 (Mendoza, et al., 2007), and we discerned that defects in *FAM83H* (family with sequence similarity 83 member H) within this linked interval caused autosomal dominant hypocalcified amelogenesis imperfecta (ADHCAI) in two Korean families (Kim, et al., 2008). The aim of this study was to further investigate for *FAM83H* (8q24.3) mutations in other kindreds with ADHCAI.

MATERIALS AND METHODS

Subjects

The study protocol and subject consents were reviewed and approved by the Institution Review Boards at the Seoul National University Hospital and the University of Michigan and appropriate informed consent was obtained from all subjects. Among the 37 AI families, we selected 7 ADHCAI families based on the clinical phenotype.

DNA extraction, PCR amplification and Mutational Analysis

Ten cc of peripheral whole blood was obtained from participating family members. Genomic DNA was obtained by a conventional salting out method. we amplified and sequenced all exons and exon/intron boundaries of the *FAM83H* gene as previously described (Kim, et al., 2008). PCR amplifications were performed using the HiPi DNA polymerase premix (ElpisBio, Korea). PCR amplification products were purified by the PCR Purification Kit and protocol (ElpisBio, Korea) and used as template for DNA sequencing, which was performed at the DNA sequencing center (Macrogen, Korea). DNA mutation numbering system is based on cDNA sequence. For cDNA numbering, nucleotide numbering reflects cDNA numbering with +1 corresponding to the A of the ATG translation initiation codon in the reference sequence (NM_198488.3), according to journal guidelines (<http://www.hgvs.org/mutnomen>).

Paternity Testing

Genomic DNA from the proband of family 2 (AI#12) and his parents were analyzed by a commercial laboratory (DowGene, Korea) using 15 genetic markers (D3S1358, D21S11, D5S818, D13S317, D7S820, CSF1PO, TPOX, FGA, VWA, D16S539, D8S1179, D18S51, THO1, PentaE, PentaD).

RESULTS

Nonsense mutations were identified in the last exon (exon 5) of *FAM83H* in four families with hypocalcified amelogenesis imperfecta (Table 1). In three of the families (1,3,4) the pattern of inheritance is autosomal dominant (Figure 1). The mutation in family 2 is spontaneous, as the mutation is present in the proband but absent in his biological parents (confirmed by paternity testing), who have normal dentitions.

Table 1. Novel *FAM83H* mutations of detected in this study

Site	Family*	Race	Mutation**	Protein	Pattern of Inheritance
Exon 5	1(AI#8)	Hispanic	c.1243G>T	p.E415X	autosomal dominant
Exon 5	2(AI#12)	Asian	c.891T>A	p.Y297X	spontaneous
Exon 5	3(AI#21)	Caucasian	c.1380G>A	p.W460X	autosomal dominant
Exon 5	4(AI#24)	Caucasian	c.2029C>T	p.Q677X	autosomal dominant

*Family ID in parenthesis correspond to families in previous report (Kim, et al., 2006).

**DNA mutation numbering system is based on cDNA sequence. For cDNA numbering, nucleotide numbering reflects cDNA numbering with +1 corresponding to the A of the ATG translation initiation codon in the reference sequence (NM_198488.3), according to journal guidelines (<http://www.hgvs.org/mutnomen>).

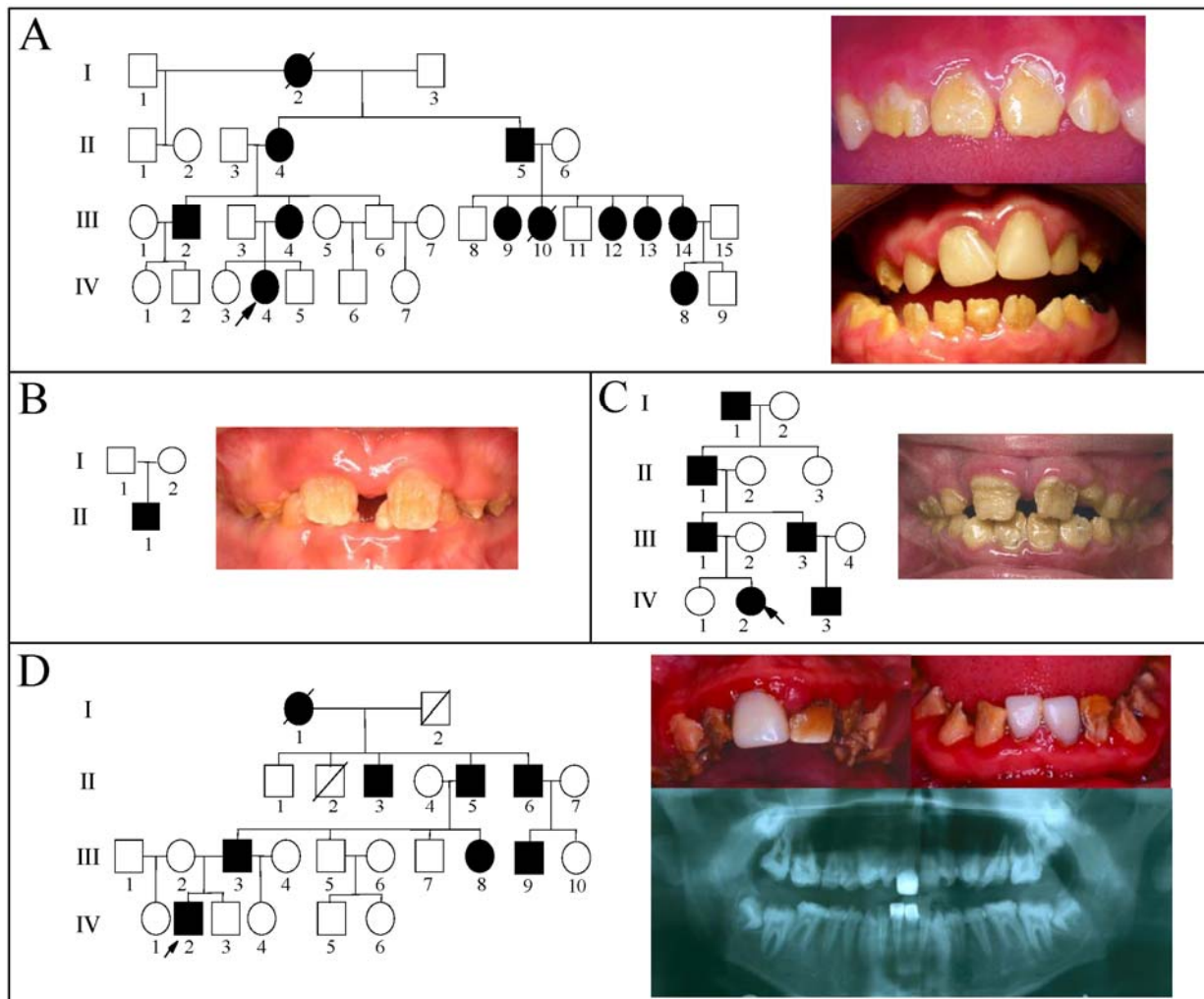


Figure 1. A: Pedigree of family 1 (p.E415X). Oral photographs show the proband (IV-4). Upper photo is the mandibular incisors at age 7 years and 11 months. Lower one is a photo at age 10 years and 10 months. **B:** Pedigree of family 2 (p.Y297X) and oral photograph of proband (II-1). **C:** Pedigree of family 3 (p.W460X) and oral photograph of proband at age 8. **D:** Pedigree of family 4 (p.Q677X) with panorex and oral photographs of proband (IV-2) at age 13 years and 5 months.

The dental enamel in the affected members of our four AI kindreds is cheesy soft in consistency, light yellow in shade, and nearly normal in thickness until erupting into function. Thereafter the enamel layer is rapidly lost due to attrition. The abraded teeth lose contour, often becoming tapered toward the incisal edge or occlusal surface. The abraded surfaces are rough in texture, take up stain rapidly, and are sensitive to thermal changes. Most of the enamel crown is rapidly lost, but sporadic islands of enamel are retained for years and appear to be of near-normal hardness. The clinical phenotype is most consistent with a diagnosis of hypocalcified AI.

There are now 6 *FAM83H* mutations that have been identified in families affected with autosomal dominant hypocalcification amelogenesis imperfecta (ADHCAI). All of the observed mutations introduce premature translation termination codons in exon 5 (Figure 2).

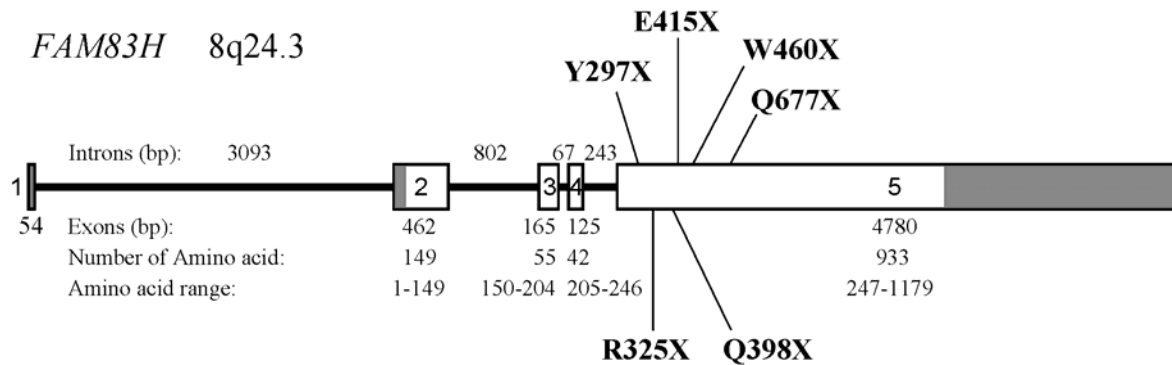


Figure 2. Gene diagram showing the 5 exons (boxes) and 4 introns (bars) of *FAM83H*. The non-coding regions in exons are shaded. The number of base pairs (bp) in an intron is shown above the intron. The number of base pairs in an exon is below the exon, followed by the number of amino acid codons in the exon and the range of amino acids encoded by the exon. The disease-causing mutations reported here are marked in bold above exon 5. The disease-causing mutations reported previously are marked in bold below exon 5.

DISCUSSION

Previously we conducted mutational analyses on 24 kindreds with amelogenesis imperfecta (Kim, et al., 2006). Seven candidate genes for AI were studied: amelogenin (*AMELX*), enamelin (*ENAM*), ameloblastin (*AMBN*), tuftelin (*TUFT1*), distal-less homeobox 3 (*DLX3*), enamelysin (*MMP20*), and kallikrein 4 (*KLK4*). The causative mutation was identified in 6 of the 24 families: two in the amelogenin, three in the enamelin and one in the enamelysin gene. We have now found non-identical *FAM83H* mutations in the affected members of four of these families, so the genetic etiologies of about half of the families are now known. These findings suggest that *FAM83H* is a major contributor to the etiology of AI, but other causative genes remain to be discovered.

FAM83H is unique among the candidate genes for AI because it does not encode an enamel matrix protein. *FAM83H* maps to chromosome 8q24.3, comprises 5 exons and encodes a protein having 1179 amino acids, most of which (933 aa) are encoded by the last exon. It is particularly intriguing that the 6 *FAM83H* mutations are all premature stop codons in the last exon, which allows the mutated transcripts to avoid nonsense-mediated mRNA decay. This means that *FAM83H* translation products lacking between 503 and 883 amino acids are synthesized along with an equal number of molecules expressed from the normal *FAM83H* allele. If the amino-terminal half of the *FAM83H* protein normally associates with another protein (as in homo- or heteromeric interactions) then the mutant and full-length proteins might be equally capable of forming these associations, but only complexes containing the full-length *FAM83H* protein could carry out their combined function. If so, expressing the truncated protein would be worse than expressing the normal protein in diminished amounts. Another possibility is that protein(s) functionally interacting with *FAM83H* might play a role in the pathogenesis of AI. Currently it is not known if *FAM83H* interacts with other proteins or if *FAM83H* haploinsufficiency results in an enamel phenotype.

However it seems evident that the large C-terminal part of the protein (after 676 amino acids) is essential for proper enamel calcification, based on mutational spectrum of the *FAM83H* in the ADHCAI families.

ACKNOWLEDGMENTS

We thank the participants in this study for their cooperation. This work was supported in part by a grant from the Korea Health 21 R&D Project, Ministry of Health & Welfare, Republic of Korea (A060010), the Korea Science and Engineering Foundation (KOSEF) through the Biotechnology R&D program (#2006-05229), and NIDCR/NIH Grants DE015846 and DE011301.

REFERENCES

- Hu JC, Chun YH, Al Hazzazzi T, Simmer JP. 2007. Enamel formation and amelogenesis imperfecta. *Cells Tissues Organs* 186:78-85.
- Kim JW, Lee SK, Lee ZH, Park JC, Lee KE, Lee MH, Park JT, Seo BM, Hu JC, Simmer JP. 2008. *FAM83H* Mutations in Families with Autosomal-Dominant Hypocalcified Amelogenesis Imperfecta. *Am J Hum Genet* 82:489-494.
- Kim JW, Simmer JP, Lin BP, Seymen F, Bartlett JD, Hu JC. 2006. Mutational analysis of candidate genes in 24 amelogenesis imperfecta families. *Eur J Oral Sci* 114: Suppl. (1):3-12.
- Mendoza G, Pemberton TJ, Lee K, Scarel-Caminaga R, Mehrian-Shai R, Gonzalez-Quevedo C, Ninis V, Hartiala J, Allayee H, Snead ML, Leal SM, Line SR, Patel PI. 2007. A new locus for autosomal dominant amelogenesis imperfecta on chromosome 8q24.3. *Hum Genet* 120:653-662.
- Nanci A, editor. 2008. *Ten Cate's Oral Histology Development, Structure, and Function*. 7th ed. St. Louis, MO, USA: Mosby. p 411.
- Simmer JP, Fincham AG. 1995. Molecular mechanisms of dental enamel formation. *Crit Rev Oral Biol Med* 6:84-108.
- Witkop CJ, Jr. 1988. Amelogenesis imperfecta, dentinogenesis imperfecta and dentin dysplasia revisited: problems in classification. *J Oral Pathol* 17:547-553.
- Wright JT. 2006. The molecular etiologies and associated phenotypes of amelogenesis imperfecta. *Am J Med Genet A* 140:2547-2555.