

REFERENCES

- Kraus MD, Fleming MD, Vonderheide RH. The spleen as a diagnostic specimen: A review of 10 years' experience at two tertiary care institutions. *Cancer* 2001;91:2001–2009.
- Rokitansky K, editor. Abnormalities of the spleen. *Lehrbuch der Pathologischen Anatomie*, 3rd edition. Vienna: Wilhelm Braumuller. 1861; p. 3.
- Silverman ML, LiVolsi VA. Splenic hamartoma. *Am J Clin Pathol* 1978;70:224–229.
- Iozzo RV, Haas JE, Chard RL. Symptomatic splenic hamartoma: A report of two cases and review of the literature. *Pediatrics* 1980;66:261–265.
- Bender BL, Yunis EJ. Splenic involvement in tuberous sclerosis. Report of three cases. *Virchows Arch A Pathol Anat Histol* 1981;391:363–369.
- Darden JW, Teeslink R, Parrish A. Hamartoma of the spleen: A manifestation of tuberous sclerosis. *Am Surg* 1975;41:564–566.
- Abbott RM, Levy AD, Aguilera NS, et al. From the archives of the AFIP: Primary vascular neoplasms of the spleen: Radiologic-pathologic correlation. *Radiographics* 2004;24:1137–1163.
- Cheuk W, Lee AK, Arora N, et al. Splenic hamartoma with bizarre stromal cells. *Am J Surg Pathol* 2005;29:109–114.
- Lee SH. Fine-needle aspiration cytology of splenic hamartoma. *Diagn Cytopathol* 2003;28:82–85.
- Kubota R, Yamada S, Kubota K, et al. Intratumoral distribution of fluorine-18-fluorodeoxyglucose in vivo: High accumulation in macrophages and granulation tissues studied by microautoradiography. *J Nucl Med* 1992;33:1972–1980.
- Metser U, Even-Sapir E. The role of 18F-FDG PET/CT in the evaluation of solid splenic masses. *Semin Ultrasound CT MR* 2006;27:420–425.
- Metser U, Miller E, Kessler A, et al. Solid splenic masses: Evaluation with 18F-FDG PET/CT. *J Nucl Med* 2005;46:52–59.
- Even-Sapir E, Lievshitz G, Perry C, et al. Fluorine-18 fluorodeoxyglucose PET/CT patterns of extranodal involvement in patients with Non-Hodgkin lymphoma and Hodgkin disease. *Radiol Clin North Am* 2007;45:697–709, vii.
- Donner LR, Marcussen S, Dobin SM. A clonal dic(16;21)(p13.1;p11.2)del(16)(q11.1), with gains of several chromosomes and monosomy 21, in a case of splenic hamartoma: Evidence for its neoplastic, not hamartomatous, origin. *Cancer Genet Cytogenet* 2005;157:160–163.
- Elsheikh TM, Herzberg AJ, Silverman JF. Fine-needle aspiration cytology of metastatic malignancies involving unusual sites. *Am J Clin Pathol* 1997;108:S12–S21.
- Silverman JF, Geisinger KR, Raab SS, et al. Fine needle aspiration biopsy of the spleen in the evaluation of neoplastic disorders. *Acta Cytol* 1993;37:158–162.
- Muraca S, Chait PG, Connolly BL, et al. US-guided core biopsy of the spleen in children. *Radiology* 2001;218:200–206.
- Kimber C, Spitz L, Drake D, et al. Elective partial splenectomy in childhood. *J Pediatr Surg* 1998;33:826–829.
- Hery G, Becmeur F, Mefat L, et al. Laparoscopic partial splenectomy: Indications and results of a multicenter retrospective study. *Surg Endosc* 2008;22:45–49.

Pediatric Duodenal Cancer and Biallelic Mismatch Repair Gene Mutations

Sumita Roy, MD,^{1*} Leon Raskin, PhD,² Victoria M. Raymond, MS,² Stephen N. Thibodeau, PhD,³
Rajen J. Mody, MD,¹ and Stephen B. Gruber, MD, PhD, MPH^{2,4,5*}

Gastrointestinal malignancies are extremely rare in the pediatric population, and duodenal cancers represent an even more unusual entity. Intestinal cancers in young adults and children have been observed to be associated with functional deficiencies of the mismatch repair (MMR) system causing a cancer-predisposition

syndrome. We report the case of a 16-year-old female with duodenal adenocarcinoma and past history of medulloblastoma found to have a novel germline biallelic truncating mutation (c.[949C>T]+[949C>T]) of the *PMS2* gene. *Pediatr Blood Cancer* 2009;53:116–120. © 2009 Wiley-Liss, Inc.

Key words: biallelic; children and young adults; duodenal adenocarcinoma; mismatch repair

INTRODUCTION

Gastrointestinal malignancies in children present challenging management issues and are often suggestive of inherited susceptibility to cancer. DNA mismatch repair (MMR) genes, *MLH1*, *MSH2*, *MSH6*, and *PMS2* maintain genome integrity by correcting DNA replication errors [1]. Defective MMR causes microsatellite instability (MSI) (errors in length of microsatellites or repeated sequences of DNA), a hallmark of MMR deficiency. Germline heterozygous mutations in MMR genes results in Lynch syndrome or Hereditary Non-Polyposis Colorectal Cancer (HNPCC), an autosomal dominant cancer susceptibility syndrome with increased risk for developing colorectal and endometrial malignancies. Within the last decade there has been mounting evidence for an inherited cancer syndrome resulting from germline biallelic mutations in MMR genes which has been alternately referred to

Additional Supporting Information may be found in the online version of this article.

¹Division of Pediatric Hematology-Oncology, Dept. of Pediatrics, University of Michigan Health System, Ann Arbor, Michigan; ²Department of Internal Medicine, University of Michigan Medical School, Ann Arbor, Michigan; ³Department of Laboratory Medicine and Pathology, Mayo Clinic, Rochester, Minnesota; ⁴Department of Epidemiology, University of Michigan School of Public Health, Ann Arbor, Michigan; ⁵Department of Human Genetics, University of Michigan Medical School, Ann Arbor, Michigan

*Correspondence to: Sumita Roy and Stephen B. Gruber, Department of Pediatrics, Division of Pediatric Hematology-Oncology, University of Michigan Health System, 1500 East Medical Center Drive, L2110 Women's Hospital, Ann Arbor, MI 48109-0238.

E-mail: sumitar@med.umich.edu; sgruber@umich.edu

Received 15 October 2008; Accepted 6 January 2009

as childhood cancer syndrome (CCS), MMR-deficiency syndrome (MMR-D) and constitutional MMR deficiency (CMMR-D) [2–4]. This syndrome results from complete deficiency of MMR function and differs from HNPCC in the tumor spectrum, age of onset and presence of café-au-lait macules (CALM).

CASE

A 16-year-old female of Syrian descent, with multiple CALM was diagnosed with a moderately differentiated adenocarcinoma arising in the ampulla and invading the pancreas, with metastases to 6/39 lymph nodes. She underwent a Whipple procedure and received adjuvant radiation therapy along with continuous 5-FU (5-fluoro-uracil) infusion for 6 weeks, followed by eight cycles of modified FOLFOX 6 (85 mg/m² of oxaliplatin and 400 mg/m² Leucovorin, followed by 400 mg/m² 5-FU bolus and 2,400 mg/m² 5-FU infusion for 46 hr). At the conclusion of chemotherapy, imaging showed a new 2 cm sigmoid mass. Laparoscopic sigmoid resection revealed an adenoma.

Her past history is significant for medulloblastoma diagnosed at age 8, treated with surgery and radiation. Family history is significant for parental consanguinity (Fig. 1A) and diagnosis of precursor T-cell acute lymphoblastic leukemia (ALL) in younger brother (IV.3) at age 5, who died at age 6. The history of consanguinity in siblings with medulloblastoma and leukemia had prompted a cancer genetics consultation 7 years ago in IV.3, who also had CALM (largest measuring 4.5 cm) and several dysmorphic features. His workup included evaluation for mutations in *MLH1* and *MSH2* based on reports in the literature documenting hematologic malignancies as a feature of MMR deficiency [5,6].

No mutations in *MLH1* and *MSH2* were identified and tissue was insufficient for immunohistochemistry (IHC) and MSI analysis. The second diagnosis of duodenal cancer in the patient (IV.1) led to further suspicion of MMR-D, and genetic counseling, molecular diagnostic workup and enrollment in an IRB-approved cancer genetics registry was offered.

MOLECULAR ANALYSIS

Duodenal carcinoma tissue analysis demonstrated high degree of MSI in 10/10 markers tested and IHC demonstrated absent PMS2 expression in tumor and normal tissue, with intact expression of MLH1, MSH2, and MSH6 [7]. Blood samples of IV.1 and her parents were tested for *PMS2* mutations on a research protocol [8]. After initial identification of the mutation, confirmatory testing was performed in research and clinical laboratories at the University of Michigan. *PMS2* exon 9 was amplified using PCR primers 5'-GGCTGGGAACATTTGTCATT-3' and 5'-TGCCAATGGAAC-TACCTGA-3', purified and genotyped by direct sequencing on an ABI 3730 sequencer. DNA sequence analysis (*GenBank RefSeq*-NM_000535.5) using Mutation Surveyor software, revealed a unique cytosine to thymine transition at coding nucleotide position 949 (949C>T) in the *PMS2* exon 9 resulting in a codon change from glutamine to a premature stop codon at amino acid 317 (Q317X) (Fig. 1C). Consistent with the expectation from a consanguineous family, IV.1 was homozygous for the mutation and both parents were heterozygous for the same mutant allele. Analysis of IV.3's normal and tumor tissue was hindered due to poor tissue quality, but clearly demonstrated at least one mutant allele. The family declined genetic testing of the other siblings.

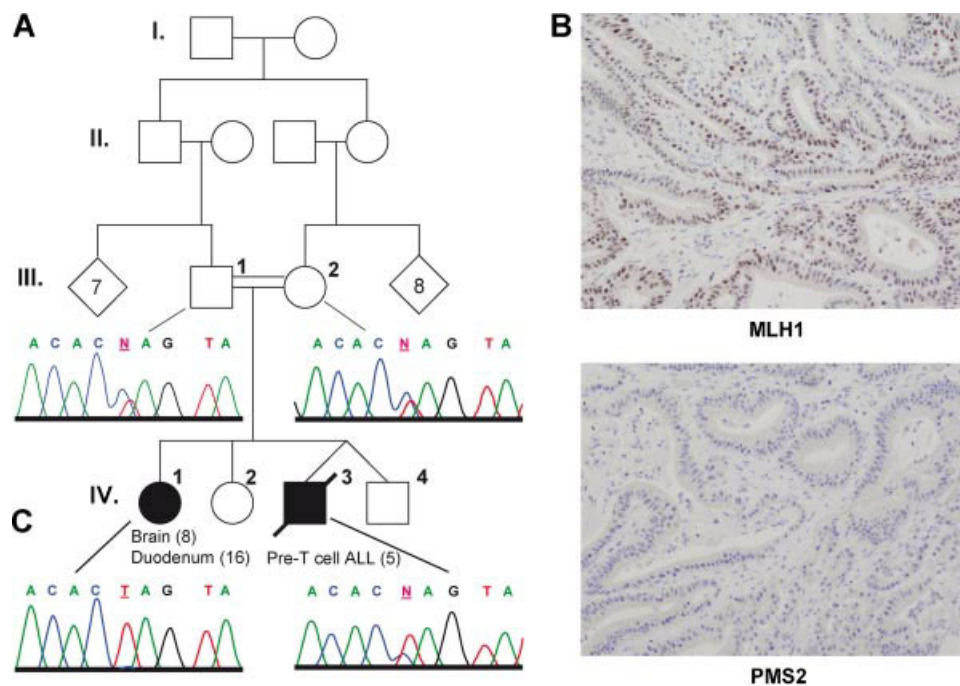


Fig. 1. Autosomal recessive susceptibility to cancer in a consanguineous Syrian family due to a homozygous mutation of *PMS2*. **A:** Pedigree showing medulloblastoma at age 8 and duodenal carcinoma at age 16 in IV.1 and Pre T-cell ALL at age 5 in IV.3, whose parents are first cousins. **B:** Immunohistochemistry showing intact expression of MHL1 (top) and absent expression of PMS2 (bottom). **C:** Sequencing chromatograms show a heterozygous mutation of *PMS2* 949C>T (Q317X) within exon 9 in both parents (who are unaffected), and a homozygous mutation in the affected 16-year-old female. [Color figure can be viewed in the online issue, which is available at www.interscience.wiley.com.]

TABLE I. Duodenal Cancer in Children and Young Adults

Family	Sex	Tumors in proband (age of diagnosis in years)	Tumors in siblings (age of diagnosis in years)	Tumors in other relatives (age of diagnosis in years)	MSI	IHC	Gene	Biallelic mutation	Cons.	CALM	References
1	M	Met. Duod. adenoCa (11)	Sister: intestinal adenoCa, Co adenoCa (9), sister-plexiform neurofibroma, hairy nevi (6)	Pat. GF: lung (62); pat. GGF: Co Ca (60s), mat.GF: stomach (58)	MSI high	Weak MLH1 present	MLH1	c.[2059C>T]+[2059C>T], p.[Arg687Trp]+[Arg687Trp]	Yes	Present	Gallinger et al. [9]
2	M	Met. Duod. adenoCa (17)	None	Mother: Co adenoCa (44), mat.GF: Jejunal adenoCa (52), father: lung (55)	MSI high	PMS2 absent in tumor and normal tissue	PMS2 (CH)	c.[137G>T (+) 1927C>T], p.[Ser46Ile (+) Gln643X]	No	Present	Agostini et al. [10]
3	M	Giant cell GBM (18) Colorectal adenoCa (18) Co Ca (22) Astrocytoma (29) Ileal adenoCa (31) Duod adenoCa (36) Duod NHL of MALT origin (37) Duod adenoCa (40) Co Ca (23)	Brother: brain tumor (23) nevi (6)	None	MSS NA	NA	NA	NA	No	NA	Murphy et al. [11]
4	M	None	None	None	MSI high	PMS2 absent in tumor and normal tissue	PMS2	c.[906-?-2589+?del]+[906-?-2589+?del], p.[Val1302_X863del]+[Val1302_X863del] deletion involves PMS2 exons 9-15, oncomodulin, TRIAD3, and FSCN1	Yes	Present	Will et al. [12]
5	NA	Duod adenoCa (25) Co Ca (20)	Brother: brain tumor (38), sister: brain tumor (31)	NA	MSI high NA	PMS2 absent in tumor and normal tissue NA NA NA	PMS2 (CH)	c.[614A>C]+[1A>G], p.[Gln205Pro]+[? (5' truncation)]	NA	NA	Senter et al. [8]
6	F	Duod Ca (41) Lymphoma (NA) Medulloblastoma (8) Met. Duod adenoCa (16)	Brother: T-ALL (6)	None	NA MSI high	PMS2 absent in tumor and normal tissue	PMS2	c.[949C>T]+[949C>T], p.[Gln317X]+[Gln317X]	Yes	Present	Present case

Tumors: adenoCa, adenocarcinoma; Met, metastatic; Duod, duodenal; Co Ca, colon cancer; GBM, glioblastoma multiforme; NHL, non-Hodgkin lymphoma; T-ALL, T-cell acute lymphoblastic leukemia
 Relatives: pat, paternal; mat, maternal; GF, grandfather; GGF, great grandfather; MSI, microsatellite instability (of tumors in proband); IHC, immunohistochemistry; CH, compound heterozygous; Cons, consanguinity; CALM, café au lait macules; NA, not available Mutation nomenclature per Human Genome Variation Society, <http://www.genomc.unimelb.edu.au/mdi/mutnomen/recs.html>.

DISCUSSION

Duodenal cancers are extremely rare with median age of diagnosis in the sixth decade of life. A systematic literature search for early onset duodenal cancers revealed five other cases (Table I), four of which had germline biallelic MMR mutations [8–12]. A comprehensive literature review through PubMed revealed 50 families with germline biallelic MMR mutations (Supplemental Tables I and II). The present case is cited in two other reviews [4,8], and here we present the full clinical details of this case and review the implications of a diagnosis of MMR-D.

MMR-D phenotype is seen in homozygotes or compound heterozygotes and absence of a family history of cancer does not diminish its likelihood. Biallelic mutations in *PMS2* accounted for majority of cases in families with MMR-D (25/50 families, 50%), while *MLH1* and *MSH6* each accounted for 20% of families, and *MSH2* accounted for 10% of families. Onset of tumors is as early as the first decade of life and the tumor spectrum primarily comprises of gastrointestinal (colorectal and small intestinal tumors), brain (glioblastoma, astrocytoma, medulloblastoma, PNET), and hematological malignancies (ALL and non-Hodgkin lymphoma, T-cell type). Colorectal cancers were reported in 37 individuals in 27/50 (54%) families (median age: 17 years); small intestinal cancers in 7 individuals in 5/50 (10%) families (median age: 17 years); brain tumors in 40 individuals in 29/50 (58%) families (median age: 8 years) and hematological malignancies in 29 individuals in 19/50 (38%) families (median age: 5 years). Other malignancies reported were: 5 cases of endometrial cancer (median age: 24 years), one case of ureter/renal pelvis cancer at age 15, two cases of rhabdomyosarcoma (ages 4 and 18), one case of Wilms tumor (age 4), one case of infantile myofibromatosis (age 1), one case of neuroblastoma (age 13), one case of breast cancer (age 35), one case of ovarian neuroectodermal tumor (age 21) and one case of sarcoma (age 65). Thirty two of the 84 (34.2%) patients developed more than one primary tumor. Survival data reported in 64 patients revealed that 38 patients (59.3%) died of their disease at median age of 10 years.

Multiple CALM have been reported in 35/50 (70%) families, with only one patient having a germline NF-1 mutation [13]. However, *NF1* may be a mutational target of MMR-deficiency [5,13,14]. Hypopigmentation, immunodeficiencies and autoimmune diseases have been reported with biallelic *MSH6* mutations [15–18]. CALM have not been reported in any heterozygous carriers. Although the chromatogram of IV.3 suggests that he is heterozygous, his phenotype is more consistent with homozygosity. The pseudogene *PMS2CL* sequence corresponds to exons 9 and 11–15 of the *PMS2* gene [19]; and may be amplified by primers used for amplification of *PMS2* exon 9. Therefore it is likely that IV.3's chromatogram illustrates sequence data from both *PMS2* and *PMS2CL*.

Patients with MMR-D and their families need heightened surveillance and we have recommended National Comprehensive Cancer Network practice guidelines for HNPCC/Lynch syndrome for IV.1 and her parents with the addition of annual upper endoscopy for IV.1. Since HNPCC or MMR-D cannot be excluded in the other siblings (IV.2, IV.4) similar surveillance was recommended for them as well until further information can be gained. Therapeutically it is important to develop chemotherapeutic agents that are relevant for these cancers since several in vitro studies have shown resistance of MMR-deficient cell lines to commonly used agents [20]. In

conclusion, this case documents a novel mutation of *PMS2*, underscores the clinical traits of the pediatric cancer syndrome of MMR-D, emphasizes the clinical value of genetic testing, and highlights pediatric duodenal carcinoma as a sentinel cancer of MMR-D.

ACKNOWLEDGMENT

This work is supported (in part) by the National Institutes of Health through the University of Michigan's Cancer Center Support Grant (5 P30 CA46592), NCI R01 CA81488 (SBG), the University of Michigan Cancer Genetics Registry, and NRSA [5 T32 HD007513-11] (SR). We are grateful to the patient and her parents for participating in this study, and to Drs. James D. Geiger and Mark Zalupski for their help in her clinical management.

REFERENCES

1. Maehara Y, Egashira A, Oki E, et al. DNA repair dysfunction in gastrointestinal tract cancers. *Cancer Sci* 2008;99:451–458.
2. Felton KE, Gilchrist DM, Andrew SE. Constitutive deficiency in DNA mismatch repair. *Clin Genet* 2007;71:483–498.
3. Felton KE, Gilchrist DM, Andrew SE. Constitutive deficiency in DNA mismatch repair: Is it time for Lynch III? *Clin Genet* 2007;71:499–500.
4. Wimmer K, Etzler J. Constitutional mismatch repair-deficiency syndrome: Have we so far seen only the tip of an iceberg? *Hum Genet* 2008;124:105–122.
5. Ricciardone MD, Ozcelik T, Cevher B, et al. Human *MLH1* deficiency predisposes to hematological malignancy and neurofibromatosis type 1. *Cancer Res* 1999;59:290–293.
6. Wang Q, Lasset C, Desseigne F, et al. Neurofibromatosis and early onset of cancers in *hMLH1*-deficient children. *Cancer Res* 1999;59:294–297.
7. Lindor NM, Burgart LJ, Leontovich O, et al. Immunohistochemistry versus microsatellite instability testing in phenotyping colorectal tumors. *J Clin Oncol* 2002;20:1043–1048.
8. Senter L, Clendenning M, Sotamaa K, et al. The clinical phenotype of Lynch syndrome because of germ-line *PMS2* mutations. *Gastroenterology* 2008;135:419–428.
9. Gallinger S, Aronson M, Shayan K, et al. Gastrointestinal cancers and neurofibromatosis type 1 features in children with a germline homozygous *MLH1* mutation. *Gastroenterology* 2004;126:576–585.
10. Agostini M, Tibiletti MG, Lucci-Cordisco E, et al. Two *PMS2* mutations in a Turcot syndrome family with small bowel cancers. *Am J Gastroenterol* 2005;100:1886–1891.
11. Murphy HR, Taylor W, Ellis A, et al. An unusual case of Turcot's syndrome associated with ileal adenocarcinoma, intestinal non-Hodgkin's lymphoma, and duodenal adenocarcinoma. Review of the classification and genetic basis of Turcot's syndrome. *Fam Cancer* 2005;4:139–143.
12. Will O, Carvajal-Carmona LG, Gorman P, et al. Homozygous *PMS2* deletion causes a severe colorectal cancer and multiple adenoma phenotype without extraintestinal cancer. *Gastroenterology* 2007;132:527–530.
13. Alotaibi H, Ricciardone MD, Ozturk M. Homozygosity at variant *MLH1* can lead to secondary mutation in *NF1*, neurofibromatosis type I and early onset leukemia. *Mutat Res* 2008;637:209–214.
14. Wang Q, Montmain G, Ruano E, et al. Neurofibromatosis type 1 gene as a mutational target in a mismatch repair-deficient cell type. *Hum Genet* 2003;112:117–123.
15. Plaschke J, Linnebacher M, Kloor M, et al. Compound heterozygosity for two *MSH6* mutations in a patient with early onset of

- HNPCC-associated cancers, but without hematological malignancy and brain tumor. *Eur J Hum Genet* 2006;14:561–566.
16. Scott RH, Mansour S, Pritchard-Jones K, et al. Medulloblastoma, acute myelocytic leukemia and colonic carcinomas in a child with biallelic MSH6 mutations. *Nat Clin Pract Oncol* 2007;4:130–134.
 17. Rahner N, Hoefler G, Hogenauer C, et al. Compound heterozygosity for two MSH6 mutations in a patient with early onset colorectal cancer, vitiligo and systemic lupus erythematosus. *Am J Med Genet A* 2008;146A:1314–1319.
 18. Etzler J, Peyrl A, Zatkova A, et al. RNA-based mutation analysis identifies an unusual MSH6 splicing defect and circumvents PMS2 pseudogene interference. *Hum Mutat* 2008;29:299–305.
 19. Hayward BE, De Vos M, Valleley EM, et al. Extensive gene conversion at the PMS2 DNA mismatch repair locus. *Hum Mutat* 2007;28:424–430.
 20. Fedier A, Fink D. Mutations in DNA mismatch repair genes: Implications for DNA damage signaling and drug sensitivity (review). *Int J Oncol* 2004;24:1039–1047.

KIR–HLA Receptor-Ligand Mismatch Associated With a Graft-Versus-Tumor Effect in Haploidentical Stem Cell Transplantation for Pediatric Metastatic Solid Tumors

Antonio Pérez-Martínez, MD, PhD,^{1*} Wing Leung, MD, PhD,² Evangelina Muñoz,¹ Rekha Iyengar, PhD,² Manuel Ramírez, MD, PhD,¹ José Luis Vicario, PhD,³ Álvaro Lassaletta, MD,¹ Julián Sevilla, MD, PhD,¹ Marta González-Vicent, MD, PhD,¹ Luis Madero, MD, PhD,¹ and Miguel Ángel Díaz-Pérez, MD, PhD¹

Killer immunoglobulin-like receptors (KIRs) on natural killer cells (NKs) recognize groups of human leukocyte antigen (HLA) class I alleles. Cells without an inhibitory HLA ligand may trigger NK activation. Reduced risk of relapse has been reported in malignant hematologic diseases after haploidentical transplantation when HLA ligands against the inhibitory KIRs present in the donor were absent in the recipient. We performed haploidentical transplant in three

children with refractory solid tumors. Our results showed that beneficial antitumor effects could be observed in the presence of inhibitory KIR–HLA mismatch. These preliminary results suggest a possible association between disease control and NK cell alloreactivity. *Pediatr Blood Cancer* 2009;53:120–124.

© 2009 Wiley-Liss, Inc.

Key words: haploidentical stem cell transplantation; KIR–HLA mismatch; NK cells; pediatric solid tumors

INTRODUCTION

Little progress has been made in the survival of children with metastatic and refractory solid tumors [1]. Allogeneic hematopoietic stem cell transplantation (HSCT) has been proposed as a potential curative alternative in patients with refractory malignancies [2]. A possible graft-versus-tumor (GVT) effect has been documented in children with metastatic and relapsed Ewing sarcoma [3], neuroblastoma [4], melanoma [5], and hepatoblastoma [6]. However, the immunological mechanisms that mediate the GVT effect have not been elucidated. Early immune reconstitution after a conditioning regimen is led by natural killer (NK) cells, and for several weeks, they represent the only detectable lymphoid population. NK cell alloreactivity *in vitro* may be predicted by the lack of ligands for inhibitory killer immunoglobulin-like receptors (KIRs) [7]. Inhibitory KIRs bind with four specificities for polymorphic human leukocyte antigen (HLA) class I molecules. NK cell reactivity may be further enhanced by a Th1 cytokine environment and by T-cell lymphopenia [8,9].

To evaluate the potential of NK cell-mediated GVT effect and its immunological mechanisms, we performed a pilot study of haploidentical HSCT in three children with refractory tumors with no known cure.

METHODS

Patients and Transplantation

The study involved three patients with metastatic solid tumors that were refractory to chemotherapy (Table I). This study was approved by the Ethical Committee of Hospital Niño Jesús. Informed consent was obtained in accordance with the

Helsinki Declaration. HSCT was performed using parental CD3/CD19 depleted G-CSF mobilized peripheral blood. Reduced-intensity conditioning consisted of busulfan (4 mg/kg/day, 2 days), fludarabine (30 mg/m²/day, 5 days), thiotepa (5 mg/kg/day, 2 days), and methylprednisolone (4 mg/kg/day, 5 days). Methotrexate (15 mg/m²/day, day +1, and 10 mg/m²/day, days +3 and +6) and cyclosporine (3 mg/kg/day, day –1 until 1 month after the infusion) were also administered. Immune reconstitution and hematopoietic chimerism were assessed monthly after HSCT. Computed tomography and magnetic resonance imaging were performed before and 3 months after HSCT.

HLA Typing and KIR Genotyping, Phenotyping, and Cytotoxicity

HLA-C allotypes (C1 and C2) and HLA-B allotypes (Bw4) were determined using high-resolution polymerase chain reaction-

¹Department of Pediatric Hematology and Oncology, Hospital Niño Jesús, Universidad Autónoma de Madrid, Madrid, Spain; ²Department of Oncology, St. Jude Children's Research Hospital, Memphis, Tennessee; ³Laboratorio de Histocompatibilidad y Biología Molecular, Centro de Transfusión de Madrid, Madrid, Spain

Grant sponsor: Spanish National Health Service; Grant number: FIS CM-04/00011.

*Correspondence to: Antonio Pérez-Martínez, Servicio de Oncología y Trasplante del Hospital Infantil Universitario Niño Jesús, Menéndez Pelayo 69, Madrid 28009, Spain.

E-mail: aperezm.hnjs@salud.madrid.org

Received 7 November 2008; Accepted 6 January 2009