

EXPERIMENTAL TRIGEMINAL NERVE INJURY

G.R. Holland

Department of Cariology, Restorative Sciences and Endodontics, School of Dentistry, University of Michigan, Ann Arbor, Michigan 48109-1078

Abstract: The successful reinnervation of peripheral targets after injury varies with the axonal population of the nerve that is injured and the extent of the dislocation of its central component from the peripheral endoneurial tube. Larger-diameter axons such as those supplying mechanoreceptors recover more readily than narrower axons such as those supplying taste. A complex, bi-directional interaction between lingual epithelium and sprouting nerve results in the redifferentiation of taste buds after denervation. Dentin and the dental pulp provide a strong attraction to sprouting nerves and will become reinnervated from collateral sources if recovery of the original innervation is blocked. The most effective repair technique for transected lingual nerves is one which brings the cut ends together rather than one that provides a temporary bridge.

Injuries can result in cell death in the trigeminal ganglion but only if the injury is severe and recovery is prevented. Lesser damage results in chromatolysis and the increased expression of neuropeptides. All nerve injuries bring about changes in the trigeminal nucleus. These occur as changes in receptive field and the incidence of spontaneously active neurons, effects which are consistent with the unmasking of existing afferents. These functional changes are short-lived and reversible. Morphologically, nerve injury results in terminal degeneration in the nuclei and an increased expression of the c-Fos gene and some neuropeptides. Only a chronic constriction injury induces behavioral changes. The adult trigeminal system retains considerable plasticity that permits it to respond successfully to nerve injury. Much remains to be learned about this response, particularly of the trophic factors that control peripheral recovery and the central response to more severe injuries.

Key words. Trigeminal nerves, trigeminal ganglion, mesencephalic nucleus, trigeminal nucleus, injury, pain, sensation, degeneration, regeneration.

(I) Introduction

Trigeminal nerves may be injured during the surgical removal of third molars (*e.g.*, Von Arx and Simpson, 1989; Rood, 1992), during osteotomies (Walter and Gregg, 1979; Yoshida *et al.*, 1989), and as a result of trauma (*e.g.*, De Man and Bax, 1988). Tooth extractions (*e.g.*, Strassburg, 1967; Hansen, 1980) and pulpectomy (Holland, 1994) are amputation injuries that result in the severance of several hundred axons and the loss of their target organ.

Clinical aspects of this topic have been recently and extensively reviewed (LaBanc and Gregg, 1992). This review will limit itself to a discussion of experimental work on animal models in which the nature of the injury is more controlled than in the clinical situation and where the range and detail of observations can be much more extensive. Consideration will be limited to work conducted on adult animals. The extensive work on trigeminal injury in developing animals warrants a separate review. The responses of nerve terminals and surrounding tissues to local injury such as corneal irritation, cavity preparation, or pulp exposure in the tooth involve a complex interaction of neural and inflammatory elements, and this too will be omitted from the current

review. It will, however, include more central responses to peripheral injuries and the recovery of terminals to injuries of the nerve trunk.

The review will be subdivided on the basis of the site of observation and the site of injury. Where sufficient data exist, electrophysiological and morphological findings will be discussed separately. A consideration of repair techniques that have been examined will be included.

(II) Responses in the Nerve Trunk and its Target Organs

(A) INJURY TO THE LINGUAL NERVE

For the purpose of this review, the chorda tympani has been 'adopted' into the trigeminal system, since it constitutes an important component of the lingual nerve trunk in the region in which it is susceptible to injury.

Observations on lingual nerve damage have been made with two different but compatible problems in mind. Because damage to the lingual nerve causes changes in the epithelium of the tongue and in particular in the differentiation of the papillae and taste buds, a number of investigators have used this model to exam-

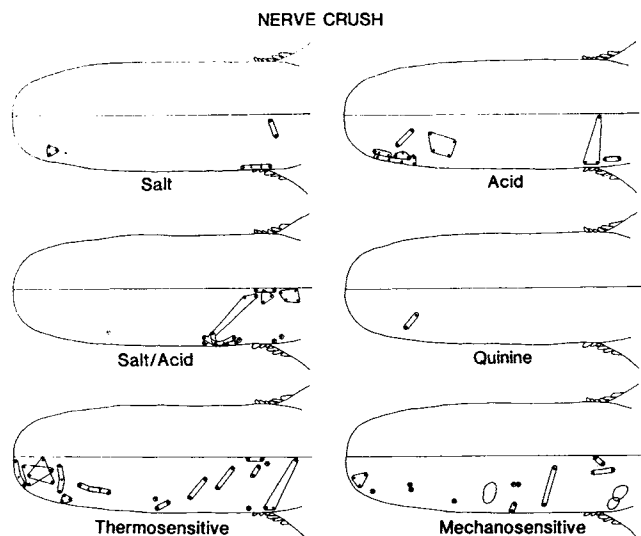


Figure 1. The receptive fields of single units of the chorda tympani three months after nerve crush classified according to the stimulus which evokes the most vigorous discharge. (From Robinson, 1989, with permission)

ine the trophic role of the nerve and the interaction of axons and epithelially derived cells in the sensory transduction process (*e.g.*, El-Eishi and State, 1974). Other investigators have looked at peripheral changes as a measure of the severity of nerve damage and as an assessment of the success of reparative procedures (*e.g.*, Robinson, 1989; Smith and Robinson, 1995a).

The chorda tympani contains taste and thermosensitive afferents from the fungiform papillae on the anterior two-thirds of the dorsum of the tongue, mechanosensitive fibers, preganglionic parasympathetic secretomotor fibers to the submandibular and sublingual salivary glands, and efferent vasodilator fibers to the tongue. The lingual nerve proper supplies the anterior two-thirds of the tongue with general afferent and sympathetic fibers. One of the valuable aspects of looking at damage to the lingual nerve is that it allows for comparison of the rate and extent of recovery of nerve fibers of different sizes and functions.

Two types of lingual nerve injury have been investigated, crushing and transection. Crushing injuries are less severe than transection injuries (Sunderland, 1951). In both cases, the axon distal to the injury site degenerates. After a crush injury, but not a transection, the connective tissue elements remain in continuity and provide guidance for axonal sprouts from the regenerating central stump (for review, see Lundborg, 1988).

(1) Electrophysiological observations

Chorda tympani

Experiments in the gerbil (Cheal *et al.*, 1977) and cat (Robinson, 1989) show a much greater recovery of taste

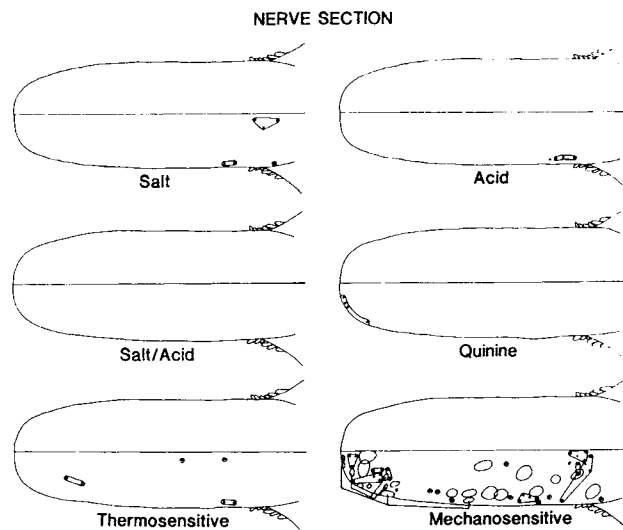


Figure 2. The receptive fields of single units of the chorda tympani three months after nerve section classified according to the stimulus which evokes the most vigorous discharge. (From Robinson, 1989, with permission)

fiber activity after crush injuries than after transection injuries. In the gerbil, activity in the chorda tympani central to a transection site in response to gustatory stimulation could be recorded from a whole nerve preparation in only two of nine animals two weeks after the injury, though a few single fibers responded in seven (Cheal *et al.*, 1977). In the cat, 12 weeks after transection of the combined chorda/lingual nerve, no significant whole-nerve activity could be recorded from the chorda tympani during gustatory stimulation of the tongue, though, again, occasional single responsive units could be found (Robinson, 1989). After a crushing injury, the basic whole-nerve response pattern is similar to that of controls (Fig. 1) (Cheal *et al.*, 1977; Robinson, 1989). Detailed examination of the responses of single units shows, however, that, even after a crushing injury, the responses to gustatory stimulation do not return to a completely normal level (Robinson, 1989). The range of effective stimuli is reduced, the discharge of single units is less vigorous, and there is an overall reduction in conduction velocities (Robinson, 1989). Mechanosensitive fibers predominate in the nerve recovering from transection (Fig. 2), suggesting that either mechanosensitive fibers regenerate more rapidly than other types of chorda afferents and/or that chorda fibers may grow down endoneurial tubes previously occupied by lingual axons and are able to make functional contacts. An alternative explanation may be that gustatory fibers are mechanosensitive at an early stage of their recovery.

Lingual

The lingual component of the nerve trunk is dominated by mechanosensitive fibers. These recover well after a

crush injury (Robinson, 1992), with receptor properties similar to those of controls 12 weeks after the injury, although conduction velocities are reduced. After transection, more severe changes are seen. The reduction in conduction velocity is greater, receptive fields are smaller, and thresholds are higher (Robinson, 1992).

Autonomics

Vasomotor activity can be estimated by measurement of tongue surface temperature after nerve trunk stimulation (Robinson, 1989). The same maximum tongue temperature as that of controls can be reached by stimulation after nerve crush, though the time taken to reach this maximum is increased. Vasomotor responses do return after transection but are reduced in magnitude. A similar pattern is seen when maximal submandibular flow rates are measured after stimulation of the nerve trunk. The response is similar to that of controls following a crushing injury but is reduced after transection (Robinson, 1989). Clearly, both parasympathetic and vasomotor fibers are able to regenerate and make effective functional connections.

The difference in response to the two injuries suggests that transection injuries are more likely to result in persistent abnormalities than crush injuries. This may explain the difference between patients who recover from an initial paresthesia and those who do not.

(2) Structural observations

Lingual epithelium

Lingual/chorda nerve injury leads to changes in the lingual epithelium. Taste buds are trophically dependent on an intact innervation by gustatory nerve fibers. Taste buds disappear from denervated tongues (Farbman, 1969; El-Eishi and State, 1974; State and Bowden, 1974) but redifferentiate when the innervation regenerates (Cheal and Oakley, 1977). Cutaneous sensory and motor nerves will not support the differentiation of taste buds, but chemosensory axons of the carotid sinus nerve do (Dinger *et al.*, 1985), as, to a limited extent, do non-gustatory vagal fibers (Zalewski, 1981). In regenerating taste buds, a subpopulation of cells expresses Neural Cell Adhesion Molecule (NCAM) (Smith *et al.*, 1993) that is first seen in regenerating nerve fibers (Smith *et al.*, 1994), suggesting, perhaps, that the recovering nerve initiates epithelial differentiation but that the differentiated taste bud then attracts sprouting axons. The epithelium of the circumvallate papillae (as well as the taste bud) may atrophy after denervation (El-Eishi and State, 1974), and the connective tissue core may disappear (Zalewski, 1981). Most of the studies that have looked at the effect of denervation on lingual epithelium have made observations after glossopharyngeal nerve section, but Cheal and Oakley (1977) and Robinson and Winkles (1991)

transected the chorda tympani. In the gerbil, beginning eight days after interruption of the chorda tympani, fungiform papillae were reinnervated and taste buds regenerated (Cheal and Oakley, 1977). Taste buds reform within two days of the reinnervation of the papilla. After a crushing injury of the chorda tympani, the taste bud population returns to more than 60% of control values but to less than 20% after transection (Cheal and Oakley, 1977).

Robinson and Winkles (1991) compared the distribution of fungiform papillae in cats three months after either transection or crushing the lingual nerve. After nerve crush, there were fewer fungiform papillae on the operated side than on the unoperated side, but the basic distribution was similar to that in controls. After nerve section, it was often difficult to distinguish between fungiform and filiform papillae on the operated side, and clearly identifiable fungiform papillae were much fewer on the operated side. This correlates well with the reduction in responses to gustatory stimuli. The recovery of taste buds is closely correlated with restored function as determined by the ability to distinguish between different salt solutions (St. John *et al.*, 1995).

Lingual/chorda nerve

Structural studies around the site of the injury also show changes complementary to those recorded electrophysiologically (Holland *et al.*, 1996a). Distal to both crush and cut injuries, there is an apparent increase in the number of fascicles. This indicates that, even after a crush injury, there is considerable damage to the perineurium. Perhaps the lingual perineurium is not as well-developed as in other sites. The number of non-myelinated axons distal to a transection injury is five times control counts and doubles after a crush injury, suggesting that axonal sprouting persists for at least 12 weeks after both injuries but is much greater after transection. A more rapid restoration of near-normal fibers distally after a crushing injury is consistent with better functional recovery (Robinson, 1989).

The principle change central to the injury site is a loss of small-diameter myelinated axons from the chorda tympani, which occurs only after transection. There is also an increase in the number of non-myelinated axons proximal to the damage, indicative of continued and probably recurrent (*i.e.*, centrally directed) sprouting following "dying back".

(3) Repair techniques

Epineurial suturing and entubulation

The recovery of a transected lingual nerve is limited by the poor opportunity sprouting axons have of extending down their original connective tissue sheaths, largely as a result of the retraction of the cut ends within the loose

connective tissue. Several techniques for re-apposing the cut ends or bridging the gap between them have been investigated. Simply suturing the cut ends together with fine sutures through the epineurium is the most successful method when the cut ends are not widely separated (Smith and Robinson, 1995a,b,c; Holland *et al.*, 1996b). This improves the proportion of gustatory units recovering and allows for good recovery of efferent vasomotor effects. An alternative approach, suturing the nerve ends within a perforated polyethylene tube, has the apparent advantage of keeping the sutures some distance away from the damaged ends of the nerve. However, little activity could be recorded from the chorda tympani central to the injury after this procedure (Smith and Robinson, 1995b). Neither type of repair prevents the increased fasciculation distal to the injury site, but epineurial suturing (though not entubulation) prevents the selective loss of small myelinated axons from the proximal chorda tympani after transection (Holland *et al.*, 1996b). Recurrent axons in the proximal nerve remain evident after both techniques. Distally, the recovery in the numbers of myelinated axons is also better after suturing, and the degree of non-myelinated sprouting is reduced.

Delayed repair

In a clinical setting, transected lingual nerves are rarely recognized and rarely repaired at the time of damage. Since the large majority of patients reporting loss of lingual sensation following the removal of impacted teeth show complete recovery within three months (Mason, 1988; Blackburn and Bramley, 1989; Rood, 1992), surgical repair is not attempted until beyond this point. In light of this, observations have been made to determine whether this delay affects the degree of success effected by epineurial suturing. In the case of the lingual component of the lingual/chorda tympani, examination of the responses in whole-nerve and single-fiber preparations suggests that, for the larger fibers, delayed repair results in only slightly better recovery than when the nerve is left unrepaired (Smith and Robinson, 1995a). Recordings of responses to gustatory and thermal stimuli from the chorda tympani showed that, 12 weeks after delayed repair, units had conduction velocities slower than those of unrepaired nerves. However, by 24 weeks after delayed repair, conduction velocities were significantly faster than those in unrepaired nerves. Vasomotor and secretomotor responses are restored after both immediate and delayed repair (Smith and Robinson, 1995d,e). Morphologically, nerves repaired three months after injury, when examined 12 weeks later, show considerable sprouting distal to the injury and significantly more than that seen after immediate repair (Holland *et al.*, 1996a). This suggests that, by structural criteria, it takes longer after a delay for the full extent of recovery to be reached.

Overall, delayed repair results in better recovery than when the nerve is left unrepaired. A 12-week delay prior to repair has little effect on the final outcome.

Grafting

Lingual nerves that require repair often show extensive neuroma formation at the site of injury that must be excised, leaving a sizable gap between central and distal segments. There are two basic approaches to repairing such injuries, either relieving the nerve ends from their surrounding connective tissue and stretching the segments together or adding material in the form of a graft to bridge the gap. Two types of graft material have been examined, autologous sural nerve and frozen muscle tissue (Smith and Robinson, 1995b,f). In the chorda tympani, the conduction velocities of the recovered nerves are higher and the secretomotor responses greater after "stretch repair" than after grafting. Stretch repair also results in the return of more gustatory units than grafting. There is no significant difference between the two graft materials.

(B) INJURY TO THE INFERIOR ALVEOLAR NERVE

The inferior alveolar nerve (IAN) is an interesting contrast to the lingual nerve in both composition (Holland, 1978) and local anatomy. It has a less extensive range of fiber types than in the lingual/chorda tympani, lacking the special sense and secretomotor components. It also lies protected within a bony canal.

(1) Electrophysiological observations

The nerve trunk

Recording directly from the nerve trunk central to the injury site after section and ligation demonstrates the development of spontaneous activity in myelinated afferents (Bongenhielm and Robinson, 1996) and the mechanical sensitivity of the induced neuroma. These changes decrease with time.

The dental pulp

The tooth provides a convenient target organ from which to monitor the effect of IAN damage and to follow the progress of reinnervation. Electrical stimulation of the tooth at appropriate levels induces a jaw opening reflex that is lost after section of the IAN (Robinson, 1981; Berger *et al.*, 1983). In the cat (Robinson, 1981), with no attempt at nerve repair, the jaw opening reflex elicited from the canine tooth returns from three to nine weeks after the injury. The electrical threshold required to initiate the reflex is increased, however, and the reflex has a prolonged latency. The conduction of impulses in regenerated pulpal fibers can be demonstrated by stimulation of the nerve central to the injury and recording from dentin and *vice versa* by stimulation of the tooth and

recording from the nerve (Fig. 3) (Holland *et al.*, 1987). In the rat, injuring the nerve central to the incisor apex raises the reflex threshold substantially in the first and second but not the third molars (Berger and Byers, 1983), because the rat third molar has an innervation derived from the mandibular nerve proximal to its entry into the inferior alveolar canal (Johansson *et al.*, 1992). Recovery in this species began at one week and was complete three to six weeks post-injury.

In the cat, if recovery is prevented by capping the cut end of the IAN with a nylon tube (Robinson, 1981), the tooth still becomes reinnervated. Collateral sprouts from the ipsilateral mylohyoid nerve, the ipsilateral and contralateral lingual nerves and the contralateral IAN enter the pulp. Except for the ipsilateral lingual nerve, these do not normally innervate the pulp. Mucosal and skin re-innervation follows a similar pattern. A collateral re-innervation crossing the mid-line has not been demonstrated elsewhere. If the original innervation is allowed to regenerate after such a collateral re-innervation has been formed, the collateral innervation is not withdrawn (Robinson, 1984). When the injury is extended to mimic some aspects of reconstructive jaw surgery (osteotomy with segmental repositioning with or without bone grafting; Robinson, 1980, 1986), reinnervation of the tooth pulp still occurs but with fewer nerves of slower conduction velocities. The sources of the recovered innervation are the recovering ipsilateral IAN, the contralateral IAN, and the mental and lingual nerves on both sides.

The periodontal ligament

While the pulpal nerves serve principally nociceptive and vasomotor roles, periodontal fibers signal position and movement. These are large-diameter axons that appear to recover well from injuries. Three months after section of the inferior alveolar nerve, single axonal units of that nerve have properties (Linden and Millar, 1992) and a distribution (Loescher and Robinson, 1989) similar, in general, to those in uninjured nerves. More detailed examination, however, reveals that the range of directions to which each receptor responds is significantly smaller after injury, whether the injury to the nerve trunk is a transection or a crushing lesion (Loescher and Robinson, 1989). Periodontal fibers are either rapidly or slowly adapting, and the balance after injury increases in

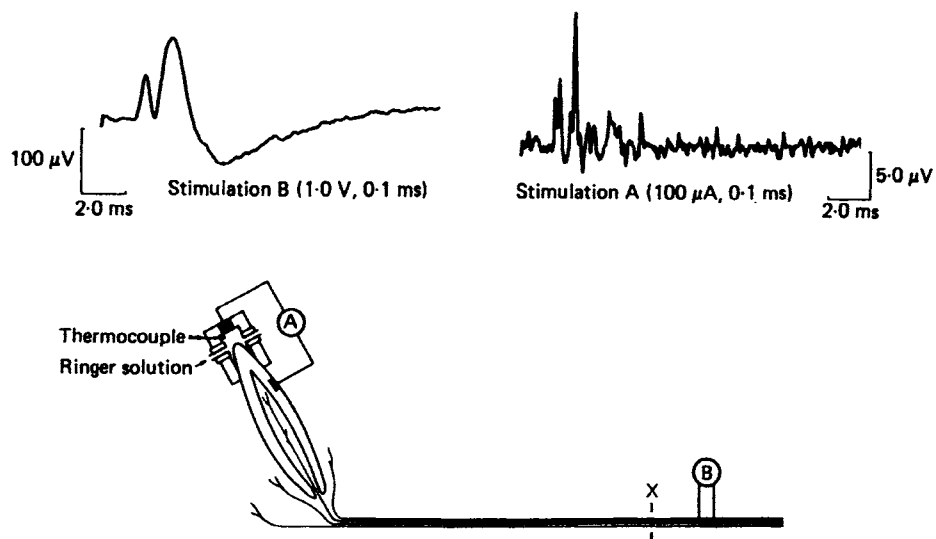


Figure 3. Compound action potentials recorded from the canine tooth (top left) and the inferior alveolar nerve (top right), demonstrating conduction of impulses in regenerated pulpal nerves. The inferior alveolar nerve was sectioned at 'X' 12 weeks previously. The stimuli used are indicated under each record. The record from the inferior alveolar nerve is the average of ten successive responses. (From Holland *et al.*, 1987, with permission)

favor of the rapidly adapting fibers. Force thresholds increase and conduction velocities are reduced after transection but not after crushing injury (Loescher and Robinson, 1989). The periodontal receptors have been examined after a much longer recovery period than have pulpal receptors. Twelve months after transection, units still have thresholds higher than those of controls as well as lower mean discharge frequencies and reduced arcs of sensitivity (Loescher and Robinson, 1991).

Freezing, a type of injury whose consequences have not been examined elsewhere in the trigeminal system, has been the subject of investigation in the periodontal ligament (Loescher and Robinson, 1990). This is a mild injury in that, while it interrupts axonal continuity, it has minimal effect on the connective tissue components of the nerve, and the maximal benefit of endoneurial sheath guidance is available. Somewhat surprisingly, the arcs of sensitivity of the receptors, force thresholds, and other parameters are affected to a similar extent as after nerve crush, leading to the conclusion that the alterations in receptor properties after nerve injury cannot be attributed to a mismatch between the regenerating axons and their receptors.

(2) Structural observations

The nerve trunk

In a transected IAN whose cut ends are re-apposed, no long-term differences from controls are seen proximal to the injury (Fried and Erdelyi, 1982; Holland and Robinson, 1990a). Distal to the injury site, there is a persisting reduction in the size of myelinated axons (Fried

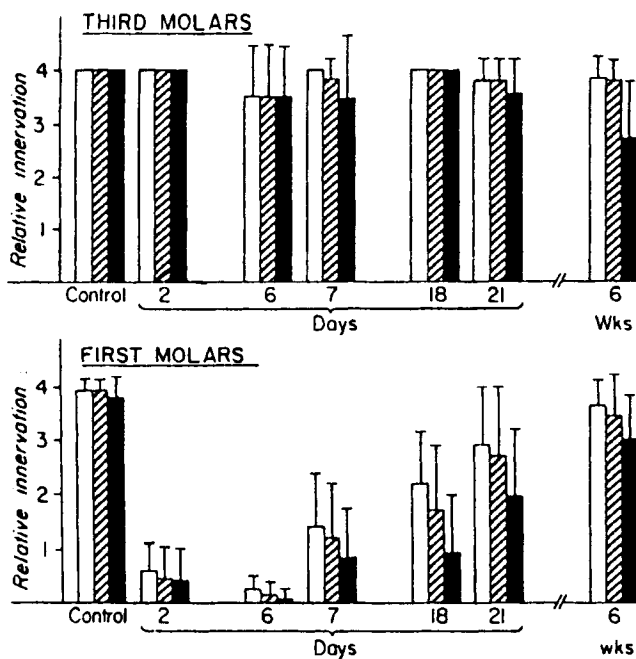


Figure 4. Quantitative data of relative innervation of pulp (white bars), crown plexus (striped bars), and dentin (black bars) in third molars (upper graph) and first molars (lower graph). Relative innervation is indicated on the vertical axis by 0 = absent, 1 = sparse, 2 = half-normal, 3 = 3/4 normal, and 4 = normal. The time after inferior alveolar nerve section is indicated on the lower axis. (From Berger and Byers, 1983, with permission)

and Erdelyi, 1982; Holland and Robinson, 1990a). Initially, there is evidence of extensive non-myelinated sprouting distally (Holland and Robinson, 1990a), but this does not continue in the long term (Fried and Erdelyi, 1982).

Blocking regeneration of the transected nerve by ligating the central stump and sealing it within a nylon tube results in a large increase in both myelinated and non-myelinated axons in the central stump, presumably as a result of sprouting and recurrent loops (Holland and Robinson, 1990a).

Dentin and the dental pulp

Several structural studies have looked at the dentin, dental pulp, and periodontium after injury to the IAN. They have had three main purposes: first, as a means of identifying nerves in dentin and their possible relationship to odontoblasts; second, to demonstrate the possible neural control of dentin formation; and third, to assess, as has been described above, the extent of recovery after nerve damage.

Although approximately 10% of the pulpal innervation in the cat is not derived from the IAN (Holland and Robinson, 1984), virtually all of the intra-dentinal axons disappear 56 hours after transection of the IAN (*e.g.*, Holland *et al.*, 1987). By 12 weeks post-injury, 44% of the

predentinal tubules are reinnervated. Similar levels of reinnervation in the rat have been reported when antero-grade autoradiographic tracing was used (Fig. 4) (Berger and Byers, 1983). The rat studies looked histologically at earlier and more frequent stages in the recovery. Pulpal reinnervation began seven days after the injury, with a 50% recovery of pulpal innervation and a 25 to 50% recovery of dentinal innervation by three weeks (Berger and Byers, 1983). Near-normal values were restored by six weeks. In the cat, the pulp itself shows an apical reinnervation (total axon count) to 90% of control values at the same point in recovery (Holland and Robinson, 1985). The comparable collateral reinnervation occurring after blocking recovery of the transected nerve is 33% of controls (Holland and Robinson, 1987).

Clearly, the denervated dental pulp provides a strong attraction not only for recovering injured axons but also to uninjured axons from nerves that did not normally supply the pulp. The most obvious candidate for this role is nerve growth factor (NGF). NGF receptor immunoreactivity has been demonstrated in some pulpal axons and Schwann cells (Byers, 1990; Fried and Risling, 1991) and, most intriguingly, in the sub-odontoblastic cell-rich zone (Byers, 1990). These are low-affinity neurotrophin receptors that bind all known neurotrophins. In developing rats, the administration of anti-NGF reduces the level of apical innervation 26 days post-natally by 38% for myelinated nerves and 59% for unmyelinated nerves (Qian and Naftel, 1994). Auto-immunization against NGF also substantially reduces the extent of collateral reinnervation when recovery of a transected IAN is prevented (Doubleday and Robinson, 1994). NGF mRNA is expressed in response to tooth injury even in denervated teeth, suggesting that its regulation is, at least in part, under non-neural control (Byers *et al.*, 1990).

Denervation of the tooth results in increased eruption rates in rat (Taylor and Butcher, 1951) and rabbit (Brown *et al.*, 1961) incisors, though this change is not apparent in teeth of limited eruption (Edwards and Kitchen, 1951). It is possible that the increased speed of eruption is linked to enhanced hard tissue formation and that dentin formation is under neural influence. Evidence for this concept is incomplete. Avery *et al.* (1971) reported reduced dentin formation and extensive defects at the incisal edge of the rabbit incisor after both IAN resection and superior cervical sympathectomy. Changes were predominantly in the older part of the tooth, and only slight alterations of the incremental pattern were seen at the growing end. In the rat incisor, however, no quantitative alteration in the deposition of dentin after denervation could be detected (Torneck *et al.*, 1972). When the rabbit incisor is subjected to cavity preparation, there is a dramatic increase in dentin deposition 14 and 35 days following IAN resection (Avery *et al.*, 1974) but not following superior cervical sympathectomy.

This suggests that any trophic effect is demonstrable only on active odontoblasts and that the effect is not vascular even though some of the sympathetics are carried in the IAN (Christensen, 1940). What is a little more difficult to resolve is the effect that a sensory deficit has on dentin formation. Loss of the afferent input from the pulp, periodontal ligament, and periosteum could result in increased attrition, and this, in turn, could lead to increased dentin formation. No studies published thus far have controlled for this effect. Radiolabeling experiments have shown an increased uptake of both amino acids (Chiego *et al.*, 1981, 1986) and carbohydrate precursors (Chiego *et al.*, 1985) by odontoblasts after both IAN section and sympathectomy. The increased uptake of amino acids was demonstrated in teeth of both continuous eruption (Chiego *et al.*, 1981) and limited eruption (Chiego *et al.*, 1986). The realization that pulpal afferents may play a major role in controlling pulpal blood flow—particularly in response to injury (Olgart, 1991)—complicates our understanding of possible neurotrophic effects. In cat canines in which shallow cavities had been prepared, transection of the IAN results in enhanced substance-P-induced vasodilatation in the pulp (Olgart *et al.*, 1993) seven and 30 days post-operatively, which coincides with increased regular secondary dentin formation. By 180 days post-operatively, with the reinnervation of the pulp, vascular responses return to control levels. Interestingly, total regular secondary dentin formation by 180 days is similar in both denervated and control teeth. Denervation seems to result in a much higher rate of secondary dentin formation, but reinnervation leads to a slowing below control values, so that the total amount deposited over six months is similar in denervated and intact teeth. With the greater understanding we now have of both neurotrophic and growth factors and of the role of pulpal afferents in vascular control, investigation of the intriguing relationship between innervation and dentinogenesis should be extended.

Periodontal ligament

Essentially all the axons in the periodontal ligament travel in the IAN (Loescher and Robinson, unpublished observation), and thus all are lost after posterior IAN section. If the cut ends of the IAN are re-apposed, there is a substantial recovery of the periodontal innervation as evidenced by the electrophysiological findings described above. Morphologically, the recovery is not as extensive as that found in the pulp (Loescher and Holland, 1991). Total axon counts are 50% of those of controls, with the reduction being relatively evenly distributed across the fiber size groups. The reduced innervation is also organized somewhat differently, with fewer large non-myelinated and large myelinated axons being found on the distobuccal aspect. The myelinated axons are narrower with a thinner myelin sheath, consistent

with their reduced conduction velocities. This is similar to the change occurring in the dental pulp. Longer recovery periods may allow for a closer return to control values in terms of both number and size of fibers, although electrophysiological observations made one year after denervation (Loescher and Robinson, unpublished observations) suggest that the change in receptor morphology is permanent.

(3) Repair techniques

With such successful recovery after simple re-apposition, and even following blocked regeneration, it is not surprising that little effort has been expended in developing techniques to enhance repair of the IAN. However, the accessibility and mechanical support of the IAN make it a good model for some experimental approaches. NGF applied locally in a silastic tube between the cut ends of a transected IAN significantly improves recovery over that occurring along a tube with no NGF (Eppley *et al.*, 1991).

(C) INJURY TO THE MENTAL NERVE

Although the effects of IAN damage are usually most appreciated in the distribution of the mental nerve, and the nerve itself is sometimes damaged independently of its parent trunk during flap surgery, it has rarely been the subject of experimental investigation. Recovery from a transection injury, as determined by the return of withdrawal reflexes and the central transport of either dyes or horseradish peroxidase (Zuniga and O'Connor, 1987; Zuniga *et al.*, 1990), is improved by approximating the cut ends with epineurial sutures but is not enhanced further by autogenous nerve grafting, a conclusion similar to that reached more recently for the injured lingual nerve (Smith and Robinson, 1995c).

(D) INJURY TO THE INFRA-ORBITAL NERVE

There is a very substantial body of knowledge on the effects of injury to the infra-orbital nerve (*e.g.*, Henderson *et al.*, 1993) that has been carried out on neonatal animals to determine the degree of plasticity of the developing sensory nervous system. Much less attention has been given to responses in the adult animal.

Structural observations

Recovery of the infra-orbital nerve, as judged by the return of the sensory innervation to the vibrissae in a rat, is very good after a crush injury (Renehan and Munger, 1986). The only detectable difference from controls is a small reduction in the proportion of Merkel cells innervated. Nerve section without repair, however, results in misdirected axons and abnormally reinnervated receptors. This difference in response is similar to that reported more recently for the lingual nerve (Robinson, 1989; Holland *et al.*, 1996b).

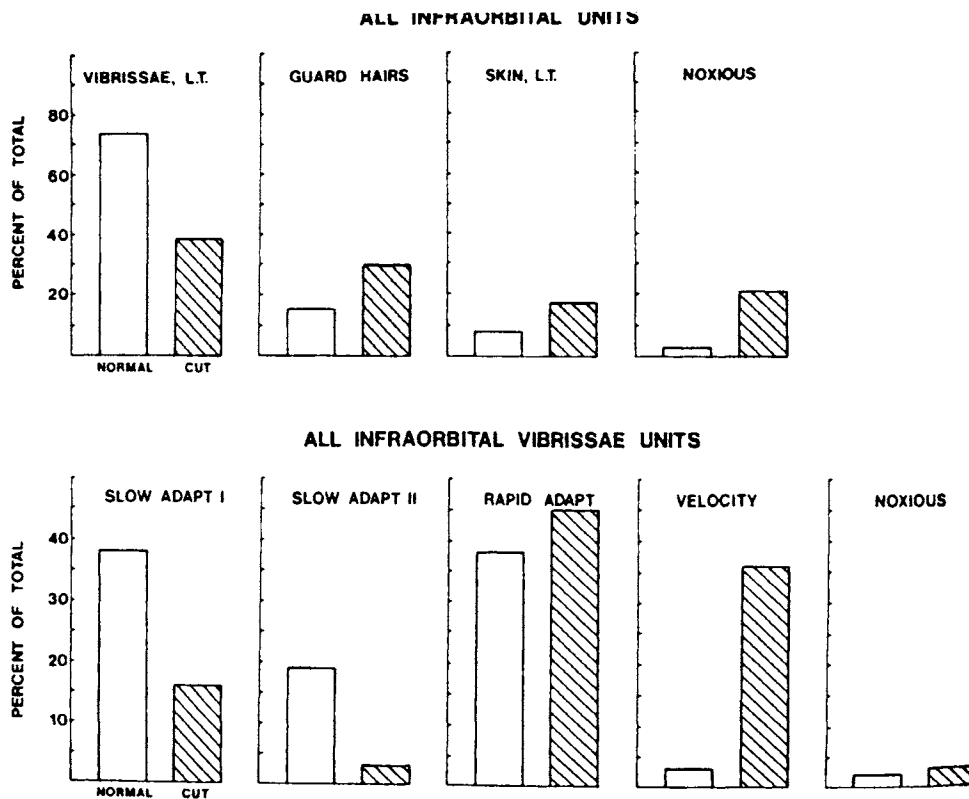


Figure 5. The upper histogram depicts the relative percentages of all primary afferent neurons with infra-orbital receptive fields recorded in the trigeminal spinal tract. Graphs indicate those units that responded to low-threshold vibrissa, guard hair, skin, or noxious mechanical stimuli. The left columns illustrate the percentage of units recorded in normal animals, and the right shows the percentage recorded in animals subjected to transection of the infra-orbital nerve 60 or more days earlier. The lower histograms show the relative percentages of units with vibrissae-receptive fields only. (From Renehan *et al.*, 1989, with permission)

(E) INJURY TO THE OPHTHALMIC NERVE

The trunk of the ophthalmic nerve is rarely damaged clinically, and experimental data on it are absent. Interest in the ophthalmic nerve is focused on its role in the inflammatory response to injuries of the cornea (*e.g.*, Butler *et al.*, 1980; Unger *et al.*, 1985). In this respect, the observations made on it closely parallel those made on dental pulp and periapical tissues to elucidate the role of sensory afferents in response to pulpal injury (*e.g.*, Byers, 1994). These reactions are beyond the scope of the present review.

(III) Responses in the Trigeminal Ganglion

(A) INJURY TO THE INFRA-ORBITAL NERVE

(1) Electrophysiological observations

Electrophysiological recordings from the cells of the trigeminal ganglion following nerve injury give a direct insight into the effect of the injury on the properties of the primary afferent neuron (Fig. 5) (Renehan *et al.*, 1989). Sixty or more days after transection of the infra-orbital

nerve in the rat, the receptive fields differ from controls in being discontinuous, presumably due to the misdirected regeneration of axonal branches. Some units also respond to both guard hair and vibrissal movement, and others, possibly associated with a neuroma, respond to deep pressure. Spontaneously active neurons are essentially absent, but several that respond to electrical stimulation of the nerve do not have a receptive field in the infra-orbital region. The proportion of ganglion cells that respond optimally to noxious stimuli increases, consistent with the clinical impression of discomfort commonly arising from healing nerves. Somewhat paradoxically, the proportion of cells responding to guard hair stimulation also increases, while the proportion responding to vibrissal stimulation is reduced. This may reflect an inherent difference between these

receptor types in their ability to attract regenerating sprouts.

(2) Structural observations

Retrograde tracer studies have shown that there is an extensive re-organization of the ganglion following infra-orbital nerve transection (Renehan *et al.*, 1989). The topographical representation of vibrissal units present in control animals is almost completely lost. This is likely to be a result of the misdirection of regenerating axons that also results in discontinuous receptive fields. Cell death also occurs as a result of transection of the infra-orbital nerve (Aldskogius and Arvidsson, 1978). There is an apparent 14% mean reduction in cell populations of rat trigeminal ganglia. It is interesting to note that, after transection, the number of cells counted on the operated side, while lower than that on the unoperated side in the same animals by 14%, is higher than counts from unoperated control animals by 19%. The cell counts on the unoperated sides of the experimental animals increased by 38% as compared with contralateral controls. The explanation probably lies in the technique

used for cell counting which relies on counting nucleoli and which, while allowing for double nucleoli, does not allow for the possible presence of inconspicuous nucleoli which become evident only after the release of some systemic factor following nerve damage (Holland and Robinson, 1990b). This means that, while there is cell death, the reported extent is probably an overestimate by somewhere from 19 to 38%. Nonetheless, this injury does result in a loss of ganglion cells of the order of four to five thousand cells in the cat. This loss would cause the degeneration of central processes and may explain some (but not all) of the central changes seen in the trigeminal nuclear complex to be described in a later section.

(B) INJURY TO THE INFERIOR ALVEOLAR NERVE

Structural observations

Simple transection of the IAN is rapidly followed by changes in neuropeptide expression in the ganglion cells of the rat (Wakisaka *et al.*, 1995). Neuropeptide Y (NPY) is not normally expressed in uninjured ganglion cells but begins to be shortly after transection and reaches a maximal level in three days. Fourteen days after transection of the mental branch of the IAN, 35% of the cell bodies with axons in the nerve (as identified by retrograde labeling) showed NPY activity (Wakisaka *et al.*, 1993). The functional role of NPY in injured neurons is unclear, though it has been suggested that NPY may be involved in the inhibition of nociceptive input (Mantyh *et al.*, 1994). This expression seems to be limited to large and medium-sized cells (Sasaki *et al.*, 1994).

Transection with good re-apposition of the cut ends of the nerve does not result in cell death in the cat, but if the central end is cut and regeneration prevented, cell death is considerable (Holland and Robinson, 1990b), averaging 25% of the ganglion population. The exaggeration of the cell loss brought about by the counting technique as described above makes this change appear more extensive than it actually is. Nonetheless, after allowing for this inaccuracy, transection and capping of a nerve containing around thirteen thousand axons result in the loss of more than three thousand ganglion cells. Retrograde labeling experiments in the rat (Takemura *et al.*, 1990) show that 56.8% of the cells labeled in controls were labeled ten weeks after transection. It is difficult to translate this into absolute figures, but the loss is clearly considerable. A complex labeling experiment involving labeling axons retrogradely before and after transection of the mental branch of the IAN (Zuniga *et al.*, 1990) suggests that immediate re-apposition of the cut ends results in minimal cell death, but failure to repair the injury leads to extensive cell death proportional to the size of the nerve. The absence of significant cell death after simple transection is supported by the labeling

study of Fried *et al.* (1991). Ganglion cells supplying the pulp were retrogradely labeled with fluorogold four to six weeks after the IAN had been sectioned and the cut ends were re-apposed. The number of labeled ganglion cells was only slightly lower than that in controls. A greater proportion of the ganglion cells, however, were substance-P- but not calcitonin-gene-related-peptide (CGRP)-immunoreactive, which is somewhat surprising since these peptides are often co-localized. The site of the lesion as well as its severity may be a factor in the induction of cell death. When the mandibular nerve, the parent trunk of the IAN, is sectioned at the foramen ovale, there is evidence of cell necrosis as well as chromatolysis in the ipsilateral ganglion (Gregg, 1971).

(C) DENTAL LESIONS

Structural observations

Rat ganglion cell responses have been examined in response to tooth extraction (Strassburg, 1967; Hansen, 1980), partial tooth extraction (Fried *et al.*, 1991), and pulpal injury (Stephenson and Byers, 1995). The principle finding after tooth extraction is chromatolysis (Strassburg, 1967; Hansen, 1980), in which the cell bodies are swollen with their nuclei displaced to one side in clear cytoplasm whose darker contents are dispersed to the periphery. This may be not a degenerative but rather a reversible process which marks the beginning of the neuron's response to injury. It is seen within twelve hours of the injury and is more extensive with more teeth extracted. The number of cells showing chromatolysis rises to a maximum within eight days and then declines steadily, with only a few cells having this appearance thirty days after the injury. The only study that has counted trigeminal ganglion cells after dental injuries (Fried *et al.*, 1991) labeled the cells supplying the dental pulp retrogradely prior to extracting most of the tooth. Four to five weeks after the injury, the number of labeled cells was lower than in controls and also lower than after transection of the inferior alveolar nerve. This suggests that there is cell death, which would, on first consideration, seem unlikely since the lesion is mild and very peripheral. However, as the authors point out, tooth extraction removes the target organ and may, in reality, be a more severe lesion than transection as the reinnervation of an appropriate target becomes impossible. Fried *et al.* (1991) also looked at the neuropeptides expressed in the pulpal ganglion cell bodies after tooth damage. The expression of substance P immunoreactivity is similar to that in controls, but the number of cells showing CGRP immunoreactivity is reduced. This most likely indicates an expression of substance P in cells that previously did not express it, though it may be an indication that substance-P-immunoreactive cells are more likely to survive a dental injury.

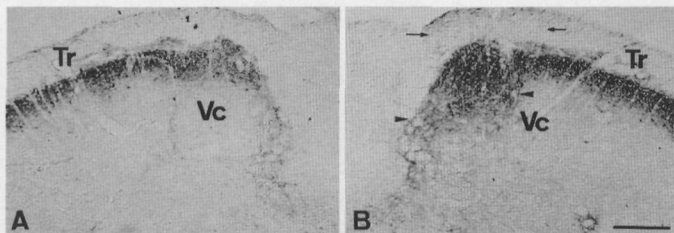


Figure 6. Photomicrographs of NPY immunoreactivity in the subnucleus caudalis (Vc) in the sham-operated side (A) and the nerve-injured side (B) 14 days following inferior alveolar nerve transection in a rat. Increased NPY immunoreactive axons and nerve terminals are observed in the dorso-medial portion of the spinal trigeminal tract (TR, arrows). Scale bar = 200 μ m. (From Sasaki *et al.*, 1994, with permission)

(IV) Responses in the Mesencephalic Nucleus

INJURY TO THE MANDIBULAR AND INFERIOR ALVEOLAR NERVES

Structural observations

A significant proportion of the primary afferent cell bodies of the trigeminal system are located in the mesencephalic nucleus within the central nervous system. Although their location is different, the response of the cell bodies is similar to that of those in the ganglion. Transection of the mandibular nerve near the foramen ovale results in chromatolysis in many of the mesencephalic cell bodies and the loss of around 25% of the cells (Imamoto, 1972). Many afferents in the masseteric nerve have their cell bodies in the mesencephalic nucleus. Transection of this nerve results in death of from 10.5 to 22.7% of the cells in the mesencephalic nucleus (Raappana and Arvidsson, 1992). This differs from simple transection of the inferior alveolar nerve, which does not result in ganglion cell death (Holland and Robinson, 1990b). It may be that, as Raappana and Arvidsson (1992) suggest, proprioceptive neurons are very sensitive to injury, or it may be the result of the greater separation, due to retraction, of the cut ends after masseteric nerve transection. It is also possible that the micro-environment of these neurons within the central nervous system rather than in a peripheral nervous system ganglion may affect their susceptibility.

(V) Responses in the Trigeminal Nucleus

The brainstem trigeminal complex extends from the upper segments of the spinal cord to the pons and is divided into the largest and most rostral unit, the main sensory nucleus, and three progressively more caudal spinal nuclei: oralis, interpolaris, and caudalis. At each level, the dorsum of the nucleus has a lamellar organization (Gobel, 1978a,b). The outer three layers—the marginal layer, the substantia gelatinosa, and the magnocellular layer—are involved in relaying and modifying sen-

sory input. Since the nucleus caudalis is considered to be the main component of the trigeminal complex involved in nociception, it is this region that has been most heavily investigated.

(A) INJURY TO THE LINGUAL/CHORDA TYMPANI

Structural observations

There are apparently no published studies on the central effects of damage to the combined lingual/chorda tympani nerve, a void that seems particularly regrettable for the trigeminal nuclear complex. Transection of the chorda alone in the middle ear of the hamster results in the degeneration of central axonal terminals in the chorda tympani entry zone of the nucleus of the solitary tract (Whitehead *et al.*, 1995). Examination of geniculate ganglion cells labeled by dye injection into the tongue shows that the chorda tympani ganglion cells survive transection and can regenerate axons to the tongue (Whitehead *et al.*, 1995). Most remarkably, the degenerative changes in the solitary tract persist for at least 161 days post-injury.

(B) INJURY TO THE INFERIOR ALVEOLAR NERVE

Structural observations

Transection of the IAN results in degeneration of the terminals of the primary afferents in the nucleus caudalis and transsynaptic degeneration of neurons that is enhanced by the administration of strychnine (Sugimoto *et al.*, 1985). Neuropeptide Y immunoreactivity is increased in the trigeminal nucleus following IAN transection, most markedly in the deeper laminae (III-IV) of the nucleus caudalis (Fig. 6) (Sasaki *et al.*, 1994). This is particularly interesting in light of the recent suggestion that NPY receptors may be involved in the inhibition of primary afferent nociceptors, especially after peripheral nerve injury (Mantyh *et al.*, 1994). It is surprising, considering the importance of this nerve trunk and the frequency with which it is damaged, that more studies of the central response to its injury have not been made.

(C) INJURY TO THE INFRA-ORBITAL NERVE

(1) Electrophysiological observations

Although earlier reports describe relatively few changes in the trigeminal nucleus after infra-orbital nerve transection in the adult (Waite, 1984), closer examination by single-unit recording techniques reveals an increase in the relative numbers of nociceptive units, guard hair, and high velocity adapting units as well as units that have either an unusual or no receptive field (responding to electrical stimulation of the proximal stump of the injured nerve but not to receptor stimulation in the normal distribution of the infra-orbital region) (Renehan *et*

al., 1989; Klein, 1991). There is also a reduction in the dorsoventral representation of the infra-orbital region, a loss of the somatotopic organization, an increase in the size of receptive fields and in the number of those that are discontinuous, together with a greater convergence of receptive fields (Klein, 1991).

(2) Structural observations

Transganglionic degeneration in the brainstem (Arvidsson and Grant, 1979) is seen from seven to 60 days after transection of the infra-orbital nerve. The degeneration occurs in the marginal zone, the magnocellular zone (laminae III & IV), and in the substantia gelatinosa. It follows a somatotopically organized pattern in both the nucleus and the sensory root; degeneration after transection of the supra-orbital nerve occurs more ventrally than that after infra-orbital nerve transection, which is, in turn, more ventral than that after mental nerve transection. Transganglionic degeneration continues for at least 130 days after the injury (Arvidsson and Grant, 1979). As it increases, it extends more caudally. It also occurs contralaterally to a much lesser extent (Arvidsson and Grant, 1979). The electrophysiological observations of Renehan *et al.* (1989) and Klein (1991) avoided any complication from contralateral effects by comparing the injured sides of transected animals with control animals. That the brainstem changes are truly degenerative is confirmed by the death of ganglion cells brought about by the same procedures (Aldskogius and Arvidsson, 1978; see discussion above). Cell death is not essential for transganglionic degeneration to be produced.

Limited dental lesions, such as pulpal extirpation, are unlikely, on present evidence, to lead to cell death in the ganglion but do lead to degenerative changes in the brainstem (Westrum *et al.*, 1976; Westrum and Canfield, 1977a,b; Johnson *et al.*, 1983). This leads to consideration of what transganglionic degeneration and recovery from it really mean. The functional data for nerve transection cited in this section and the data on primary afferent changes following dental lesions in the next section suggest that functional recovery occurs while structurally degenerative changes are continuing. c-Fos-like immunoreactivity in the brainstem is increased when the branches of the infra-orbital nerve that supply the vibrissae are transected (Sharp *et al.*, 1989). Expression of the c-Fos gene may be involved in mediating alterations in gene expression associated with CNS adaptations. This same study (Sharp *et al.*, 1989) included one of the few observations of the response of the contralateral cerebral cortex to peripheral nerve injury where, interestingly, the level of c-Fos-like immunoreactivity in the brainstem is decreased following nerve injury. Sharp and his colleagues suggest that this may be due to a reduced sensory or trophic input. A chronic constriction injury

model that produces behavior consistent with chronic pain (Vos *et al.*, 1994) also increases c-Fos expression in the outer lamellae of the spinal nucleus (Vos and Strassman, 1995). The behavioral effect is, presumably, produced by alterations in the central processing of afferent input.

Most previously reported morphological approaches are limited in that they can detect degeneration and the absence of degeneration but cannot discriminate or define recovery. Detecting biological markers for neuronal activity and axonal sprouting would profitably balance the present body of knowledge on degenerative responses to nerve injury.

There may be several forms of recovery. If there is cell death, then axons from remaining cells may sprout and provide terminals to the second-order neurons, replacing those that have been lost. In cells that survive, there may be degeneration of the terminals, but this is probably only a dying back, and new sprouts may return to re-establish the original pattern of the terminals. The extent to which these events occur and the degree to which they reproduce the original pattern of input depend, presumably, on the severity of the lesion (in terms of cell death and numbers of cells and axons affected) and the degree of peripheral recovery (whether the target organ is re-innervated). Transection of a peripheral nerve that recovers well and whose peripheral connections are effectively re-established (the inferior alveolar nerve) may result in the same initial brainstem changes as transection of a nerve that does not recover well (the lingual nerve), but the long-term recovery may be very different, especially if a neuroma is formed. Unfortunately, no studies have thus far correlated central and peripheral recovery.

(D) TERMINAL INJURIES (DENTAL PULP EXTIRPATION, TOOTH EXTRACTION, VIBRISSAE DENERVATION)

(1) Electrophysiological observations

Electrophysiological observations demonstrate that central changes resulting from minor peripheral injuries are recordable but reversible, attesting to the plasticity of the trigeminal system (Fig. 7). The tooth injuries applied to both cats (Hu *et al.*, 1986, 1990; Hu and Sessle, 1989) and rats (Hu *et al.*, 1992; Kwan *et al.*, 1993) from which central recordings were made were similar to the tooth pulp extirpations used in morphological studies (*e.g.*, Gobel and Binck, 1977; Westrum and Canfield, 1977a,b; discussed below). They may have been somewhat milder in that only part of the tooth pulp was removed and the apical pulp remained histologically normal at the end of the observation period. The electrophysiological experiments also differ in design from most of the morphological studies in other ways. The post-injury survival times

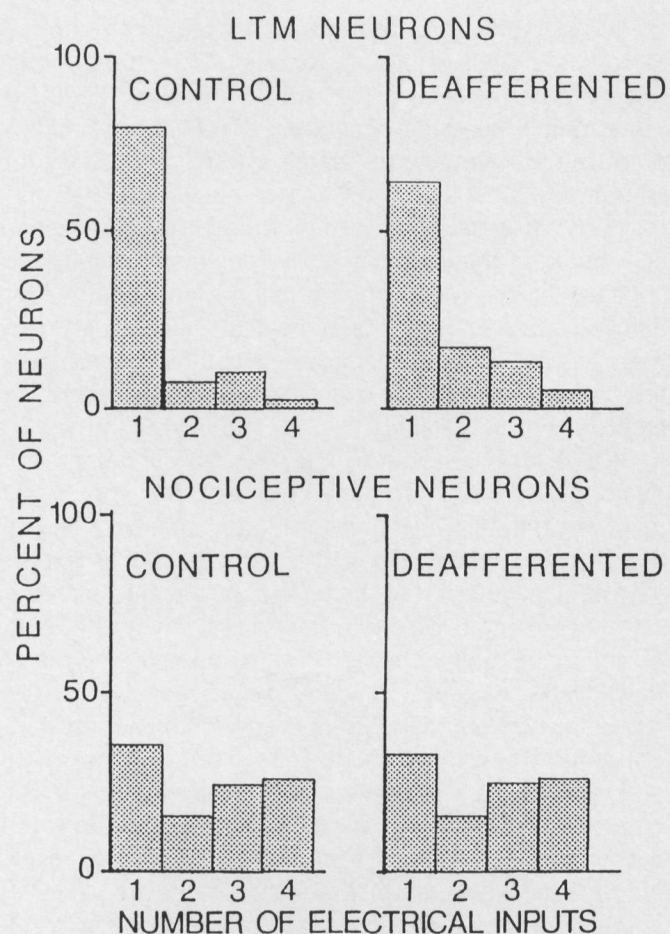


Figure 7. Distributions of proportions of low-threshold mechanoreceptive (LTM) and nociceptive neurons having excitatory input from one or more afferent sources in control and 7-15-day pulp-deafferented cats. The four electrically evoked inputs were facial skin/oral mucosa, tooth pulp, superior laryngeal nerve, and hypoglossal nerve. (From Hu and Sessle, 1989, with permission)

extend up to two years, the severity of the injury is increased (Hu *et al.*, 1990), and behavioral observations are made on the recovering animals (Hu *et al.*, 1986). Single-unit extracellular recordings, predominantly from low-threshold mechanoreceptive neurons, show that there are statistically significant changes in brainstem neuron properties in comparison with those in uninjured control animals. After multiple pulpotomies, fewer of the neurons respond only to mechanical stimulation within either the mandibular or maxillary division, but the number of neurons with fields in two or three divisions of the trigeminal system increases. This change is short-lived, since the proportion of neurons exhibiting these altered properties declines progressively during the seven- to 15-day post-injury period (Hu *et al.*, 1986). In the pulpotomized cats, there are also more spontaneously active neurons, though it is important to add that there are spontaneously active neurons in control animals and that the firing rate of the spontaneously active neurons

in the treated animals did not differ from the rate in controls. With longer survival times (Hu and Sessle, 1989), the incidence of spontaneously active neurons declines rather than increases in comparison with controls. The incidences and latencies of all oralis neuronal responses evoked by electrical stimuli applied inside as well as outside the normal mechanoreceptive field of these neurons did not change between control and deafferented groups. Over 50% of neurons could be activated by electrical stimuli applied to cutaneous or mucosal sites outside the V division(s) containing their localized mechanoreceptive field. Thus, the increase in mechanoreceptive field size and changes in the response properties associated with the pulp deafferentation may have involved unmasking of a previously silent afferent input to the neurons. Most of the responses to pulp deafferentation in the cat may also be observed in the rat (Kwan *et al.*, 1993). Recording in the subnucleus caudalis (Hu and Sessle, 1989) reveals that the incidence of nociceptive neurons responding to noxious heat stimuli is reduced by pulpotomy for 7-15 days after the injury but thereafter returns to control values. There is no other evidence of enhanced nociceptive activity after injury.

Hu and his colleagues (1986) interpret these results as consistent with an unmasking of existing afferent inputs following partial deafferentation (most neurons receive some of their input from non-pulpal afferents). Furthermore, Shortland *et al.* (1996) show evidence, based on intracellular staining of single primary afferent axons in the V brainstem complex, that seems to exclude the collateral sprouting of non-deafferented afferent inputs as an alternative mechanism. Deafferentation may lead to these central changes through an alteration in the extent of primary afferent depolarization-induced pre-synaptic inhibition. In intact animals, conditioning stimuli to afferents ending in the trigeminal nucleus readily induce such changes (Sessle and Dubner, 1971). However, Shyu *et al.* (1993) recently demonstrated that facial stimulation can induce primary afferent depolarization in endings in nucleus oralis to a similar extent in both control and pulp-deafferented rats, demonstrating that central changes previously reported in deafferented animals did not result from an alteration in peripherally induced pre-synaptic regulatory mechanisms. Apart from the unmasking mechanism proposed above, no convincing explanation of the physiological data associated with pulpotomy-induced neuroplastic changes has been put forward.

(2) Structural observations

The vibrissal innervation in the rat has an advantage as an experimental model in that it has a restricted, but well-defined and well-ordered, termination zone in the magnocellular layer of the nucleus caudalis (Arvidsson, 1986). Transganglionic degeneration is first detectable

ten days after transection of the vibrissal nerves just outside their follicles (Arvidsson, 1986), a time that corresponds closely with degeneration following the more radical and more central transection of the infra-orbital nerve (Arvidsson and Grant, 1979). The ganglionic effects of these more peripheral lesions have not been reported, but it would be surprising if they led to cell death, and it is most unlikely that this would have occurred by ten days. It may be safe to conclude that transganglionic degeneration is not (or not only) a sequel to neuronal death.

Following unilateral tooth extractions or pulpectomies, degeneration is seen bilaterally in the ventral half of the pars interpolaris and in the rostral pars caudalis (Fig. 8) (Westrum *et al.*, 1976; Gobel and Binck, 1977; Westrum and Canfield, 1979; Johnson and Westrum, 1980). Degeneration of terminals and of both myelinated and non-myelinated axons occurs (Gobel and Binck, 1977). The degenerative changes in the terminals of the trigeminal complex have been described at the ultrastructural level as consisting of electron-dense degeneration, neurofilamentous hyperplasia, flocculent degeneration, and glycogen accumulation (Johnson *et al.*, 1983). The degenerating material seems to have a different fate, depending on its position in the laminar organization of the nucleus. Glial cells rapidly phagocytose terminals in layer I, the process beginning as soon as 14 days after pulpal extirpation (Gobel and Binck, 1977), though debris is still present for at least 60 days after the injury. Although thin glial processes gradually surround degenerating endings in layers II and III, the endings do not appear to be phagocytosed but degenerate *in situ* (Gobel and Binck, 1977). The longer degenerative process in layers II and III parallels the degeneration of myelinated axons and leads to the suggestion that these are the terminals of myelinated axons (Gobel and Binck, 1977). Recent tracer studies injected horseradish peroxidase or neurobiotin intra-axonally into low-threshold mechanosensitive fibers 10 to 32 days following pulpotomy (Shortland *et al.*, 1996). The central collaterals of these uninjured trigeminal afferents show normal morphology and maintain normal somatotopy. Thus, changes in the morphology of low-threshold primary afferents cannot account for the changes that occur in the receptive field properties of trigeminal brainstem neurons after pulp deafferentation, described in the preceding section.

There is some unresolved controversy as to the presence of transsynaptic changes. Gobel and Binck (1977) and Gobel (1984) describe degenerative changes in the cell bodies and dendrites of layer I as soon as 14 days after tooth pulp extirpation, evident as large areas of cytoplasm devoid of organelles and as discontinuities in the cell membrane. In the same species and with similar survival times, Johnson *et al.* (1983) report, in a summary

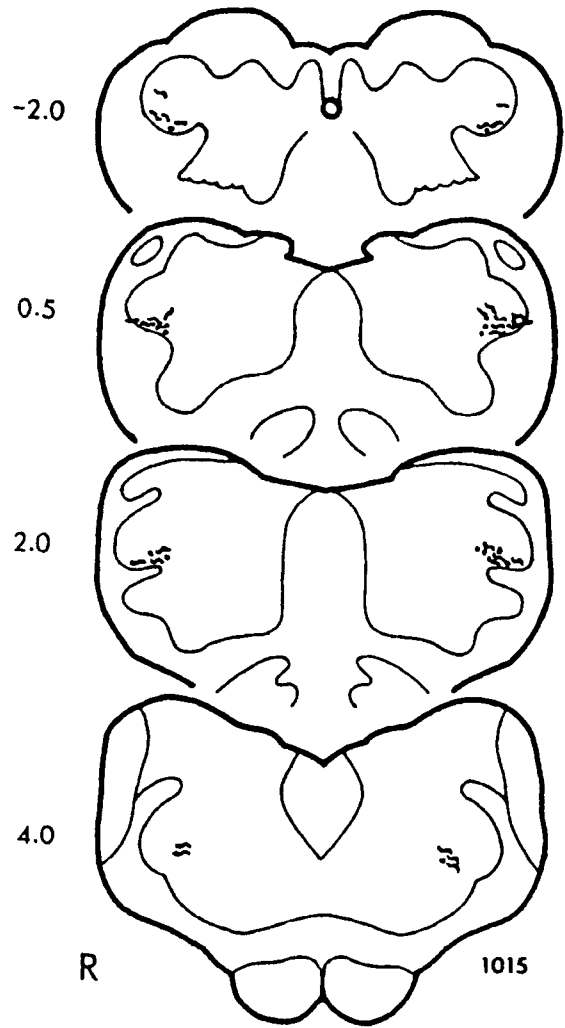


Figure 8. A drawing of silver-stained sections from a cat surviving four days after complete unilateral tooth pulpectomies, to show the degeneration pattern in various subnuclei of the spinal trigeminal complex. The two middle sections are from the pars interpolaris, the upper from the rostral pars caudalis, and the lower from the pars oralis. The numbers on the left represent the approximate distances in mm from the obex. The unoperated side is marked with an R. Irregular, wavy lines represent degenerating axons, and dots represent degenerating terminals. (From Westrum *et al.*, 1976, with permission)

of several studies, no changes in the post-synaptic profiles or in nearby somata. It may be that the post-synaptic changes are transient rather than truly degenerative, but this important point, in terms of the extent of central response to a peripheral injury, requires clarification.

No behavioral changes have been reported for animals in which these peripheral dental lesions were induced, and it seems unlikely that such changes would result in significant loss of function or disturbance of sensory input. Perhaps most telling in this regard is the finding of similar patterns of terminal degeneration occurring as a result of normal deciduous tooth exfoliation (Westrum and Canfield, 1979; Westrum *et al.*, 1984).

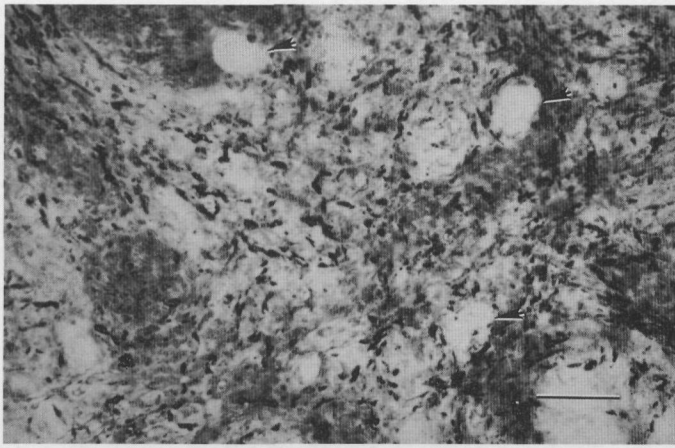


Figure 9. Light photomicrograph from the ipsilateral brainstem of a cat in which a retrogasserian rhizotomy was carried out four days earlier. The section is taken from the deeper laminae of the pars interpolaris-pars caudalis area near the obex. The tissue has been treated with a Nauta silver stain for detection of degeneration. The black precipitate surrounding the clear cell bodies (arrowed) marks degenerating terminals. Calibration bar = 25 μm . (Micrograph provided by Dr. L. Westrum, University of Washington)

Expression of proto-oncogene *c-Fos* in the brainstem has been interpreted as an indicator of continuing noxious input (*e.g.*, Sugimoto *et al.*, 1993), though the specificity of this seems unlikely since it can be induced by stimuli as mild as tooth movement (Kato *et al.*, 1994). This effect has received little attention as a response to injury rather than noxious stimulation in the trigeminal system. *c-Fos* expression in the nucleus caudalis increases after tooth extraction or pulp exposure, but the effect begins to decrease by eight hours and is very small 24 hours after the injury (Wakisaka *et al.*, 1992).

Toxins that induce neural degeneration have been used as an alternative to classic degeneration techniques and retrograde tracers to describe the central projection of dental afferents. The toxic lectin ricin, when placed in the dental pulp, causes, within six to eight days, central degeneration ipsilaterally and dorsally throughout the trigeminal nuclear complex and ventrally in the pars intermedius and pars caudalis (Johnson *et al.*, 1983; Henry *et al.*, 1987). This supports other evidence from pulpal extirpations (Gobel and Binck, 1977; Johnson *et al.*, 1983) of a dual dorsal and ventral projection of dental afferents. Degeneration (rather than chromatolysis) is also seen in the trigeminal ganglion. Similar changes are seen when this toxin or adriamycin (doxorubicin) is applied to a nerve trunk (Kato *et al.*, 1988) or around sensory nerve terminals (Bigotte and Olsson, 1987). Capsaicin is a toxin that has been widely used in neonatal animals for the selective destruction of narrow fibers. It is less effective in the adult. In neonatal animals, capsaicin greatly reduced the number of mechanically nociceptive neurons that also responded to noxious levels of heat, but this effect is absent in treated adult animals (Salt *et al.*, 1982).

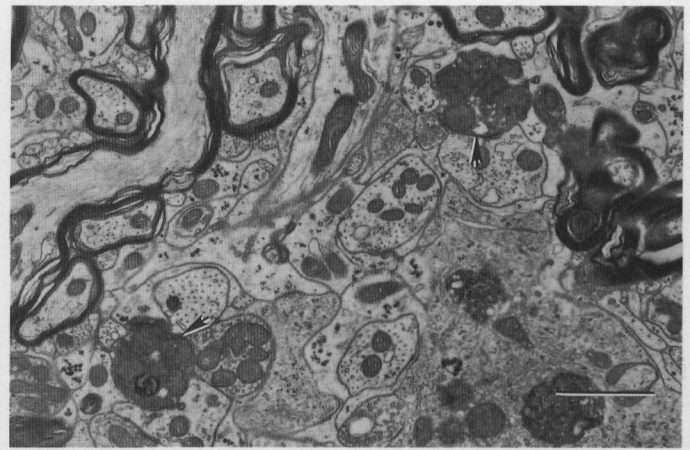


Figure 10. Electronmicrograph from the deeper laminae of the pars interpolaris-pars caudalis area near the obex of a cat whose trigeminal sensory root had been transected two days earlier. Arrows indicate degenerating terminals. Calibration bar = 1 μm . (Micrograph provided by Dr. L. Westrum, University of Washington)

(E) INJURIES TO THE TRIGEMINAL ROOTS—RHIZOTOMY

Structural observations

Sectioning the sensory root of the trigeminal nerve between the ganglion and the brainstem is a severe injury that results in extensive degeneration primarily in the ipsilateral trigeminal nucleus (Figs. 9, 10; Westrum and Black, 1968; Westrum, 1973; Westrum and Henry, 1991, 1993; Stover *et al.*, 1992). Paradoxically, it also causes a marked decrease in nerve growth factor p75 receptor immunoreactivity in the nucleus but an increase in NGF expression in the trigeminal ganglion, associated, presumably, with sprouting of the severed axons (Henry *et al.*, 1993). An increase in nerve growth factor receptor immunoreactivity also occurs in the trigeminal motor nucleus if the motor root is included in the rhizotomy (Kullas *et al.*, 1991). After sensory rhizotomy, CGRP immunoreactivity is reduced, particularly in the more rostral elements of the nucleus (Stover *et al.*, 1992). Cervical transection of the trigeminal tract eliminates most of the remaining CGRP immunoreactivity from the more caudal components, suggesting that some primary input is derived from lower levels. Some lesser degeneration is also evident in the contralateral nucleus caudalis (Westrum and Henry, 1991), and ultrastructural evidence (Westrum and Henry, 1993) suggests that some of the degenerating terminals are those of primary afferents but that others may be derived from intrinsic interneurons affected transsynaptically. The degenerative/regenerative process in the nucleus following rhizotomy is also reflected in changes in the level and distribution of acetylcholinesterase activity (Wilson *et al.*, 1988).

(VI) Neuromas, Deafferentation, and Chronic Pain

A case has been made, in the spinal system, for sensory nerve injury contributing to the genesis of chronic pain (for summaries, see Tasker and Dostrovsky, 1984; Devor and Rappaport, 1985; Cooper and Sessle, 1992). Neither the electrophysiological nor the morphological data summarized above support this concept in the trigeminal system. Both groups of data indicate that the changes following peripheral injury in the form of dental lesions would appear to be reversible, the functional recovery beginning to occur at approximately the time that morphological changes become detectable (7-10 days). However, the extent of the injury is small, and there is evidence that, following such injuries, the peripheral nerve recovers well (Fried *et al.*, 1991; Mason and Holland, 1993; Holland, 1994). Only one of the reports cited in this review (Vos *et al.*, 1994) describes behavioral changes in the experimental animals that would be consistent with chronic pain. More extensive and prolonged injury may result in more severe and enduring central changes. Hu *et al.* (1990) show that extending the severity of the pulp injury by including more teeth prolongs at least the time course of the central changes. Rhizotomy would denervate large numbers of second-order neurons and seriously disrupt synaptic arrangements. However, no reports of behavioral changes following this procedure are currently available.

Clearly, it would be of considerable interest to extend the observations of central change both morphologically and electrophysiologically to include more severe peripheral injuries. Severe injury compounded by restricted recovery such as that resulting from amputation can lead to the formation of neuromas. Neuromas are the greatly altered and distorted parts of a nerve in which the Schwann cell-endoneurial barrier has been broken and regenerated axons have escaped to grow in a disordered fashion in the connective tissue framework of the nerve trunk (Sunderland, 1978). They commonly occur at the end of severely damaged nerves but can also occur 'in continuity' along the course of a partially regenerated nerve. Some neuromas are painful. Painful neuromas outside the trigeminal system have been investigated and have been shown to exhibit spontaneous activity that can be enhanced by mechanical stimulation and the application of norepinephrine (*e.g.*, Wall and Gutnick, 1974a,b; Govrin-Lippman and Devor, 1978). In experiments in which the recovery of an injured inferior alveolar nerve was impeded (Robinson, 1981; Holland and Robinson, 1987, 1990a), the animals showed no abnormalities of behavior, and the most significant finding was an extensive recovery of peripheral target innervation despite neuroma formation. More recent direct observation of the properties of myelinated afferents in the IAN shows that while neuroma formation results in increased

spontaneous activity in the nerve and mechanical sensitivity of the neuroma, these changes decline with time (Bongenhielm and Robinson, 1996). Few of the other injuries included in this review induce significant neuroma formation, and this may be an important factor in developing dysesthesias and pain. There are limitations in designing and implementing chronic pain models. The model of Bennett and Xie (1988) has been applied in the spinal system, and its use is currently being extended very effectively to the trigeminal system (Vos *et al.*, 1994; Vos and Strassman, 1995).

(VII) Conclusions

In viewing the data available from experimental approaches to trigeminal nerve injury, one may draw several conclusions with various degrees of safety. There clearly remains a considerable degree of plasticity in the system, even in the adult. After nerve trunk injury, in favorable circumstances, the reinnervation of peripheral targets is good, and there is no neuronal death though conduction velocities in the trunk may be reduced. 'Favorable circumstances' would be an injury in which there was either no loss of continuity of the connective tissue sheath (crushing) or where the cut ends of a transected nerve remain in apposition. Unfavorable circumstances would include separation of the damaged ends of a nerve trunk, loss of a segment of the trunk, an obstruction to regeneration, and greater proximity of the injury to the central nervous system. Under these conditions, some neurons die, and this may be particularly pronounced in narrow fibers. Axonal sprouting is exceptionally high and persistent, and there is limited or no reinnervation of the target organs though sprouts from other non-injured nerves may supply some collateral reinnervation. Alternate inappropriate targets may be innervated. Active repair, particularly by epineurial sutures, even if delayed for up to three months after the injury, can convert a possibly unfavorable outcome to a favorable one. Unfortunately, although the response in the periphery, in the ganglion, and in the nerve trunk itself has been examined extensively after nerve trunk damage, few data are available on changes in the brainstem. The lesions whose central consequences have been examined in detail are, in general, minor and peripheral. One would expect the changes seen after nerve trunk injury to be more substantial and persistent, particularly after nerve trunk injuries in which regeneration was difficult or discouraged. This assumption requires experimental testing.

The evidence for transsynaptic degeneration in the trigeminal system is not extensive. It would likely be more obvious after more severe lesions. While the available descriptions of brainstem degeneration are detailed and have been corroborated from several laboratories, there is only limited evidence of central regeneration.

Johnson *et al.* (1983) provided evidence that terminals that show subtle degenerative changes may recover. The reversibility of the central electrophysiological changes after minor peripheral lesions may be due to functional adaptations to the modified input, but it may also be that normal connections are restored by regenerating axons. Central studies have been restricted to minor lesions in which peripheral recovery would be good and primary afferent cell death absent. It would be of considerable interest to compare the data currently available with similar observations after nerve trunk injuries in which regeneration was prevented. The work that has thus far been published where immunocytochemical techniques were used to observe changes in the central expression of neuropeptides is fascinating but clearly incomplete, particularly in the brainstem. Descriptions of the changes in the patterns of expression of peptides and receptors to a variety of lesions, particularly those of greater severity, would considerably enhance our understanding of central plasticity. One study (Drew *et al.*, 1987) has reported the numbers and affinities of GABA (gamma amino butyric acid) receptors in the nucleus caudalis following central rhizotomy. Experimental studies of the effects of rhizotomy have been limited largely to one group, whereas accounts of its use as a clinical procedure for pain relief abound (*e.g.*, Ferguson *et al.*, 1981; Arias, 1986). Apart from this direct clinical relevance, it is important as a procedure which produces Wallerian degeneration of central processes.

In general, the nature of the lesions whose peripheral consequences have been examined differs from that of those whose central sequelae are known. Consolidation in this respect would lead to a more valid and comprehensive description of the response to nerve injuries. In the majority of experiments, the period of observation has been relatively brief, and a suspicion remains that changes or the reversal of changes may continue over a much longer period. While the functional data on the peripheral recovery are substantial if not definitive, the morphological approaches have frequently been restricted to a simple fiber analysis proximal and distal to the various injuries. This has several limitations. The number of axons distal to an injury may well represent the degree of sprouting within the recovery region of the nerve and not the number of axons that have crossed the injury site. Simple histology does not demonstrate the peptidergic character of the nerve or reveal the possible sensory/sympathetic approximation that may occur in healing nerves. The detailed ultrastructure of trigeminal neuromas is unknown.

There are enormous opportunities for the acquisition of new knowledge in this area. The clinical significance in terms of pain, sensory dysfunction, and motor handicaps is considerable. In addition, the trigeminal system offers some special advantages over the spinal

system as a model for examining the consequences of nerve injury and for the development of treatment strategies. There are well-defined end organs (teeth, vibrissae, and, by adoption, taste buds) whose development, regeneration, and reinnervation are readily observable. There is a wide range of sensory information carried by the system, but the predominance of pain in both normal and disturbed conditions is particularly significant. There are several motor functions—skeletal, secretomotor, and vasomotor—that can be segregated and examined discretely. There are examples of trophic influences on development (*e.g.*, odontogenesis) that are readily accessible to experimental observation. The scientific virtues of the trigeminal system are substantial.

In offering comment on future directions, one could be at least as expansive on what is unknown as the preceding review is on what is known. This research area is blessed with a good number of gifted and industrious investigators, and it is difficult, without being unjustly critical, dismissive and/or patronizing and/or pompous, to suggest what these people should be doing. Fortunately, the author feels no inhibitions in this regard, and what follows is a personal list, in random order, with a certain amount of internal repetition and contradiction of the directions in which experimental studies on trigeminal nerve injury are, will, or should be applying increased emphasis:

- Examination of the central consequences of more severe injuries, particularly those following impeded regeneration and most particularly those looking at the chronic pain model of Bennett and Xie (1988) applied to the trigeminal system
- Measurement of the extent of post-synaptic changes in the brainstem following injuries of different severities
- The extension of observations to levels of the central nervous system above the brainstem
- Closer examination of the consequences of procedures such as rhizotomy which are used clinically but not widely examined experimentally
- Determination of the neurotrophic factors (and their source) involved in the regenerative process
- Description of the expression of peptides, transmitters, trophins, and other neurally active molecules during injury and recovery
- A clearer demonstration of the relationship between nerve injury and the genesis of chronic pain
- A clarification of whether recovery, peripheral or central, is a process of regeneration or adaptation or both
- The development of techniques for the optimal recovery of injured nerves
- The role of inflammation, particularly when chronic, on the recovery of peripheral nerve injuries
- Definition of the conditions that lead to neuronal

death in the trigeminal ganglion and mesencephalic nucleus

- Estimation of recovery of axons in terms of the number and nature of the proximal axons that are continuous with axons distal to the injury site
- The extension of behavioral studies that demonstrate functional recovery
- Application of new neurotoxins and neural tracers for differential identification of components of the recovering trigeminal system
- Clarification of the possible role of nerve injury in the genesis of chronic pain

Acknowledgments

I would like to thank Dr. Margaret Byers, University of Washington, Dr. Norman Capra, University of Maryland, Dr. James Hu, University of Toronto, and Dr. Lesnick Westrum, University of Washington, who kindly reviewed a draft of this article and whose comments and suggestions led to a considerable improvement. My own work included in this review and carried out in collaboration with Drs. Peter Robinson, Tilly Loescher, and Keith Smith of the University of Sheffield and with Enid Pehowich of the University of Alberta was supported by the Medical Research Council of Canada and the Wellcome Trust.

REFERENCES

- Aldskogius H, Arvidsson J (1978). Nerve cell degeneration and death in the trigeminal ganglion of the adult rat following peripheral nerve transection. *J Neurocytol* 7:229-250.
- Arias MJ (1986). Percutaneous retrogasserian glycerol rhizotomy for trigeminal neuralgia. A prospective study of 100 cases. *J Neurosurg* 65:32-36.
- Arvidsson J (1986). Transganglionic degeneration in vibrissae innervating primary sensory neurons of the rat: a light and electron microscopic study. *J Comp Neurol* 249:392-403.
- Arvidsson J, Grant G (1979). Further observations on transganglionic degeneration in trigeminal primary sensory neurons. *Brain Res* 162:1-2.
- Avery JK, Strachan DS, Corpron RE, Cox CF (1971). Morphological studies of the altered pulps of the New Zealand white rabbit after resection of the inferior alveolar nerve and/or the superior cervical ganglion. *Anat Rec* 171:495-508.
- Avery JK, Cox CF, Corpron RE (1974). The effects of combined nerve resection and cavity preparation and restoration on response dentine formation in rabbit incisors. *Arch Oral Biol* 19:539-548.
- Bennett GJ, Xie YK (1988). A peripheral mononeuropathy in rat that produces disorders of pain sensation like those seen in man. *Pain* 33:87-107.
- Berger RL, Byers MR (1983). Dental nerve regeneration in rats. II. Autoradiographic studies of nerve regeneration to molar pulp and dentin. *Pain* 15:359-375.
- Berger RL, Byers MR, Calkins DF (1983). Dental nerve regeneration in rats. I. Electrophysiological studies of molar sensory deficit and recovery. *Pain* 15:345-357.
- Bigotte L, Olsson Y (1987). Degeneration of trigeminal ganglion neurons caused by retrograde axonal transport of doxorubicin. *Neurology* 37:985-992.
- Blackburn CW, Bramley PA (1989). Lingual nerve damage associated with the removal of lower third molars. *Br Dent J* 167:103-107.
- Bongenhielm U, Robinson PP (1996). Spontaneous and mechanically evoked afferent activity originating from inferior alveolar nerve neuromas in ferrets. *Pain* (in press).
- Brown GN, Kupfer SR, Darlington CG (1961). Effects of inferior alveolar nerve severance on the eruption rate of the mandibular incisor in the 10 day old Wistar albino rat. *Oral Surg* 14:1227-1255.
- Butler JM, Unger WG, Cole DF (1980). Axon reflex in ocular injury: sensory mediation of the response of the rabbit eye to laser irradiation of the iris. *Q J Exp Physiol Cogn Med Sci* 65:261-272.
- Byers MR (1990). Segregation of NGF receptor in sensory receptors, nerves and local cells of teeth and periodontium demonstrated by EM immunocytochemistry. *J Neurocytol* 19:765-775.
- Byers MR (1994). Dynamic plasticity of dental sensory nerve structure and cytochemistry. *Arch Oral Biol* 39(Suppl):13S-21S.
- Byers MR, Schatteman GC, Bothwell M (1990). Multiple functions for NGF receptor in developing, aging and injured rat teeth are suggested by epithelial, mesenchymal and neural immunoreactivity. *Development* 109:461-471.
- Cheal M, Oakley B (1977). Regeneration of fungiform taste buds: temporal and spatial characteristics. *J Comp Neurol* 172:609-626.
- Cheal M, Dickey WP, Jones LB, Oakley B (1977). Taste fiber response during reinnervation of fungiform papillae. *J Comp Neurol* 172:627-646.
- Chiego DJ Jr, Klein RM, Avery JK (1981). Tritiated thymidine autoradiographic study of the effects of inferior alveolar nerve resection on the proliferative compartments of the mouse incisor formative tissues. *Arch Oral Biol* 26:83-89.
- Chiego DJ, Fisher MA, Avery JK, Klein RM (1985). Effects of denervation on ³H-fucose incorporation by odontoblasts in the mouse incisor. *Cell Tissue Res* 230:197-203.
- Chiego DJ Jr, Klein RM, Avery JK, Gruhl IM (1986). Denervation-induced changes in cell proliferation in the rat molar after wounding. *Anat Rec* 21:348-352.

- Christensen K (1940). Sympathetic nerve fibers in the alveolar nerves and nerves of the dental pulp. *J Dent Res* 19:227-242.
- Cooper BY, Sessle BJ (1992). Anatomy, physiology and pathophysiology of trigeminal system paresthesias and dysesthesias. In: Oral and maxillofacial surgery clinics of North America. Trigeminal nerve injury: Diagnosis and management. Gregg JM, LaBanc JP, editors. Philadelphia: W.B. Saunders, pp. 297-322.
- De Man K, Bax WA (1988). The influence of the mode of treatment of zygomatic bone fractures on the healing process of the infraorbital nerve. *Br J Oral Maxillofac Surg* 26:419-425.
- Devor M, Rappaport ZH (1985). Pain and the pathophysiology of damaged nerve. In: Pain syndromes in neurology. Fields HL, editor. London: Butterworths, pp. 47-83.
- Dinger B, Fidone SJ, Stensaas LJ (1985). Regeneration of taste buds by nongustatory nerve fibres. *Exp Neurol* 89:189-203.
- Doubleday B, Robinson PP (1994). Nerve growth factor depletion reduces collateral sprouting of cutaneous mechanoreceptive and tooth-pulp axons in ferrets. *J Physiol (Lond)* 481:709-718.
- Drew JP, Westrum LE, Baskin DB, Franck JE (1987). Benzodiazepine binding increases in the superficial laminae of the trigeminal subnucleus caudalis following central rhizotomy. *Neurosci Lett* 80:39-43.
- Edwards LF, Kitchen DC (1951). Does resection of nerves supplying the mandible affect development of teeth? *J Dent Res* 17:115-124.
- El-Eishi HI, State FA (1974). The role of the nerve in formation and maintenance of taste buds. *Acta Anat* 89:599-609.
- Eppley BL, Snyders RV, Winkelmann TM, Roufa DG (1991). Efficacy of nerve growth factor in regeneration of the mandibular nerve: a preliminary report. *J Oral Maxillofac Surg* 49:61-68.
- Farbman AI (1969). Fine structure of degenerating taste buds after denervation. *J Embryol Exp Morphol* 22:55-68.
- Ferguson GG, Brett DC, Peerless SJ, Barr HW, Girvin JP (1981). Trigeminal neuralgia: a comparison of the results of percutaneous rhizotomy and microvascular compression. *Can J Neurol Sci* 8:207-214.
- Fried K, Erdelyi G (1982). Inferior alveolar nerve regeneration and incisor pulpal reinnervation following intra-mandibular neurotomy in the cat. *Brain Res* 244:259-268.
- Fried K, Risling M (1991). Nerve growth factor receptor-like immunoreactivity in primary and permanent canine tooth pulps of the cat. *Cell Tissue Res* 264:321-328.
- Fried K, Arvidsson J, Robertson B, Pfaller K (1991). Anterograde horseradish peroxidase tracing and immunohistochemistry of trigeminal ganglion tooth pulp neurons after dental nerve lesions in the rat. *Neuroscience* 43:269-278.
- Gobel S (1978a). Golgi studies of the neurons in layer I of the dorsal horn of the medulla (trigeminal nucleus caudalis). *J Comp Neurol* 180:375-393.
- Gobel S (1978b). Golgi studies of the neurons in layer II of the dorsal horn of the medulla (trigeminal nucleus caudalis). *J Comp Neurol* 180:395-413.
- Gobel S (1984). An electron microscopic analysis of the trans-synaptic effects of peripheral nerve injury subsequent to tooth pulp extirpations on neurons in laminae I and II of the medullary dorsal horn. *J Neurosci* 4:2281-2290.
- Gobel S, Binck JM (1977). Degenerative changes in primary trigeminal axons and in neurons in nucleus caudalis following tooth pulp extirpations in the cat. *Brain Res* 132:347-354.
- Govrin-Lippman R, Devor M (1978). Ongoing activity in severed nerves: source and variations with time. *Brain Res* 159:406-410.
- Gregg JM (1971). Posttraumatic pain: experimental trigeminal neuropathy. *J Oral Surg* 29:260-267.
- Hansen HJ (1980). Neuro-histological reactions following tooth extractions. *Int J Oral Surg* 9:411-426.
- Henderson TA, Rhoades RW, Bennett-Clarke CA, Osborne PA, Johnson EM, Jacquin MF (1993). NGF augmentation rescues trigeminal ganglion and principalis neurons, but not brainstem or cortical whisker patterns, after infraorbital nerve injury at birth. *J Comp Neurol* 336:243-260.
- Henry MA, Westrum LE, Johnson LR, Canfield RC (1987). Ultrastructure of degenerative changes following ricin application to feline dental pulps. *J Neurocytol* 16:601-611.
- Henry MA, Westrum LE, Bothwell M, Johnson LR (1993). Nerve growth factor receptor (p75)-immunoreactivity in the normal adult feline trigeminal system and following retrogasserian rhizotomy. *J Comp Neurol* 335:425-436.
- Holland GR (1978). Fibre numbers and sizes in the inferior alveolar nerve of the cat. *J Anat* 127:343-352.
- Holland GR (1994). A histological comparison of periapical inflammatory and neural responses to two endodontic sealers in the ferret. *Arch Oral Biol* 39:539-544.
- Holland GR, Robinson PP (1984). Evidence for the persistence of axons at the apex of the cat's lower canine tooth after section of the inferior alveolar nerve. *Anat Rec* 208:175-183.
- Holland GR, Robinson PP (1985). Reinnervation of the canine tooth pulp after section of the inferior alveolar nerve in the cat. *Brain Res* 329:300-303.
- Holland GR, Robinson PP (1987). A morphological study of the collateral reinnervation of the cat's canine tooth. *Exp Neurol* 98:489-498.

- Holland GR, Robinson PP (1990a). The number and size of axons central and peripheral to inferior alveolar nerve injuries in the cat. *J Anat* 173:129-137.
- Holland GR, Robinson PP (1990b). Cell counts in the trigeminal ganglion of the cat after inferior alveolar nerve injuries. *J Anat* 171:179-186.
- Holland GR, Matthews B, Robinson PP (1987). An electrophysiological and morphological study of the innervation and reinnervation of cat dentine. *J Physiol (Lond)* 386:31-43.
- Holland GR, Robinson PP, Smith KG, Pehowich E (1996a). A quantitative morphological study of the recovery of cat lingual nerves after transection or crushing. *J Anat* 188:289-297.
- Holland GR, Andrade D, Smith KG, Lahl S, Robinson PP, Pehowich E (1996b). A quantitative morphological comparison of cat lingual nerve repair using epineurial sutures or entubulation. *J Dent Res* 75:942-948.
- Hu JW, Sessle BJ (1989). Effects of tooth pulp deafferentation on nociceptive and nonnociceptive neurons of the feline trigeminal subnucleus caudalis (medullary dorsal horn). *J Neurophysiol* 61:1197-1206.
- Hu JW, Dostrovsky JO, Lenz YE, Ball GJ, Sessle BJ (1986). Tooth pulp deafferentation is associated with functional alterations in the properties of neurons in the trigeminal spinal tract nucleus. *J Neurophysiol* 56:1650-1668.
- Hu JW, Sharav Y, Sessle BJ (1990). Effects of one- or two-stage deafferentation of mandibular and maxillary tooth pulps on the functional properties of trigeminal brainstem neurons. *Brain Res* 516:271-279.
- Hu JW, Shohara E, Sessle BJ (1992). Patterns and plasticity of dental afferent inputs to trigeminal (V) brainstem neurons in kittens. *Proc Finn Dent Soc* 88(Suppl 1):563-569.
- Imamoto K (1972). Electron microscopic observations in the trigeminal mesencephalic nucleus following neurectomy of the third division of the trigeminal nerve. *Arch Histol Jpn* 34:361-374.
- Johansson CS, Hildebrand C, Povlsen B (1992). Anatomy and developmental chronology of the rat inferior alveolar. *Anat Rec* 234:144-152.
- Johnson LR, Westrum LE (1980). Brain stem degeneration patterns following tooth extractions: visualization of dental and periodontal afferents. *Brain Res* 194:489-493.
- Johnson LR, Westrum LE, Canfield RC (1983). Ultrastructural study of transganglionic degeneration following dental lesions. *Exp Brain Res* 52:226-234.
- Johnson LR, Westrum LE, Henry MA, Canfield RC (1985). Toxic ricin demonstrates a dual dental projection. *Brain Res* 345:379-383.
- Kato J, Wakisaka S, Tabara MJ, Sasaki Y, Kurisu K (1994). Induction of Fos protein in the rat trigeminal nucleus complex during an experimental tooth movement. *Arch Oral Biol* 39:723-726.
- Kato S, Yamamoto T, Iwasaki Y, Niizuma H, Nakamura T, Suzuki J (1988). Experimental retrograde adriamycin trigeminal sensory ganglionectomy. *J Neurosurg* 69:760-765.
- Klein BG (1991). Chronic functional consequences of adult infraorbital nerve transection for rat trigeminal subnucleus interpolaris. *Somatosens Motor Res* 8:175-191.
- Kullas CD, Henry MA, Westrum LE, Johnson LR, Bothwell M (1991). Retrogasserian rhizotomy causes expression of nerve growth factor receptor-immunoreactive protein in motoneurons within the feline trigeminal motor nucleus. *Neurosci Lett* 126:145-148.
- Kwan CL, Hu JW, Sessle BJ (1993). Effects of tooth pulp deafferentation on brainstem neurons of the rat trigeminal subnucleus oralis. *Somatosens Motor Res* 10:115-131.
- Labanc JP, Gregg JM (1992). Trigeminal nerve injuries. Basic problems, historical perspectives, early successes and remaining challenges. In: Oral and maxillofacial surgery clinics of North America: Trigeminal nerve injury: Diagnosis and management. Vol. 4. LaBanc JP, Gregg JM, editors. Philadelphia: Saunders, pp. 277-283.
- Linden RW, Millar BJ (1992). The relation between the response properties and the position of reinnervated periodontal ligament mechanoreceptors in the cat. *J Biol Buccale* 20:203-206.
- Loescher AR, Holland GR (1991). Distribution and morphological characteristics of axons in the periodontal ligament of cat canine teeth and the changes observed after reinnervation. *Anat Rec* 230:57-72.
- Loescher AR, Robinson PP (1989). Properties of reinnervated periodontal mechanoreceptors after inferior alveolar nerve injuries in cats. *J Neurophysiol* 62:979-983.
- Loescher AR, Robinson PP (1990). Characteristics of periodontal mechanoreceptors reinnervated after freezing the inferior alveolar nerve. *Brain Res* 546:257-260.
- Loescher AR, Robinson PP (1991). Properties of periodontal mechanoreceptors supplying the cat's lower canine at short and long periods after reinnervation. *J Physiol (Lond)* 444:85-97.
- Lundborg G (1988). Nerve injury and repair. London: Churchill Livingstone.
- Mantyh PW, Allen CJ, Rogers S, DeMaster E, Ghilardi JR, Mosconi T, et al. (1994). Some sensory neurons express neuropeptide Y receptors: potential paracrine inhibition of primary afferent nociceptors following peripheral nerve injury. *J Neurosci* 14:3958-3968.
- Mason AG, Holland GR (1993). The reinnervation of healing extraction sockets in the ferret. *J Dent Res* 72:1215-1221.
- Mason DA (1988). Lingual nerve damage following lower

- third molar surgery. *Int J Oral Maxillofac Surg* 17:290-294.
- Olgart L (1991). Involvement of sensory nerves in hemodynamic reactions. *Proc Finn Dent Soc* 88(Suppl 1):403-410.
- Olgart L, Edwall L, Fried K (1993). Cat dental pulp after denervation and subsequent re-innervation: changes in blood-flow regulation and distribution of neuropeptide-, GAP-43- and low-affinity neurotrophin receptor-like immunoreactivity. *Brain Res* 625:109-119.
- Qian XB, Naftel JP (1994). The effects of anti-nerve growth factor on retrograde labelling of superior cervical ganglion neurones projecting to the molar pulp in the rat. *Arch Oral Biol* 39:1041-1047.
- Raappana P, Arvidsson J (1992). The reaction of mesencephalic trigeminal neurons to peripheral nerve transection in the adult rat. *Exp Brain Res* 90:567-571.
- Renehan WE, Munger BL (1986). Degeneration and regeneration of peripheral nerve in the rat trigeminal system. I. Identification and characterization of the multiple afferent innervation of the mystacial vibrissae. *J Comp Neurol* 246:129-145.
- Renehan WE, Klein BG, Chiaia NL, Jacquin MF, Rhoades RW (1989). Physiological and anatomical consequences of infraorbital nerve transection in the trigeminal ganglion and trigeminal spinal tract of the adult rat. *J Neurosci* 9:548-547.
- Robinson PP (1980). Reinnervation of teeth following segmental osteotomy in the cat. *J Dent Res* 59:1741-1749.
- Robinson PP (1981). Reinnervation of teeth, mucous membrane and skin following section of the inferior alveolar nerve in the cat. *Brain Res* 220:241-253.
- Robinson PP (1984). Regenerating nerve fibres do not displace the collateral reinnervation of cat teeth. *Brain Res* 310:303-310.
- Robinson PP (1986). Reinnervation of teeth after segmental osteotomy in the cat. The effect of segment repositioning and bone grafting. *Int J Oral Maxillofac Surg* 15:152-159.
- Robinson PP (1989). The reinnervation of the tongue and salivary glands after lingual nerve injuries in cats. *Brain Res* 483:259-271.
- Robinson PP (1992). The effect of injury on the properties of afferent fibres in the lingual nerve. *Br J Oral Maxillofac Surg* 30:39-45.
- Robinson PP, Winkles PA (1991). The number and distribution of fungiform papillae and taste buds after lingual nerve injuries in cats. *Arch Oral Biol* 36:885-891.
- Rood JP (1992). Permanent damage to inferior alveolar and lingual nerves during the removal of impacted mandibular third molars. *Br Dent J* 172:108-110.
- St. John SJ, Markison S, Spector A (1995). Salt discriminability is related to number of regenerated taste buds after chorda tympani nerve section in rats. *Am J Physiol* 269:R141-R153.
- Salt TE, Crozier CS, Hill RG (1982). The effects of capsaicin pre-treatment on the responses of single neurones to sensory stimuli in the trigeminal nucleus caudalis of the rat: evidence against a role for substance P as the neurotransmitter serving thermal nociception. *Neuroscience* 7:1141-1148.
- Sasaki Y, Wakisaka S, Kurisu K (1994). Effects of peripheral axotomy of the inferior alveolar nerve on the levels of neuropeptide Y in rat trigeminal primary afferent neurons. *Brain Res* 664:108-114.
- Sessle BJ, Dubner R (1971). Presynaptic excitability changes of trigeminothalamic and corticothalamic afferents. *Exp Neurol* 30:239-250.
- Sharp FR, Griffith J, Gonzalez MF, Sagar SM (1989). Trigeminal nerve section induces Fos-like immunoreactivity (FLI) in brainstem and decrease (FLI) in sensory cortex. *Brain Res Mol Brain Res* 6:217-220.
- Shortland PJ, Jacquin MF, DeMarco JA, Kwan CL, Hu JW, Sessle BJ (1996). Central projections of identified trigeminal primary afferents after molar pulp deafferentation in adult rats. *Somatosens Motor Res* (in press).
- Shyu BC, Leung GM, Hu JW, Sessle BJ (1993). Tooth pulp deafferentation is not associated with changes in primary afferent depolarization of facial afferent endings in the brain stem. *Exp Neurol* 123:243-250.
- Smith DV, Akeson RA, Shipley MT (1993). NCAM expression by subsets of taste cells is dependent upon innervation. *J Comp Neurol* 336:493-506.
- Smith DV, Akeson RA, Shipley MT (1994). Expression of the neural cell adhesion molecule (NCAM) and polysialic acid during taste bud degeneration and regeneration. *J Comp Neurol* 347:187-196.
- Smith KG, Robinson PP (1995a). An experimental study on lingual nerve repair using epineurial sutures and entubulation. *Br J Oral Maxillofac Surg* 33:211-219.
- Smith KG, Robinson PP (1995b). An experimental study of three methods of lingual nerve defect repair. *J Oral Maxillofac Surg* 53:1051-1062.
- Smith KG, Robinson PP (1995c). The reinnervation of the tongue and salivary glands after two methods of lingual nerve repair in the cat. *Arch Oral Biol* 40:373-383.
- Smith KG, Robinson PP (1995d). The effect of delayed repair on the properties of regenerated afferent fibres in the chorda tympani. *Brain Res* 691:142-152.
- Smith KG, Robinson PP (1995e). An experimental study on the recovery of the lingual nerve after injury with or without repair. *Int J Oral Maxillofac Surg* 24:372-379.
- Smith KG, Robinson PP (1995f). The reinnervation of the tongue and salivary glands after lingual nerve repair by stretch, sural nerve graft or frozen muscle graft. *J Dent Res* 74:1850-1860.
- State FA, Bowden RE (1974). Innervation and cholinesterase activity of the developing taste buds in the circumvallate papilla of the mouse. *J Anat* 118:211-221.

- Stephenson JL, Byers MR (1995). GFAP immunoreactivity in trigeminal ganglion satellite cells after tooth injury in rats. *Exp Neurol* 131:11-22.
- Stover JD, Schwab CA, Matthews MA (1992). Selective deafferentation of convergent inputs to trigeminal subnucleus caudalis: effects on calcitonin gene-related peptide distribution. *Somatosens Motor Res* 9:107-130.
- Strassburg M (1967). Experimental studies on nerve-cell alterations in the trigeminal ganglion after artificial fractures of the mandible. *Trans Int Conf Oral Surg* 1967:165-170.
- Sugimoto T, Takemura M, Okubo J, Sakai A (1985). Strychnine and L-allylglycine but not bicuculline and picrotoxin induce transsynaptic degeneration following transection of the inferior alveolar nerve in adult rats. *Brain Res* 341:393-398.
- Sugimoto T, Ichikawa H, Hijiyama H, Mitani S, Nakago T (1993). c-Fos expression by dorsal horn neurons chronically deafferented by peripheral nerve section in response to spared, somatotopically inappropriate nociceptive primary input. *Brain Res* 621:161-166.
- Sunderland S (1951). A classification of peripheral nerve injuries producing loss of function. *Brain* 74:491-516.
- Sunderland S (1978). Nerves and nerve injuries. 2nd ed. Edinburgh: Churchill Livingstone.
- Takemura M, Sugimoto T, Wakisaka S, Akai M (1990). Re-innervation of rat molar tooth pulp following transection of the inferior alveolar nerve. *Neurosci Lett* 108:65-70.
- Tasker RR, Dostrovsky JO (1984). Deafferentation and central pain. In: Textbook of pain. Wall P, Melzack R, editors. London: Churchill Livingstone, pp. 154-180.
- Taylor AC, Butcher EO (1951). The regulation of eruption rate in the incisor teeth of the white rat. *J Exp Zool* 117:165-188.
- Torneck CD, Harnett B, Johnson T, Leung T (1972). The effect of surgical denervation on dentin formation in the incisor of the rat. *J Dent Res* 51:48-52.
- Unger WG, Terenghi G, Ghatei MA, Ennis KW, Butler JM, Zhang SQ, et al. (1985). Calcitonin gene-related polypeptide as a mediator of the neurogenic ocular injury response. *J Ocul Pharmacol* 30:189-199.
- Von Arx DP, Simpson MT (1989). The effect of dexamethasone on neuropraxia following third molar surgery. *Br J Oral Maxillofac Surg* 27:477-480.
- Vos BP, Strassman AM (1995). Fos expression in the medullary dorsal horn of the rat after chronic constriction injury to the infraorbital nerve. *J Comp Neurol* 357:362-375.
- Vos BP, Strassman AM, Maciewicz RJ (1994). Behavioral evidence of trigeminal neuropathic pain following chronic constriction injury to the rat's infraorbital nerve. *J Neurosci* 14:2708-2723.
- Waite PM (1984). Rearrangement of neuronal responses in the trigeminal system of the rat following peripheral nerve section. *J Physiol (Lond)* 352:425-435.
- Wakisaka S, Sasaki Y, Ichikawa H, Matsuo S (1992). Increase in c-fos-like immunoreactivity in the trigeminal nucleus complex after dental treatment. *Proc Finn Dent Soc* 88(Suppl 1):551-555.
- Wakisaka S, Takikita S, Sasaki Y, Kato J, Tabata MJ, Kurisu K (1993). Cell size-specific appearance of neuropeptide Y in the trigeminal ganglion following peripheral axotomy of different branches of the mandibular nerve of the rat. *Brain Res* 620:347-350.
- Wakisaka S, Sasaki Y, Kurisu K (1995). Temporal analysis of neuropeptide Y expression in the rat trigeminal ganglion following peripheral axotomy of the inferior alveolar nerve. *Neurosci Lett* 188:49-52.
- Wall PD, Gutnick M (1974a). Properties of afferent nerve impulses originating from a neuroma. *Nature* 248:740-743.
- Wall PD, Gutnick M (1974b). Ongoing activity in peripheral nerves: The physiology and pharmacology of impulses originating from a neuroma. *Exp Neurol* 43:580-593.
- Walter JM, Gregg JM (1979). Analysis of postsurgical neurologic alteration in the trigeminal nerve. *J Oral Surg* 37:410-414.
- Westrum LE (1973). Early forms of terminal degeneration in the spinal trigeminal nucleus. *J Neurocytol* 2:189-215.
- Westrum LE, Black RG (1968). Changes in the synapses of the spinal trigeminal nucleus after ipsilateral rhizotomy. *Brain Res* 11:706-709.
- Westrum LE, Canfield RC (1977a). Electron microscopy of degenerating axons and terminals in spinal trigeminal nucleus after tooth pulp extirpations. *Am J Anat* 149:591-596.
- Westrum LE, Canfield RC (1977b). Light and electron microscopy of degeneration in the brain stem spinal trigeminal nucleus following tooth pulp removal in adult cats. In: Pain in the trigeminal region. Anderson DJ, Matthews B, editors. Amsterdam: Elsevier, pp. 171-179.
- Westrum LE, Canfield RC (1979). Normal loss of milk teeth causes degeneration in brain stem. *Exp Neurol* 65:69-77.
- Westrum LE, Henry MA (1991). Contralateral degeneration in the cat spinal trigeminal nucleus following unilateral retrogasserian trigeminal rhizotomy. *Neurosci Lett* 121:143-146.
- Westrum LE, Henry MA (1993). Unilateral retrogasserian rhizotomy causes contralateral degeneration in spinal trigeminal nuclei of cats: an ultrastructural study. *Exp Brain Res* 93:28-36.
- Westrum LE, Canfield RC, Black RG (1976). Axonal degeneration patterns in the cat brainstem spinal trigeminal nucleus after tooth pulp removal. In:

- Advances in pain research and therapy. Vol. 1. Bonica JJ, Albe-Fessard D, editors. New York: Raven Press, pp. 161-164.
- Westrum LE, Johnson LR, Canfield RC (1984). Ultrastructure of transganglionic degeneration in brain stem trigeminal nuclei during normal primary tooth exfoliation and permanent tooth eruption in the cat. *J Comp Neurol* 230:198-206.
- Whitehead MC, McGlathery ST, Manion BG (1995). Transganglionic degeneration in the gustatory system consequent to chorda tympani damage. *Exp Neurol* 132:239-250.
- Wilson FR, Westrum LE, Broderson SH (1988). Ultrastructural changes in acetylcholinesterase activity in the deafferented spinal trigeminal nucleus. *Synapse* 2:341-352.
- Yoshida AT, Nagamine T, Kobayashin T, Michimi N, Nakajima T, Sasakura H, *et al.* (1989). Impairment of the inferior alveolar nerve after sagittal split osteotomy. *J Craniomaxillofac Surg* 17:271-277.
- Zalewski AA (1981). Regeneration of taste buds after reinnervation of a denervated tongue papilla by a normally nongustatory nerve. *J Comp Neurol* 200:309-314.
- Zuniga JR, O'Connor B (1987). Primary and secondary microneuroanastomotic repair of the mental nerve in the rat. *Int J Oral Maxillofac Surg* 16:465-472.
- Zuniga JR, Pate JD, Hegtvedt AK (1990). Regenerative organization of the trigeminal ganglion following mental nerve section and repair in the adult rat. *J Comp Neurol* 295:548-558.