

## ORIGINAL COMMUNICATION

---

# Variability of the Lateral Femoral Cutaneous Nerve: An Anatomic Basis for Planning Safe Surgical Approaches

A. MAJKRZAK,<sup>1</sup> J. JOHNSTON,<sup>1</sup> D. KACEY,<sup>2,3</sup> AND J. ZELLER<sup>1,4\*</sup>

<sup>1</sup>Department of Medical Education, Division of Anatomical Sciences, University of Michigan Medical School, Ann Arbor, Michigan

<sup>2</sup>Clinical Assistant Professor in Surgery, University of Illinois, Chicago, Illinois

<sup>3</sup>Site Program Director at Mercy Hospital and Medical Center for the Metropolitan Group Hospitals Surgical Program, Chicago, Illinois

<sup>4</sup>South Michigan Bone and Joint, PC, Battle Creek, Michigan

---

Current surgical assumptions identify the lateral femoral cutaneous nerve (LFCN) running just under the inguinal ligament two fingerbreadths medial to the anterior superior iliac spine (ASIS). On the basis of the increasing incidence of Meralgia Paresthetica associated with various surgical procedures, it is clear that surgeons are relying on an inadequate description of the nerve's course. This study provides a better understanding of the variability of the LFCN with regards to its relationship to the ASIS and the depth at which it passes deep to the inguinal ligament. A total of 35 bodies were examined yielding 65 sets of data. Dissections were performed on 26 formalin fixed cadavers and 9 fresh morgue specimens. Measurements and calculations were made with regard to the distance from the LFCN to the ASIS along the inguinal ligament, the depth of the LFCN as it crossed the inguinal ligament, and the length of the inguinal ligament. The LFCN was observed to cross the inguinal ligament  $1.4 \pm 0.4$  cm medial to the ASIS with a standard deviation of 1.5 cm. The LFCN traversed the inguinal ligament  $1.0 \pm 0.1$  cm deep to the ligament with a standard deviation of 0.6 cm. The LFCN runs approximately one fingerbreadth medial to the ASIS. The nerve may be found far more medial or lateral than expected with several distinct branching patterns. In addition, the LFCN crosses deeper to the inguinal ligament than previously described in the literature, with a high variability of depth between specimens. Clin. Anat. 23:304–311, 2010. © 2010 Wiley-Liss, Inc.

**Key words:** laparoscopy; inguinal ligament; anterior superior iliac spine; pubic tubercle

---

## INTRODUCTION

Compression or effacement of the lateral femoral cutaneous nerve (LFCN) results in a condition known as Meralgia Paresthetica (MP), causing paresthesia, tingling, and/or burning along the anterolateral aspect of the thigh. Severity of the symptoms can range from mildly uncomfortable to painfully disabling (Harney, 2007). The condition was originally described by Bernhardt in 1878 and by Hager in 1885 and was eventually named by Roth in 1895.

Early observations often related the condition to severe toxic disorders, such as lead poisoning,

\*Correspondence to: Dr. John Zeller, Department of Anatomical Sciences, University of Michigan Medical School, 3767 Med Sci II, Ann Arbor, MI 48109-5608, USA. E-mail: jzeller@umich.edu

Received 24 August 2009; Revised 17 December 2009; Accepted 22 December 2009

Published online 18 February 2010 in Wiley InterScience (www.interscience.wiley.com). DOI 10.1002/ca.20943

chronic alcoholism (Grossman, 2001), and diabetes (O'Brian, 1979). It has since been demonstrated that this pathologic condition can result from local mechanical factors. Historically, the most common etiological factor causing direct impingement of the nerve has been related to the tethering of a belt in an obese individual (Boyce, 1984). As a consequence of its varied presentation, the LFCN may be difficult to identify and protect during surgical dissection. Iatrogenic injury to the LFCN was traditionally observed in the context of spinal surgery, secondary to devices such as the Relton-Hall frame exerting significant pathologic pressure upon the pelvis (Mirovsky, 2000; Yang, 2005; Cho, 2008). Most relevant to this discussion of the nerve's anatomic variability, is the increase in incidence and severity of MP since the advent of laparoscopic procedures.

Since the 1970s, MP has been seen as a significant complication of laparoscopic cholecystectomy (Yamout, 1994), appendectomy (Polidori, 2003), hysterectomy (Nahabedian, 1995), and herniorrhaphy due to the standard placement of trocars in the inguinal region. Additionally, placement of staples in close proximity to the inguinal ligament (IL) during abdominal hernia repair (Eubanks, 2003) has resulted in compression of the LFCN and subsequent symptomatology associated with MP. Specifically, since the advent of laparoscopic hernia repair it has been reported that the incidence of iatrogenic MP has increased fivefold from 1 to 5% over open surgical procedures (Stark, 1999).

The traditional surgical assumption identifies the LFCN running under the inguinal ligament two fingerbreadths (3.5 cm) (Milne, 2005) medial to the anterior superior iliac spine (ASIS) (Miller, 2004). On the basis of the increasing incidence of MP from laparoscopic procedures it is reasonable to assume, based on previous anatomical studies, that surgeons may have an inaccurate description of the nerve's course. This study will provide a better understanding of the variability of the LFCN as it traverses the inguinal ligament, specifically with regards to its relationship to the ASIS and the depth at which it passes deep to the ligament.

## MATERIALS AND METHODS

The trajectory of the LFCN was studied at the University of Michigan Medical School (UMMS). Cadaveric specimens were obtained from the UMMS Anatomical Donations Program, with the bodies either formalin embalmed or fresh morgue specimens. The number of samples for this study was initially determined by endeavoring to dissect comparable or higher numbers of cadavers as compared with previous research done on the LFCN. The quantity and quality of cadaveric specimens made available to the UMMS during the research period, however, determined the final number of dissections. Over an eight month period, a total of 35 bodies were examined for dissection (including 26 formalin fixed cadavers and nine fresh morgue specimens), generating 65 sets of data.

Dissections were performed by removing the anterior abdominal wall from the costal margin to 3 cm

superior to the inguinal ligament and extending the incision laterally to the anterior axillary line. The abdominal viscera were retracted and careful blunt dissection technique was used to identify and expose the course of the LFCN on the posterior abdominal wall and pelvis. The skin was then removed from the proximal thigh and the LFCN was subsequently followed from the pelvis through the inguinal ligament to its area of distribution onto the anterolateral thigh. After exposing the entire course of the LFCN, measurements were taken to describe the nerve's relationship to the ASIS and inguinal ligament (Fig. 1).

The following data were collected for each successful dissection:

1. Demographic data consisting of age, sex, height, weight, and ethnicity.
2. The distance from the ASIS to the pubic tubercle: i.e. the length of the inguinal ligament.
3. The distance from the LFCN to the ASIS as it entered the inguinal ligament.
4. The depth of the LFCN as it entered the inguinal ligament.

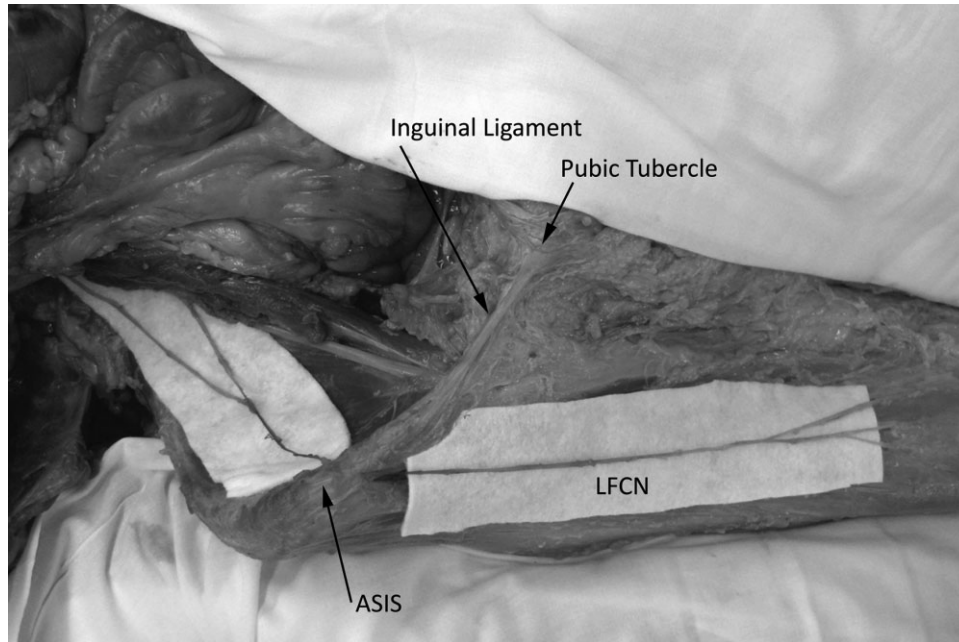
For collection of the data, the ASIS was defined as the most prominent projection of the iliac bone at the lateral end of the inguinal ligament, while the pubic tubercle was defined as the most prominent bony projection at the medial end of the IL. The inguinal ligament was measured as the distance between the middle of these two prominences. When measuring the distance of the nerve to the ASIS, measurements were made from the midline of the nerve to the middle of the bony prominence. When measuring the depth of the nerve, measurements were made from the top of the inguinal ligament to the top of the nerve, i.e. the most anterior surfaces of both. To ensure uniformity among data sets, all dissections and measurements were performed by the same two individuals. The measurements were taken independently by the two researchers, and were found to be statistically equivalent.

Statistical analysis of the data was performed using R version 2.7.1. Regression analysis of the data was performed which compared age, sex, height, weight, depth of the LFCN, and the distance between the ASIS and LFCN. Statistical significance was defined at  $P < 0.05$ . Microsoft Excel 2007 was used for graphing and data presentation.

## RESULTS

A total of 35 bodies were examined for dissection generating 65 sets of data (Table 1). All donated cadavers were Caucasian and there was a near equal number of male and female specimens (20 M, 15 F). Additionally there was near parity of left and right sided dissections (33 L, 32 R). Finally, the formalin fixed and fresh morgue specimen data sets were found to be statistically equivalent (defined as  $P < 0.05$ ) and these two data sets were combined for final analysis.

The mean distance between the LFCN and the ASIS along the inguinal ligament was  $1.4 \pm 0.4$  cm



**Fig. 1.** Origination and distribution of the LFCN. Anterior view of the right inguinal region and thigh showing the LFCN's origination in the lumbar plexus and distribution in the anterolateral thigh (body number 33230).

(Table 2). This data was plotted over an anterior view of the lower right abdominal quadrant to show relations to anatomical structures (Fig. 2). The distribution was skewed slightly lateral with values ranging from 2.3 cm lateral to 6.2 cm medial to the ASIS.

The mean depth of the LFCN below the inguinal ligament was  $1.0 \pm 0.1$  cm (Table 2). The distribution of the depth of the LFCN was skewed anteriorly with values ranging from 0.1 to 3.2 cm deep to the inguinal ligament (Fig. 3).

The LFCN's depth below the inguinal ligament and distance from the ASIS were combined and plotted against an oblique cross-sectional view of the inguinal ligament (Fig. 4). Circles representing first, second, third, and fourth quartiles of the data were plotted centered around the mean course of the LFCN. The mean course of the nerve was marked with an X.

Four distinct branching patterns of the LFCN within the abdomen were noted (Fig. 5). The traditional LFCN had one distinct vertebral origin and crossed the inguinal ligament as a single process (86% of dissections). The first variant had two distinct branches from the lumbar plexus that joined together before traversing the inguinal ligament (8% of dissections). The second variant had one distinct vertebral origin, which split into two branches before traversing the inguinal ligament (3% of dissections). The third variant had two distinct branches from the lumbar plexus that did not join before traversing the inguinal ligament, but nonetheless innervated the anterolateral thigh (3% of dissections).

Significant side to side variance of the LFCN was found in a minority of specimens. The distance between the ASIS and the LFCN along the inguinal

ligament varied 3 cm or greater between left and right sides of the same body in 17% of dissections. Additionally, the depth of the LFCN below the inguinal ligament varied 1 cm or greater between left and right sides of the same body in 7% of dissections.

Ordinary least squares (OLS) statistical analysis was used to compare interactions between age, sex, height, weight, and inguinal ligament length on (1) the distance between the LFCN and the ASIS and (2) the depth of the LFCN below the inguinal ligament. Statistical significance was defined at  $P < 0.05$ . No statistically significant relationship was found between any of the measured biometric variables.

## DISCUSSION

In Hollingshead's 1956 edition of *Anatomy for Surgeons* he states "The LFCN appears at the lateral border of the psoas muscle at or below the level of the iliac crest and runs across the posterior surface of the iliacus muscle to pass beneath the inguinal ligament a little below and medial to the anterior superior iliac spine." (Hollingshead, 1956). For approximately 30 years, this rather static disposition of the LFCN has been perpetuated in the surgical literature and extensively referenced in surgical training. Accordingly, the variable course of the LFCN went largely unnoticed by the abdominal surgeon until the advent of the laparoscopic extraperitoneal inguinal hernia repair. Although designed to be less painful, this new approach resulted in a marked increase in injuries to the LFCN. This was the result of several factors, including difficulty identifying the nerve, the nerve's variable course, excessive dissection, and

**TABLE 1. Biometric Data**

ID Number	Sex	Age (years)	Height (cm)	Weight (kg)	Body side	IL length <sup>a</sup> (cm)	LFCN distance <sup>b</sup> (cm)	LFCN depth <sup>c</sup> (cm)
32907	M	91	188	70	L	12.9	0.6	1.0
					R	13.4	1.1	0.1
32837	F	89	157	54	L	10.8	0.1	1.2
					R	11.5	1.1	1.3
32903	F	98	155	-	L	11.4	4.6	0.7
					R	10.7	2.0	0.4
32862	F	87	164	59	L	11.2	0.5	1.1
					R	11.9	1.3	0.6
32870	M	76	188	71	L	11.1	3.0	1.0
					R	10.3	2.1	1.2
32851	F	89	150	52	L	12.8	0.2	0.5
					R	12.5	1.0	0.5
32840	M	45	180	91	L	-	-	-
					R	11.9	0.2	1.9
32896	F	85	160	45	L	14.6	0.0	0.7
					R	-	-	-
32863	F	66	168	54	L	12.4	2.7	1.3
					R	12.2	2.1	2.4
32838	M	82	183	91	L	12.0	2.1	1.3
					R	13.5	2.4	1.2
32865	F	86	163	42	L	12.6	0.6	0.5
					R	12.6	0.5	0.4
32854	M	63	168	54	L	-	-	-
					R	12.5	0.3	1.3
32798	F	96	165	61	L-Med <sup>d</sup>	12.0	2.9	0.5
					L-Lat <sup>e</sup>	12.0 <sup>f</sup>	2.1	0.6
					R	10.7	0.2	0.9
32902	M	77	170	79	L	12.7	0.2	0.4
					R	12.2	0.2	1.1
32827	F	85	165	59	L-Med <sup>d</sup>	13.0	0.7	1.5
					L-Lat <sup>e</sup>	13.0 <sup>f</sup>	0.1	1.3
					R	-	-	-
32908	M	85	173	69	L	14.1	-0.2	1.1
					R	15.0	-1.8	1.9
32807	M	88	175	73	L	12.1	0.3	1.5
					R	12.2	0.5	0.8
32911	M	54	183	79	L	9.3	1.9	0.6
					R	11.9	0.9	1.3
32826	F	87	175	70	L	13.5	1.5	0.4
					R	13.0	1.9	0.3
32861	M	64	170	69	L-med <sup>d</sup>	13.4	3.4	0.8
					L-Lat <sup>e</sup>	13.4 <sup>f</sup>	1.4	1.3
					R	12.6	0.2	3.2
32843	F	85	168	64	L	11.2	0.3	0.7
					R	13.2	1.1	0.3
32853	M	59	178	68	L	10.7	2.3	0.4
					R-Med <sup>g</sup>	12.5	0.4	0.9
					R-Lat <sup>h</sup>	12.5 <sup>f</sup>	0.0	1.7
32849	F	92	157	50	L	11.6	1.5	1.3
					R	12.1	-2.3	2.8
32895	M	87	-	-	L	13.8	1.0	1.0
					R	-	-	-
32897	F	60	173	64	L	10.6	0.3	0.8
					R	10.1	1.5	0.3
32915	F	97	152	41	L	17.2	3.8	1.8
					R	10.1	2.9	-
32958	M	83	175	64	L	13.6	6.2	1.7
					R	10.6	0.5	1.1
32962	M	80	173	61	L	12.4	3.2	1.7
					R	11.1	3.2	1.8
32950	M	75	165	73	L	13.3	1.3	0.8
					R	12.9	2.7	0.8
33195	M	63	170	70	L	12.1	-0.4	0.7
					R	12.8	0.3	0.6
33218	M	53	185	59	L	13.2	0.4	0.2
					R	13.7	0.2	0.1
33222	M	78	160	73	L	13.5	1.7	1.1
					R	13.5	5.7	1.3
33220	F	56	-	-	L	12.0	1.8	1.2
					R	12.1	5.2	0.8
33219	M	87	178	59	L	13.4	2.1	0.7
					R	14.0	1.5	1.0
33230	M	78	178	41	L	14.0	1.8	0.4
					R	13.1	0.5	0.8

Dashes indicate unobtainable data.

<sup>a</sup>Length of inguinal ligament.

<sup>b</sup>LFCN distance from ASIS.

<sup>c</sup>LFCN depth below Inguinal Ligament.

<sup>d</sup>Left medial branch of LFCN within abdomen (Refer to Fig. 5).

<sup>e</sup>Left lateral branch of LFCN within abdomen (Refer to Fig. 5).

<sup>f</sup>Inguinal ligament lengths for branched LFCNs are duplicated for clarity but were not included in calculations.

<sup>g</sup>Right medial branch of LFCN within abdomen (Refer to Fig. 5).

<sup>h</sup>Right lateral branch of LFCN within abdomen (Refer to Fig. 5).

**TABLE 2. Summary of Biometric Data**

	Age (years)	Height (cm)	Weight (kg)	IL Length <sup>a</sup> (cm)	LFCN distance <sup>b</sup> (cm)	LFCN depth <sup>c</sup> (cm)
SD <sup>d</sup>	14.0	10.1	12.7	1.3	1.5	0.6
Mean	78±5	170 ± 3	63 ± 4	12.4 ± 0.3	1.4 ± 0.4	1.0 ± 0.1

<sup>a</sup>Length of inguinal ligament.

<sup>b</sup>LFCN distance from ASIS.

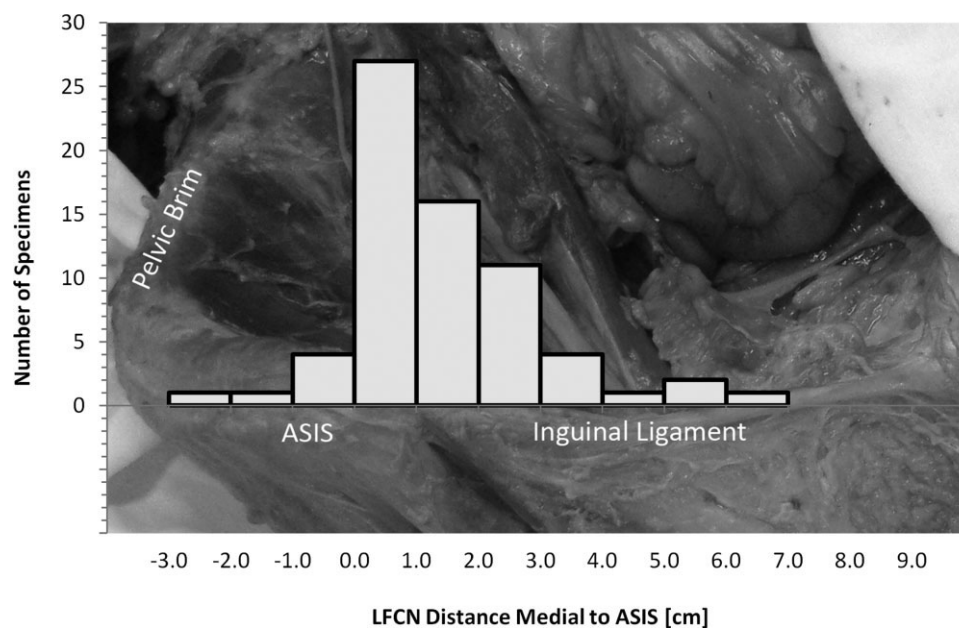
<sup>c</sup>LFCN depth below inguinal ligament.

<sup>d</sup>Standard deviations calculated to 95% confidence intervals.

nerve entrapment secondary to tacking mesh below the iliopubic tract (Scott-Conner, 2002; Felix, 2006). Accordingly, surgeons meticulously and emphatically described the extraperitoneal "Trapezoid of Disaster" (Seid, 1994) and the "Triangle of Doom" (Spaw, 1991). In an effort to deal with such surgical complications, subsequent work has insightfully documented that the anterolateral thigh may be innervated by varying branches of the lumbar plexus. Branches of the ilioinguinal, anterior femoral cutaneous, and the genitofemoral nerves have all been described as contributing to the distribution of the LFCN (Bergman, 1988). In addition, the LFCN has been shown to exit the pelvis by directly piercing the inguinal ligament or by running deep to that structure (Aszmann, 1997). Finally, various papers have demonstrated that the LFCN may run many centimeters medial or lateral to the ASIS (Williams, 1991; Dibenedetto, 1996; Rosen, 1997; Surucu, 1997; Dias Filho, 2003; Grothaus, 2005; Ropars, 2009). Since the 1970s, Meralgia Paresthetica (MP) has been seen as a significant complication of vari-

ous laparoscopic surgeries. Specifically since the advent of laparoscopic hernia repair, it has been reported that the incidence of iatrogenic MP has increased five-fold over open surgical procedures (Stark, 1999). Additionally, it was recently reported that the LFCN may be unidentifiable in up to 8.8% of MP cases requiring surgical LFCN entrapment release (Carai, 2009). These facts have been the impetus which prompted our interest and directed our research efforts.

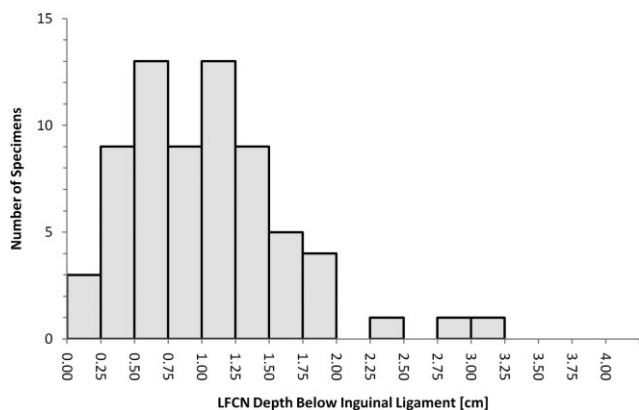
After careful dissection, it was found that the LFCN crossed the inguinal ligament  $1.4 \pm 0.4$  cm medial to the ASIS with a standard deviation of 1.5 cm. Additionally, the LFCN crossed the inguinal ligament  $1.0 \pm 0.1$  cm deep to the ligament with a standard deviation of 0.6 cm. No statistical correlation was found between the course of the LFCN and either age, gender, height, weight, or body side. This is consistent with previous work on the course of the LFCN (Urbanowicz, 1977). Four distinct anatomical variations of the LFCN were noted within the abdomen. Previous research noted that the LFCN ran, on



**Fig. 2.** Frequency of distance between LFCN and ASIS along the inguinal ligament. A histogram of the LFCN distance from the ASIS along the inguinal ligament is overlaid on anterior view of the right inguinal region to show relations to anatomy. The ASIS is

located at (0, 0). Bins are defined in 1 cm increments and are inclusive at the higher number (e.g. the tallest bar indicates that 27 LFCN specimens traversed the inguinal ligament between 0.001 and 1.000 cm medial to the ASIS).



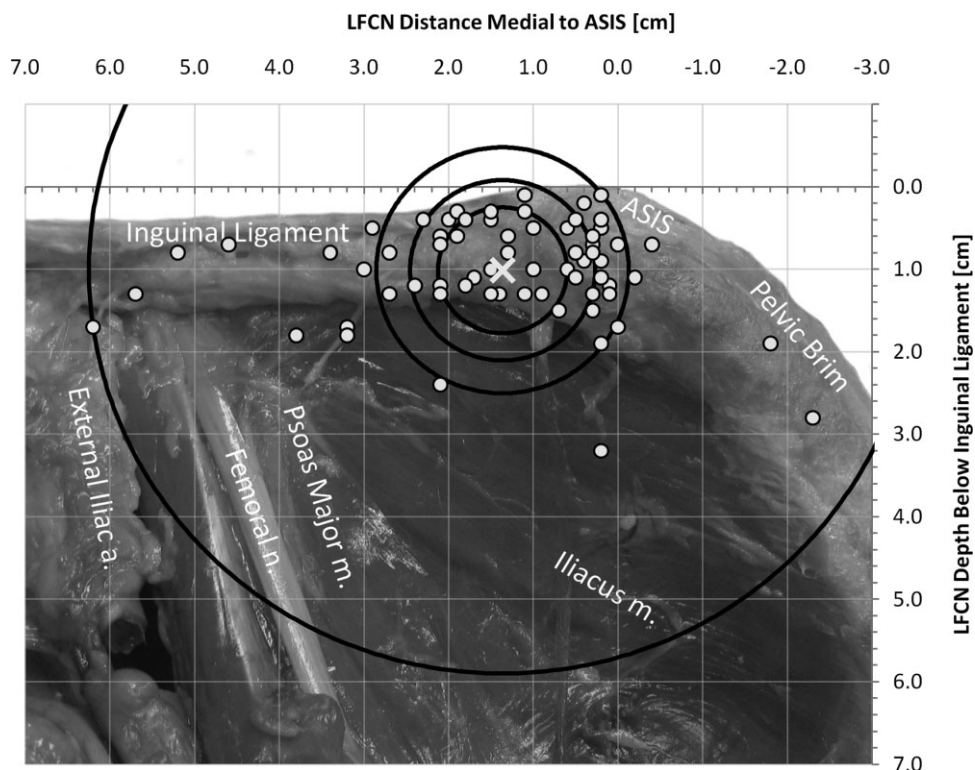


**Fig. 3.** LFCN depth below the inguinal ligament. The number of specimens versus LFCN depth below the inguinal ligament is represented in a histogram. Bins are defined in 0.25 cm increments and are inclusive at the higher number (e.g., the last bar indicates that 1 LFCN specimen exited the pelvis between 3.001 and 3.250 cm deep to the inguinal ligament).

average, 0.7 cm (Dias Filho, 2003) to 3.6 cm (Grotzhaus, 2005) medial to the ASIS (Rosen, 1997; Surucu, 1997; Ropars, 2009). Our observations coincide

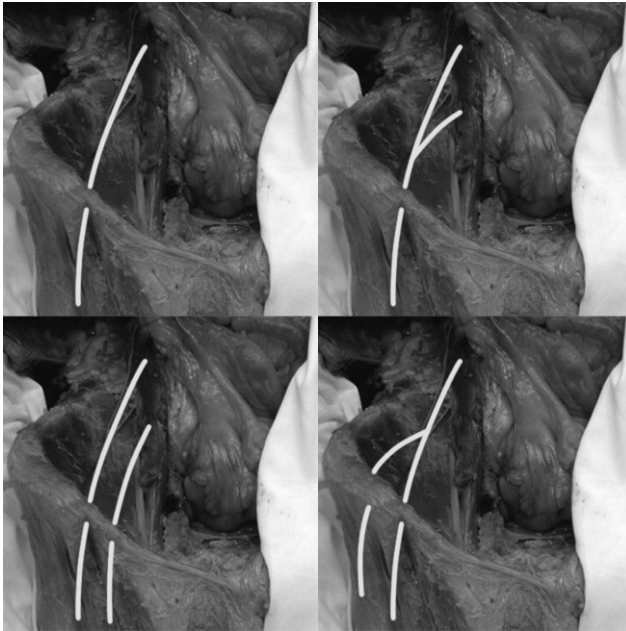
with this data range but redefine, clarify, and expand the previous work done on this topic. While our study included a wide range of donor ages (45–98 years), heights (150–188 cm), and weights (41–91 kg), all dissections were performed on Caucasians. Although it may have been preferable to have included a mix of ethnicities, the research was essentially limited by the cadavers made available to the UMMS Anatomical Donations Program. Furthermore, since no correlation was found between the course of the LFCN and age, sex, height, or weight, it is conceivable that ethnicity would have had little impact on the results. An additional limitation of our study may have been the advanced age of our specimens (range, 45–98 years; average age of 78 years). Variation in a pediatric or adolescent subgroup may be a topic for further research.

While prior data provided a simple description of the LFCN, it did not fully articulate the nerve's unique variability. The presented data adds to our anatomical understanding of this structure and can provide surgeons with a more complete description of the nerve's course and placement. Despite the previous attention to the LFCN, the description of the nerve's variable course has not been well appreciated and injury to the nerve has not been limited to only laparoscopic hernia repair. The LFCN may become involved in any pathologic process along the



**Fig. 4.** LFCN distribution at the inguinal ligament. Superior oblique view of the right hemipelvis. The ASIS is located at (0, 0). Distances medial to the ASIS are positive and distances lateral are negative. The inguinal ligament runs horizontally from (0, 0) to (7, 0). An X

marks the mean location of the LFCN as it crosses under the inguinal ligament at (1.4, 1.0). Circles representing first, second, third, and fourth quartiles of the data are centered about the mean course of the LFCN.



**Fig. 5.** Varied branching pattern of the LFCN. Four variants of the LFCN are presented on anterior views of the right inguinal region from the nerve's origination in the abdomen to its distribution in the thigh. Clockwise from top left; (1) One vertebral origin with one distributing branch, (2) Two vertebral origins with one distributing branch, (3) One vertebral origin with two distributing branches, (4) Two vertebral origins with two distributing branches.

nerve's course such as abscesses, hematomas, and sarcomas. On the other hand, the LFCN may simply be an innocent bystander endangered as a result of necessary surgical exposures in such cases as vascular exposures in and around the inguinal ligament or radical ilioinguinal lymph node dissections. In our dissection of 65 cadaveric specimens, we sought to precisely identify the variability of the LFCN to the ASIS and the inguinal ligament. Briefly stated, surgeons should be aware that the LFCN will most commonly be found between 0.0 and 3.0 cm medial to the ASIS and within 1.5 cm deep to the superior border of the inguinal ligament. Rather than to attach a threatening moniker to this "anatomical danger zone", surgeons should plan incisions, dissections, and retroperitoneal excursions accordingly. In an operative field distorted and/or obscured by a retroperitoneal abscess, hematoma, or malignancy, reliable anatomical landmarks are critical. This added anatomic detail regarding the relationship of the LFCN to the ASIS and the inguinal ligament should prove useful in the successful completion of the various aforementioned laparoscopic procedures but also in draining pelvic retroperitoneal abscesses or hematomas while avoiding injury to the LFCN, as well as in large pelvic sarcoma resections in which the LFCN may need to be sacrificed in an attempt to achieve a curative result. Furthermore, it is not only the surgeon, but the anesthesiologist specializing in pain

management that will most likely benefit from this added anatomic detail (Candido, 2009; Dalman-Carola, 2009; Philip, 2009), whose recent efforts have centered on treatment of Meralgia Paresthetica with pulsed radiofrequency of the lateral femoral cutaneous nerve.

## REFERENCES

- Aszmann OC, Dellon ES, Dellon AL. 1997. Anatomical course of the lateral femoral cutaneous nerve and its susceptibility to compression and injury. *Plast Reconstr Surg* 100:600-604.
- Bergman RA, Thompson SA, Afifi AK, Saadeh FA. 1988. *Compendium of Human Anatomic Variation*. Baltimore-Munich: Urban & Schwarzenberg.
- Bernhardt M. 1878. Neuropathologische Beobachtungen. I. periphere Lahmungen. *D Arch Klin Med* 22:362-393.
- Boyce JR. 1984. Meralgia paresthetica and tight trousers. *JAMA* 251:1553.
- Candido KD. 2009. In response to treatment of meralgia paresthetica with pulsed radiofrequency of the lateral femoral cutaneous nerve. *Pain Physician* 12:1026-1027.
- Carai A, Fenu G, Sechi E, Crotti FM, Montella A. 2009. Anatomical variability of the lateral femoral cutaneous nerve: Findings from a surgical series. *Clin Anat* 22:365-370.
- Cho KT, Lee HJ. 2008. Prone position-related meralgia paresthetica after lumbar spinal surgery: A case report and review of the literature. *J Korean Neurosurg Soc* 44:392-395.
- Dalman-Carola J. 2009. Treatment of meralgia paresthetica with pulsed radiofrequency of the lateral femoral cutaneous nerve. *Pain Physician* 12:1025-1026.
- Dias Filho LC, Valença MM, Guimarães Filho FA, Medeiros RC, Silva RA, Morais MG, Valente FP, França SM. 2003. Lateral femoral cutaneous neuralgia: An anatomical insight. *Clin Anat* 16:309-316.
- Dibenedetto LM, Lei Q, Gilroy AM, Hermey DC, Marks SC Jr, Page DW. 1996. Variations in the inferior pelvic pathway of the lateral femoral cutaneous nerve: Implications for laparoscopic hernia repair. *Clin Anat* 9:232-236.
- Eubanks S, Newman L III, Goehring L, Lucas GW, Adams CP, Mason E, Duncan T. 1993. Meralgia paresthetica: A complication of laparoscopic herniorrhaphy. *Surg Laparosc Endosc* 3:381-385.
- Felix EL. 2006. *Laparoscopic Inguinal Hernia Repair. Mastery of Endoscopic and Laparoscopic Surgery*. 2nd Ed. Philadelphia: Lippincott Williams and Wilkins. p 501-512.
- Grossman MG, Ducey SA, Nadler SS, Levy AS. 2001. Meralgia paresthetica: Diagnosis and treatment. *J Am Acad Orthop Surg* 9:336-344.
- Grothaus MC, Holt M, Mekhail AO, Ebraheim NA, Yeasting RA. 2005. Lateral femoral cutaneous nerve: An anatomic study. *Clin Orthop Relat Res* 437:164-168.
- Hager W. 1885. Neuralgia femoris. Resection des Nerv. Cutan. Femoris anterior externus. Heilung. *Deutsch Med Wochenschr* 11:218-219.
- Harney D, Patijn J. 2007. Meralgia paraesthetica: Diagnosis and management strategies. *Pain Med* 8:669-677.
- Hollinshead WH. 1956. *Anatomy for Surgeons*. Vol 2. London: Cassell. p638.
- Miller RD. 2004. *Miller's Anesthesia*. Orlando: Elsevier.
- Milne AD, Vakharia N. 2005. Inaccuracies of fingerbreadth measurements for airway assessment. *Can J Anaesth* 52(Suppl 1):A126.
- Mirovsky Y, Neuwirth M. 2000. Injuries to the lateral femoral cutaneous nerve during spine surgery. *Spine* 25:1266-1269.
- Nahabedian MY, Dellon AL. 1995. Meralgia paresthetica: Etiology, diagnosis, and outcome of surgical decompression. *Ann Plast Surg* 35:590-594.
- O'Brian JT, Massey EW. 1979. Mononeuropathy in diabetes mellitus: A phenomenon easily overlooked. *Postgrad Med* 65:128-135.
- Philip CN, Candido KD, Joseph NJ, Crystal GJ. 2009. Successful treatment of meralgia paresthetica with pulsed radiofrequency

- of the lateral femoral cutaneous nerve. *Pain Physician* 12:881–885.
- Polidori L, Magarelli M, Tramutoli R. 2003. Meralgia paresthetica as a complication of laparoscopic appendectomy. *Surg Endosc* 17:832.
- Ropars M, Morandi X, Hutten D, Thomazeau H, Berton E, Darnault P. 2009. Anatomical study of the lateral femoral cutaneous nerve with special reference to minimally invasive anterior approach for total hip replacement. *Surg Radiol Anat* 31:199–204.
- Rosen A, Halevy A. 1997. Anatomical basis for nerve injury during laparoscopic hernia repair. *Surg Laparosc Endosc* 7:469–471.
- Roth V. 1895. Meralgia Paresthetica. *Med Obozr* 43:678.
- Scott-Conner CEH. 2002. Chassin's Operative Strategy in General Surgery. An Expositive Atlas. 3rd Ed. New York: Springer-Verlag. p 777.
- Seid AS, Amos E. 1994. Entrapment neuropathy in laparoscopic herniorrhaphy. *Surg Endosc* 8:1050–1053.
- Spaw AT, Ennis BW, Spaw LP. 1991. Laparoscopic hernia repair: The anatomic basis. *J Laparoendosc Surg* 1:269–277.
- Stark E, Oestreich K, Wendl K, Rumstadt B, Hagmuller E. 1999. Nerve irritation after laparoscopic hernia repair. *Surg Endosc* 13:878–881.
- Surucu HS, Tanyeli E, Sargon MF, Karahan ST. 1997. An anatomic study of the lateral femoral cutaneous nerve. *Surg Radiol Anat* 19:307–310.
- Urbanowicz Z, Zaluska S. 1977. External structure of the cutaneous femoral lateral nerve in postfetal life in man. *Folia Morphol* 36:283–291.
- Williams PH, Trzil KP. 1991. Management of meralgia paresthetica. *J Neurosurg* 74:76–80.
- Yamout B, Tayyim A, Farhat W. 1994. Meralgia paresthetica as a complication of laparoscopic cholecystectomy. *Clin Neurol Neurosurg* 96:143–144.
- Yang SH, Wu CC, Chen PQ. 2005. Postoperative meralgia paresthetica after posterior spine surgery: Incidence, risk factors, and clinical outcomes. *Spine* 30:E547–E550.