

A Long-RP Interval Tachycardia: What is the Mechanism?

AMAN CHUGH, M.D., and FRED MORADY, M.D.

From the Division of Cardiology, University of Michigan, Ann Arbor, Michigan, USA

Case Presentation

A 34-year-old woman with a long history of paroxysmal supraventricular tachycardia underwent an electrophysiologic procedure. The baseline sinus cycle length, atrial-His (AH), and His-ventricular (HV) intervals were 720, 70, and 50 msec, respectively. A narrow-QRS complex tachycardia was induced by ventricular pacing at a cycle length of 380 msec (Fig. 1). The tachycardia cycle length was 400 msec, the AH interval was 140 msec, and the His-atrial (HA) interval was 250 msec. The response to a single ventricular extrastimulus delivered during tachycardia when the His bundle was refractory is shown in Figure 2. During tachycardia, the earliest atrial activation was recorded at the ostium of the coronary sinus. What is the mechanism of the tachycardia?

Commentary

The three most common mechanisms of a narrow-QRS complex supraventricular tachycardia with a long RP interval consist of atypical AV nodal reentrant tachycardia (AVNRT), orthodromic reciprocating tachycardia (ORT) with a slowly conducting accessory pathway, and atrial tachycardia. Atrial tachycardia is easily excluded by the response to ventricular pacing shown in Figure 1, in which the last atrial electrogram entrained by ventricular pacing was followed by a ventricular electrogram, not by another atrial electrogram.¹ Therefore, the most likely mechanism of tachycardia in this case is either atypical AVNRT or ORT. The atrial activation sequence, in which the earliest atrial activation was observed at the coronary sinus ostium, is consistent with either mechanism.

There are two clues present in Figures 1 and 2 that may help to distinguish atypical AVNRT from ORT. The first is the difference between the postpacing interval and the tachycardia cycle length (PPI-TCL interval) upon cessation of ventricular pacing, as seen in Figure 1. Ventricular pacing was performed at a cycle length of 380 msec, which was 20 msec shorter than the tachycardia cycle length of 400 msec. The postpacing interval was 565 msec, resulting in a PPI-TCL interval of 165 msec. A prior study demonstrated that the PPI-TCL interval was always <115 msec in ORT using a septal accessory pathway and was always >115 msec

in atypical AVNRT.² Therefore, in the present case, the PPI-TCL interval of 165 msec was consistent with atypical AVNRT.

A second clue is the response to a ventricular extrastimulus introduced during His-bundle refractoriness, as seen in Figure 2. Measurement of the atrial cycle lengths in the right atrial recording indicates that the ventricular extrastimulus resulted in a delay of 20 msec in the atrial electrogram. The ability of a ventricular extrastimulus to either advance or delay the atrial electrogram when the His bundle was refractory is irrefutable proof that an extranodal pathway is present, but it does not prove that the tachycardia is ORT. In light of the PPI-TCL interval of 165 msec, a likely explanation for the findings in this case is atypical AVNRT and the presence of a posteroseptal accessory pathway that was an "innocent bystander."

Could the tachycardia have been ORT, with a longer-than-usual PPI-TCL interval because of markedly decremental conduction through the accessory pathway? This possibility is ruled out by the ventricular-atrial (VA) intervals in Figures 1 and 2. The long PPI-TCL interval in Figure 1 is attributable to a VA interval during pacing that is approximately 130 msec longer than during the tachycardia. In Figure 2, when the ventricular extrastimulus shortened the ventricular cycle length by 90 msec, the VA interval increased by 100 msec (from 270 to 370 msec). This degree of decremental conduction could not account for the long postpacing VA interval that occurred in Figure 1 when pacing was performed at a cycle length only 10 msec shorter than the tachycardia cycle length.

The response to the ventricular extrastimulus seen in Figure 2 proves that an accessory pathway is present, but instead of atypical AVNRT and a bystander accessory pathway, one might hypothesize that the first cycle of atypical AVNRT was followed by ORT. The issue then becomes how to distinguish ORT from atypical AVNRT in combination with a bystander accessory pathway. Because the sites of atrial insertion of a slow AV nodal pathway and a posteroseptal accessory pathway may be identical, analysis of the atrial activation sequence may not be helpful in distinguishing the two possibilities. Findings that would be helpful consist of (1) AV block during tachycardia, which would rule out ORT; (2) a change in the VA interval during bundle branch block, which would rule in ORT; and (3) termination of the tachycardia by a ventricular extrastimulus coincident with His-bundle refractoriness, which also would rule in ORT. However, these findings are helpful diagnostically only when they are present, and they were not present in this case.

This manuscript was processed by a guest editor.

J Cardiovasc Electrophysiol, Vol. 14, pp. 551-553, May 2003.

Address for correspondence: Fred Morady, M.D., Division of Cardiology, University of Michigan Medical Center, 1500 East Medical Center Drive, Ann Arbor, MI 48109. Fax: 734-936-7026; E-mail: fmorady@umich.edu

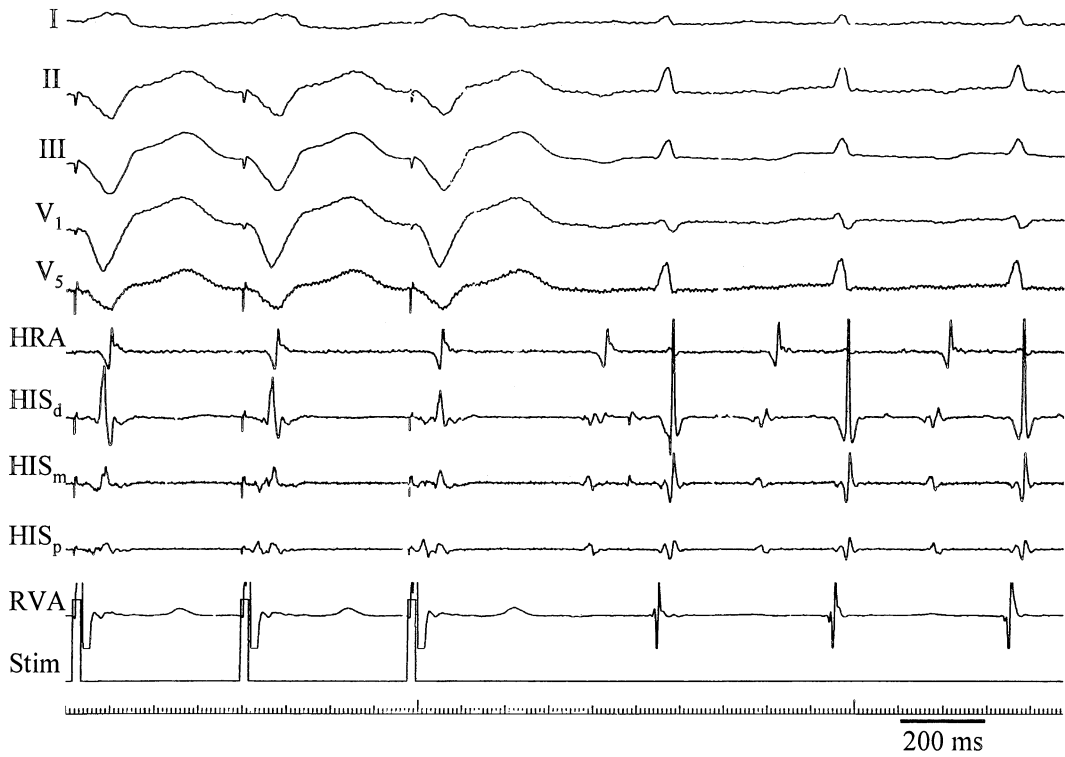


Figure 1. Induction of tachycardia by ventricular pacing at a cycle length of 390 ms. Shown are leads I, II, III, V₁, and V₅, high right atrial electrogram (HRA), His-bundle electrograms (HIS_d, HIS_m, and HIS_p), right ventricular apex electrogram (RVA), and the stimulus channel (Stim).

Therefore, it may not be possible to clearly establish whether the tachycardia was persistent atypical AVNRT with a bystander accessory pathway or one cycle of atypical AVNRT followed by ORT. However, the response to ven-

tricular pacing suggests that either the retrograde conduction time or the VA block cycle length of the accessory pathway was longer than that of the slow AV nodal pathway. This being the case, it would be difficult to explain why a single beat

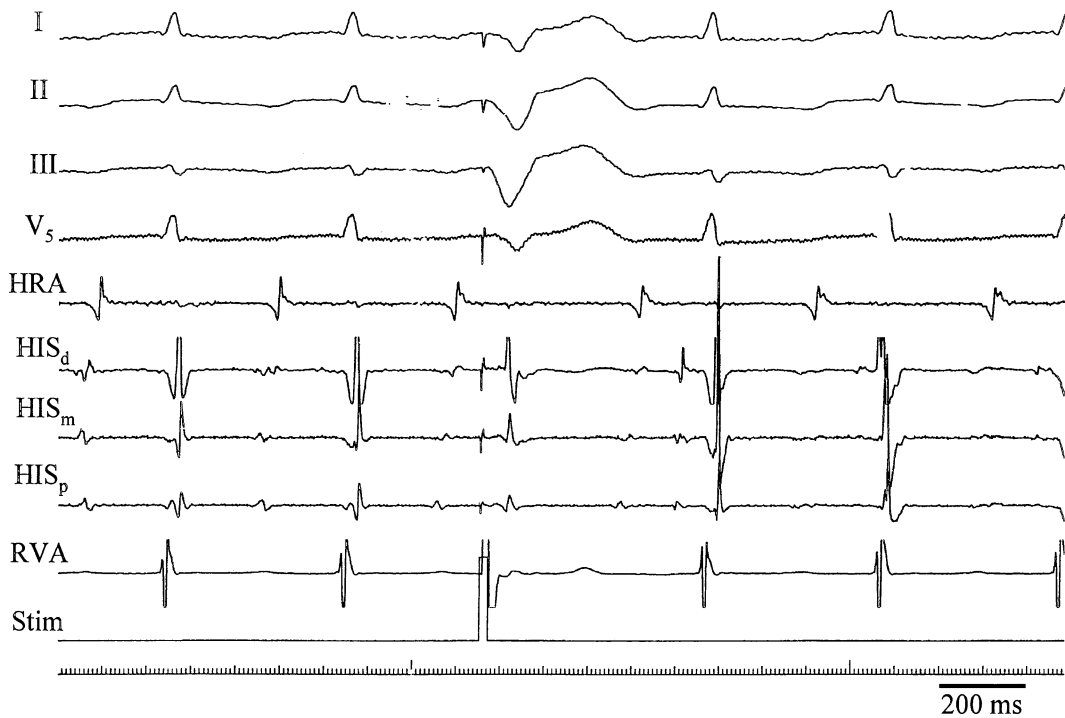


Figure 2. Response to a single ventricular extrastimulus delivered during tachycardia when the His bundle was refractory. Abbreviations as in Figure 1.

of atypical AVNRT would induce ORT, and this favors the explanation of atypical AVNRT with a bystander accessory pathway.

A single application of radiofrequency energy at the coronary sinus ostium, where there was the earliest atrial activation during tachycardia, resulted in VA block, at which point the tachycardia was no longer inducible. Regardless of whether the posteroseptal accessory pathway was or was not simply a bystander, it appears that a single application of energy ablated both the retrograde slow AV nodal pathway and the accessory pathway.

References

1. Knight BP, Zivin A, Souza J, Flemming M, Pelosi F, Goyal R, Man C, Strickberger SA, Morady F: A technique for the rapid diagnosis of atrial tachycardia in the electrophysiologic laboratory. *J Am Coll Cardiol* 1999;33:775-781.
2. Michaud GF, Tada H, Chough S, Baker R, Wasmer K, Sticherling C, Oral H, Pelosi F Jr, Knight BP, Strickberger SA, Morady F: Differentiation of atypical atrioventricular node re-entrant tachycardia from orthodromic reciprocating tachycardia using a septal accessory pathway by the response to ventricular pacing. *J Am Coll Cardiol* 2001;38:1163-1167.