

Marcio A. da Fonseca, DDS, MS, Fernanda Fontes, DDS, MS

## Early tooth loss due to cyclic neutropenia: long-term follow-up of one patient

**In young patients with abnormal loosening of teeth and periodontal breakdown, dental professionals should consider a wide range of etiological factors/diseases, analyze differential diagnoses, and make appropriate referrals. The long-term oral and dental follow-up of a female patient diagnosed in early infancy with cyclic neutropenia is reviewed, and recommendations for care are discussed.**

Dentists and dental hygienists play an important role in the early detection of diseases or conditions whose initial signs are seen in the oral cavity. In cases of abnormal loosening of teeth and periodontal breakdown without an apparent cause, the dental professional must be prepared to investigate a wide range of differential diagnoses, recommend further investigation, and make appropriate referrals.

Cyclic neutropenia (CN) is characterized by a transient decrease in the neutrophil count, with a periodicity of approximately 21 days (range, 14 to 36 days).<sup>1,2</sup> It is inherited as an autosomal-dominant condition in about one-third of the patients, with the remaining cases having an unclear mode of inheritance.<sup>1</sup> CN is caused by a defect in early hematopoietic precursor cell development (more pronounced in the myeloid precursors), leading to a periodic failure of neutrophil production in the bone marrow.<sup>1,2</sup> It has also been suggested that granulocyte colony-stimulating factor (G-CSF) production is affected.<sup>1,2</sup> Oscillations in other hematopoietic elements such as monocytes, reticulocytes, and platelets are also seen.<sup>1,3</sup>

Manifestations of the disease appear in early childhood, even though it may develop at any age.<sup>4,5</sup> These manifestations include fever, malaise, aphthous stomatitis, skin infections, pharyngitis, and lymphadenitis.<sup>1-3,6</sup> They typically appear one to three days prior to changes in the blood count and may persist from 3 to 10 days.<sup>4</sup> Because neutrophils are

the first line of defense against infection, their depletion can be fatal, although the child may appear healthy between cycles.<sup>6</sup> The diagnosis is made by documentation of two cycles of decreased neutrophil count observed in complete blood count (CBC) tests done twice weekly for 6 weeks.<sup>1</sup>

This report reviews the oral manifestations of CN and presents the case of an adult female who has been followed by our pediatric dental service since early infancy.

### Case report

Shortly after birth, in February, 1978, our patient had pustular skin infections from which *Staphylococcus aureus* was cultured, followed by several episodes of fungal diaper rash and otitis media (OM). A CBC obtained at 7 months of age, after she presented with abscesses on the buttocks, showed a white blood count cell (WBC) of 7000/mm<sup>3</sup>, with a differential count of 40% neutrophils, 55% lymphocytes, and 5% monocytes (for normal blood values, refer to the Table). Further studies revealed positive myeloperoxidase, normal immunoglobulins, normal *S. aureus* bactericidal activity, and normal chemotactic migration. Otitis media and skin infections continued to occur intermittently, and by her first birthday, she was placed on daily sulfisoxazole for 3 months, which failed to resolve her infections. Fever, neutropenia, facial cellulitis caused by mosquito bites, upper respiratory tract infections, infected thumbs, leg sores, and oral infections led to multiple hospitalizations. The patient had

**Table. Blood count normal reference values.17**

Complete Blood Count	Normal Value
Hemoglobin (g/dl)	males, 14-18; females, 12-16 newborns, 16-19; children, 11-16
Hematocrit (%)	males, 40-54; females, 37-47 newborns, 49-54; children, 35-49
White blood cells	5000-10,000 cells/mm <sup>3</sup>
Platelets	150,000-400,000 cells/mm <sup>3</sup>
Differential Blood Count	Normal Value
Neutrophils	50-70%
Lymphocytes	30-40%
Monocytes	3-7%
Eosinophils	0-5%
Basophils	0-1%

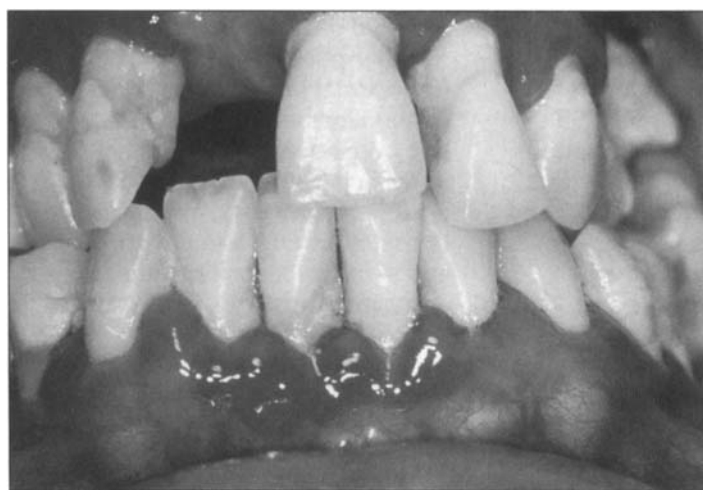$$\text{Absolute Neutrophil Count (ANC)} = \text{WBC} \times (\% \text{segs} + \% \text{bands})$$

difficulties with feeding, toothbrushing, and taking oral medications because of painful mouth ulcers. Gingival bleeding, severe gingivitis, significant bone loss, and loose primary teeth were evident by 2 years of age. Because of the oral problems, the examining pediatric dentist asked for the CBC to be repeated, and it revealed abnormalities: hemoglobin = 8.9 g/dl, platelets = 705,000/mm<sup>3</sup>, and WBC = 11,800/mm<sup>3</sup>, with a dif-

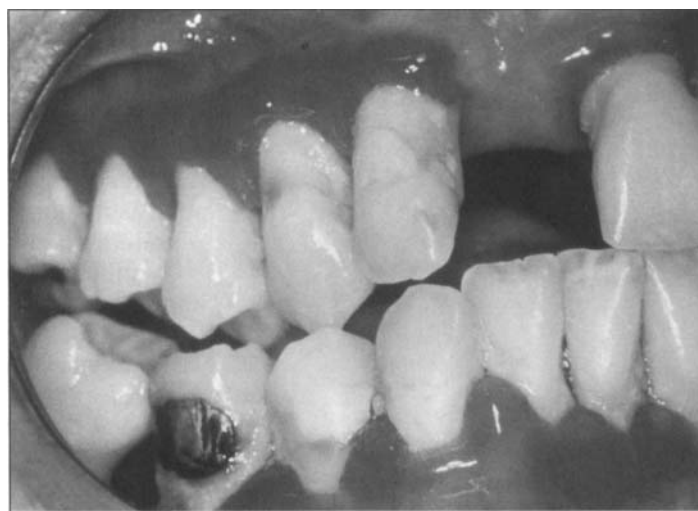ferential count of 38% monocytes, 22% eosinophils, 37% lymphocytes, 1% segmented neutrophils, and 1% bands. The majority of the neutrophils showed a lack of maturation. After additional blood tests, the patient was diagnosed with severe congenital CN. She was initially treated with steroids, followed by daily subcutaneous injections of G-CSF and GM-CSF (granulocyte macrophage colony-stimulating factor). After the

growth factors were prescribed, few oral lesions have been observed, and hospitalizations have decreased to about twice a year.

At age 5, her only remaining teeth were the maxillary right second molar and the canines. Bone loss was uniform, and the family was counseled about the poor prognosis for retaining her permanent dentition. At 6 years of age, the maxillary left permanent first molar was removed, and root caries was noted on both mandibular first molars. Despite repeated counseling, oral hygiene was not optimal at most visits, with the gingival tissues consistently appearing erythematous, edematous, and bleeding on contact. In November of 1998, clinical and radiographic examinations revealed poor oral hygiene, generalized periodontal breakdown with pocket formation, gingival recession, moderate to severe mobility of all teeth, severe bone loss, and caries (Figs. 1-3). Complete exodontia was performed uneventfully while the patient was under intravenous sedation with midazolam hydrochloride and ketorolac tromethamine. Before the procedure, her blood values were WBC = 9900/mm<sup>3</sup>, hemoglobin = 11.4 g/dl, hematocrit = 33.8%, platelets = 200,000/mm<sup>3</sup>, and ANC = 2.2. She was prescribed clindamycin for 10 days, 0.12% chlorhexidine rinses twice daily for a week, and ketorolac tromethamine for 5 days. After adequate tissue healing, complete



**Fig 1. Gingival recession, erythematous and edematous tissues, plaque accumulation.**



**Fig 2. Periodontal breakdown.**

dentures were made for her. Interestingly, following the extractions, her blood counts improved to a level not previously seen by her hematologist.

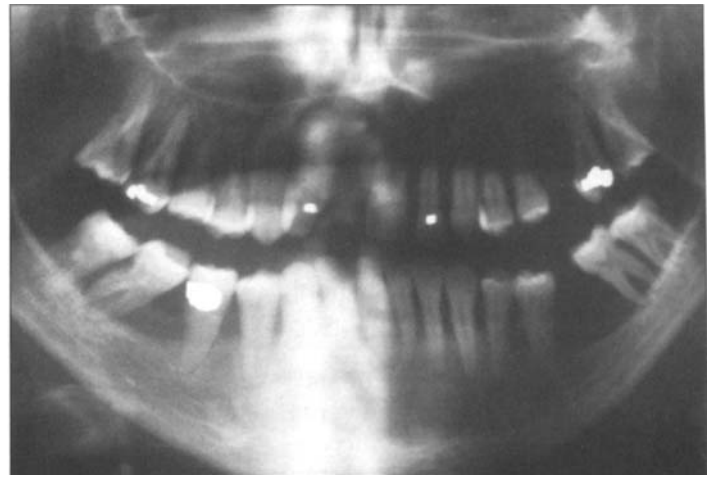
## Discussion

In hematologic disorders such as CN, prolonged neutropenia and neutrophil dysfunction can lead to life-threatening infections.<sup>7</sup> Therefore, prompt treatment of infections with antibiotics and administration of hematopoietic growth factors, such as G-CSF and GM-CSF, are required.<sup>1,2</sup> Growth factors are glycoproteins that stimulate the proliferation of bone marrow stem cells and their subsequent maturation into fully differentiated peripheral blood elements.<sup>8</sup> G-CSF, the critical cytokine for maintenance of a normal neutrophil count,<sup>10</sup> also potentiates the functional properties of mature cells by increasing phagocytic activity, antimicrobial killing, and antibody-dependent cell-mediated cytotoxicity.<sup>9</sup> Neutrophils typically spend 6 days from the last stage of cell division before entering the circulating blood. Daily injections of 30 g of G-CSF decreased the interval to 4.5 days, and 300 g daily further reduced the transit time to approximately 3 days.<sup>11</sup> The choice, dosage, and administration schedule of growth factor should be adjusted to maintain the neutrophil counts above 500/mm<sup>3</sup> and to eliminate all infections.<sup>1</sup> Our patient is currently on daily injections of 500 g of G-CSF.

The pediatric dentist who initially examined the patient was able to correlate the clinical picture with a possible neutrophil problem, leading to further studies that provided the correct diagnosis. The oral ulcerations, which occurred with a periodicity of 3 weeks, constituted one of the initial manifestations of the disorder. These were painful, and could appear in the buccal mucosa, lips, tongue, gingiva, and pharynx.<sup>2,4</sup> The lesions were usually present as a central ulceration surrounded by erythema and edema, with a white coagulum at the base.<sup>2</sup> Use of topical 2% viscous lidocaine hydrochloride or dyclonine hydrochloride (0.5% or 1.0%) helps

relieve the oral pain. Because these are contact medications, the patients should rinse or bathe the oral tissues for at least 3 minutes; otherwise the desired effect will not be produced. Diluting the viscous lidocaine a little with water makes rinsing easier. These anesthetic solutions can also be applied directly to the ulcers with a cotton tip if the patient is not able to rinse and spit. Gargling and swallowing are not advised, since loss of gag reflex can result in aspiration.<sup>12</sup> The rate of mucosal absorption of anesthetics is particularly rapid when open wounds and ulcerations are present; hence, the abuse of topical anesthetics can lead to high blood levels and systemic effects such as cardiovascular complications and central nervous system depression and excitation.<sup>13</sup> Therefore, caregivers and patients should be instructed to use topical anesthetics with caution (not more than once every 30 minutes). At least 20 minutes should elapse after an application before the patient eats a meal, to decrease the chance of accidental trauma. When the neutrophil count recovers, the ulcerations heal, usually without scarring.<sup>5,14</sup> In the patient presented here, the boost in neutrophil levels triggered by G-CSF resulted in a decrease in the frequency of oral lesions and an improvement of nutritional status, leading to fewer annual hospital admissions and lower treatment costs.

Because the resistance against bacterial infection in patients with CN is impaired, rapidly progressive periodontal breakdown is observed.<sup>15</sup> The gingiva are usually inflamed, hyperemic, and enlarged, with destruction of the interproximal papillae (Figs. 1, 2).<sup>4</sup> The periodic depression of the normal mecha-



**Fig 3. Panoramic radiograph showing extensive bone loss, caries, and several missing (extracted) permanent teeth.**

nisms that protect against oral infections leads to bone loss with occlusal dysfunction and premature loss of both primary and permanent teeth, as seen in this patient (Fig. 3).<sup>3,5,6,14</sup> Dental therapy was directed at maintenance of optimal oral care in order to keep the periodontal tissues healthy and delay the loss of alveolar bone and teeth for as long as possible. Intensive preventive care was advocated, with professional prophylaxis and scaling done every few weeks when the CBC was high.<sup>15,16</sup> The caregivers should be educated about the role of dental plaque in the development and progression of periodontal disease. They should be trained and periodically re-evaluated in their ability to provide adequate home care with meticulous plaque control through brushing and flossing, and with chlorhexidine rinses as an adjunct. Prescription of fluoride rinses or gels should be considered, because these patients are at high risk for caries due to their often sub-optimal oral hygiene and soft diet.

An important issue for the dental professional treating neutropenic patients is the development of fungal infections, particularly candidiasis, which is frequently seen as raised, white, curd-like plaque appearing in any area of the oral cavity.<sup>17</sup> These can be scraped off, showing a raw, bleeding base.<sup>17</sup> The common topical medications used to treat candidiasis,

such as nystatin rinses and clotrimazole troches, have a high sugar content; therefore, the patients should be advised about the risk of dental caries. Azole agents (ketoconazole, clotrimazole, fluconazole) are effective as antifungal prophylaxis, while nystatin is usually not successful when used prophylactically.<sup>18-21</sup> Intravenous amphotericin B should be used only for invasive and systemic infections.<sup>12</sup>

Cooperation from the patients and their caregivers must be very high for the outcome to be successful.<sup>3,15</sup> Antibiotic and corticosteroid coverage should be discussed with the physician prior to dental procedures that require invasion of oral tissues.<sup>4</sup> Placement of restorations should be carefully done in order to avoid gingival irritation. Intra-oral prostheses should be designed not to impinge on the soft tissues and to facilitate good oral hygiene.<sup>4,5</sup> Splinting of loose teeth should be considered carefully to ensure integrity of the remaining teeth and their supporting structures.<sup>4,5</sup>

Dr. da Fonseca (corresponding author) is Assistant Clinical Professor, Department of Orthodontics and Pediatric Dentistry, University of Michigan, 1011 N. University Ave., # K-1014, Ann Arbor, MI 48109 (marcio@umich.edu). Dr. Fontes is Lecturer,

Pediatric Dentistry, also at the University of Michigan.

1. Souid AK. Congenital cyclic neutropenia. *Clin Pediatr* 34:151-5, 1995.
2. Rodenas JM, Ortego N, Herranz MT, et al. Cyclic neutropenia: a cause of recurrent aphthous stomatitis not to be missed. *Dermatol* 184:205-7, 1992.
3. Pernu HE, Pajari UH, Lanning M. The importance of regular dental treatment in patients with cyclic neutropenia. Follow-up of 2 cases. *J Periodontol* 67:454-9, 1996.
4. Spencer P, Fleming JE. Cyclic neutropenia: a literature review and report of case. *J Dent Child* 52:108-13, 1985.
5. Binon PP, Dykema RW. Rehabilitative management of cyclic neutropenia. *J Prosthet Dent* 31:52-60, 1974.
6. Prichard JF, Ferguson DM, Windmiller J, et al. Prepubertal periodontitis affecting the deciduous and permanent dentition in a patient with cyclic neutropenia. *J Periodontol* 55:114-22, 1984.
7. Malech HC, Gallin JI. Neutrophils in human diseases. *N Engl J Med* 317:687-94, 1987.
8. Metcalf D. The colony-stimulating factors: discovery, development and clinical applications. *Cancer* 65:2185-95, 1990.
9. Platzer E, Welte K, Gahrlove J, et al. Biological activities of human pluripotent hematopoietic colony stimulating factor on normal and leukemic cells. *J Exp Med* 162:1788-801, 1985.
10. Dale DC, Liles WC, Sumer WR, et al. Review: granulocyte colony-stimulating factor-role and relationships in infectious disease. *J Infect Dis* 172:1061-75, 1992.
11. Price TH, Chatta GS, Dale DC. The effect of recombinant granulocyte colony-stimulating factor (G-CSF) on neutrophil kinetics in normal human subjects (abstract). *Blood* 80:350a, 1992.
12. Schubert MM, Sullivan KM, Truelove EL. Head and neck complications of bone marrow transplantation. In: Head and neck management of the cancer patient. Peterson DE, Elias EG, Sonis ST, editors. Boston: Martinus Nijhoff Publishers, pp. 401-27, 1986.
13. Epstein JB. Oral cancer. In: Burket's oral medicine diagnosis and treatment. 9th ed. Lynch MA, Brightman VJ, Greenberg MS, editors. Philadelphia: J.B. Lippincott Co., pp. 203-39, 1994.
14. Long LM, Jacoway JR, Bawden JW. Cyclic neutropenia: case report of two siblings. *Pediatr Dent* 5:142-4, 1983.
15. Rylander H, Ericsson I. Manifestations and treatment of periodontal disease in a patient suffering from cyclic neutropenia. *J Clin Periodontol* 8:77-87, 1981.
16. Scully C, MacFadyen E, Campbell A. Oral manifestations in cyclic neutropenia. *Br J Oral Surg* 20:96-101, 1982.
17. Sonis S, Fazio RC, Fang L. Principles and practice of oral medicine. 2nd ed. Philadelphia: W.B. Saunders Co., pp. 17-8, 426-54, 1995.
18. Reents S, Goodwin SD, Singh V. Antifungal prophylaxis in immunocompromised hosts. *Ann Pharmacother* 27:53-60, 1993.
19. Denning DW, Donnelly JP, Hellreigel KP, et al. Antifungal prophylaxis during neutropenia or allogeneic bone marrow transplantation: what is the state of the art? *Chemotherapy* 38:43-9, 1992.
20. Meunier F, Paesmans M, Autier P. Value of antifungal prophylaxis with antifungal drugs against oropharyngeal candidiasis in cancer patients. *Oral Oncol Eur J Cancer* 30(B):196-9, 1994.
21. Milliken ST, Powles RL. Antifungal prophylaxis in bone marrow transplantation. *Rev Infect Dis* 12:S374-9, 1990.