

## Hematochezia and the False Negative Meckel's Scan: A Continued Need for Barium Studies

K. Stiennon Gebarski, M.D., William J. Byrne, M.D., Stephen S. Gebarski, M.D., John R. Wesley, M.D., and Arnold G. Coran, M.D.

*Departments of Radiology, Pediatrics (Gastroenterology), and Pediatric Surgery, University of Michigan Medical Center, Ann Arbor, Michigan*

A patient with hematochezia and a false negative Meckel's scan is presented. A Meckel's diverticulum was subsequently diagnosed on barium small bowel follow-through. Meckel's diverticulum is discussed with emphasis on the relationship of barium and radionuclide studies.

### INTRODUCTION

Incomplete obliteration of the omphalomesenteric duct results in a diverticulum and/or tract first described by Meckel in 1809. The diverticulum was infrequently diagnosed preoperatively (1, 2) until the advent of the technetium  $99^m$  pertechnetate scan. Despite a specificity of 85% and an accuracy of greater than 90% (3), false negative studies are a problem. Modern imaging modalities tend to distract from the more traditional barium studies, and as our case demonstrated, barium studies may diagnose a Meckel's diverticulum in light of a negative Meckel's scan.

### CASE REPORT

A 17-year-old white man developed cramping right lower quadrant abdominal pain followed 8 h later by the passage of a large bloody stool. He subsequently became dizzy and 30 min later passed a second grossly bloody stool. In the emergency room, his blood pressure was 138-60, heart rate 115. He had three more large bloody bowel movements. After transfusion of three units of whole blood, his vital signs returned to and remained normal. His posttransfusion hemoglobin was 14.6 g/dl and the hematocrit 42%. Past medical history was unremarkable. The physical examination was normal.

A technetium  $99^m$  pertechnetate Meckel's scan performed the following day was negative. Total colonoscopy revealed no pathological lesions. Old blood was visible up to the level of the ileocecal valve. A subsequent pentagastrin stimulated Meckel's scan was also negative. On a barium small bowel follow-through, an abnormally dilated loop of bowel was seen approximately 15 cm proximal to the ileocecal valve (Fig. 1).

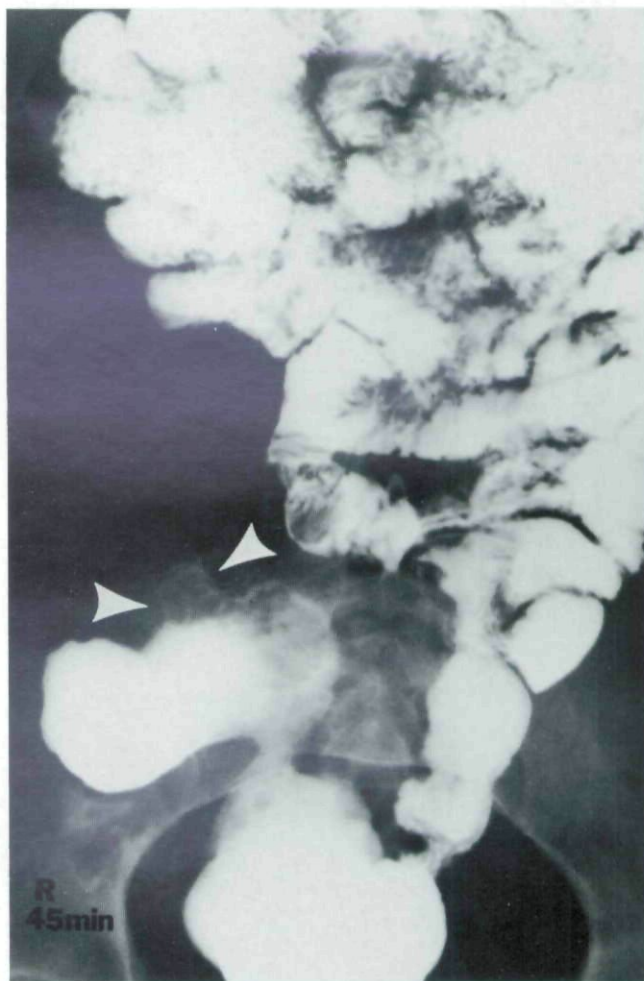

FIG. 1. Anterior-posterior 45-min small bowel follow-through film demonstrating a dilated, edematous segment of ileum with a double contrast image of the Meckel's diverticulum (arrowheads).

On lateral view, a small portion projected anteriorly consistent with a Meckel's diverticulum (Fig. 2). At laparotomy, the distal ileum was edematous, and a 2 x 3 cm Meckel's diverticulum (Fig. 3) was excised. Pathological sectioning and microscopic examination revealed foci of gastric mucosa and a small acute ulcer. The postoperative recovery was uneventful.



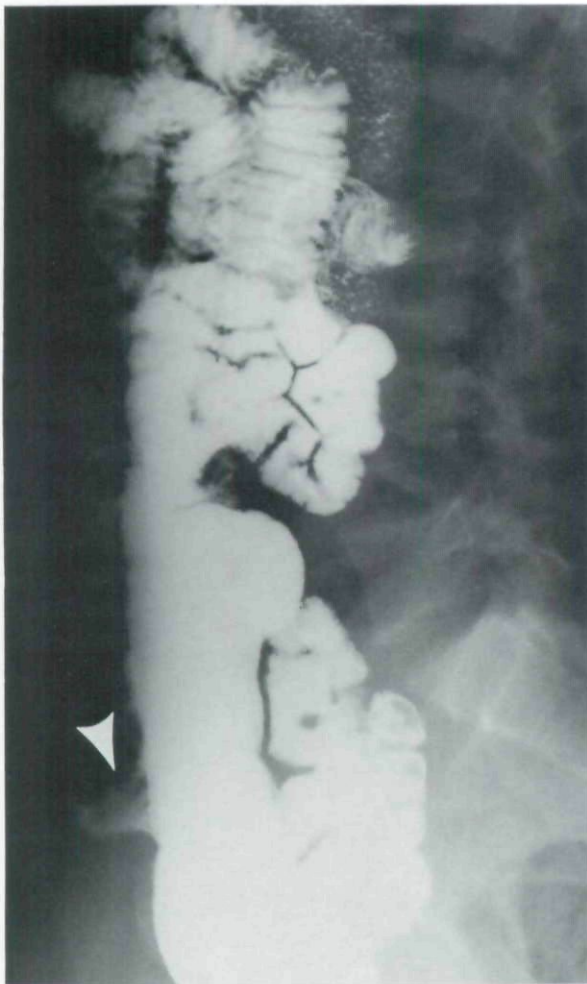

FIG. 2. Lateral 45-min small bowel follow-through film again showing a double contrast image of the Meckel's diverticulum (*arrowhead*). The antimesenteric projection of this diverticulum is clearly demonstrated.

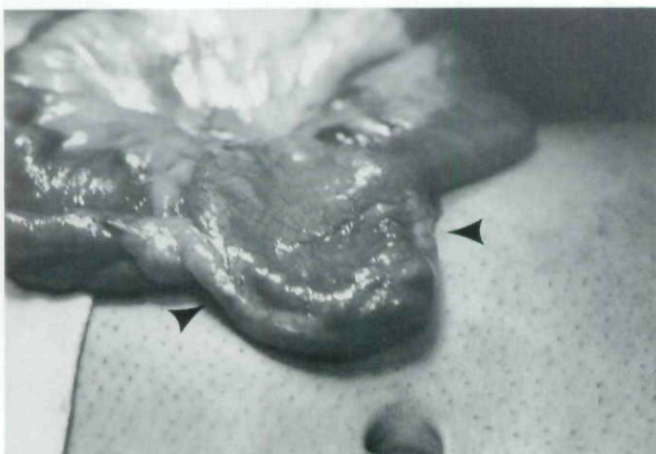


FIG. 3. Operative photograph demonstrating the Meckel's diverticulum (*arrowheads*). The lesion measured approximately  $2 \times 3$  cm.

#### DISCUSSION

The Meckel's diverticulum is usually found within 1 m of the ileocecal valve on the antimesenteric border of the ileum. The incidence in the general population,

determined by autopsy series, is 1–3% (1–5). Complications (inflammation, adhesions, obstruction, volvulus, intussusception, ulceration, bleeding, perforation, and neoplasm) are responsible for the symptomatic cases estimated at approximately 25–40% of all affected people (4, 6). Of these, slightly more than 50% contain ectopic gastric mucosa (1, 3, 5). However, 90% or more of bleeding Meckel's diverticula have gastric mucosa accounting for the high accuracy and specificity of the radionuclide scan (5, 7). Pentagastrin stimulates the concentration of pertechnetate anion in gastric mucosa, improving the scan quality. False negatives result from insufficient mass of gastric tissue, suboptimal technique, downstream washout of pertechnetate, and excessive secretions or motility. As the barium-filled bowel will attenuate the radioactivity, the Meckel's scan must be performed first. Although unusual, Meckel's diverticula (2) can be diagnosed with barium studies in the face of a negative Meckel's scan.

Why both our Meckel's scans were negative is unclear. The first scan was performed within 24 h after admission so one might speculate that there was a washout of isotope due to continued bleeding. However, the second pentagastrin augmented scan was performed on the 3rd hospital day, at a time when there was no evidence for ongoing blood loss, suggesting another mechanism to explain the negative studies. Since the patient was not having excessive numbers or large volumes of stool, excessive secretions or increased motility seem unlikely explanations. Technical problems were not encountered and the protocols used for the studies have been successful in the past. We are then left with the possibility that even though gastric tissue was present on pathological examination of the diverticulum, it was of insufficient mass to be detected by the pertechnetate studies.

Radiographically, the diverticula vary in length from 1 to several cm, are usually dilated, and often have a wide mouth. They arise perpendicular to the antimesenteric ileal border and may project anteriorly towards the umbilicus. They may be filled with old blood or calculi, and can ulcerate, perforate, intussuscept, torsion, or obstruct (1, 3, 4, 6).

The clinical presentation of a Meckel's diverticulum depends upon the complication. A bleeding Meckel's diverticulum should be included in the differential diagnosis of hematochezia with or without accompanying pain. If this or other small bowel lesions are suspected, and the Meckel's scan is negative, a contrast study of the small bowel should be performed. When the barium reaches the distal ileum, careful attention, including lateral views, may demonstrate the diverticulum and establish the diagnosis.

Reprint requests: Dr. K. Stienon Gebarski, Department of Radiology, University of Michigan Medical Center, Ann Arbor, MI 48109.

## REFERENCES

1. Bischoff ME, Stampfli WP. Meckel's diverticulum. *Radiology* 1955;65:572-7.
2. Mackey WC, Dineen P. A fifty year experience with Meckel's diverticulum. *Surg Gynecol Obstet* 1983;156:56-64.
3. Craig O, Murfitt J. Radiological demonstration of Meckel's diverticulum. *Br J Surg* 1908;67:881-3.
4. Dalinka MK, Wunder JF. Meckel's diverticulum and its complications, with emphasis on roentgenologic demonstration. *Radiology* 1973;106:295-8.
5. Sfakianakis GN, Conway JJ. Detection of ectopic gastric mucosa in Meckel's diverticulum and in other aberrations by syntography: I. Pathophysiology and ten year clinical experience. *J Nucl Med* 1981;22:647-54.
6. Enge I, Frimann-Dhal J. Radiology in acute abdominal disorders due to Meckel's diverticulum. *Br J Radiol* 1964;37:775-80.
7. Sfakianakis GN, Conway JJ. Detection of ectopic gastric mucosa in Meckel's diverticulum and other aberrations by syntography: I. Indications and methods—a ten-year experience. *J Nucl Med* 1981;22:732-8.

This document is a scanned copy of a printed document. No warranty is given about the accuracy of the copy. Users should refer to the original published version of the material.