

## Original Contribution

# Combination Therapy With Adapalene Gel 0.1% and Doxycycline for Severe Acne Vulgaris: A Multicenter, Investigator-Blind, Randomized, Controlled Study

Diane M. Thiboutot, MD;<sup>1</sup> Alan R. Shalita, MD;<sup>2</sup> Paul S. Yamauchi, MD, PhD;<sup>3</sup> Catherine Dawson, BSc;<sup>4</sup> Stéphanie Arsonnaud, BMCA;<sup>4</sup> Sewon Kang, MD;<sup>5</sup> on behalf of the Differin Study Group

From The Pennsylvania State University College of Medicine, Milton S. Hershey Medical Center, Hershey, PA;<sup>1</sup> SUNY Downstate Medical Center, Brooklyn, NY;<sup>2</sup> UCLA School of Medicine, Santa Monica, CA;<sup>3</sup> Galderma Research & Development, Princeton, NJ;<sup>4</sup> University of Michigan, Ann Arbor, MI<sup>5</sup>

Address for correspondence:  
Diane M. Thiboutot, MD,  
Department of Dermatology,  
HU14, Milton S. Hershey  
Medical Center, The  
Pennsylvania State University,  
P.O. Box 850, Hershey,  
PA 17033-0850  
E-mail: dthiboutot@psu.edu

 www.lejacq.com  
ID: 4279

**Background.** Combination therapy with a topical retinoid and an antibiotic is recognized as a rational and effective approach for the treatment of acne vulgaris. Adapalene, a naphthoic acid derivative with anti-inflammatory and receptor-selective retinoid properties, is safe and well tolerated. While the combination of adapalene with oral or topical antibiotics has been shown to deliver a superior and faster response than an antibiotic alone, the clinical benefits of a combination of adapalene and doxycycline, the most frequently prescribed oral antibiotic for acne in the United States, have yet to be evaluated.

**Objective and Methods.** In a 12-week study, the efficacy and safety of the combination of adapalene gel 0.1% with doxycycline was compared with doxycycline alone for the treatment of severe acne. Subjects were randomized to receive doxycycline once daily in the morning and either adapalene or vehicle once daily in the evening.

**Results.** At Week 12, the combination adapalene-doxycycline was significantly superior to doxycycline alone for change from baseline in total ( $p < 0.001$ ), inflammatory ( $p = 0.02$ ), and noninflammatory ( $p < 0.001$ ) lesions. Significant differences in total lesions were observed as early as Week 4 ( $p = 0.04$ ). Both treatments were well tolerated, and no serious adverse events were reported.

**Conclusions.** The study demonstrates that the combination of adapalene and an oral antibiotic provides a superior and faster benefit than antibiotic therapy alone and should be considered at the initiation of treatment. (SKINmed. 2005;4:138-146) ©2005 Le Jacq Ltd.

**A**cne vulgaris is a complex skin disorder involving multiple abnormalities of the pilosebaceous unit including hyperkeratinization, sebum production, bacterial proliferation, and inflammation.<sup>1,2</sup> If not treated properly, acne may be physically and emotionally scarring, causing those afflicted by the disease to have significant psychosocial morbidity and reduced self-esteem.<sup>2-4</sup> Existing topical and systemic therapies recommended for the treatment of acne include retinoids, antibiotics, benzoyl peroxide, and hormonal therapy. Since most anti-acne medications do not act against all four of the major pathophysiologic features of acne, combination therapy with a topical retinoid and an antimicrobial is often used in the management of moderate-to-severe acne<sup>4</sup>; however, until recently, only a few well controlled combination studies have been reported.<sup>5-7</sup>

Adapalene, a naphthoic acid derivative with anti-inflammatory and receptor-selective retinoid properties,<sup>8-12</sup> is a rational choice for combination therapy. The efficacy of adapalene in the treatment of acne vulgaris has been extensively studied in numerous clinical trials.<sup>13,14</sup> Adapalene is safe and well tolerated, consistently demonstrating a more favorable tolerability profile than other topical retinoids, including all tazarotene<sup>15,16</sup> and tretinoin formulations.<sup>16-19</sup>

In addition, adapalene is well tolerated when concomitantly administered with a variety of other topical acne medications.<sup>20,21</sup> The use of multiple agents may increase irritation and decrease the likelihood of treatment adherence. Therefore, it is imperative that the selection of medications used in combination therapy involve careful consideration of the efficacy as well as irritation potential of the individual acne medications.

Several recent studies have investigated the efficacy and safety of adapalene when used in combination therapy with oral or topical antibiotics for the treatment of inflammatory acne.<sup>22,23</sup> Results from these studies clearly demonstrated that the combination of adapalene gel 0.1% with oral lymecycline or topical clindamycin delivered a superior and faster response than either antibiotic alone; however, the clinical benefits of a combination of adapalene gel 0.1% and doxycycline, the most frequently prescribed oral antibiotic for acne in the United States, have yet to be evaluated. The objective of this study was to compare the efficacy and safety of the combination of adapalene gel 0.1% with doxycycline 100 mg capsules to doxycycline alone for the treatment of severe acne vulgaris.

## Methods

**Study Design.** The efficacy and safety of the combination adapalene gel 0.1% plus doxycycline were compared with doxycycline alone in a randomized, multicenter, vehicle-controlled, investigator-blind, parallel group study conducted at 35 centers in the United States between August 20, 2003, and January 29, 2004. Subjects were randomized in 1:1 ratio to receive doxycycline (100 mg capsule) once daily in the morning (as per its labeling) and either adapalene or adapalene gel vehicle once daily in the evening for 12 weeks. The integrity of the blinding was ensured by packaging the topical medication in identical tubes and requiring a third party other than the investigator/evaluator to dispense the medication. Evaluations occurred at baseline and at Weeks 4, 8, and 12. A urine pregnancy test was required at screening and at the final study visit for all females of childbearing potential. Subjects were free to withdraw from the study at any time and for any reason. Subjects not completing the entire study were fully evaluated when possible.

This study was conducted in accordance with the ethical principles originating from the Declaration of Helsinki and Good Clinical Practices and in compliance with local regulatory requirements. This study was reviewed and approved by an institutional review board. All patients provided their written informed consent before entering the study.

**Subjects.** Men and women with severe facial acne (global severity score of at least 4 on a scale ranging from 0 [clear] to 5 [very severe]) were recruited. Eligible subjects were required to have a minimum of 15 inflammatory lesions and 15–100 noninflammatory facial lesions. Washout periods were required for subjects taking certain topical and systemic treatments. Exclusion criteria prohibited the enrollment of subjects with acne requiring isotretinoin therapy or other dermatologic conditions requiring interfering treatment. Women were excluded if they were pregnant, nursing, or planning a pregnancy, as were men with facial hair that would interfere with the assessments.

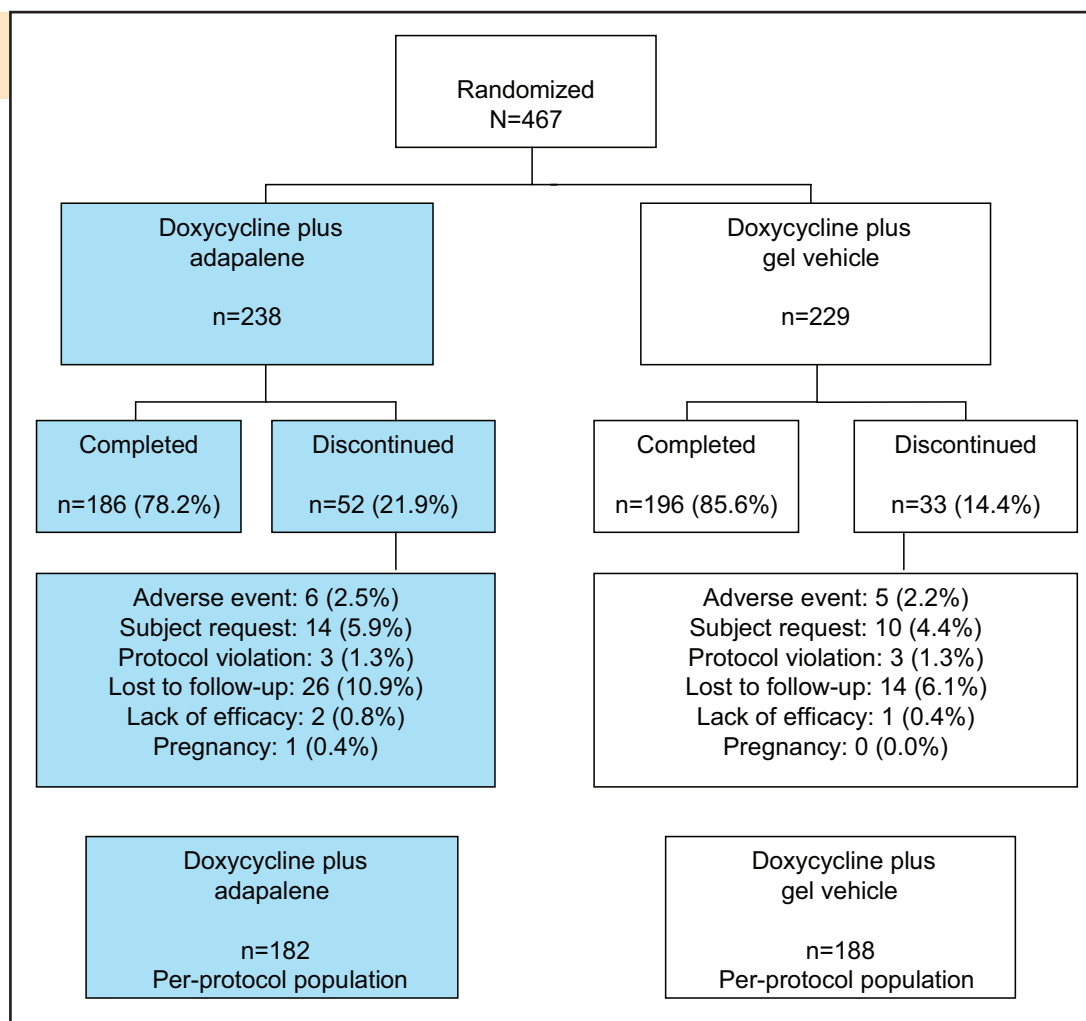
**Efficacy and Safety Assessments.** The primary efficacy variable was the percent reduction in total lesion count from baseline. Secondary efficacy assessments included percent reduction in inflammatory and noninflammatory lesion counts, the global assessment of improvement of the disease from baseline, and the global severity score using the dichotomous scale of success (grades 0 [clear] and 1 [almost clear]) or failure (grades 2 [mild], 3 [moderate], 4 [severe], and 5 [very severe]). At the last visit, subject satisfaction was assessed via a four-question survey.

Safety and tolerability were assessed through evaluations of local facial tolerability and adverse events. At each visit, the investigator rated erythema, scaling, dryness, and stinging/burning on a scale ranging from 0 (none) to 3 (severe). Adverse events were evaluated at each visit.

**Statistical Analyses.** All data analyses were carried out according to a preestablished analysis plan. A sample size of 210 subjects

**Combination therapy with a topical retinoid and an oral antibiotic is a rational and effective approach for the treatment of acne vulgaris.**

**Figure 1.** Flowchart of subject disposition



per group was deemed necessary to detect a statistically significant difference in total lesion count between treatment groups based on the use of a 2-tailed test with  $\alpha=0.5$  and a power of 90%, an assumption of a median 12% difference with an SD of 35 units in percent change from baseline in total lesions, and a dropout rate of 15%.

Three study populations were analyzed. The safety population was defined as all patients randomized and treated at least once. The intent-to-treat (ITT) population included all randomized subjects who were dispensed study medication. The per-protocol (PP) population included all randomized subjects without any major protocol deviations.

The objective was to show superior efficacy of the combination of adapalene gel 0.1% plus doxycycline relative to doxycycline alone. Analyses for efficacy were performed on

the Week 12 data for the ITT population and the PP population. Continuous variables were tested for baseline comparability with the analysis of variance model, with treatment, center, and their interaction as factors. Categorical variables were tested with the Cochran-Mantel-Haenszel (CMH) test stratified by the center. All tests were 2-sided and used the 0.05 level to declare significance. No adjustment for multiplicity was made.

## Results

**Subject Disposition and Baseline Characteristics.** A total of 467 subjects were randomized and included in the ITT population: 238 receiving doxycycline plus adapalene gel 0.1% and 229 receiving doxycycline plus gel vehicle (Figure 1). Subject disposition was similar between the treatment groups. The PP population consisted of 370 subjects (79%). Overall, 82% of subjects completed the study. Discontinuation

**Table.** Subject Demographics and Baseline Characteristics (Intent-to-Treat Population)

PARAMETER	DOXYCYCLINE PLUS ADAPALENE (N=238)	DOXYCYCLINE PLUS GEL VEHICLE (N=229)	P VALUE
Age (yr) (mean [SD])	17.7 (4.20)	18.0 (4.53)	0.3784*
Range	12–36	12–34	
Gender			
Male (n [%])	122 (51.3)	128 (55.9)	0.3015*
Female (n [%])	116 (48.7)	101 (44.1)	
Race			
Caucasian (n [%])	149 (62.6)	142 (62.0)	0.9859*
Black (n [%])	31 (13.0)	31 (13.5)	
Asian (n [%])	7 (2.9)	6 (2.6)	
Hispanic (n [%])	48 (20.2)	48 (21.0)	
Other (n [%])	3 (1.3)	2 (0.9)	
Lesion counts			
Total (mean [SD])	82.0 (31.07)	83.0 (32.18)	0.7586
Inflammatory (mean [SD])	31.7 (13.63)	33.9 (18.08)	0.3008
Noninflammatory (mean [SD])	49.9 (24.41)	48.6 (23.60)	0.7147
Global severity assessment			
Clear (n [%])	0 (0.0)	0 (0.0)	
Minimal (n [%])	0 (0.0)	0 (0.0)	
Mild (n [%])	0 (0.0)	0 (0.0)	
Moderate (n [%])	0 (0.0)	0 (0.0)	
Severe (n [%])	238 (100.0)	229 (100.0)	
Very severe (n [%])	0 (0.0)	0 (0.0)	

\*p Value is from a two-way analysis of variance for age with treatment, center, and their interaction as factors for comparing age, and from Cochran-Mantel-Haenzsel test stratified by center for comparing gender and race.

rates were slightly higher in the doxycycline plus adapalene group (21.9%) relative to the doxycycline plus vehicle group (14.4%), mainly due to differences in the percentage of subjects who were lost to follow-up (10.9% in the doxycycline plus adapalene group and 6.1% in the doxycycline plus vehicle group). Subject request and lost to follow-up were the most frequent reasons for discontinuation.

The baseline characteristics of the ITT population are summarized in the Table. The treatment groups were comparable with respect to the demographic characteristics and baseline dermatologic scores.

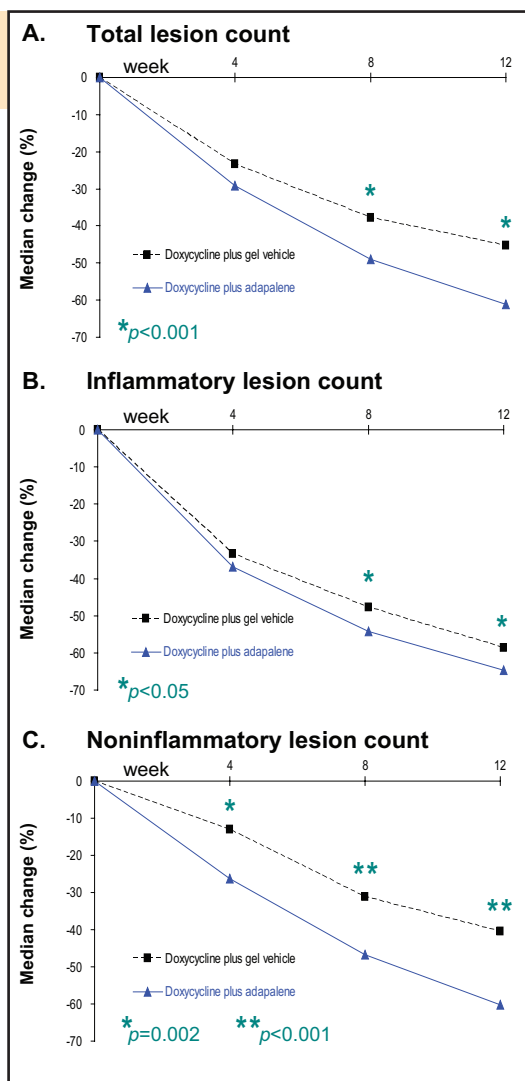
**Efficacy Evaluation.** Percent changes in lesion counts (total, inflammatory, and noninflammatory) from baseline at Weeks 4, 8, and 12 are shown in Figure 2. The combination of doxycycline plus adapalene consistently demonstrated statistically superior advantages for all efficacy assessments relative to doxycycline alone. At Week 12, the combination of doxycycline and adapalene produced significantly greater reductions relative to doxycy-

cline alone for median percent change from baseline in total (61.2% vs. 45.3%;  $p<0.001$ ), inflammatory (64.6% vs. 58.5%;  $p=0.02$ ), and noninflammatory (60.3% vs. 40.5%;  $p<0.001$ ) lesion counts. Significant differences in total lesion count were observed as early as the first post-baseline visit (Week 4;  $p=0.04$ ; data not shown). Early onset of action was also observed for noninflammatory lesion counts (Week 4;  $p=0.02$ ) and inflammatory lesion counts (Week 8;  $p=0.02$ ).

Analyzing the global severity assessment using the dichotomous scale of success or failure, more subjects were “clear” or “almost clear” (success) in the adapalene–doxycycline group relative to the doxycycline-alone group (22.1% vs. 13.1%;  $p=0.02$ ) after 12 weeks of treatment. In addition, fewer subjects in the adapalene–doxycycline group were “severe” or “very severe” at the end of the study compared with the doxycycline-alone group (8.4% vs. 13.6%). Similarly, data for global improvement of disease from baseline demonstrated significantly superior progress for subjects receiving adapalene and doxycycline relative to those receiving doxycycline alone

## Combination Therapy for Severe Acne

**Figure 2.** Percent change in lesion counts (intent-to-treat population)



(49.5% vs. 40.9% [clear, almost clear, marked improvement];  $p=0.02$ ; Figure 3). Results in the PP population were similar. Figure 4 illustrates the effect of adapalene–doxycycline combination therapy on severe facial acne during the course of the 12-week study.

**Safety Evaluation.** The scores for the severity of erythema, scaling, dryness, and stinging/burning after study treatment are summarized in Figure 5. Local cutaneous tolerability of the study treatments was good for both groups, with mean tolerability scores for erythema, dryness, scaling, and stinging/burning at each visit and worst scores all less than 1 (mild). A majority of subjects in both groups experienced mild or no irritation.

The incidence of adverse events in both treatment groups was similar, with 34.5% and

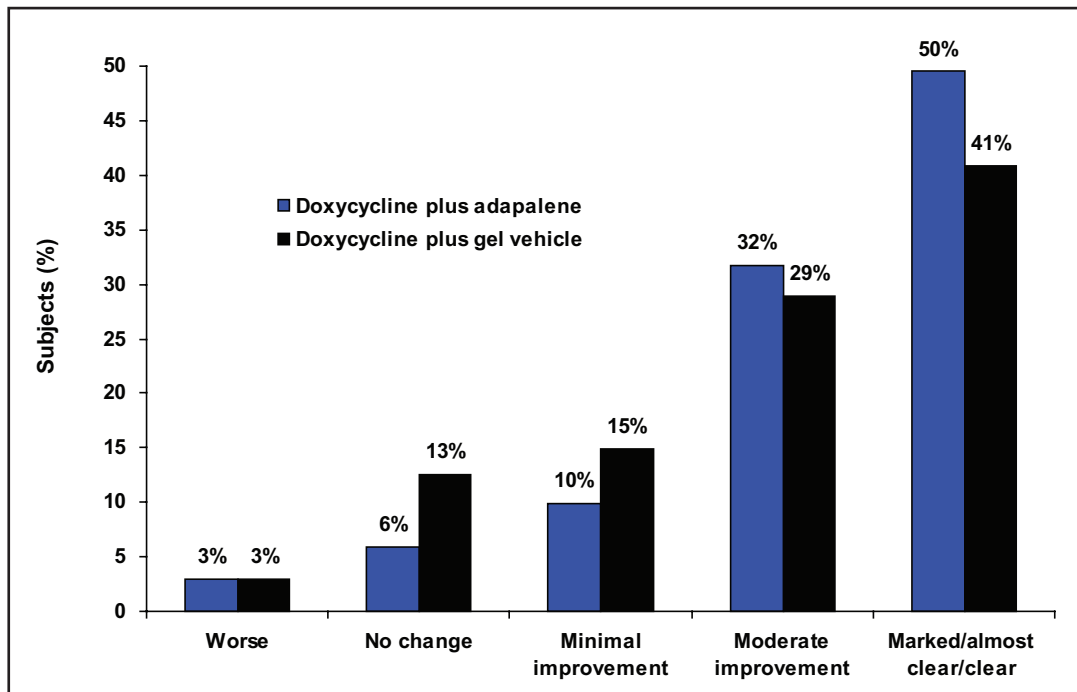
37.6% reported in the adapalene–doxycycline and doxycycline-alone groups, respectively. Treatment-related adverse events occurred in 12.6% of subjects in the adapalene–doxycycline group and 16.2% of the doxycycline-alone group. The most frequently reported treatment-related adverse events were nausea (4.2% adapalene–doxycycline; 4.8% doxycycline alone), vomiting (3.4% adapalene–doxycycline; 2.6% doxycycline alone), dyspepsia (1.7% adapalene–doxycycline; 2.6% doxycycline alone), and headache (2.5% adapalene–doxycycline; 2.6% doxycycline alone).

There were five (2.1%) discontinuations due to treatment-related adverse events in the adapalene–doxycycline group and four (1.7%) in the doxycycline-alone group; only one of the treatment-related discontinuations were deemed possibly related to adapalene (sunburn). Most adverse events were mild or moderate in severity (98%), and there were no deaths or serious adverse events during the study.

**Subject Survey.** Figure 6 illustrates the results from the four-question subject survey. A majority of subjects in both groups were not bothered by the combination treatment side effects (79.2% adapalene–doxycycline; 80.0% doxycycline alone;  $p=0.69$ ). Significantly more subjects in the adapalene–doxycycline group were satisfied or very satisfied with the combination treatment effectiveness compared with the doxycycline-alone group (77.7% vs. 62.7%;  $p=0.004$ ). Similarly, significantly more subjects receiving the combination of adapalene and doxycycline felt better about themselves at the end of the study (75.5% vs. 61.7% [“much better” or “a lot better”];  $p=0.04$ ). Overall, subject satisfaction with their treatment regimen was significantly better in the adapalene–doxycycline group relative to subjects taking doxycycline alone (79.2% vs. 68.8% [“very satisfied” or “satisfied”];  $p=0.006$ ).

## Discussion

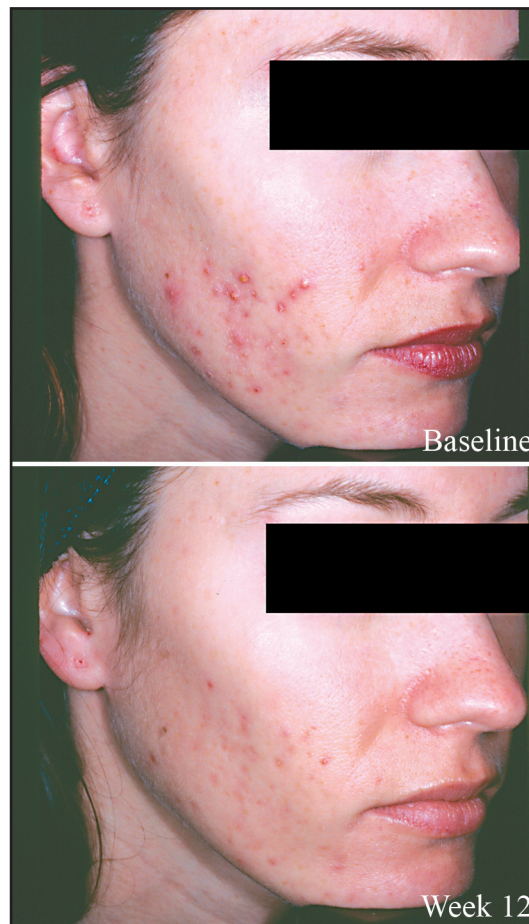
Due to the complex pathogenesis of acne vulgaris, combination therapy for the treatment of acne is widely prescribed and extensively cited throughout the literature as a highly effective treatment approach for this disease.<sup>4,24</sup> Despite the ubiquitous nature of this treatment regimen, there are relatively few



**Figure 3.** Global improvement of disease relative to baseline (intent-to-treat population)

controlled studies exploring the efficacy and safety of such combinations—and no previous studies investigating the combination of adapalene gel 0.1% with an oral antibiotic that is currently approved in the United States for the treatment of acne. The aim of this study was to evaluate the safety and efficacy of the combination of adapalene gel 0.1% plus oral doxycycline relative to doxycycline plus vehicle in subjects with severe facial acne vulgaris.

Results of this study show that the combination was significantly more effective than doxycycline alone for the treatment of acne vulgaris. There were significantly superior reductions at the end of the study in the combination group relative to the doxycycline-alone group in total, inflammatory, and noninflammatory lesions (at least  $p < 0.05$ ). Subjects also demonstrated a faster response to the combination therapy, with statistically significant differences in lesion counts observed as early as the first post-baseline assessment. Similarly, results from secondary efficacy analyses showed significantly improved results for subjects in the adapalene-doxycycline combination group relative to the doxycycline-alone group. Global severity assessments and the global assessment of improvement from baseline showed significantly greater improvement in the combination group relative to the antibiotic-alone group (both  $p = 0.02$ ).

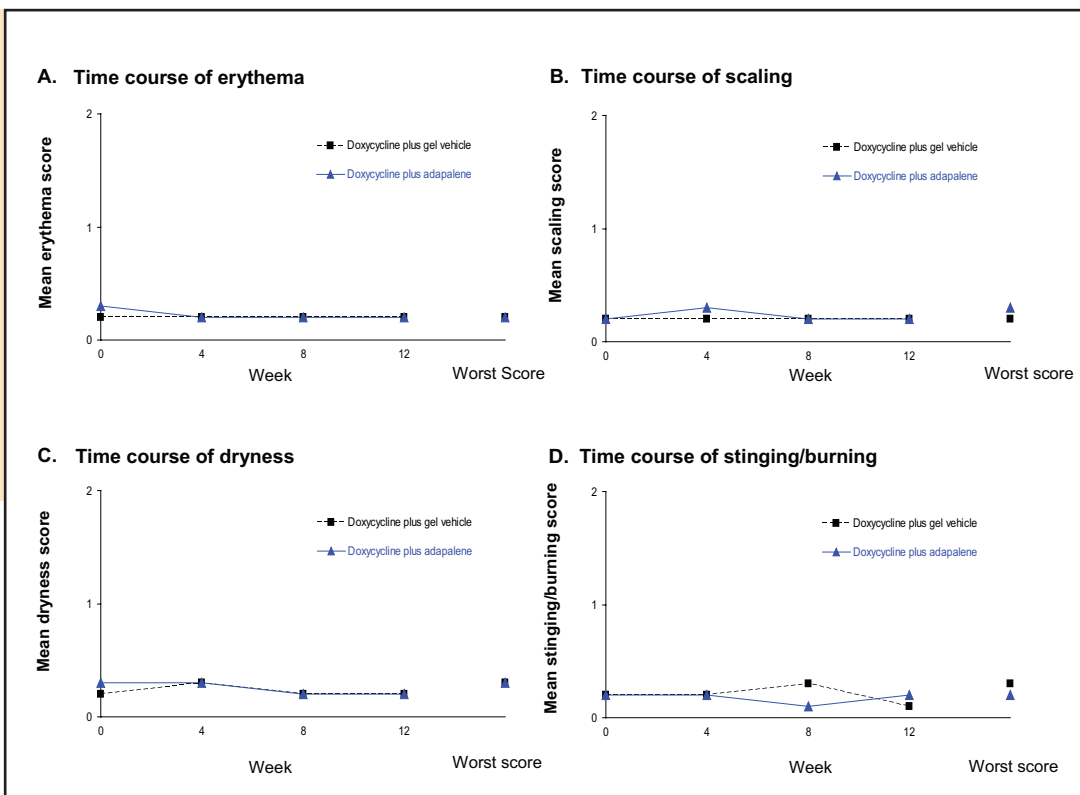


**Figure 4.** Effect of adapalene gel 0.1% plus doxycycline on severe facial acne lesions after 12 weeks of treatment

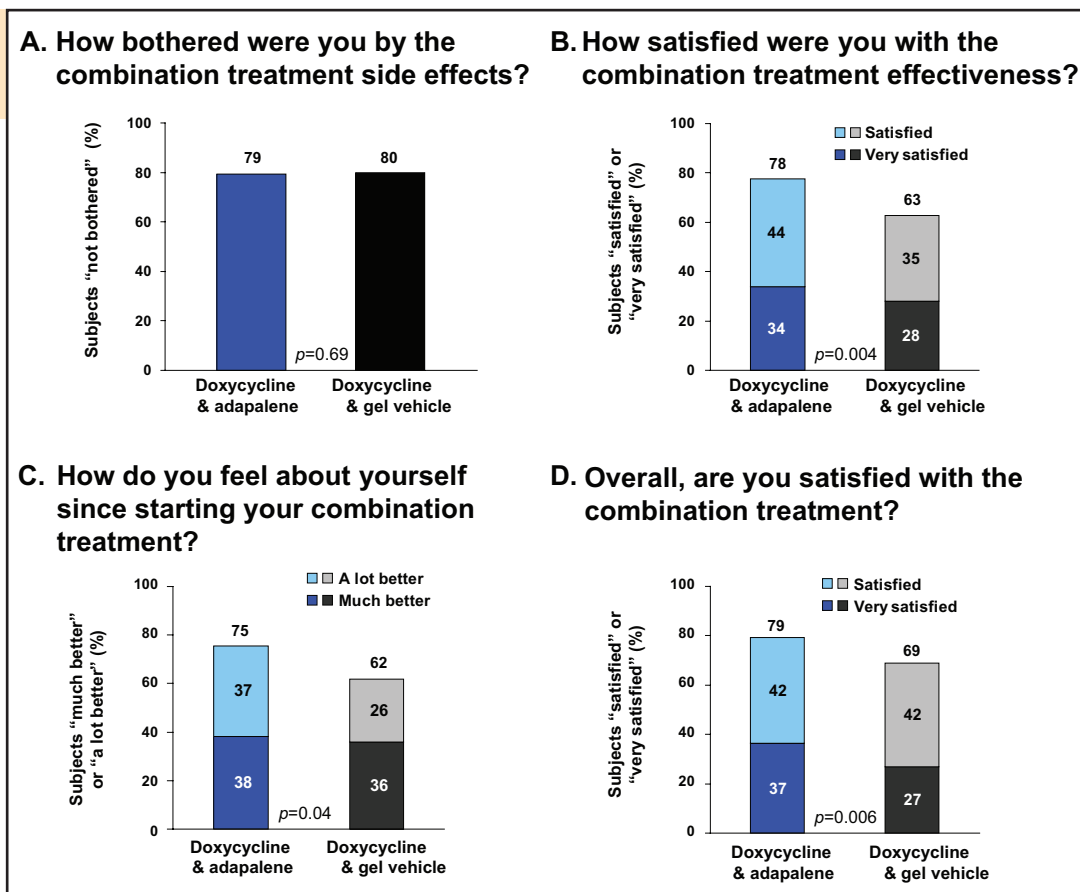
Both treatment regimens were safe and well tolerated, with similar incidences of adverse events. Treatment-related adverse

Combination Therapy for Severe Acne

**Figure 5.** Local tolerability. Effects of doxycycline plus adapalene vs. doxycycline plus gel vehicle on mean scores for skin tolerance variables: A, erythema; B, scaling; C, dryness; and D, stinging/burning. Skin tolerability variables were assessed according to the following scoring scale: none=0; mild=1; moderate=2; and severe=3. Mean scores at each post-baseline visit and worst score (worst observation recorded for a subject during the post-baseline period) are included in the figure.



**Figure 6.** Four-question subject survey (intent-to-treat population)



events were reported in 12.6% and 16.2% of subjects in the adapalene–doxycycline and doxycycline-alone groups, respectively, with most adverse events typical of oral antibiotic therapy. Topical therapy was well tolerated, as the worst post-baseline score for each of the local cutaneous tolerability variables was none or mild for a majority of subjects in both groups. The subject satisfaction survey demonstrated that the addition of adapalene did not increase the impact of side effects ( $p=0.69$ ) and that subjects had a significantly greater satisfaction with the combination adapalene–doxycycline therapy ( $p=0.006$ ). Of note, subjects receiving combination therapy felt better about themselves ( $p=0.04$ ), indicating the potential of aggressive combination therapy to limit the psychosocial effects of acne. The safety results of this study are similar to the tolerability noted in previous adapalene-plus-antibiotic combination therapy studies and consistent with the well documented safety profile of adapalene.<sup>15–21</sup> Regarded as the best tolerated topical retinoid,<sup>25</sup> adapalene is a logical choice for combination therapy, as it can be added to other therapies without significantly increasing skin irritation.

## Conclusions

Overall, this study shows that the combination of adapalene plus doxycycline is more effective than doxycycline alone for the treatment of acne vulgaris. The results support the existing published data showing the efficacy of combination therapy for the treatment of acne vulgaris.<sup>5–7,22,23</sup> The magnitude of the clinical benefit of the combination of adapalene and doxycycline is comparable to that seen in previous studies of the combinations of adapalene plus oral lymecycline and adapalene plus topical clindamycin.<sup>22,23</sup> The complementary as well as discrete mechanisms of action of adapalene and antibiotics produce a significantly superior—and faster—reduction of acne lesions, indicating that this therapeutic regimen may be useful at the onset of therapy to obtain an enhanced clinical response. As noted in previous studies, the addition of adapalene enhances the activity of the antibiotic in reducing inflammatory acne lesions, reflecting the anti-inflammatory properties of adapalene.<sup>10–12,22,23</sup> The faster response afforded by the combination regimen may also reduce the duration of

antibiotic therapy and thereby reduce the potential for developing resistance.

The early onset of action of the combination regimen, the similar tolerability of the combination relative to the antibiotic alone, and the complete concordance between physician and subject evaluation seen in this study provide strong evidence that such combination therapy should be used at the initiation of therapy. These results confirm the findings in the recently published consensus recommendations for the management of acne developed by the Global Alliance to Improve Outcomes in Acne.<sup>4</sup> The report states that adding a topical retinoid to antimicrobial therapy significantly improves the treatment of inflammatory acne, and it recommends the use of topical retinoids at the onset of therapy for all but the most severe cases of acne. For moderate-to-severe cases, the guidelines recommend adding a topical or oral antibiotic. In addition, the consensus guidelines emphasize the importance of maintenance therapy to prevent future lesion development and suggest utilizing effective agents with good skin tolerability, such as adapalene, for long-term use. Subjects who successfully responded to treatment in this study have recently completed a 16-week follow-up, controlled study to assess the maintenance effect of adapalene gel 0.1% monotherapy. The results of this study will soon be available.

The present study reinforces results of a previous clinical study: the combination of adapalene with an oral antibiotic provides significantly superior and faster improvements in inflammatory and noninflammatory lesions relative to antibiotic therapy alone in subjects with severe acne. The study confirms that the use of adapalene gel 0.1% in combination therapy is beneficial at the initiation of treatment for those suffering from acne.

**Acknowledgments and disclosure:** The authors would like to thank the following additional members of the Differin Study Group: **Dr. Elizabeth Arthur**, Rochester, NY; **Dr. Debra Breneman**, Cincinnati, OH; **Dr. Suzanne Bruce**, Houston, TX; **Dr. Alicia Bucko**, Albuquerque, NM; **Dr. Valerie Callender**, Mitchellville, MD; **Dr. Jeffrey Carmel**, Fremont, CA; **Dr. James Del Rosso**, Las Vegas, NV; **Dr. Zoe Diana Draelos**, Highpoint, NC; **Dr. Nancy Egan**, Rockland, ME; **Dr. Javier Flores**, Miami, FL; **Dr. Joseph Fowler**, Louisville,



## Combination Therapy for Severe Acne

KY; **Dr. Jon Hanifin**, Portland, OR; **Dr. Michael Jarratt**, Austin, TX; **Dr. Norman Kanof**, Port Chester, NY; **Dr. David Kaplan**, Overland Park, KS; **Dr. Steven Kempers**, Fridley, MN; **Dr. Bruce Miller**, Portland, OR; **Dr. Eugene Monroe**, Milwaukee, WI; **Dr. Amit Pandya**, Dallas, TX; **Dr. Marina Peredo**, Smithtown, NY; **Dr. Tooraj J. Raoof**, Encino, CA; **Dr. Phoebe Rich**, Portland, OR; **Dr. Ronald Savin**, New Haven, CT; **Dr.**

**Joel Schlessinger**, Omaha, NE; **Dr. Dow B. Stough**, Hot Springs, AR; **Dr. Leonard Swinyer**, Salt Lake City, UT; **Dr. Helen Mary Torok**, Medina, OH; **Dr. James Turner**, Memphis, TN; **Dr. David Whiting**, Dallas, TX; **Dr. Hector Wiltz**, Miami, FL; **Dr. John Wolf**, Houston, TX; and **David Cox, PhD** for editorial assistance. This study was funded by Galderma Research & Development, Princeton, NJ.

## REFERENCES

- Pawin H, Beylot C, Chivot M, et al. Physiopathology of acne vulgaris: recent data, new understanding of the treatments. *Eur J Dermatol*. 2004;14:4-12.
- Leyden JJ. A review of the use of combination therapies for the treatment of acne vulgaris. *J Am Acad Dermatol*. 2003;49:S200-S210.
- Layton AM. Psychosocial aspects of acne vulgaris. *J Cutan Med Surg*. 1998;2:19-23.
- Gollnick H, Cunliffe W, Berson D, et al. Management of acne: a report from a Global Alliance to Improve Outcomes in Acne. *J Am Acad Dermatol*. 2003;49:S1-S37.
- Korting HC, Braun-Falco O. Efficacy and tolerability of combined topical treatment of acne vulgaris with tretinoin and erythromycin in general practice. *Drugs Exp Clin Res*. 1989;15:447-451.
- Rietschel RL, Duncan SH. Clindamycin phosphate used in combination with tretinoin in the treatment of acne. *Int J Dermatol*. 1983;22:41-43.
- Mills OH Jr, Kligman AM. Treatment of acne vulgaris with topically applied erythromycin and tretinoin. *Acta Derm Venereol*. 1978;58:555-557.
- Gollnick H, Schramm M. Topical drug treatment in acne. *Dermatology*. 1998;196:119-125.
- Brogden RN, Goa KL. Adapalene: a review of its pharmacological properties and clinical potential in the management of mild to moderate acne. *Drugs*. 1997;53:511-519.
- Michel S, Jomard A, Demarchez M. Pharmacology of adapalene. *Br J Dermatol*. 1998;139(suppl 52):3-7.
- Vega B, Jomard A, Michel S. Regulation of human monocyte toll-like receptor 2 (TLR2) expression by adapalene [abstract]. *J Eur Acad Dermatol Venereol*. 2002;16:123-124.
- Shroet B, Michel S. Pharmacology and chemistry of adapalene. *J Am Acad Dermatol*. 1997;36:S96-S103.
- Cunliffe WJ, Poncet M, Loesche C, et al. A comparison of the efficacy and tolerability of adapalene 0.1% gel versus tretinoin 0.025% gel in patients with acne vulgaris: a meta-analysis of five randomized trials. *Br J Dermatol*. 1998;139:48-56.
- Waugh J, Noble S, Scott LJ. Adapalene: a review of its use in the treatment of acne vulgaris. *Drugs*. 2004;64:1465-1478.
- Dosik JS, Homer K, Arsonnaud S. Cumulative irritation potential of adapalene cream and gel, 0.1% compared to tazarotene cream, 0.05% and 0.1%. *Cutis*. In press.
- Greenspan A, Loesche C, Vendetti N, et al. Cumulative irritation comparison of adapalene gel and solution with 2 tazarotene gels and 3 tretinoin formulations. *Cutis*. 2003;72:76-81.
- Dunlap FE, Mills OH, Tuley MR, et al. Adapalene 0.1% gel for the treatment of acne vulgaris: its superiority compared to tretinoin 0.025% cream in skin tolerance and patient preference. *Br J Dermatol*. 1998;139:17-22.
- Caron D, Sorba V, Kerrouche N, et al. Split-face comparison of adapalene 0.1% gel and tretinoin 0.025% gel in acne patients. *J Am Acad Dermatol*. 1997;36:S110-S112.
- Egan N, Loesche MC, Baker MM. Randomized, controlled, bilateral (split-face) comparison trial of the tolerability and patient preference of adapalene gel 0.1% and tretinoin microsphere gel 0.1% for the treatment of acne vulgaris. *Cutis*. 2001;68(suppl 4):20-24.
- Brand B, Gilbert R, Baker MD, et al. Cumulative irritancy comparison of adapalene gel 0.1% versus other retinoid products when applied in combination with topical antimicrobial agents. *J Am Acad Dermatol*. 2003;49(3 suppl):S227-S232.
- Caron D, Sorba V, Clucas A, et al. Skin tolerance of adapalene 0.1% gel in combination with other topical antiacne treatments. *J Am Acad Dermatol*. 1997;36:S113-S115.
- Wolf JE Jr, Kaplan D, Kraus SJ, et al. Efficacy and tolerability of combined topical treatment of acne vulgaris with adapalene and clindamycin: a multicenter, randomized, investigator-blinded study. *J Am Acad Dermatol*. 2003;49:S211-S217.
- Cunliffe WJ, Meynadier J, Alirezai M, et al. Is combined oral and topical therapy better than oral therapy alone in patients with moderate to moderately severe acne vulgaris? A comparison of the efficacy and safety of lymecycline plus adapalene gel 0.1%, versus lymecycline plus gel vehicle. *J Am Acad Dermatol*. 2003;49(3 suppl):S218-S226.
- Thiboutot D. New treatments and therapeutic strategies for acne. *Arch Fam Med*. 2000;9:179-187.
- Haider A, Shaw JC. Treatment of acne vulgaris. *JAMA*. 2004;292:726-735.