

Nail Surgery: A Review

RONALD J. SIEGLE, M.D., AND NEIL A. SWANSON, M.D.

The ability to perform nail surgery broadens a physician's diagnostic and therapeutic capabilities in managing disorders or dysfunction of the nail apparatus. Nail anatomy and function are reviewed. Principles and general techniques of nail surgery are presented as a background for the discussion of several commonly employed surgical procedures.

The nail, the largest of the skin adnexa, is unique to primates and appears to have evolved from the claw of lower animals.¹ It has many functions,¹ the most important of which is prehension. Without nails our ability to grasp and manipulate objects would be limited. Nails also protect the delicate distal phalanx and the soft tissues of the distal digit. For man, the nail is also of cosmetic importance. Lastly, as objects with which to scratch, nails can give dramatic and immediate relief to localized areas of pruritus.

Since disorders or dysfunctions of the nail apparatus often come to the dermatologist's attention for treatment, his ability to perform nail surgery necessarily broadens his diagnostic and therapeutic capabilities in managing these complaints. A discussion of some principles of nail surgery and specific surgical techniques used in the treatment of such disorders follows.

NAIL ANATOMY AND FUNCTION

When performing nail surgery it is imperative that the surgeon know the anatomy^{1,2,3} of the nail apparatus (Fig. 1) and the functional roles played by each of its components.^{2,3} The proximal or posterior nail fold, an extension of the dorsal skin of the digit over the nail

matrix and proximal nail plate, folds back on itself creating a superficial (dorsal) and deep (ventral) epithelial surface. The cuticle, the horny layer extension of the proximal nail fold which extends for a short distance distally onto the nail plate, seals the potential space between the nail plate and the proximal nail fold. Laterally, the proximal nail fold is continuous with the lateral nail walls.

The nail matrix, the germinal epithelium which forms the nail plate, begins 3–5 mm proximal and deep to the cuticle and extends distally to the junction of the lunula and the nail bed. It is separated from the underlying distal phalanx by only several millimeters. The lunula, the distal-most matrix, is the component that is visible as a white crescent on the thumb and great toe. Although present on all digits, it is clinically visible to a varying degree on the lesser digits. The nature of origin of this white color, present both on the nail plate as well as the matrix, is still debated.² The distal convex border of the lunula is responsible for the shape of the nail and should be maintained when performing surgery.² The proximal matrix that extends laterally and proximally is termed the lateral matrix horn, and becomes important at the time of surgery because in some people this area extends far laterally as well as volarly.

The nail itself is a nearly rectangular, dense, keratin plate that sits in the proximal and lateral nail folds and is adherent to the underlying nail matrix and bed. The nail bed, which extends from the distal lunula to the point of nail plate-bed separation, is composed of parallel and longitudinally arranged ridges that mesh with similar ridges on the undersurface of the nail plate which it supports. The onychodermal band is a faint, yellow line just proximal to the free white edge of the nail plate and is a marker for the area of nail plate–nail bed separation. The hyponychium extends from the onychodermal band to the distal groove, a wide transverse groove that separates the hyponychium from the volar skin of the digit. The paronychia are

Dr. Siegle is a Resident, Department of Dermatology, University of Michigan Medical Center, Ann Arbor, Michigan.

Dr. Swanson is Assistant Professor of Dermatology, and Director, Mohs Surgery Unit, University of Michigan Medical Center, Ann Arbor, Michigan.

Address reprint requests to Neil A. Swanson, M.D., Department of Dermatology, C-2065 Outpatient Building, University of Michigan, Ann Arbor, MI 48109.

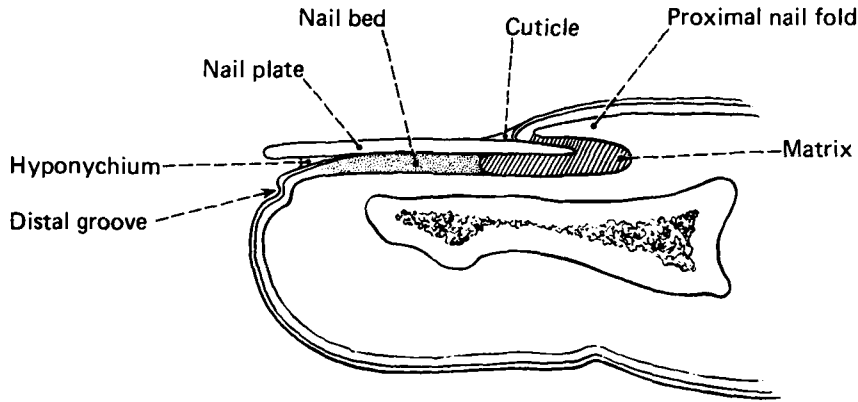


FIGURE 1. Anatomy of a nail.

soft tissues that surround the nail plate and include the proximal nail fold, the lateral nail walls, and the lateral nail folds. Due to the absence of subcutaneous tissue beneath the nail apparatus, the dermis sits directly on the distal phalanx.

The blood supply to the nail apparatus comes from two arches, a proximal and a distal, that originate from the digital arteries in the pulp space below the distal phalanx. Additionally, there is a branch of the digital artery that runs dorsally over the distal interphalangeal joint to anastomose with the proximal arch. These branch, creating an extensive capillary network seen clinically as the bright pink color of the nail.³

The site of nail-plate formation has been and still is a source of great controversy.¹⁻⁴ It is generally agreed that most of the nail plate does come from the nail matrix area as previously defined. Additionally, there is a component of the nail matrix that exists on the ventral surface of the proximal nail fold. Other sites of debated nail plate origin include the nail bed and the area of the onychodermal band. Zaias⁵ has demonstrated that the upper half of the nail plate originates from the proximal matrix and the bottom half from the more distal or lunular matrix.² Nail thickness is directly correlated with the length of the nail matrix and the rate of nail growth is a function of the rate of proliferation of the matrix cells. Fingernails grow roughly 0.1 mm per day⁶ and they outgrow toenails by a factor of approximately 2 or 3 to 1.³

PRINCIPLES AND GENERAL TECHNIQUES OF NAIL SURGERY

The surgical approach to nail disease has four main objectives, namely, relief of pain, treatment of infection, development of access to subungual problems,

and correction of anatomical deformities.⁷ Some principles of nail surgery and general surgical techniques that allow these objectives to be met will be discussed.

A number of nail disorders that require surgical intervention are often accompanied by significant paronychia inflammation and possibly infection. It is important that these infections be controlled preoperatively since the consequences of extensive digital cellulitis may be severe, e.g., osteomyelitis. For example, treatment of an ingrown toenail should include avulsion of that part of the nail plate embedded in the lateral nail wall as well as antiseptic soaks. If the infection is severe, oral antibiotics are indicated and clinical resolution of the infection is required prior to performing a definitive surgical procedure. At times, antibiotics may be continued during the procedure and for a short time postoperatively.

Anesthesia is obtained using 1% plain Lidocaine. In cases where an extended surgical procedure is anticipated, longer-acting Marcaine or Duranest can be used to achieve anesthesia. The anesthetic may be given locally by direct injection into the area of planned surgery, most commonly the proximal nail fold, or anesthesia may be obtained by a digital block. Here, 1-2 cc of Lidocaine is injected slowly into both the lateral and the medial sides of the digit at its most proximal portion. A partial block anesthesia, blocking only one side of the digit, may be used though local anesthesia is often also needed.

Because the nail apparatus has such an extensive capillary network, achieving hemostasis is a real concern. Although not mandatory, appropriate use of a tourniquet allows for a clean and dry surgical field and, therefore, more efficient surgery. Most commonly a wide Penrose drain tourniquet, secured with a hemostat, is sufficient for short surgical procedures. There

are times when a bloodless field is required and in such cases an "exsanguinating" tourniquet is appropriate. To make such a tourniquet, one can cut off a 2 cm circumferential band from the cuff of a used surgical glove. The band is then cut open giving a long rubber strip which can then be used to wrap the digit in overlapping bands from the distal end. Beginning distally, this strip is then rolled back on itself creating a donut-like tourniquet where it will remain securely fastened at the base of the now exsanguinated digit. Any tourniquet should be applied just before the surgical procedure begins and be removed as soon as possible thereafter. Tourniquets are not needed for simple nail plate avulsions.

Bleeding, particularly after releasing the tourniquet, may be extensive. However, because the vessels involved are small, bleeding can usually be controlled with use of direct pressure, Monsel's solution, or Oxycel.

Aseptic technique when performing nail surgery is similar to that used when performing any cutaneous surgery. However, it is not necessary when performing a simple nail plate avulsion.

There are a number of general principles recommended for postoperative care. Generally, an antibiotic ointment is placed on the wound. A dressing should be bulky, so as to absorb any postoperative bleeding and to provide a cushion against local trauma. It should also be non-constricting and be removed after 24 hours. The involved extremity should be elevated as much as possible for the first 48 hours postoperatively. When the dressing is removed, antiseptic soaks should begin for 15–30 minutes t.i.d. The wound should then be dressed with an antibiotic ointment and a nonadherent pad or Bandaid. Any sutures should be removed in 7–10 days. Since pain may be significant, analgesia with acetaminophen with codeine or some similar non-aspirin-containing drug should be available. Lastly, antibiotics are rarely indicated unless an obvious infection was present at the time of surgery. Postoperative infection is uncommon following procedures performed with proper surgical technique and appropriate care of the wound by the patient. When infection does occur, wounds should be cultured and treated immediately with oral antibiotics and soaks.

SPECIFIC SURGICAL PROCEDURES

With knowledge of the aforementioned principles and techniques of nail surgery, we can now discuss some specific surgical techniques. Additional information can be found in a number of surgical reference books.^{7–11} No further discussion of anesthesia, hemostasis, pre-operative or postoperative care will be given unless required for a specific procedure.

NAIL PLATE AVULSION

The first and simplest surgical technique is that of nail plate avulsion (Fig. 2)^{2,10,12} which requires only a straight, blunt-ended hemostat. With the grooved surface of the hemostat applied to the dorsal nail plate, the proximal nail fold is freed from the nail plate using longitudinal back and forth motions. This is repeated on the undersurface of the nail, again keeping the grooved surface of the hemostat directly opposed to the nail plate, thus freeing the nail plate from the bed. The plate may then be clamped with the hemostat along one of the lateral margins, rolled gently from the lateral nail fold and lifted from the digit.

NAIL BED/MATRIX EXPLORATION

Exploration of the nail apparatus is indicated for a number of nail disorders. Nail bed exploration¹² requires simple avulsion of the nail plate. For nail matrix exploration, two incisions, each extending laterally and proximally, are made at the junction of the proximal and lateral nail folds (Fig. 3).¹² Blunt dissection of the flap of the proximal nail fold will expose the matrix and, if the incisions are carried far enough laterally,

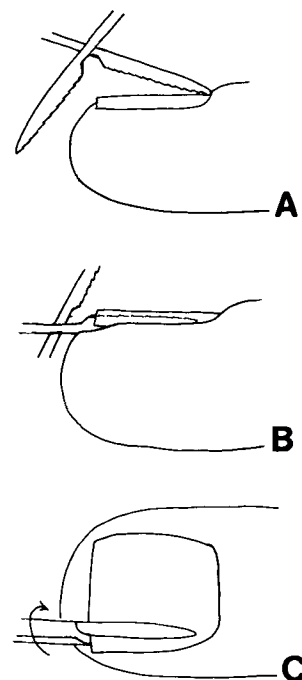


FIGURE 2. Avulsion of a nail plate. (A) Nail plate-proximal nail fold separation. (B) Nail plate-nail bed separation. (C) Rotation of the nail plate off the digit.

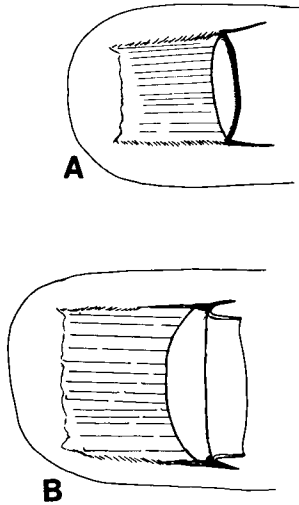


FIGURE 3. Exploration of a nail matrix. (A) Symmetric incisions freeing the proximal nail fold. (B) Proximal nail fold reflection exposing the matrix.

maximal visualization of the lateral matrix horns will be possible. Following the procedure, the flap is either loosely sutured or steristripped in place.

NAIL BED BIOPSY

There are many ways to perform nail biopsies.^{2,7,10,12-14} There are two general rules to be followed: 1) perform an x-ray if there is significant distortion of the tissue or if you are unsure of the pathology involved and 2) given a choice of nail bed versus nail matrix biopsy, perform the former. Indications for this surgical procedure include diagnosis of a disease, a tumor, or an unknown lesion. Of the two techniques for biopsy of the nail bed we will discuss, the first employs either avulsion of a full nail plate or avulsion of the distal half of a nail plate. A standard punch biopsy or a longitudinal elliptical wedge of tissue down to the bone may be taken (Fig. 4) for this purpose. If using a 3 mm or smaller punch, the biopsy site need not be closed. For longitudinal biopsies, the site should be closed by undermining and placement of 4-0 nylon sutures for any biopsy wider than 2 mm. A second technique for biopsy of a nail bed leaves the nail plate in place. Two punches are used: the first and larger punch to remove a circular defect in the nail plate and a second, smaller punch to biopsy the nail bed through

the nail plate defect created by the first, larger punch. Scarring from biopsies of nail beds is uncommon.

NAIL MATRIX BIOPSY

Biopsy of the nail matrix,^{2,7,10,12-18} while most often indicated to rule out the presence of malignancy, can also be used to diagnose pathology of nail plates. In biopsying pigmented lesions it is important to mark the proximal nail fold so that following nail plate avulsion it is still obvious where the pigmented change existed. Following avulsion of the nail plate, the proximal nail fold is exposed as previously described. Two important points to remember when performing nail matrix biopsies are to maintain the curvilinear configuration of the distal lunula and not to split the matrix longitudinally. Biopsies may be performed with a small punch biopsy or a fusiform excision, with each carried down to the bone (Fig. 5). The long axis of a biopsy should be parallel with the distal border of the lunula. If lunular morphology is maintained and, as described for nail bed biopsies, if a biopsy site is small, then the defect does not need to be sutured. Biopsy of a visible lunula, as on the great toe, can also be performed with the two-punch technique previously described for nail bed biopsy. It should be assumed that some permanent defect will result in the nail plate from biopsies of the nail matrix, but if performed properly, such defects will be barely visible.

It is also possible to biopsy both the nail matrix and nail bed at one time, particularly to determine the extent of a probable malignancy. Usually, the nail plate is avulsed but if part of the plate is to be part of the biopsy specimen then only the plate on each side of the area to be biopsied should be avulsed. With a scalpel and scissors, a rectangular block, including the

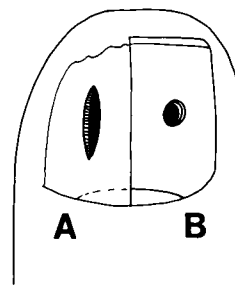


FIGURE 4. Biopsy of the nail bed. (A) Longitudinal ellipse after nail plate avulsion. (B) Two punch technique without nail plate avulsion.

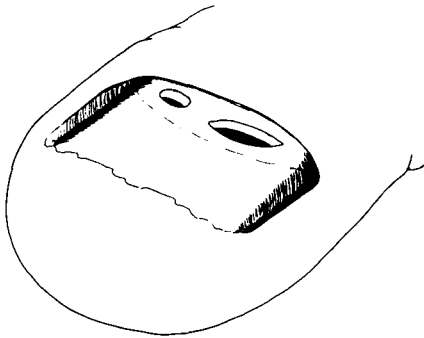


FIGURE 5. Biopsy of a nail matrix.

hyponychium, nail bed, nail matrix, and proximal nail fold with or without the nail plate, is excised en bloc down to the bone (Fig. 6). The width of the biopsy should be limited to 3 mm. The surrounding tissues are then undermined and closed, again taking care to ensure good lunular approximation.

PROXIMAL NAIL FOLD BIOPSY

Occasionally, the proximal nail fold needs to be biopsied.¹³ The indications here are the same as for any routine skin biopsy. Anesthesia may be local and the biopsy of choice is a 2 mm punch advanced down to the nail plate. The plug can then be lifted free and closure is unnecessary. It is important to avoid cutting the margin of the fold as this would make scarring more likely.

MATRICECTOMIES

Matricectomies or ablation of the nail matrix are indicated for many disorders, namely, recalcitrant ingrown toenails (onychocryptosis), onychauxis (thickened nails), onychogryphosis, onychomycosis, split nails, and congenital nail dystrophies. Matricectomies

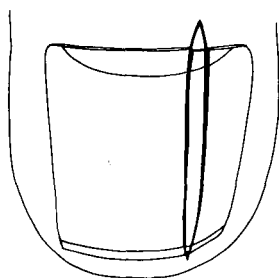


FIGURE 6. Combined nail matrix-nail bed biopsy.

are performed using many different techniques that employ various surgical, chemical, and electrical modalities. This diversity in the number and kind of techniques used reflects the poor success rate of most of them. We will discuss only a few.

Chemosurgical matricectomies are very effective techniques well known to podiatrists, but rarely employed by medical physicians. The first technique we describe employs liquefied phenol (carbolic acid) in 88% concentration. Following nail plate avulsion the matrix is debulked with a #1 curette (Fig. 7). Particular importance should be placed on curetting the lateral matrix horn. A tight or exsanguinating tourniquet creating a mandatory bloodless field is placed and the surrounding periungual tissues are then protected with Vaseline. The phenol is applied using saturated, but not dripping, cotton tip applicators. Three, thirty-second applications are performed during which the matrix is vigorously massaged. It is important to push laterally into the lateral matrix horns and dorsally to treat the matrix present on the ventral surface of the proximal nail fold. The phenol is then diluted with 70% isopropyl alcohol and the tourniquet is released. Bleeding is usually absent or minimal. There is usually little

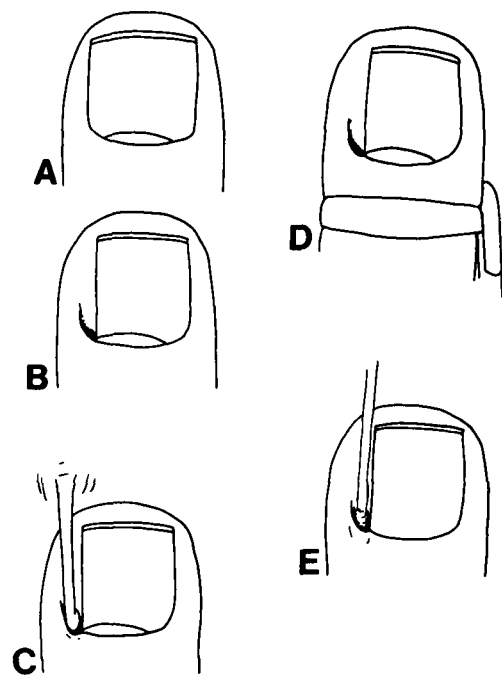


FIGURE 7. Phenol matricectomy for ingrown nail. (A) Preoperatively. (B) Partial plate avulsion. (C) Matrix curettage. (D) Tight or "exsanguinating" tourniquet. (E) Phenol application.

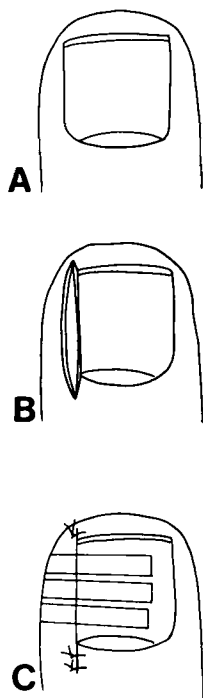


FIGURE 8. Longitudinal matricectomy for ingrown nail. (A) Preoperatively. (B) Combined nail plate, nail matrix, and soft tissues excision. (C) Closure.

grad's technique, that is performed in the same manner as the combined longitudinal nail bed and matrix biopsy already described (Fig. 8). However, there is no 3 mm width limitation to the excision and the wound does not always need to be closed. When used for ingrown nails, it is important to carry the dissection down to the bone as well as proximally and laterally from the proximal nail fold to insure removal of the lateral matrix horn. This particular approach also allows a wide excision to be made through the lateral nail wall and, therefore, allows both definitive removal of the nail matrix as well as excision of any lateral wall hypertrophy that may be present. Compared to the phenol procedure, however, this technique requires more time, more surgical expertise, and results in much greater morbidity. The success rate for longitudinal matricectomies may approach 90% under optimal conditions.

The more radical surgical matricectomies attempt to destroy all potential nail-forming sites. The most effective of these is an en bloc excision of the entire nail apparatus beginning just distally to the distal interphalangeal joint and extending to the end of the digit.²⁵ The distal phalanx is then shortened using bone ronguers and the now free distal pulp of the digit acts as a flap which is used to close the dorsal defect. The success of this technique approaches 100%. The morbidity is surprisingly low, and the protective function of the nail is maintained by the use of the distal digital fat pad as a "cushion." This is an excellent technique for someone with recalcitrant ingrown nails whose occupation requires a good deal of walking and protection of the toe, e.g., a construction worker.

pain and most patients rarely require anything more than acetaminophen. The patient is allowed to return to work immediately.

Either partial or total matricectomies may be employed to manage ingrown nails. If doing a partial matricectomy only the portion of the nail to be destroyed should be avulsed. This technique does not treat hypertrophy of a nail wall and an additional surgical procedure performed simultaneously may be necessary. The success rate for phenol matricectomies is greater than 95%.¹⁹⁻²¹

A newer but similar chemosurgical technique employs 10% sodium hydroxide.²² While this technique reportedly has a shorter healing time, it does require more expertise to perform. Success rates are similar to those of phenol.

Matricectomies using cold steel surgery, the standard approach taken by most medical physicians, have had significant recurrence and morbidity rates. In general, the more radical the surgery the greater the chance of success. Most of the techniques reflect variations on the procedures initially defined by Zadik²³ and Winograd²⁴ for treatment of ingrown toenails. We employ a longitudinal matricectomy, similar to Wino-

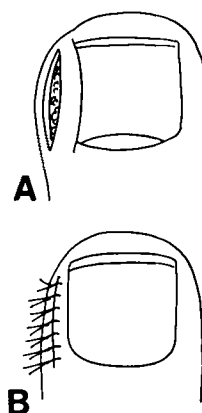


FIGURE 9. Soft tissue resection for hypertrophy of a nail wall. (A) Excision with sparing of the nail fold. (B) Closure.

SOFT TISSUE RESECTIONS FOR INGROWN NAILS

Specifically, when dealing with the problem of ingrown nails with lateral wall hypertrophy, there are nonmatricectomy nail-sparing techniques in which the nail matrix and, therefore, the nail plate are maintained at the expense of the surrounding soft tissues. The simplest nail-sparing technique involves avulsion, either partial or whole, of the nail with removal of the hypertrophied component of the lateral nail wall by excision, cauterization, or curettage. If there is prominent hypertrophy of the nail wall, a large resection of the nail wall may be performed. As seen in Figure 9, an ellipse can be excised along the length of the nail wall but separate from the nail fold. This excision should be carried deep into the subcutaneous tissue and then closed with simple interrupted 4-0 nylon sutures. A similar technique includes the lateral nail wall and fold in the wedge excision. The nail plate is then steristripiped to the new lateral nail wall (Fig. 10). The success rate of the nail-sparing procedures increases from 30% seen with the simple nail plate avulsions²⁶ to 50–70%.²⁷

None of these surgical procedures require extensive

surgical expertise. What they do require is a thorough awareness of the structure and function of the nail apparatus as well as of the many diseases which can affect the nail. With this background, the physician should be able to approach problems of the nail both medically and surgically and, therefore, be able to offer the patient the best possible evaluation and treatment of his particular problem.

ACKNOWLEDGMENT

James Harkness, D.P.M., kindly provided the line drawings used in this article.

REFERENCES

1. Montagna, W., and Parakkal, P. Nails. In: *The Structure and Function of the Skin*. New York, Academic Press, 1974, pp. 271–278.
2. Zaias, N. *The Nail in Health and Disease*. New York, Spectrum Publications, Inc. 1980.
3. Samman, P. D. *The Nails in Disease*. London, Heineman Medical Books, Ltd., 1978.
4. Samman, P. D. The nails. In: Rook, A., Wilkinson, D. S., and Ebling, F. J. G., eds. *Textbook of Dermatology*. London, Blackwell Scientific Publications, 1979, pp. 1825–1855.
5. Zaias, N., and Alvarez, J. The formation of the primate nail plate. An autoradiographic study in squirrel monkeys. *J. Invest. Dermatol.* 51:120–136, 1968.
6. Bean, W. B. Nail growth: 30 years of observation. *Arch. Intern. Med.* 134:497–502, 1974.
7. Fosnaugh, R. P. Surgery of the nail. In: Epstein, E., and Epstein, E., Jr., eds. *Skin Surgery*. Springfield, Illinois, Charles C Thomas, 1978, pp. 725–755.
8. Hymes, L. Forefoot Minimum Incision Surgery in Podiatric Medicine. Mount Kisco, New York, Futura Publishing Co., Inc., 1977.
9. Mann, R. A. *DuVries' Surgery of the Foot*. Saint Louis, C.V. Mosby Co., 1978.
10. Scher, R. K. Nail surgery. In: Epstein, E., and Epstein, E., Jr., eds. *Techniques in Skin Surgery*. Philadelphia, Lea and Febiger, 1979, pp. 164–170.
11. Weinstein, F. *Principles and Practice of Podiatry*. Philadelphia, Lea and Febiger, 1968.
12. Krull, E. A. Surgical treatment of nail disorders. Presented at the annual meeting, American Academy of Dermatology, New York, 1980.
13. Stone, O. J., Barr, R. J., and Herten, R. J. Biopsy of the nail area. *Cutis* 21:257–260, 1978.
14. Scher, R. K. Punch biopsies of nails: A simple, valuable procedure. *J. Dermatol. Surg. Oncol.* 4:428–530, 1978.
15. Baran, R., and Sayag, J. Nail biopsy—why, when, where, how? *J. Dermatol. Surg. Oncol.* 2:322–324, 1976.
16. Bennett, R. G. Technique of biopsy of nails. *J. Dermatol. Surg. Oncol.* 2:325–326, 1976.
17. Scher, R. K. Biopsy of the matrix of a nail. *J. Dermatol. Surg. Oncol.* 6:19–21, 1980.
18. Scher, R. K. Longitudinal resection of nails for purposes of biopsy and treatment. *J. Dermatol. Surg. Oncol.* 6:805–807, 1980.

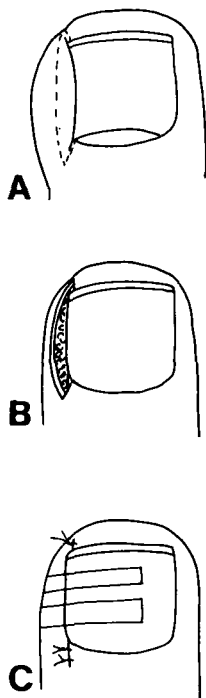


FIGURE 10. Soft tissue resection for hypertrophy of a nail wall. (A) Planned excision including nail wall and nail fold. (B) Excision with nail plate left intact. (C) Closure.

19. Boll, O. F. Surgical correction of ingrowing nails. *J. Am. Podiatry Assoc.* 35:8-9, 1945.
20. Suppan, R. J., and Ritchlin, J. D. A nondebilitating surgical procedure for "ingrown toenail." *J. Am. Podiatry Assoc.* 52:900-902, 1962.
21. Siegle, R. J., Harkness, J. J., and Swanson, N. A. The phenol alcohol technique for permanent matricectomy. *J. Dermatol Surg. Oncol.* Submitted for publication.
22. Travers, G. R., and Ammon, R. G. The sodium hydroxide chemical matricectomy procedure. *J. Am. Podiatry Assoc.* 70:476-478, 1980.
23. Zadik, F. R. Obliteration of the nailbed of the great toe without shortening of the terminal phalange. *J. Bone Joint Surg.* 32:66-67, 1950.
24. Winograd, A. M. A modification in the technique of operation for ingrown toenail. *JAMA* 92:229-230, 1929.
25. Rees, R. W. M. Radical surgery for embedded or deformed great toenails. *Proc. R. Soc. Med.* 57:355-356, 1964.
26. Murray, W. R., and Bedi, B. S. The surgical management of ingrowing toenail. *Br. J. Surg.* 62:409-412, 1975.
27. Murray, W. R., and Robb, J. E. Soft-tissue resection for ingrowing toenails. *J. Dermatol. Surg. Oncol.* 7:157-158, 1981.