

Defects of the Broad Ligament of the Uterus

Robert Cilley, M.D., Karl Poterack, B.S., John Lemmer, M.D., and Donald Dafoe, M.D.

Section of General Surgery, University of Michigan Hospitals, Ann Arbor, Michigan

A case of intestinal obstruction resulting from passage of the entire small bowel and cecum and its mesentery through a fenestration in the broad ligament of the uterus is presented. A review of the literature reveals that broad ligament defects may occur in multiple locations, which may be responsible for intestinal obstruction. A simple classification of broad ligament defects is proposed. Type 1 defects occur caudal to the round ligament of the uterus. Type 2 defects occur above the round ligament. Type 3 defects occur between the round ligament and the remainder of the broad ligament, through the meso-ligamentum teres.

INTRODUCTION

Defects can occur at multiple sites in the broad ligament of the uterus and may be responsible for the entrapment of abdominal viscera (1, 2). These defects have not been systematically classified. We describe an interesting case of such an occurrence and present a classification of broad ligament defects. This classification is based on the nature of the defect and its anatomic location in relationship to the round ligament of the uterus.

CASE REPORT

R.S. is a 63-yr-old black woman who presented with a 36-h history of abdominal pain and vomiting with one episode of diarrhea. Similar but less severe pain had occurred infrequently over the past several years. Her past medical and surgical history was otherwise unremarkable except for a tubal ligation 25 yr before admission.

Physical examination revealed a frail woman in moderate distress. She was afebrile with stable vital signs. Abdominal inspection showed marked distention with an old 6-cm infraumbilical vertical incision. Bowel sounds were hypoactive. There was generalized tenderness to palpation with localization to the left lower quadrant. Pelvic and rectal examinations were unremarkable.

Laboratory studies included a white blood cell count of 12,100/mm³. Abdominal x-rays showed multiple loops of dilated small bowel with air-fluid levels and the presence of some air in the distal large bowel.

With the diagnosis of intestinal obstruction, after vigorous fluid resuscitation, the patient was taken to the operating room. At operation it was noted that except for a 10-cm segment of small bowel, the entire small bowel and cecum had passed beneath the left round ligament of the uterus through a 2-cm fenestration in the broad ligament such that the mesentery of the small bowel and the ascending colon filled the defect (type 3 complete broad ligament defect, see below). Blood flow to this 10-cm segment was compromised whereas the remainder of the bowel appeared normal (Figs. 1 and 2). It was impossible to ascertain whether this short segment had failed to pass through the fenestration with the rest of the bowel or whether it had returned back through the fenestration as a secondary event. The round ligament was divided allowing for return of incarcerated intestine to its normal anatomic position. The entire bowel appeared viable. The patient had an uneventful recovery and was discharged on the 5th postoperative day. She has remained asymptomatic since her discharge 4 months ago.

DISCUSSION

A review of the literature revealed 47 cases of intestinal obstruction secondary to broad ligament defects in which the nature of the defect and the anatomic site were specified. These defects have not been systematically classified. We propose a simple anatomic classification based on the nature of the defect and its location. Three kinds of defects of broad ligament structures can occur. Complete defects or true fenestrations may be present which allow the passage of viscera with potential strangulation. These are by far the most common (2, 4). Single layer defects in the peritoneum of the broad ligament may occur which allow visceral structures to enter and become entrapped in the parametrial tissues (2, 5). Rarely defects are present which allow the herniation of abdominal viscera covered by a double layer of attenuated peritoneum. These represent true internal hernias (2, 4). Defects can occur in three anatomic sites (Fig. 3). Type 1 defects occur in the broad ligament caudal to the round ligament of the uterus (1-3). Type 2 defects occur in the broad ligament above the round ligament, including defects in the suspensory ligament

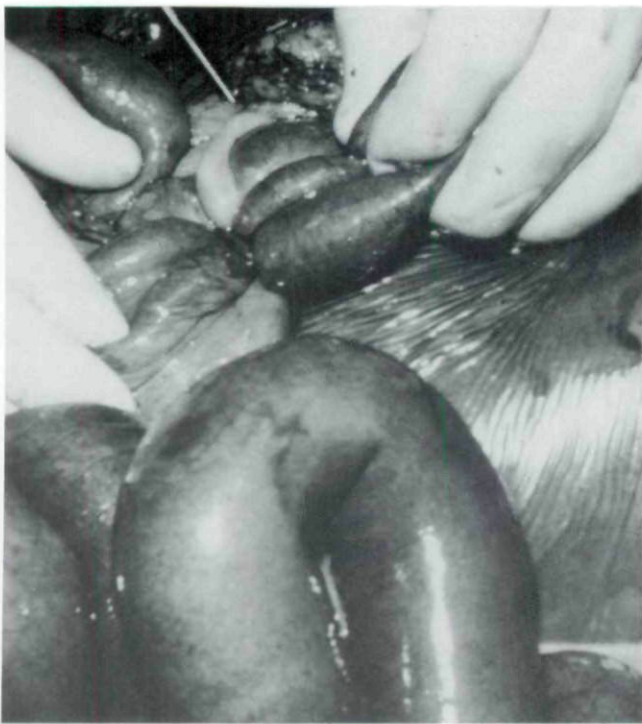


FIG. 1. Operative photograph showing entire small bowel and cecum beneath round ligament of the uterus (type 3 complete defect).

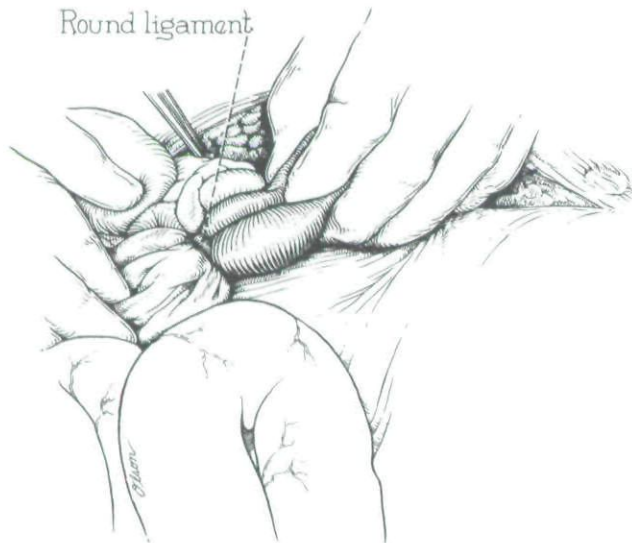


FIG. 2. Illustrative drawing of operative photograph.

of the ovary, the mesosalpinx, and the utero-ovarian ligament (2, 5, 10). Type 3 defects occur in the "mesoligamentum teres" of the uterus. This is the two-layered peritoneal surface between the round ligament and the remainder of the broad ligament and was responsible for the intestinal obstruction reported herein (3, 7). For a tabulation of previously reported broad ligament defects by nature and location of defect see Table 1.

The relationship of broad ligament defects to previous abdominal or pelvic surgery is variable. Numer-

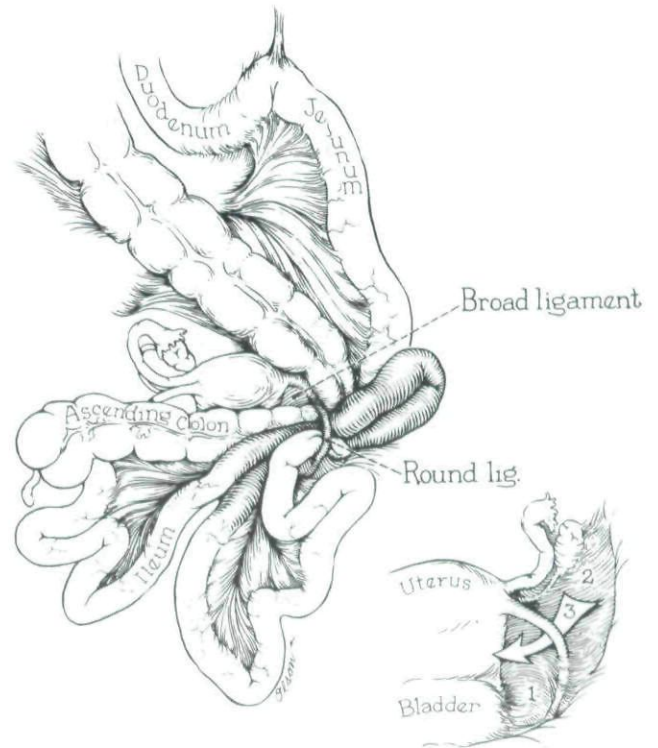


FIG. 3. Illustrative drawing showing classification of broad ligament defects, types 1, 2, and 3.

TABLE 1
*Review of 47 Cases of Broad Ligament Defects**

Nature of Defect	Anatomic Site		
	Type 1	Type 2	Type 3
Complete	31	3	4
Single layer	2	5	
True hernia		2	

* Included in type 1 complete defects are 25 cases presumed to be secondary to uterine suspension operations, as this is the type of defect created in these operations.

ous cases have been reported of broad ligament defects responsible for intestinal obstruction in patients who have not undergone prior surgery (5, 9). However, there is a well-recognized association with the Baldy-Webster uterine suspension operation where a defect is created in the broad ligament as a part of the procedure (6, 8, 10). This procedure is no longer performed. In the case reported herein, a previous tubal ligation was apparently unrelated to the type 3 complete defect.

There are several notable features of this case. The entire small bowel on its mesentery as well as the mobile cecum had passed through the defect without apparent complication. A small loop of bowel however had either not passed through with the remainder of the intestines or had returned back through the defect. Strangulation of this loop resulted in the symptoms which prompted operation. Correction was easily accomplished by divi-

sion of the round ligament and postoperative recovery was uneventful.

Reprint requests: Donald C. Dafoe, M.D., D-2242 MPB, Box 46, Section of General Surgery, University of Michigan Hospitals, Ann Arbor, MI 48109.

REFERENCES

1. Armstrong CP, Drummond A. Small bowel obstruction and perforation through a defect in the broad ligament. *J R Coll Surg Edinb* 1983;28:333-4.
2. Baron A. Defect in the broad ligament and its association with intestinal strangulation. *Br J Surg* 1948;36:91-4.
3. Goode TV, Newbern WR. Intestinal obstruction associated with defects in the broad ligaments of the uterus—review of literature and case report. *Am J Surg* 1944;65:127-32.
4. Hunt AB. Fenestrae and pouches in the broad ligament as an actual and potential cause of strangulated intra-abdominal hernia—report of two cases without strangulation, with review of literature. *Surg Gynecol Obstet* 1934;85:906-13.
5. Mathieson AJ, Millar WG. Ileovaginal fistula complicating internal hernial strangulation through a broad ligament defect. *Br J Surg* 1971;58:353-5.
6. Michael MA. Internal hernia following round ligament suspension, report of two cases. *JAMA* 1936;107:1293-4.
7. Pidcock BH. Two cases of intestinal obstruction. *Br Med J* 1924;1:369-70.
8. Pulrang S. Disastrous sequelae to the Webster-Baldy operation—case report. *Am J Surg* 1944;65:281-5.
9. Rose D. Congenital bowel invagination into the broad ligament—report of a case. *Obstet Gynecol* 1963;21:218-19.
10. Wills SA. Intestinal obstruction associated with a hiatus in the broad ligament—a case report. *Am J Obstet Gynecol* 1957;74:1143-5.

This document is a scanned copy of a printed document. No warranty is given about the accuracy of the copy. Users should refer to the original published version of the material.